



# Use of the Ranger Paclitaxel-Coated Balloon in Patients With Chronic Limb-Threatening Ischemia: Short-Term Safety and Efficacy Results From Singapore

Mervin Han Hui Nathan Lim, MD<sup>1</sup>; Tze Tec Chong, MD<sup>2</sup>; Sze Ling Chan, PhD<sup>3</sup>; Shereen Xue Yun Soon, BSc<sup>2</sup>; Charyl Jia Qi Yap, BSc<sup>2</sup>; Ankur Patel, FRCR<sup>4</sup>; Kiang Hong Tay, FRCS<sup>2</sup>; Sivanathan Chandramohan, FRCR<sup>4</sup>; Hsien Ts'ung Luke Tay, FRCS<sup>2,5</sup>; Tjun Yip Tang, FRCS<sup>2,5</sup>

## Abstract

**Introduction.** Chronic limb-threatening ischemia, also known as critical limb ischemia (CLI), is the most advanced stage of peripheral arterial disease (PAD), and patients have high risk of major lower-limb amputation and mortality. An endovascular-first approach has become the preferred revascularization strategy for these patients. The aim of the study was to evaluate the safety and short-term efficacy of the Ranger paclitaxel-coated balloon (PCB; Boston Scientific) in the setting of CLI. **Methods.** This was a single-center, single-arm, multi-investigator, prospective study of CLI patients who underwent endovascular revascularization using the Ranger PCB from July 2019 to November 2019 at Singapore General Hospital in Singapore. Data were retrieved from the Vascular Quality Initiative database recently set up at this institution. Primary lesion patency, amputation-free survival (AFS), freedom from target-lesion revascularization (TLR), and complete wound healing were the efficacy endpoints of interest at 6 months post intervention. **Results.** A total of 84 patients (87 limbs; 229 lesions) were enrolled. Fifty-one of the 84 patients (60.7%) were men. Baseline characteristics included diabetes mellitus in 76/84 patients (90.5%), chronic renal impairment in 25/84 patients (29.8%), and Rutherford category 6 foot wounds in 22/87 limbs (24.7%). TASC D lesions were present in 63/229 lesions (27.9%) and moderate/severe vessel wall calcification was present in 167/229 lesions (72.9%). Immediate technical success was achieved in 218/229 lesions (95.2%) with no device-related mortality at 30 days. Primary patency rates at 3 months and 6 months were 76/82 (92.7%) and 69/81 (85.2%), respectively. Six-month primary patency rates of below-the-knee (BTK) lesions treated with and without Ranger balloons were 89/94 (94.7%) and 34/41 (82.9%), respectively ( $P=.03$ ). Six-month AFS occurred in 68/78 (87.2%) and freedom from TLR occurred in 73/81 (90.1%). Six-month complete wound healing rate was respectable, at 28/50 (56.0%). **Conclusion.** Use of the Ranger PCB showed favorable outcomes and short-term patency rates, especially in the BTK region, in what is an otherwise challenging patient cohort. Extended follow-up is awaited to evaluate the long-term safety and efficacy of the balloon.

J CRIT LIMB ISCHEM 2021;1(1):E17-E26.

**Key words:** chronic limb threatening ischemia, drug-coated balloon, limb salvage, percutaneous angioplasty, Ranger DCB

The prevalence of peripheral artery disease (PAD) increased by a quarter between 2000 and 2010, with 200 million estimated to have PAD globally.<sup>1</sup> Primary drivers of this increase have been longer life expectancy<sup>1</sup> and a diabetic epidemic.<sup>2</sup> Chronic limb-threatening ischemia, also known as critical limb ischemia (CLI), is the most advanced stage of PAD, defined by the

presence of PAD in combination with rest pain, gangrene, or lower-limb ulceration of more than 2-week duration.<sup>3</sup> Despite no proven superiority over open surgical revascularization in terms of amputation-free survival (AFS) and overall mortality,<sup>4</sup> an endovascular-first revascularization strategy is recommended for lower-limb arterial short occlusions or stenotic lesions

for CLI.<sup>5</sup> However, its role in longer, more complex occlusions remains debatable. Plain old balloon angioplasty (POBA) was initially used to increase lumen diameter, but had high rates of restenosis.<sup>6-8</sup> Shear stress during balloon angioplasty triggers vessel-wall inflammation, initiating hypertrophic neointimal hyperplasia (NIH).<sup>9</sup> Provisional bare-metal stenting with POBA was introduced to reduce restenosis rates by providing mechanical scaffolding,<sup>10</sup> but a permanently implanted stent has potential complications, eg, in-stent restenosis, thrombosis, and stent fracture. Stent implantation also causes vascular inflammation because of vessel-wall irritation, causing NIH.<sup>9</sup>

Drug-coated balloons (DCBs) have gained popularity over the past 5 years because of the “leave nothing behind” concept. They have been shown to reduce late lumen loss, binary restenosis, and target-lesion revascularization (TLR) in the treatment of femoropopliteal disease, compared with POBA.<sup>11</sup> DCBs overcome the limitations of drug-eluting stent (DES) options, such as stent-related complications. The majority of DCBs use a paclitaxel-based platform. Paclitaxel reduces late restenosis by exerting antiproliferative effects to inhibit NIH.<sup>12</sup>

Existing studies evaluating the efficacy of the Ranger DCB (Boston Scientific) in the treatment of PAD have reported satisfactory results. The prospective, randomized RANGER SFA study reported higher rates of 12-month primary patency (86.4% vs 56.5%) and freedom from TLR (91.2% vs 69.9%) in the DCB arm compared with POBA.<sup>13</sup> Lichtenberg et al also reported excellent primary patency rates (91.0%), freedom from TLR (92.4%), and significant improvement in clinical outcomes at 6 months.<sup>14</sup> However, the majority of patients in both studies presented with intermittent claudication. To our knowledge, there have been no studies evaluating the efficacy of the Ranger DCB in the setting of CLI.

The aim of this study was to evaluate the safety and short-term (6-month) efficacy of the Ranger balloon in the treatment of infrainguinal arterial occlusive disease in Asian patients with CLI from Singapore. Technical success, target-lesion patency, and clinical outcomes are presented.

## Methods

**Patients and study design.** This was a single-center, single-arm, prospective study of 84 patients (87 limbs) with CLI, who underwent endovascular revascularization using Ranger DCBs from July 2019 to November 2019 at Singapore General Hospital (SGH). This allowed for at least a 6-month follow-up period. Symptomatic patients with Rutherford classification<sup>15</sup> 4-6 were included. Data were retrieved from the Vascular Quality Initiative (VQI) database and hospital electronic records. The VQI<sup>16</sup> is a collaborative network of vascular specialists in the United States seeking to improve the quality and safety of vascular care by sharing data among physicians, medical centers, and regions. SGH, a tertiary vascular center in central Singapore,

performs over 900 lower-limb endovascular revascularization procedures annually,<sup>17</sup> and is the only participating center from the Asia-Pacific region. Consent to collect, analyze, and publish anonymized patient data was waived. The local institutional review board approved this study (ref number: 2018/2995).

Premorbid variables collected included patient demographics, comorbidities, prior vascular interventions, and baseline medication history. Preoperative toe pressure, wound severity, and infection severity were assessed to calculate the baseline wound, ischemia, and foot infection (WIFI) scores.<sup>18</sup> Procedural data included location, degree of calcification, TransAtlantic InterSociety Consensus (TASC) severity<sup>19</sup> of the atherosclerotic lesions, and degree of vessel recoil after angioplasty. Outcomes measured included bailout stenting rate, major adverse cardiac event (MACE) rate, clinically driven TLR rate, complete wound healing rate, amputation free survival (AFS) rate, Rutherford scores, and functional status at 3 and 6 months post intervention.

**Procedure.** All patients underwent preoperative arterial Duplex ultrasonography (DUS) and toe-pressure measurements. Medications and comorbidities were optimized by attending cardiologists and nephrologists. Our center has adopted a predominantly endovascular-first approach for the past 10 years. Percutaneous transluminal angioplasty (PTA) was performed in a fixed imaging hybrid operating room by an attending vascular surgeon. Depending on the complexity of the procedure and whether concomitant amputation(s) or wound debridement were required, PTA was performed under local, regional, or general anesthesia. Carbon dioxide angiography was used in patients with contrast allergy or poor renal function. Standard digital subtraction techniques were employed otherwise. An ipsilateral antegrade common femoral access was preferred for infrainguinal and infrapopliteal lesions. Contralateral up-and-over approach was performed only when there was severe disease of the ipsilateral common femoral artery precluding ipsilateral antegrade puncture, or when there were concomitant iliac lesions to be treated. After a diagnostic angiogram had been performed and when angioplasty was intended, intra-arterial heparin (3000-5000 IU) was routinely administered via the intra-arterial sheath. Transluminal crossing of the stenosis or occlusion was preferred.

Predilation with a conventional non-DCB balloon catheter for at least 2 minutes was mandatory for all target lesions (diameter 1:1 sizing to the reference vessel using digital subtraction angiography). DCB was only implanted if there was <30% recoil. For DCB sizing, the nominal balloon diameter had to match the reference vessel diameter distal to the target lesion. In order to secure full lesion coverage, DCB length was required to be >1 cm longer at each end than the predilation balloon to avoid geographical miss, with a DCB inflation time >90 seconds for the first dilation. In balloons that were >150 mm in length, a

3-minute inflation was employed to maximize drug transfer to the arterial wall. In cases when  $\geq 2$  DCBs were required, overlapping of DCBs by at least 1 cm was accomplished. Patients with residual stenosis of  $>30\%$  or major flow-limiting dissection underwent prolonged postdilation for at least 180 seconds. If postdilation was unsuccessful, bailout stenting with a bare-metal or DES was performed at the operator's discretion. Full-length coverage of all atherosclerotic lesions was not routinely performed, and which stenoses or occlusions required treatment was left to the discretion of the operating surgeon. Hybrid procedures were performed in some patients with complex, multilevel disease involving the common femoral artery.

**Postoperative care and follow-up.** All patients were given 3 months of dual-antiplatelet agents unless there were medical contraindications. Clinical assessments were performed at 3 months and 6 months post procedure to assess wound healing. DUS was performed at 6 months to check vessel patency.

**Ranger paclitaxel-coated balloon.** The Ranger balloon is a low-dose paclitaxel-coated PTA balloon catheter that is deployed over a 0.018" Sterling platform (Boston Scientific), designed for treating peripheral vascular atherosclerotic lesions. The Sterling balloon platform has excellent pushability and trackability to enable navigation through challenging anatomies. Ranger has a proprietary loading tool that minimizes drug loss during handling. The TransPax coating (Boston Scientific) utilizes citrate ester as the excipient formulation to optimize the drug coating integrity. This ensures efficient and homogenous delivery of paclitaxel to the target lesions. The Ranger catheter is available in balloon diameter sizes of 2.0, 2.5, 3.0, 4.0, 5.0, 6.0, 7.0, and 8.0 mm and lengths of 40, 60, 80, 100, 120, 150, and 200 mm, with a working shaft length of 90 cm and 135 cm.

**Outcome definitions.** *Acute technical success* was defined as the ability to deliver and inflate the balloon to the intended target lesion and achieve final residual stenosis  $\leq 30\%$  without flow-limiting dissection and without requiring bailout stenting. *AFS* was defined as survival without any amputation above the ankle. *Patent vessels* were those in which DUS did not show a significant restenosis (peak velocity ratio  $\geq 2.5$ , which is indicative of  $>50\%$  diameter stenosis). *Primary patency rate* was defined as the percentage of patients with uninterrupted vessel patency until reintervention was required. *Clinically driven TLR* was defined as either repeat percutaneous or surgical revascularization performed on a patient who returned with clinical symptoms such as rest pain or non-healing wounds.

**Statistical analysis.** Baseline demographics were summarized with the use of descriptive statistics. Continuous numeric variables were reported as mean  $\pm$  standard deviation or median (interquartile range [IQR]), as appropriate. Categorical

variables were reported as absolute number and percentage. Associations between baseline and operative characteristics and outcomes were tested for using univariate logistic regression. Variables with  $P < .05$  were then combined into a multivariate logistic regression model. Kaplan-Meier survival estimation was used to calculate vessel patency rates. The statistical analyses were performed using SPSS statistical software, version 25.0 (IBM).

## Results

**Patient and clinical characteristics.** Over a 6-month period, a total of 84 patients (87 limbs; 229 lesions) were enrolled. Men comprised 51 of the 84 patients (60.7%) and mean age was  $68.8 \pm 9.63$  years. Seventy-six of the 84 patients (90.5%) had diabetes mellitus, 55/84 (65.5%) had chronic renal impairment, and 25/84 (29.8%) had end-stage renal failure requiring hemodialysis. Only 58/84 patients (69.0%) were on aspirin at presentation. Eleven of 87 limbs (12.4%) were Rutherford category 4, 56/87 (62.9%) were Rutherford category 5, and 22/87 (24.7%) were Rutherford category 6. Mean baseline toe pressure of the affected foot was  $39.9 \pm 20.9$  mm Hg. Mean Wifi score was  $4.26 \pm 1.88$ . Using the Society for Vascular Surgery clinical stages by expert consensus,<sup>18</sup> a total of 33/87 limbs (37.9%) were deemed at high risk of amputation at 1 year, while 12/87 (13.8%) were at very low risk, 11/87 (12.6%) were at low risk, and 31/87 (35.6%) were at moderate risk. Table 1 summarizes baseline demographics and clinical characteristics.

**Lesion characteristics.** Seventy of the 84 patients (83.3%) required multilevel treatment. A total of 229 lesions were treated, comprising 138/229 (60.3%) left lesions and 135/229 (59.0%) infrapopliteal lesions. Mean lesion length was  $18.4 \pm 16.7$  cm. Sixty-four of 229 lesions (27.9%) were TASC D lesions. The anterior tibial artery (ATA) was the most treated crural vessel, in 47/229 lesions (20.5%). There was a high incidence of moderate-to-severe vessel-wall calcification (167/229 lesions; 72.9%). Nine of 87 limbs (10.3%) had inframalleolar treated lesions. Table 2 shows lesion characteristics and procedural data.

**Procedural data.** Technical success was achieved in 218/229 lesions (95.2%). Of the 11 technical failures, 2 (18.2%) had final vessel stenosis  $>30\%$  and 9 (81.8%) were unable to be crossed due to severe calcification. The subintimal arterial flossing with antegrade-retrograde intervention (SAFARI) technique<sup>20</sup> and combined open hybrid procedures were performed in 11/87 limbs (12.6%) and 8/87 limbs (9.2%), respectively. A total of 170 Ranger balloons (mean number of Ranger balloons/limb,  $1.95 \pm 0.963$ ) of mean diameter  $4.25 \pm 1.26$  mm and mean length of  $156 \pm 52.4$  mm were deployed to treat 170/229 lesions (74.2%). Recoil was noted in 2/87 limbs (2.3%). Four of 229 lesions (1.7%) were spot stented with a bare-metal stent. Overall bailout stenting

TABLE 1. Baseline demographics and clinical characteristics.	
Baseline Demographics	Patients (n = 84)
Mean age (years)	68.8 ± 9.63
Mean body mass index (kg/m <sup>2</sup> )	24.3 ± 4.55
Gender	
Male	51 (60.7%)
Female	33 (39.3%)
Ethnic group	
Chinese	50 (59.5%)
Malay	12 (14.3%)
Indian	18 (21.4%)
Others	4 (4.8%)
Smoking status	
Smoker	22 (26.2%)
Non-smoker	46 (54.8%)
Ex-smoker	16 (19.0%)
Comorbidities	
Diabetes	76 (90.5%)
Diabetic retinopathy	28 (33.3%)
Diabetic nephropathy	54 (64.3%)
Diabetic neuropathy	7 (8.3%)
Hypertension	77 (91.7%)
Coronary artery disease	44 (52.4%)
Cerebrovascular disease	22 (26.2%)
Dysrhythmia	11 (13.1%)
Atrial fibrillation	9 (10.7%)
Chronic obstructive pulmonary disease	2 (2.4%)
Congestive heart failure	14 (16.7%)
Chronic renal impairment	55 (65.5%)
End-stage renal function (on dialysis)	25 (29.8%)
Hemoglobin levels	
<10 g/dL	29 (34.5%)
≥10 g/dL	55 (65.5%)
Baseline Medication History	Patients (n = 84)
Antiplatelets	
Aspirin	58 (69.0%)
Clopidogrel	22 (26.2%)
Ticagrelor	3 (3.6%)

TABLE 1. Baseline demographics and clinical characteristics.	
Baseline Medication History (continued)	Patients (n = 84)
Statin	73 (86.9%)
Anticoagulants	15 (17.9%)
Angiotensin-converting enzyme inhibitor/ angiotensin II receptor blocker	49 (58.3%)
Prior Coronary and Peripheral Arterial Interventions	Patients (n = 84)
Coronary artery bypass graft	22 (26.2%)
<5 years	12 (14.3%)
≥5 years	10 (11.9%)
Percutaneous coronary intervention	19 (22.6%)
<5 years	8 (9.5%)
≥5 years	11 (13.1%)
Leg arterial bypass/endarterectomy/ percutaneous vascular interventions	45 (53.6%)
Prior Interventions/Limb	Limbs (n = 87)
Femoral endarterectomy	6 (6.9%)
Contralateral amputations	25 (28.7%)
Minor (forefoot, single/multiple toes)	18 (20.7%)
Major lower-extremity amputation	7 (8.0%)
Angioplasty (ipsilateral)	38 (43.7%)
Ischemia/Tissue Loss Severity	Limbs (n = 87)
Rutherford classification	
4	11 (12.4%)
5	56 (62.9%)
6	22 (24.7%)
SVS Wifl Wound Score	
0	11 (12.6%)
1	35 (40.2%)
2	31 (35.6%)
3	10 (11.5%)
Mean SVS Wifl score	4.26 ± 1.88
Baseline toe pressure (mm Hg)	39.9 ± 20.9

Data presented as mean ± standard deviation or number (%).  
SVS = Society of Vascular Surgery; Wifl = wound extent, degree of ischemia, and extent of foot infection.

**TABLE 2. Lesion characteristics and procedural data.**

Lesion Details	Lesions (n = 229)
<b>Technical success</b>	
Final vessel stenosis ≤30%	218 (95.2%)
Final vessel stenosis >30%	2 (0.9%)
Technical failure	9 (3.9%)
<b>Right</b>	91 (39.7%)
<b>Left</b>	138 (60.3%)
<b>Lesion length (cm)</b>	18.4 ± 16.7
<b>Location of treated vessel</b>	
Common iliac	1 (0.4%)
Common femoral + external iliac arteries	14 (6.1%)
Profunda	1 (0.4%)
Superior femoral artery	24 (10.5%)
Popliteal	12 (5.2%)
Superficial femoral + popliteal arteries	42 (18.3%)
Anterior tibial artery	47 (20.5%)
Posterior tibial artery	29 (12.7%)
Dorsalis pedis artery	7 (3.1%)
Tibioperoneal trunk	25 (10.9%)
Peroneal	25 (10.9%)
Plantar	2 (0.9%)
<b>TASC classification</b>	
A	17 (7.4%)
B	57 (24.9%)
C	82 (35.8%)
D	64 (27.9%)
<b>Inframalleolar lesions</b>	9 (3.9%)
<b>Calcification classification</b>	
None	1 (0.4%)
Focal	18 (7.9%)
Mild	43 (18.8%)
Moderate	83 (36.2%)

**TABLE 2. Lesion characteristics and procedural data.**

Lesion Details	Lesions (n = 229)
<b>Severe</b>	84 (36.7%)
<b>Lesions treated with Ranger balloon</b>	170 (74.2%)
<b>Location of lesion treated with Ranger balloon</b>	<b>Ranger Lesions (n = 170)</b>
Common femoral + external iliac arteries	6 (3.5%)
Superior femoral artery	23 (13.5%)
Popliteal	8 (4.7%)
Superior femoral + popliteal arteries	39 (22.9%)
Anterior tibial artery	43 (25.3%)
Posterior tibial artery	24 (14.1%)
Tibioperoneal trunk	18 (10.6%)
Peroneal	9 (5.3%)
<b>Operation Details</b>	<b>Limbs (n = 87)</b>
Below-ankle treatment	9 (10.3%)
Recoil	2 (2.3%)
SAFARI technique	11 (12.6%)
Hybrid procedure	8 (9.2%)
<b>Devices/limb</b>	5.22 ± 1.95
<b>Stent Details</b>	<b>Stents (n = 4)</b>
Bare-metal stent	4 (100%)
<b>Stent diameter (mm)</b>	5.75 ± 0.96
<b>Stent length (mm)</b>	90.0 ± 11.6
<b>Ranger Balloon Details</b>	<b>Balloons (n = 170)</b>
<b>Balloon diameter (mm)</b>	4.25 ± 1.26
<b>Balloon length (mm)</b>	156 ± 52.4
<b>Surface area (mm<sup>2</sup>)</b>	2120 ± 140
<b>Ranger balloons/limb</b>	1.95 ± 0.963

Data presented as mean ± standard deviation or number (%).  
SAFARI = subintimal arterial flossing with antegrade-retrograde intervention;  
TASC = Trans-Atlantic Inter-Society Consensus.

rate was 2/87 limbs (2.3%). Access-site complications include hematoma in 4/87 limbs (4.6%) and arteriovenous fistula formation in 1/87 limbs (1.1%). Four of 87 limbs (4.6%), 6/87 limbs (6.9%), and 1/87 limbs (1.1%) had arterial perforations, target-lesion dissection, and embolization, respectively. One of the 4 perforations (25.0%) resolved with compression using

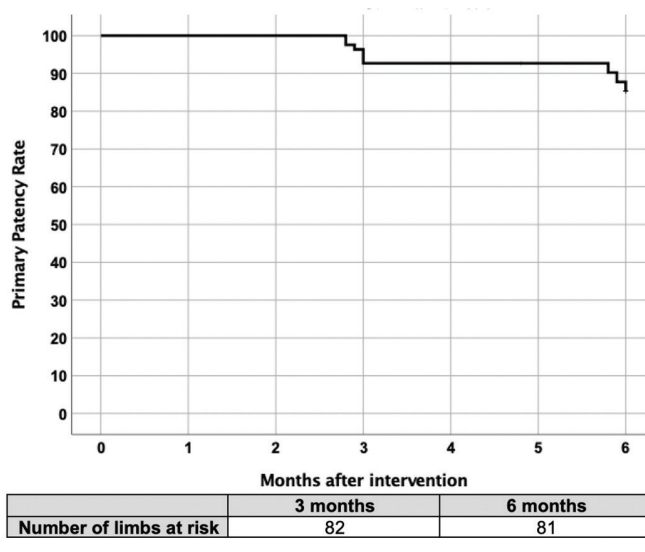
balloon angioplasty and the other 3 perforations (75.0%) were self-contained. Four of the 6 target-lesion dissections (66.7%) were managed with balloon angioplasty alone. Hematomas and arteriovenous fistulas resolved with manual compression. There were no instances of retained device components or device-related deaths.

TABLE 3. Postprocedural data and follow-up data.	
<b>Perioperative Complications</b>	<b>Patients (n = 84) or Limbs (n = 87)</b>
<b>Perioperative complications</b>	
Myocardial infarction	1/84 (1.2%)
Renal injury	1/84 (1.2%)
Embolization	1/87 (1.1%)
Target-lesion dissection	6/87 (6.9%)
Perforation	4/87 (4.6%)
<b>Access-site complications</b>	
Hematoma	4/87 (4.5%)
Arteriovenous fistula	1/87 (1.1%)
<b>Amputation during admission</b>	
None	46/87 (52.9%)
Toe(s)	27/87 (31.0%)
Transmetatarsal/midfoot	9/87 (10.3%)
Below knee/through knee	2/87 (2.3%)
Above knee or higher	3/87 (3.4%)
<b>Postprocedure Medications</b>	<b>Patients</b>
<b>Antiplatelets</b>	
Aspirin	79/84 (94.0%)
Clopidogrel	67/84 (79.8%)
Ticagrelor	2/84 (2.4%)
Statin	72/84 (85.7%)
<b>Anticoagulants</b>	
Angiotensin-converting enzyme inhibitor/ angiotensin II receptor blocker	47/84 (56.0%)
Cilostazol	1/84 (1.2%)
<b>Follow-Up Data</b>	<b>Patients</b>
Mean follow-up time (days)	168 ± 89.3
<b>Functional status</b>	
<b>Baseline</b>	
Independent	21/84 (25.0%)
Assisted	46/84 (54.8%)
Wheelchair/bed bound	17/84 (20.2%)

**Outcome.** Patients were followed up for a mean duration of 168 ± 89.3 days. On a patient-level analysis, 1/84 (1.2%) had contrast-induced renal injury post operation. All-cause mortality rate was 7/84 patients (8.3%) at 6 months and consisted of hospital-acquired pneumonia in 1/7 (14.3%), osteomyelitis in 1/7 (14.3%), ischemic bowel in 1/7 (14.3%), sepsis in 1/7 (14.3%), and cardiovascular related in 3/7 (42.9%). Twenty-one of the 84

TABLE 3. Postprocedural data and follow-up data.	
<b>Functional status (continued)</b>	
<b>3 months</b>	
Independent	35/79 (44.3%)
Assisted	31/79 (39.2%)
Wheelchair/bed bound	13/79 (16.5%)
<b>6 months</b>	
Independent	29/67 (43.3%)
Assisted	25/67 (37.3%)
Wheelchair/bed bound	13/67 (19.4%)
<b>Change in Rutherford score</b>	
Baseline to 3 months	1.43 ± 1.92 ( <i>P</i> < .001)
Baseline to 6 months	2.73 ± 2.41 ( <i>P</i> < .001)
<b>Complete wound healing</b>	
3 months	19/74 (25.7%)
6 months	28/50 (56.0%)
<b>Primary patency rates (overall)</b>	
3 months	76/82 (92.7%)
6 months	69/81 (85.2%)
<b>6-month primary patency rates</b>	
ATK lesions treated with Ranger DCB	64/76 (84.2%)
ATK lesions not treated with Ranger DCB	3/8 (37.5%)
BTK lesions treated with Ranger DCB	89/94 (94.7%)
BTK lesions not treated with Ranger DCB	34/41 (82.9%)
<b>Amputation-free survival rate</b>	
3 months	78/84 (92.9%)
6 months	68/78 (87.2%)
<b>Freedom from target-lesion revascularization</b>	
3 months	78/82 (95.1%)
6 months	73/81 (90.1%)
Data presented as mean ± standard deviation, number/total limbs (%), or number/total patients (%). ATK = above the knee; BTK = below the knee; DCB = drug-coated balloon.	

patients (25.0%) had independent ambulatory status at baseline. At 3 months and 6 months, 35/79 patients (44.3%) and 29/67 patients (43.3%) had independent ambulatory status, respectively. On a limb-based analysis, freedom from TLR occurred in 78/82 (95.1%) and 73/81 (90.1%) at 3 months and 6 months, respectively. Three-month and 6-month primary patency rates were 76/82 (92.7%) and 69/81 (85.2%), respectively. Figure



**FIGURE 1.** Kaplan-Meier curve for 3-month and 6-month primary patency rates.

1 shows the Kaplan-Meier survival curve. Complete wound healing rates at 3 months and 6 months were 19/74 (25.7%) and 28/50 (56.0%), respectively. Six-month AFS rate was 68/78 (87.2%). Mean Rutherford scores decreased by a mean of  $1.43 \pm 1.92$  ( $P < .001$ ) and  $2.73 \pm 2.41$  ( $P < .001$ ) at 3 months and 6 months post procedure, respectively. Fifty-three of 84 patients (63.1%) had at least 1 Rutherford class improvement at 6 months. On a lesion-level analysis, 6-month primary patency rates of above-the-knee (ATK) lesions treated with and without Ranger balloons were 64/76 (84.2%) and 3/8 (37.5%), respectively ( $P < .01$ ). Six-month primary patency rates of below-the-knee (BTK) lesions treated with and without Ranger balloons were 89/94 (94.7%) and 34/41 (82.9%), respectively ( $P = .03$ ). Table 3 summarizes the postprocedural and follow-up data.

Multivariate analysis showed that patients with end-stage renal function undergoing any form of renal dialysis (odds ratio [OR], 0.22; 95% confidence interval [CI], 0.07-20.91) and the SAFARI procedure (OR, 0.23; 95% CI, 0.06-0.92) were associated with higher loss of 6-month primary patency. The SAFARI procedure was an independent predictor of higher TLR at 6 months (OR, 0.20; 95% CI, 0.05-0.78).

## Discussion

In a challenging cohort of CLI patients with high atherosclerotic disease burden and multiple comorbidities, such as diabetes and renal failure, our 6-month outcomes are highly satisfactory using the Ranger DCB. Despite only including CLI patients, our 6-month primary patency and freedom from TLR rates were comparable with those reported in the RANGER SFA and Lichtenberg studies (6-month primary patency rate,

85.2% vs 87.0% vs 91.0%, respectively; freedom from TLR, 90.1% vs 94.4% vs 92.4%, respectively). All patients in the DCB arm of the RANGER SFA study had only Rutherford category 2-3 disease,<sup>21</sup> while 84% of patients included by Lichtenberg had Rutherford 1-3 disease.<sup>14</sup> This makes our results all the more compelling in the setting of severe PAD. CLI is characterized by extensive multilevel arterial occlusive disease with diffuse calcific involvement, associated with poorer outcomes despite successful revascularization.<sup>3</sup> Lesions treated in our cohort had higher rates of moderate-to-severe calcification (167/229; 72.9%) vs the Ranger SFA study (42/70; 60.0%). Higher calcium burden in CLI was reported to have a proportional impact on restenosis formation, as calcium potentially represents a barrier to optimal drug absorption,<sup>22</sup> but the data we have presented do not seem to support this notion, as freedom from TLR was high. Patients included in our study had higher rates of renal impairment compared with the Ranger SFA and Lichtenberg studies (66% vs 11% vs 19%, respectively), with 29.8% being dialysis dependent. End-stage renal function is associated with high incidence of cardiovascular morbidity and mortality in PAD patients.<sup>23</sup>

To our knowledge, there is no study evaluating the Ranger DCB in treating BTK lesions for CLI patients. A meta-analysis on infrapopliteal angioplasty for CLI conducted by Marcello et al<sup>24</sup> reported 6-month primary patency rates of 65% vs 89/94 (94.7%) in our study. BTK lesions are challenging to treat due to their long length, small vessel diameter (especially pertinent in an Asian population), multiple treatment paths, poor outflow, and severe calcification. Endovascular management of these lesions is associated with higher rates of recoil, dissections, and restenosis.<sup>25</sup> Isolated BTK arterial disease is more commonly seen in diabetics with end-stage renal function and in the elderly, and is associated with higher rates of limb loss at 1 year.<sup>26</sup> Treatment of infrapopliteal lesions is vital to relieve ischemic pain, heal ulcers, and prevent amputation and gangrene.<sup>27</sup>

In our study, 6-month primary patency rates of BTK lesions treated with Ranger DCB were significantly better than those without Ranger DCB (89/94 [94.7%] vs 34/31 [82.9%];  $P = .03$ ). The DEBATE-BTK randomized controlled trial also showed that DCBs were associated with lower restenosis (27% vs 74%;  $P < .001$ ) and TLR rates (18% vs 43%;  $P < .01$ ) compared with POBA for infrapopliteal lesions in diabetic patients with CLI.<sup>28</sup> Even in the face of long and severely calcified lesions, DCBs allow longer patency rates to aid wound healing. However, PTA with DCBs for BTK-PAD has produced heterogeneous results and remains controversial.<sup>29</sup> A recent meta-analysis conducted by Zhang et al<sup>30</sup> revealed that DCBs have no obvious advantage in the treatment of infrapopliteal disease. Furthermore, the use of paclitaxel DCBs in BTK lesions has recently been suggested to lower AFS rates.<sup>29,31</sup> Multivariate analysis showed that the SAFARI procedure was an independent

predictor for lower freedom from TLR and primary patency rates at 6 months. The current study authors believe that lesions requiring the SAFARI procedure are more complex, demonstrated by the inability to cross from an antegrade position. The guidewire is more likely to be in a subintimal plane, which may predispose to less-efficient drug transfer to the adventitial plane. The SAFARI procedure has been reported to lead to flow-limiting dissection and thrombosis of the accessed artery.<sup>32</sup>

Adequacy of vessel preparation can affect the efficacy of DCBs in treating infrapopliteal disease in CLI, especially in heavily calcified lesions.<sup>33</sup> Giannopoulos et al<sup>25</sup> recommend assessment of lesion calcification and adequate vessel preparation as the first step for optimal balloon angioplasty of infrapopliteal lesions. Vessel preparation minimizes risk of dissections, maximizes luminal gain, and prepares the vessel bed for local drug delivery via DCBs. We have recently shown that the use of prolonged dilation with a non-compliant, high-pressure balloon is safe and efficacious in treating highly complex infrapopliteal lesions in CLI patients.<sup>34</sup>

Drug doses differ between DCBs. The COMPARE study was the first prospective, randomized, non-inferiority clinical trial of high-dose (In.Pact; Medtronic) vs low-dose (Ranger) paclitaxel DCBs for femoropopliteal lesions. Ranger DCB was shown to be non-inferior to In.Pact DCB with respect to both primary patency and safety at 1 year, despite double exposure to paclitaxel in the In.Pact group.<sup>35</sup> In a rabbit model, Ranger DCB was associated with significantly lower non-target paclitaxel embolization rates compared with 4 other DCBs.<sup>36</sup> In a healthy swine model, particulate embolization was extremely infrequent in the Ranger DCB group and more common in the In.Pact DCB group.<sup>37</sup> In the current study, 1/87 (1.1%) had clinically significant embolization, which resolved with angioplasty. The hydrophobic coating and low macrocrystalline paclitaxel concentration of Ranger DCBs could be responsible for lower embolization rates. Non-target paclitaxel embolism in distal arteries can lead to arterial occlusion, non-healing wounds, and acute hypersensitivity reactions,<sup>38</sup> more so in CLI patients due to limited blood flow reserve.<sup>37</sup> A meta-analysis of randomized controlled trials comparing paclitaxel DCBs with POBA for infrapopliteal disease in CLI reported significantly worse AFS in the DCB group, which was more evident in high-dose ( $3.0\text{--}3.5\ \mu\text{g}/\text{mm}^2$ ) than low-dose devices ( $2.0\ \mu\text{g}/\text{mm}^2$ ).<sup>31</sup> Paclitaxel embolism was postulated to be the underlying mechanism for worse AFS rate.

Lutonix (Bard) and Ranger balloons are low-dose paclitaxel DCBs. They differ in paclitaxel formulation (Lutonix = hybrid; Ranger = microcrystalline) and excipient formulation (Lutonix = polysorbate sorbitol; Ranger = citrate ester). The highly water-soluble sorbitol excipient of Lutonix may facilitate paclitaxel downstream washing during navigation of the DCB to its intended position. In a rabbit model, the Lutonix

DCB was associated with significantly higher embolization rates as compared with the Ranger DCB.<sup>36</sup>

Katsanos et al reported an increased risk of all-cause mortality at 2 years and 5 years following application of paclitaxel devices in femoropopliteal arteries.<sup>39</sup> However, there is no biological mechanism linking paclitaxel devices with delayed mortality. Numerous arguments have been raised to counter these findings, mostly concerning the lack of patient-level data, insufficient stratification of non-homogenous subgroups, and lack of long-term follow-up data for most included trials.<sup>40</sup> More recent meta-analyses showed that mortality was not correlated with paclitaxel exposure.<sup>11,41</sup> In our experience, the use of Ranger DCBs in PAD is safe and effective, with low morbidity and mortality. All-cause mortality at 6 months was 7/84 (8.3%), with no device-related deaths. The mean number of Ranger balloons used in these patients was  $1.83 \pm 0.753$ , compared with the overall mean of  $1.95 \pm 0.963$ . Limb-salvage rates were favorable, with low incidence of major lower-extremity amputations (AFS at 6 months in 68/78 [87.2%]).

CLI is an end-stage manifestation of systemic atherosclerosis. Management of risk factors and comorbid conditions is necessary to prevent high mortality. In our study, only 58/84 patients (69.0%) were on aspirin at presentation, despite 79/84 patients (94.0%) having known PAD, and 31.0% of patients received suboptimal preoperative medical therapy. Twenty-two of 84 patients (26.2%) were on clopidogrel. The global vascular guidelines on the management of CLI strongly recommend antiplatelet agents for all patients with symptomatic PAD.<sup>3</sup> The CLIPS (Critical Leg Ischemia Prevention Study) group performed a randomized placebo-controlled double-blind clinical trial and reported a 26.0% reduction in incidence of vascular events with prophylactic low-dose aspirin in patients with PAD.<sup>42</sup>

**Study limitations.** This study was limited by its single-arm, non-randomized nature, with no comparator arm and relatively small sample size. The duration of follow-up was short and lacking long-term outcomes, which are awaited from the Ranger DCB worldwide. However, this study is more relevant to everyday clinical practice in Asian CLI patients, who have longer and more complex lesions with high calcium burden and chronic complete total occlusions.

## Conclusion

The Ranger paclitaxel DCB is a safe and efficacious modality for treating extensive multilevel arterial occlusive disease with diffuse calcific involvement in a challenging population of CLI patients with multiple comorbidities. It is associated with favorable acute technical success, as well as 6-month primary patency, freedom from TLR, and AFS. Bailout stenting rates were low, with no device-related complications.



## References

- Fowkes FGR, Rudan D, Rudan I, et al. Comparison of global estimates of prevalence and risk factors for peripheral artery disease in 2000 and 2010: a systematic review and analysis. *Lancet*. 2013;382:1329-1340.
- Huang ES, Laiteerapong N, Liu JY, John PM, Moffet HH, Karter AJ. Rates of complications and mortality in older patients with diabetes mellitus: the diabetes and aging study. *JAMA Intern Med*. 2014;174:251-258.
- Conte MS, Bradbury AW, Kolh P, et al. Global vascular guidelines on the management of chronic limb-threatening ischemia. *J Vasc Surg*. 2019;69:3S-125S e40.
- Popplewell MA, Davies HOB, Narayanswami J, et al. A comparison of outcomes in patients with infrapopliteal disease randomised to vein bypass or plain balloon angioplasty in the bypass vs angioplasty in severe ischaemia of the leg (BASIL) trial. *Eur J Vasc Endovasc Surg*. 2017;54:195-201.
- Aboyans V, Ricco JB, Bartelink MEL, et al. 2017 ESC guidelines on the diagnosis and treatment of peripheral arterial diseases, in collaboration with the European Society for Vascular Surgery (ESVS): document covering atherosclerotic disease of extracranial carotid and vertebral, mesenteric, renal, upper and lower extremity arteries. Endorsed by: the European Stroke Organization (ESO), the Task Force for the Diagnosis and Treatment of Peripheral Arterial Diseases of the European Society of Cardiology (ESC), and the European Society for Vascular Surgery (ESVS). *Eur Heart J*. 2018;39:763-816.
- Rosenfield K, Jaff MR, White CJ, et al. Trial of a paclitaxel-coated balloon for femoropopliteal artery disease. *N Engl J Med*. 2015;373:145-153.
- Tepe G, Schnorr B, Albrecht T, et al. Angioplasty of femoral-popliteal arteries with drug-coated balloons: 5-year follow-up of the THUNDER trial. *JACC Cardiovasc Interv*. 2015;8:102-108.
- Schneider PA, Laird JR, Tepe G, et al. Treatment effect of drug-coated balloons is durable to 3 years in the femoropopliteal arteries: long-term results of the IN.PACT SFA randomized trial. *Circ Cardiovasc Interv*. 2018;11:e005891.
- Schillinger M, Minar E. Restenosis after percutaneous angioplasty: the role of vascular inflammation. *Vasc Health Risk Manag*. 2005;1:73-78.
- de Donato G, Bosiers M, Setacci F, et al. 24-month data from the BRAVISSIMO: a large-scale prospective registry on iliac stenting for TASC A & B and TASC C & D lesions. *Ann Vasc Surg*. 2015;29:738-750.
- Caradu C, Lakhlifi E, Colacchio EC, et al. Systematic review and updated meta-analysis of the use of drug-coated balloon angioplasty versus plain old balloon angioplasty for femoropopliteal arterial disease. *J Vasc Surg*. 2019;70:981-995. e10.
- Lindquist J, Schramm K. Drug-eluting balloons and drug-eluting stents in the treatment of peripheral vascular disease. *Semin Intervent Radiol*. 2018;35:443-452.
- Steiner S, Willfort-Ehringer A, Sievert H, et al. 12-month results from the first-in-human randomized study of the Ranger paclitaxel-coated balloon for femoropopliteal treatment. *JACC Cardiovasc Interv*. 2018;11:934-941.
- Lichtenberg M, von Bilderling P, Ranft J, et al. Treatment of femoropopliteal atherosclerotic lesions using the Ranger paclitaxel-coated balloon catheter: 12-month results from an all-comers registry. *J Cardiovasc Surg (Torino)*. 2018;59:45-50.
- Rutherford RB, Baker JD, Ernst C, et al. Recommended standards for reports dealing with lower extremity ischemia: revised version. *J Vasc Surg*. 1997;26:517-538.
- Society for Vascular Surgery Vascular Quality Initiative Patient Safety Organization. Available at <https://vascular.org/research-quality/vascular-quality-initiative/patient-safety-organization>. Accessed February 7, 2021.
- Tay WL, Chong TT, Chan SL, et al. Two-year clinical outcomes following lower limb endovascular revascularization for chronic limb threatening ischemia from an Asian vascular centre in Singapore. *Singapore Med J*. 2020 Jul 16. Epub ahead of print.
- Mills JL Sr, Conte MS, Armstrong DG, et al. The Society for Vascular Surgery Lower Extremity Threatened Limb Classification System: risk stratification based on wound, ischemia, and foot infection (WIFI). *J Vasc Surg*. 2014;59:220-234.e1-e2.
- Norgren L, Hiatt WR, Dormandy JA, et al. Inter-society consensus for the management of peripheral arterial disease (TASC II). *J Vasc Surg*. 2007;45:S5-S67.
- Spinosa DJ, Bissonette EA, Cage D, et al. Subintimal arterial flossing with antegrade-retrograde intervention (SAFARI) for subintimal recanalization to treat chronic critical limb ischemia. *J Vasc Interv Radiol*. 2005;16:37-44.
- Bausback Y, Sievert H, Geist V, et al. Six-month results from the initial randomized study of the Ranger paclitaxel-coated balloon in the femoropopliteal segment. *J Endovasc Ther*. 2017;24:459-467.
- Fanelli F, Cannavale A, Gazzetti M, et al. Calcium burden assessment and impact on drug-eluting balloons in peripheral arterial disease. *Cardiovasc Intervent Radiol*. 2014;37:898-907.
- Rajagopalan S, Dellegrottaglie S, Furniss AL, et al. Peripheral arterial disease in patients with end-stage renal disease observations from the dialysis outcomes and practice patterns study (DOPPS). *Circulation*. 2006;114:1914-1922.
- Romiti M, Albers M, Brochado-Neto FC, Durazzo AE, Pereira CA, De Luccia N. Meta-analysis of infrapopliteal angioplasty for chronic critical limb ischemia. *J Vasc Surg*. 2008;47:975-981.
- Giannopoulos S, Varcoe RL, Lichtenberg M, et al. Balloon angioplasty of infrapopliteal arteries: a systematic review and proposed algorithm for optimal endovascular therapy. *J Endovasc Ther*. 2020;27:547-564. Epub 2020 Jun 17.
- Fernandez N, McEnaney R, Marone LK, et al. Multilevel versus isolated endovascular tibial interventions for critical limb ischemia. *J Vasc Surg*. 2011;54:722-729.
- Rand T, Uberoi R. Current status of interventional radiology treatment of infrapopliteal arterial disease. *Cardiovasc Intervent Radiol*. 2013;36:588-598.
- Liisto F, Porto I, Angioli P, et al. Drug-eluting balloon in peripheral intervention for below the knee angioplasty evaluation (DEBATE-BTK): a randomized trial in diabetic patients with critical limb ischemia. *Circulation*. 2013;128:615-621.
- Zeller T, Baumgartner I, Scheinert D, et al. Drug-eluting balloon versus standard balloon angioplasty for infrapopliteal arterial revascularization in critical limb ischemia: 12-month results from the IN.PACT DEEP randomized trial. *J Am Coll Cardiol*. 2014;64:1568-1576.
- Zhang J, Xu X, Kong J, et al. Systematic review and meta-analysis of drug-eluting balloon and stent for infrapopliteal artery revascularization. *Vasc Endovasc Surg*. 2017;51:72-83.
- Katsanos K, Spiliopoulos S, Kitrou P, Krokidis M, Paraskevopoulos I, Karnabatidis D. Risk of death and amputation with use of paclitaxel-coated balloons in the infrapopliteal arteries for treatment of critical limb ischemia: a systematic review and meta-analysis of randomized controlled trials. *J Vasc Intervent Radiol*. 2020;31:202-212.
- Lupattelli T, Clerissi J, Losa S, Faglia E. Regarding the "SAFARI" technique: a word of caution. *Cardiovasc Intervent Radiol*. 2009;32:197-198.
- Tepe G, Ruether C, Fischer I, Pfaffinger P, Noory E, Zeller T. Drug-eluting balloon therapy for femoropopliteal occlusive disease: predictors of outcome with a special emphasis on calcium. *J Endovasc Ther*. 2015;22:727-733.
- Tang TY, Lee SQW, Chan SL, et al. Utility of a novel high pressure non-compliant balloon for tibial atherosclerotic lesions in Asian patients with chronic limb threatening ischaemia. *Vasa*. 2020;1-8.
- Steiner S, Schmidt A, Zeller T, et al. COMPARE: prospective, randomized, non-inferiority trial of high- vs. low-dose paclitaxel drug-coated balloons for femoropopliteal interventions. *Eur Heart J*. 2020;41:2541-2552.
- Boitet A, Grassin-Delyle S, Louedec L, et al. An experimental study of paclitaxel embolisation during drug coated balloon angioplasty. *Eur J Vasc Endovasc Surg*. 2019;57:578-586.

37. Torii S, Jinnouchi H, Sakamoto A, et al. Comparison of biologic effect and particulate embolization after femoral artery treatment with three drug-coated balloons in healthy swine model. *J Vasc Interv Radiol*. 2019;30:103-109.
38. Lake E, Twigg M, Farquharson F. Acute hypersensitivity reaction to femoral drug-coated balloons. *Vasa*. 2017;46:223-225.
39. Katsanos K, Spiliopoulos S, Kitrou P, Krokidis M, Karnabatidis D. Risk of death following application of paclitaxel-coated balloons and stents in the femoropopliteal artery of the leg: a systematic review and meta-analysis of randomized controlled trials. *J Am Heart Assoc*. 2018;7:e011245.
40. Bonassi S. Letter by Bonassi regarding article, "Risk of death following application of paclitaxel-coated balloons and stents in the femoropopliteal artery of the leg: a systematic review and meta-analysis of randomized controlled trials." *J Am Heart Assoc*. 2019;8:e012315.
41. Dinh K, Gomes ML, Thomas SD, et al. Mortality after paclitaxel-coated device use in patients with chronic limb-threatening ischemia: a systematic review and meta-analysis of randomized controlled trials. *J Endovasc Ther*. 2020;27:175-185.
42. Critical Leg Ischaemia Prevention Study (CLIPS) Group, Catalano M, Born G, Peto R. Prevention of serious vascular events by aspirin amongst patients with peripheral arterial disease: randomized, double-blind trial. *J Intern Med*. 2007;261:276-284.

From the <sup>1</sup>Yong Loo Lin School of Medicine, National University of Singapore, Singapore; <sup>2</sup>Department of Vascular Surgery, Singapore General Hospital, Singapore; <sup>3</sup>Health Services Research Centre, SingHealth, Singapore; <sup>4</sup>Department of Vascular Interventional Radiology, Singapore General Hospital, Singapore; and <sup>5</sup>Duke NUS Graduate Medical School, Singapore.

Disclosure: The authors have completed and returned the ICMJE Form for Disclosure of Potential Conflicts of Interest. Dr Tang and Dr Chong report an investigator-initiated grant from Boston Scientific Singapore for an unrelated research project. The remaining authors report no conflicts of interest regarding the content herein.

Manuscript accepted January 11, 2021.

Address for correspondence: T.Y. Tang, MD, FRCS, FAMS, Senior Consultant, Vascular & Endovascular Surgeon, Associate Professor Duke-NUS Medical School, Department of Vascular Surgery, Singapore General Hospital, Level 5, Academia, 20 College Road, Singapore 169856. Email: tang.tjun.yip@singhealth.com.sg