



Successful Treatment of Critical Hand Ischemia With Orbital Atherectomy and Balloon Angioplasty

Ismail Dogu Kilic, MD¹; Deniz Mutlu, MD²; Konstantinos Marmagkiolis, MD^{3,4}; Vasili Lendel, MD⁵; Cezar Iliescu, MD³; Mehmet Cilingiroglu, MD³

Abstract

Critical hand ischemia (CHI) is a relatively infrequent yet potentially devastating clinical entity. CHI is more frequent in patients with end-stage renal disease. Percutaneous treatment with balloon angioplasty can be performed successfully in the majority of patients. In our case, we present the successful treatment of CHI in a young patient with end-stage renal disease using orbital atherectomy and balloon angioplasty.

J CRIT LIMB ISCHEM 2022;2(2):E46-E48.

Key words: critical hand ischemia, end-stage renal disease, orbital atherectomy

Critical hand ischemia (CHI) is a relatively infrequent yet potentially devastating clinical entity. It is more frequent in end-stage renal disease (ESRD) patients with failed arteriovenous access sites combined with peripheral occlusive arterial disease. CHI presents with pain, ulcerations, tissue necrosis, and/or gangrene, depending on the level of obstruction and the extent of the peripheral arterial disease.¹ Endovascular treatment with balloon angioplasty represents a feasible and safe approach, with high success rates.^{1,2} However, in the presence of heavily calcified lesions, both the procedural and long-term success rates are suboptimal.² Ancillary percutaneous techniques such as atherectomy improve angiographic and clinical outcomes.³ Herein, we present the treatment of CHI in a young patient with ESRD using orbital atherectomy and balloon angioplasty.

Case Description

A 33-year-old male patient with ESRD presented with gangrenous changes in the right index finger (**Figure 1A**). He had a history of 2 failed hemodialysis fistulas and multiple procedures on the right brachial veins and arteries to maintain the function of the hemodialysis access. Vascular access was maintained with 6-Fr, 90-mm Super Arrow-Flex sheath (Teleflex Corporation), No guiding catheter was used. On his angiogram, the right brachial, radial, and ulnar arteries were occluded (**Figures 1B, 1C**). The right brachial artery was crossed with a 0.014" Regalia XS guidewire and Corsair Pro microcatheter (Asahi Intecc) for support (**Figures**

1D, 1E). The calcified distal brachial artery stenosis was treated with 3 initial passes of the 1.25-mm solid-crown Diamondback 360 orbital atherectomy system (Cardiovascular Systems, Inc) and subsequent 4.0-mm balloon angioplasty. The radial and ulnar artery stenoses were treated with sequential balloon angioplasty (2.0 mm, 2.5 mm, and 3.0 mm). Final angiogram showed re-establishment of flow in the right forearm arteries (**Figures 1F, 1G, 1H**). At 30-day follow-up, there was significant clinical improvement with resolution of skin changes in his right index finger and with patent right radial and ulnar arteries by vascular ultrasound.

Discussion

CHI is a rare condition affecting patients with ESRD. More rarely, CHI is the result of Buerger's disease, scleroderma, Raynaud's disease, systemic vasculitis, cardiac embolism, congenital or acquired hypercoagulability, or thoracic outlet syndrome. Patients with ESRD are at increased risk for arterial occlusive disease, resulting in CHI.^{4,5} Shunting of a high volume of blood from the arterial into the venous system through an arteriovenous fistula can contribute to the risk.⁶ Moreover, chronic kidney disease and ESRD are associated with increased vascular calcification,⁷ which poses a significant challenge for interventionists. Ferraresi et al showed that angioplasty of below-the-elbow arteries is feasible and safe.¹ However, in their study, balloon angioplasty was unsuccessful in 18% of the hands due to severely calcified lesions.

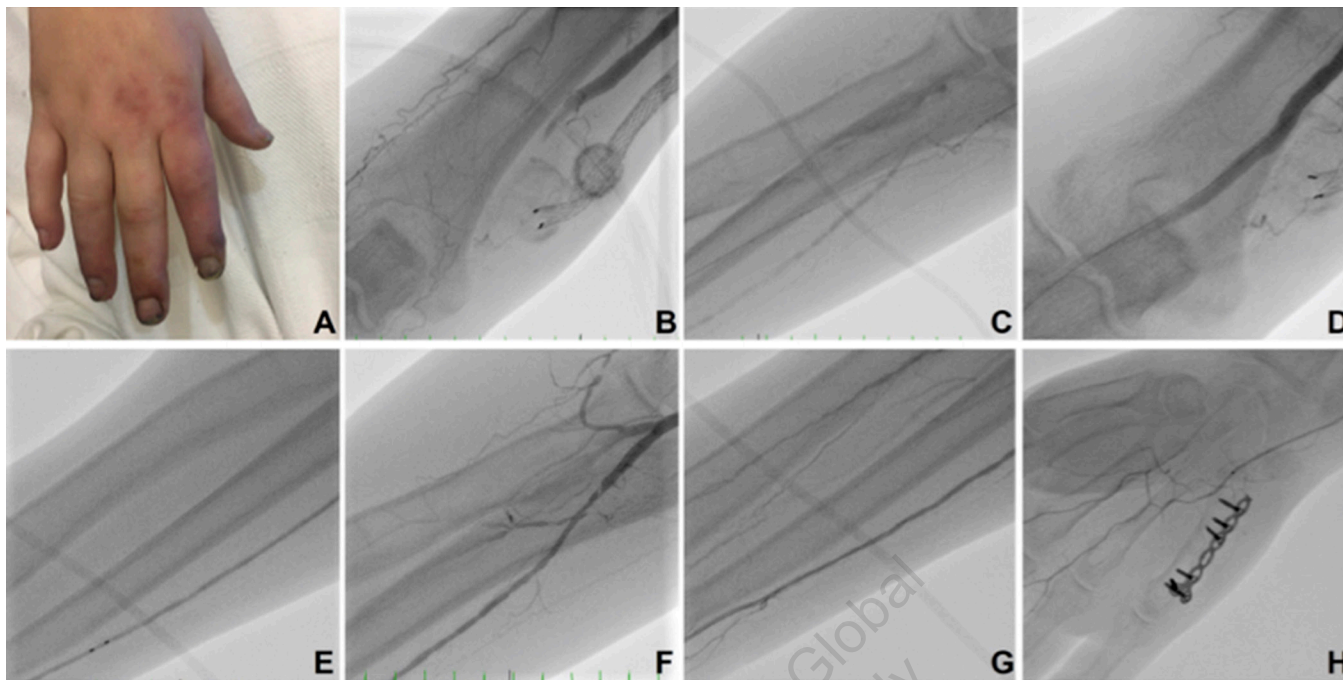


FIGURE 1. (A) Ischemic changes in the right hand with early gangrene findings. (B, C) Baseline angiography of the right forearm showing occlusion of the right brachial, ulnar, and radial arteries. (D, E) Crossing of arterial occlusion with a 0.14" Regalia guidewire and Corsair. (F, G, H) Final angiogram showing re-establishment of flow in the right brachial, ulnar, and radial arteries and palmar arch.

Therefore, plaque modification by atherectomy can be helpful in obtaining more favorable results and reducing complications in heavily calcified vessels.⁸⁻¹⁰

The currently commercially available Diamondback 360 peripheral orbital atherectomy device consists of an eccentrically mounted diamond-coated crown that orbits around a proprietary guidewire. During the rotation of the catheter, the softer tissue flexes away from the crown, allowing preferential ablation of inelastic tissue such as calcified plaque.⁸ Debulking the calcified atherosclerotic plaque with orbital atherectomy improves angiographic results by enhancing vessel compliance and reducing the risk of dissections and bail-out stenting.⁹

Endovascular treatment of below-the-elbow arteries using orbital atherectomy has been rarely reported in the literature. Dishmon et al described a case of successful hand intervention after orbital atherectomy and balloon angioplasty in the interosseous ulnar artery in a patient with CHI.¹⁰ In another report, Bahro et al presented a case of CHI related to a severely calcified lesion in the distal ulnar artery in which they achieved immediate angiographic success with orbital atherectomy and balloon angioplasty with a Chocolate balloon (Medtronic).¹¹ Bahro et al reported the use of orbital atherectomy and balloon angioplasty in a hemodialysis patient with CHI for the treatment of a heavily calcified radial artery stenosis with favorable angiographic and clinical outcomes.¹² In a retrospective, observational, single-center study of 11 CHI patients with calcific disease of the radial artery treated with orbital atherectomy, the authors

reported optimal blood flow restoration in all patients, without any major periprocedural complications.³ All wounds healed and none of the patients required additional revascularization or amputation.

Conclusion

Orbital atherectomy in combination with balloon angioplasty is a safe and effective approach in patients with CHI due to calcified arterial disease.

References

1. Ferraresi R, Pallosi A, Aprigliano G, et al. Angioplasty of below-the-elbow arteries in critical hand ischaemia. *Eur J Vasc Endovasc Surg.* 2012;1;43(1):73-80. Epub 2011 Nov 9. doi:10.1016/j.ejvs.2011.10.006
2. Ruzsa Z, Berta B, Tóth J, et al. Short- and long-term results with a percutaneous treatment in critical hand ischaemia. *Catheter Cardiovasc Interv.* 2019;93(7):1301-1310. Epub 2019 Mar 29. doi:10.1002/ccd.28166
3. Bahro A, Igyarto Z, Martinsen B. Critical hand ischemia treatment via orbital atherectomy—a single center observational retrospective analysis. *Cardiovasc Revasc Med.* 2017;18(2):91-94. Epub 2016 Oct 29. doi:10.1016/j.carrev.2016.10.009
4. Valji K, Hye RJ, Roberts AC, Oglevie SB, Ziegler T, Bookstein JJ. Hand ischemia in patients with hemodialysis access grafts: angiographic diagnosis and treatment. *Radiology.* 1995;196(3):697-701. doi:10.1148/radiology.196.3.7644631
5. Yeager RA, Moneta GL, Edwards JM, et al. Relationship of hemodialysis access to finger gangrene in patients with end-stage renal disease. *J Vasc Surg.* 2002;36(2):245-249; discussion 249. doi:10.1067/mva.2002.125026

6. Tordoir JHM, Dammers R, Sande FM van der. Upper extremity Ischemia and hemodialysis vascular access. *Eur J Vasc Endovasc Surg*. 2004;27(1):1-5. doi:10.1016/j.ejvs.2003.10.007
7. Rocha-Singh KJ, Zeller T, Jaff MR. Peripheral arterial calcification: prevalence, mechanism, detection, and clinical implications. *Catheter Cardiovasc Interv*. 2014;83(6):E212-E220. Epub 2014 Feb 10. doi:10.1002/ccd.25387
8. Saab F, Martinsen BJ, Wrede D, Behrens A, Adams GL, Mustapha J. Orbital atherectomy for calcified femoropopliteal lesions: a current review. *J Cardiovasc Surg (Torino)*. 2019;60(2):212-220. Epub 2019 Jan 28. doi:10.23736/S0021-9509.19.10879-8
9. Korosoglou G, Giusca S, Andrassy M, Lichtenberg M. The role of atherectomy in peripheral artery disease: current evidence and future perspectives. *Vasc Endovasc Rev*. 2019;2(1):12-18. doi:10.15420/ver.2018.16.2
10. Dishmon D. Atherectomy in the occluded forearm: a case presentation of interosseous ulnar artery treatment. *Vasc Disease Manag*. 2016;13:E95-E100.
11. Bahro A, Igyarto Z, Williams C, Abraham JP, Martinsen BJ. Treatment of critical hand ischemia via orbital atherectomy and focal force balloon angioplasty: a mini-review. *Cardiovasc Revasc Med*. 2019;20(3):248-253. Epub 2018 Apr 6. doi:10.1016/j.carrev.2018.03.012
12. Bahro A, Williams C, Igyarto Z, Martinsen BJ. Treatment of critical hand ischemia via orbital atherectomy and balloon angioplasty in an African-American hemodialysis patient. *Cath Lab Digest*. 2019;27(9).

From ¹Pamukkale University Hospital, Department of Cardiology, Denizli, Turkey; ²Istanbul University-Cerrahpasa, Cerrahpasa Faculty of Medicine, Department of Cardiology, Istanbul, Turkey; ³University of Texas, MD Anderson Cancer Center, Department of Cardiology, Houston, Texas; ⁴HCA Northside Hospital, St Petersburg, Florida; and ⁵Arkansas Heart Hospital, Department of Cardiology, Little Rock, Arkansas.

Disclosure: The authors have completed and returned the ICMJE Form for Disclosure of Potential Conflicts of Interest. The authors report no conflicts of interest regarding the content herein.

The authors report that patient consent was provided for publication of the images used herein.

Manuscript accepted May 18, 2022.

Address for correspondence: Mehmet Cilingiroglu, MD, FSCAI, FACC, FESC, FAHA, Professor of Medicine, University of Texas, MD Anderson Cancer Center, Department of Cardiology, 7703 Floyd Curl Drive, San Antonio, TX 78229. Email: Cilingiroglumehmet@gmail.com

Copyright 2022 HMP Global
For Personal Use Only