

RENASYS<sup>◇</sup> EDGE

Negative Pressure Wound  
Therapy System

# Clinical Outcomes from RENASYS<sup>TM</sup> EDGE Traditional Negative Pressure Wound Therapy System, a Next Generation Negative Pressure Wound Therapy Device utilized in North American Post-Acute Care Settings

## Authors

Leticia Vallejo<sup>1</sup>, PhD, FNP, MSN, CWS, CSWS  
Angela Arsenault<sup>2</sup>, RN, BN, IIWCC-CAN, MN, NP  
Melissa Gosse<sup>3</sup>, RN, BN, IIWCC-CAN, MSc  
Julie Murdoch<sup>4</sup>, PhD  
Mandy Spitzer<sup>5</sup>, MBA, RN, CWOCN, CFCN

## Affiliations

<sup>1</sup>President and Professor, Wound Care Plus Research and Education Center, San Juan, PR.  
<sup>2</sup>Wound Consultant Nurse Practitioner, Health Association Nova Scotia/igility, Nova Scotia, CA.  
<sup>3</sup>Provincial Professional Development Coordinator, Health Association Nova Scotia/igility, Nova Scotia, CA.  
<sup>4</sup>Director – Global Clinical Strategy, Global Clinical and Medical Affairs, Smith and Nephew, Watford, UK.  
<sup>5</sup>Lead - Global Clinical Strategy, Global Clinical and Medical Affairs, Smith and Nephew, Fort Worth, Texas, USA.

## Corresponding Author

Mandy Spitzer, MBA, RN, CWOCN, CFCN

<sup>2</sup>Senior Clinical Strategy Manager, Global Clinical and Medical Affairs, Smith and Nephew, Fort Worth, Texas, USA.



## Abstract

### Introduction

Negative pressure wound therapy (NPWT) is a wound treatment modality indicated for acute and chronic wounds, most often utilized to expedite the healing process of large and/or highly exuding wounds. Complex dressing application and pump operation, maintenance, and patient concordance with therapy are obstacles often associated with NPWT. The new RENASYS™ EDGE Traditional Negative Pressure Wound Therapy System has recently been introduced, specifically designed to improve upon known clinical, operational, and patient barriers to NPWT.

### Methods

Case information was extracted retrospectively and recorded on anonymized forms. Patient demographics and comorbidities, wound types, locations, characteristics, dressing application, and therapy selection until discontinuation was captured. Cases were captured on 6 patients exhibiting 13 wounds treated with NPWT between August 2023 and September 2024 in North America.

### Results

The RENASYS™ EDGE system was applied to wounds classified as a pressure injury or post-surgical wound. The wounds presented in different anatomical locations, and the patient demographics, comorbidities, levels of chronicity, and durations of therapy varied between all patients. Multiple approved fillers and wound contact layers, different pressure and therapy delivery settings, and dressing application techniques were utilized. Despite the variations in approach, the 13 wounds were observed to fully close or improve in tissue quality, area, and volume.

### Discussion

The new pump was designed to improve access to and clinician and patient acceptance of tNPWT. The cases presented here demonstrate the efficacy of the new RENASYS™ EDGE pump and provide insight into the varied approaches that can be taken in the application of tNPWT.

## Introduction

Chronic wounds are known to carry a high human and economic cost. Rather than healing in a linear fashion, wounds are deemed chronic when they become stalled in a cycle of inflammation, impairing the body's ability to restore granulation and epithelial tissue<sup>1,2</sup>. Wounds are typically deemed to be chronic if they have not healed in 4 to 6 weeks<sup>3</sup>. As a result, chronic wounds are both costly and hard to treat, requiring substantial resources from healthcare systems<sup>4</sup>. Though difficult to quantify, estimates on annual global spend on wound treatment ranges from \$173 billion<sup>5</sup> to \$250 billion<sup>6</sup>.

Negative pressure wound therapy (NPWT) is a wound treatment modality indicated for a range of acute and chronic wounds, most often utilized to expedite the healing process of large and/or highly exuding wounds<sup>7</sup>. It is believed that the effects on wound healing seen with NPWT result from multiple modes of action being applied to the affected tissue<sup>8</sup>. In vitro models have demonstrated that the application of sub-atmospheric

pressure causes a mechanical contraction of the wound edges<sup>9</sup>, increases perfusion<sup>9,10</sup>, and promotes the production of extracellular matrix components<sup>11-13</sup>. Additionally, NPWT facilitates a moist environment while providing continuous removal of excess wound fluid<sup>8</sup> and negative pressure has been shown to help reduce edema<sup>14</sup> and improve vascular<sup>15</sup> and lymphatic<sup>16</sup> circulation.

There are two forms of NPWT on the market, both available from multiple manufacturers. Traditional NPWT (tNPWT) delivers subatmospheric pressure to the wound bed through a mechanical pump which affixes to the wound via tubing that connects to a wound interface secured by an occlusive drape<sup>7,8</sup>. The wound interface is typically changed 2-3 times weekly depending upon the wound characteristics and dressings used, and a disposable canister collects wound exudate and is changed weekly or as needed<sup>7</sup>. Single-use NPWT (sNPWT) applies subatmospheric pressure to wounds through smaller, more portable devices that vary in design, such as therapy setting options, wound interface design, battery operation, and exudate management, with or without a canister<sup>17</sup>. Patients are treated with tNPWT or sNPWT, or a step-across approach from tNPWT to sNPWT can be taken based upon the characteristics of the wound and the patient. For example, tNPWT is best suited for larger, heavily exuding wounds, but the transition to sNPWT may be made once the wound dimensions and volume of exudate have reduced<sup>18</sup>. If a wound is deemed appropriate for sNPWT, the transition of therapy to sNPWT may allow the patient greater freedom throughout therapy due to its smaller, more discreet design.

Complex dressing application and pump operation, maintenance, and patient concordance with therapy are a few of the obstacles often associated with NPWT<sup>19</sup>. Innovations in NPWT technology are helping reduce barriers to therapy. Recently, the new RENASYS™ EDGE Traditional Negative Pressure Wound Therapy System was introduced, specifically designed to address clinical, operational, and patient barriers. To support clinicians, the pump interface offers step-by-step guidance for pump set up, application, and troubleshooting as well as a Bluetooth interface which automatically directs to online support<sup>20</sup>. Operational improvements include a durable design which may minimize the number of device returns due to malfunction<sup>21</sup> and streamline the cleaning, maintenance, and repair processes<sup>20</sup>, which can improve pump utilization efficiency. These changes may ultimately drive down operational costs incurred by the health care system.

A descriptive qualitative study examining patients undergoing NPWT concluded that patients often reported physical limitations, mental burdens, and social limitations during their course of tNPWT<sup>22</sup>. Physical limitations resulted due to pain or the device, mental burdens due to odor or device noise, and social limitations due to not being able to return to work<sup>22</sup>. Despite these disturbances, patients desired an improvement in their condition and seemed to accept

the limitations, even expressing gratitude toward the device as it did help them heal<sup>22</sup>. To improve the patient's experience during therapy, the new RENASYS™ EDGE Pump was designed to be small and lightweight<sup>23</sup>, and the canister affixes to the bottom of the device, reducing the visibility of wound exudate and providing a flat surface to keep the pump upright. It was designed to operate more quietly<sup>24</sup> than previous iterations and offers up to 24-hour battery life<sup>23</sup>. These design innovations intended to improve patient concerns around discretion could result in improved patient concordance.

This case series aims to report the early clinical outcomes made during the routine clinical use of the RENASYS™ EDGE System and also supports the requirement of post market clinical follow up as part of European Union Medical Device Regulation. Three wound specialists at sites in Puerto Rico and Canada collected case reports on 6 patients exhibiting 13 wounds appropriate to receive therapy with the RENASYS™ EDGE Pump.

## Methods

Data for this case series was extracted retrospectively from the medical records and recorded on anonymized data capture forms. The data capture forms instructed clinicians to document patient demographics and comorbidities, wound types and locations, wound characteristics, and dressing application and therapy selection from initiation to discontinuation of the next generation RENASYS™ EDGE Pump or discharge from wound management service. Six patients were selected for the case series, exhibiting a total of 13 wounds that received treatment with the new device. Standard wound photography was captured to record wound progression, with patient consent for photographic images recorded in the medical record. The data from the data capture forms were aggregated and transcribed into an Excel (Microsoft Office 365) spreadsheet file. In addition, each case was described under the following sub-headings; presentation, treatment and outcome. A two-step quality control of data entry was performed. The results were reported as an aggregated data set using descriptive statistics.

Ethics committee approval was not required for this retrospective review of cases, as all data captured and being reported is fully de-identified and there was no prescribed intervention or alteration to the routine care of patients. All products utilized were cleared by local regulatory authorities and used within their indications, as per the device Instructions for Use (IFU).

## Results

All six patient cases were recorded between August 2023 and September 2024. The 13 wounds treated were considered chronic, with wound durations ranging from 4 – 62 weeks, prior to initiation of therapy with the new RENASYS™ EDGE System. One patient was transitioned from an alternative tNPWT device to the new tNPWT pump, the remaining 5 had therapy initiated with the new tNPWT pump. The dressings and disposable products were applied at the discretion of the treating clinicians.

### Patient 1 (Figure 1)

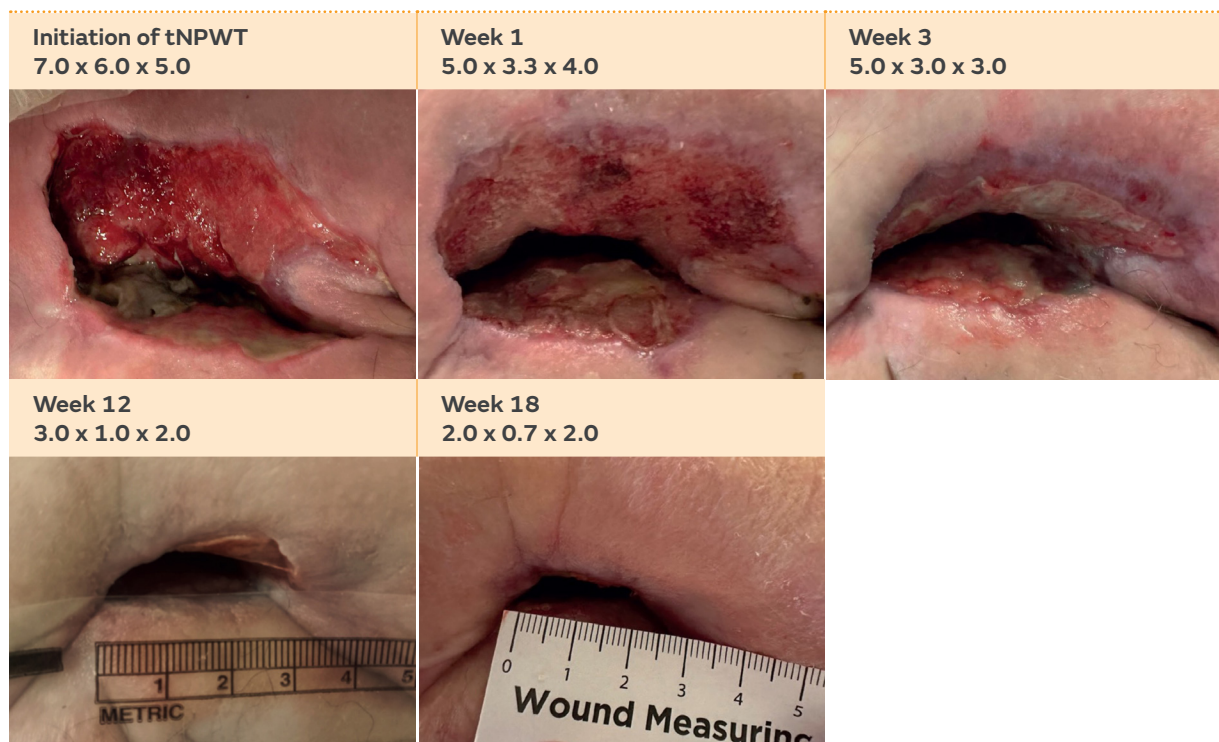


Figure 1: Patient 1 case timeline (weeks) from initiation of the RENASYS™ EDGE System to conclusion of treatment, dimensions (cm), and imagery

#### Presentation:

A 59-year-old male with a history of cerebrovascular accident which resulted in paraplegia with wheelchair dependence and incontinence developed an ulcer on the left buttock, which resulted from a combination of incontinence-associated dermatitis and pressure. Care was provided in the patient's residence, a long-term care (LTC) facility.

#### Treatment:

After 23 weeks of local wound care, nutritional optimization, and attempted pressure relief, tNPWT with RENASYS™ –F Foam Dressing Kit with Soft Port was initiated due to the lack of wound progression.

#### Outcome:

The RENASYS™ EDGE Pump allowed the patient to continue daily activities whilst managing the wound and promoting healing and the wound progressed towards healing despite compromised pressure offloading.

## Patient 2 (Figure 2)

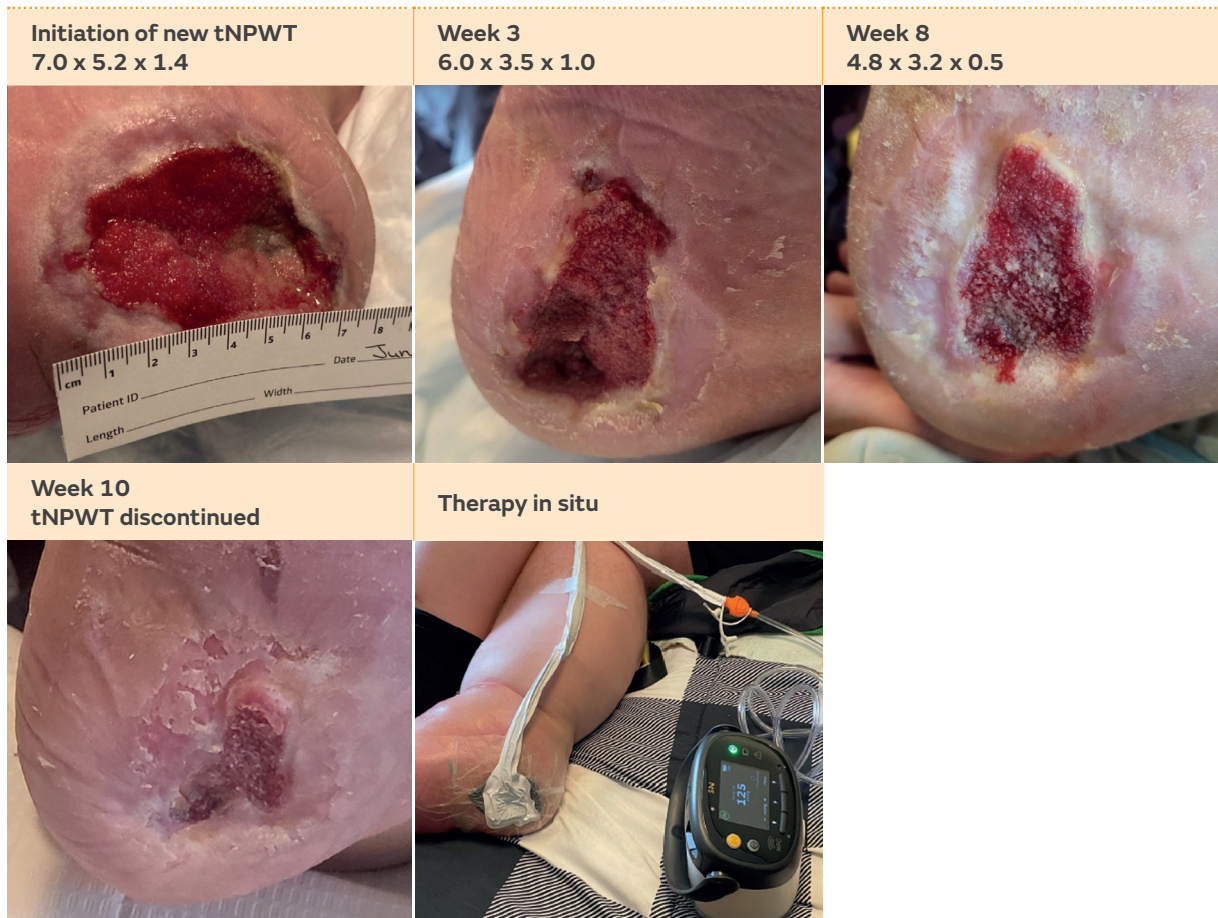

Figure 2: Patient 2 case timeline (weeks) from initiation of the RENASYS™ EDGE System to conclusion of treatment, dimensions (cm), and imagery

### Presentation:

A 43-year-old male with multiple comorbidities developed a Stage 4 pressure injury (PI) to the right heel. The wound became chronic with complications including infection and osteomyelitis. Treatment was delivered at patient's place of residence, a LTC facility.

### Treatment:

After 4 weeks of sharp debridement, treatment with alternative tNPWT device, and antibiotics, the new tNPWT pump was initiated with black foam filler. Following clinical improvement, including reduction in wound size and exudate levels, treatment was stepped across to the PICO™ Single Use Negative Pressure Wound Therapy System.

### Outcome:

The patient reported that treatment with the RENASYS™ EDGE System brought them hope due to the fast and effective results.

## Patient 3 (Figure 3)

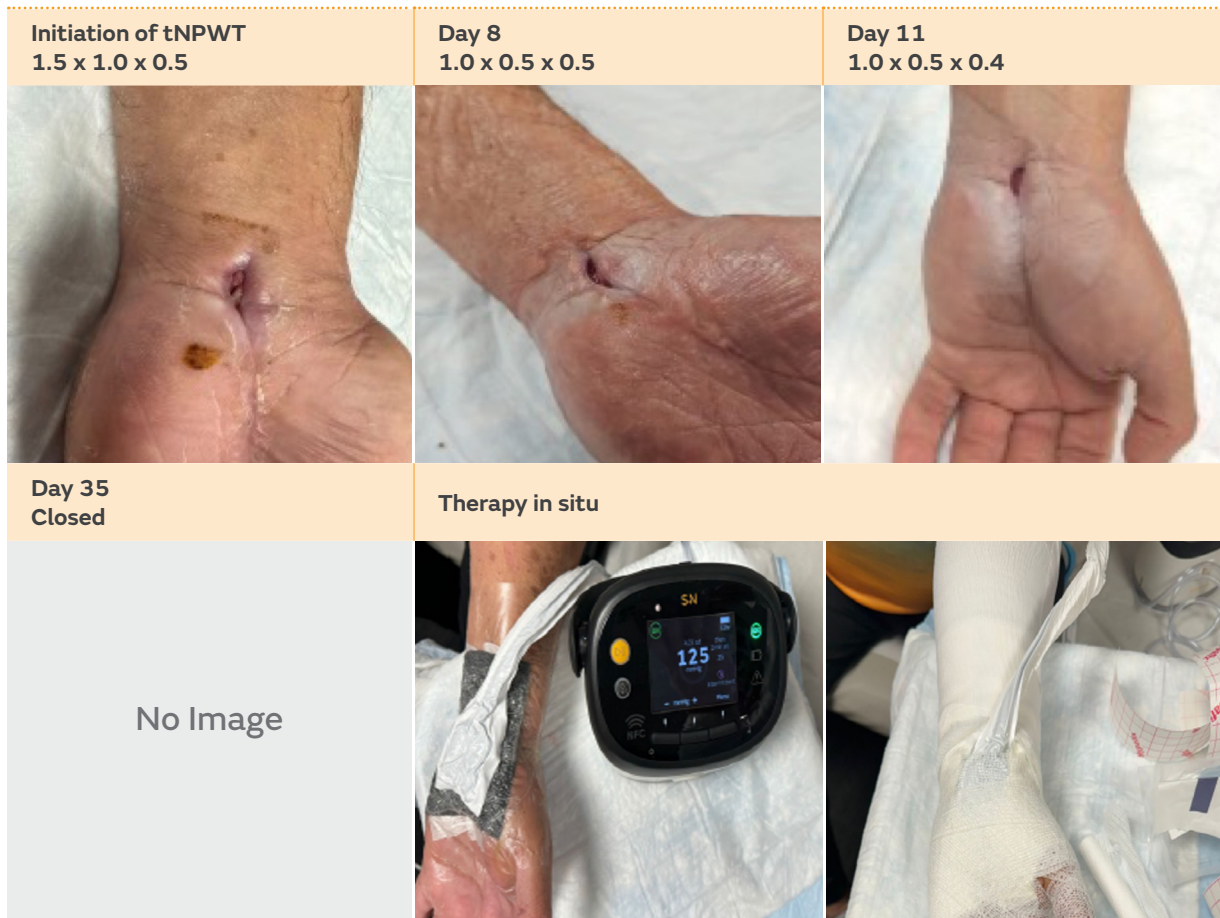

Figure 3: Patient 3 case timeline (days) from initiation of the RENASYS™ EDGE System to conclusion of treatment, dimensions (cm), and imagery

### Presentation:

A 61-year-old male with multiple comorbidities presented to a wound clinic with a dehiscid surgical wound 8 weeks status post-surgery to the right wrist. The wound exhibited tendon exposure and suspected infection.

### Treatment:

Sharp debridement was performed and tNPWT initiated. Sulfate powder was applied at the first application, along with ACTICOAT™ FLEX 3 Antimicrobial Barrier Dressing, a low adherent nanocrystalline silver wound contact layer. The wound was then filled with black foam and the pump set to deliver therapy with variable intermittent pressure.

### Outcome:

The wound fully closed following 35 days of therapy.

## Patient 4 (Figure 4)

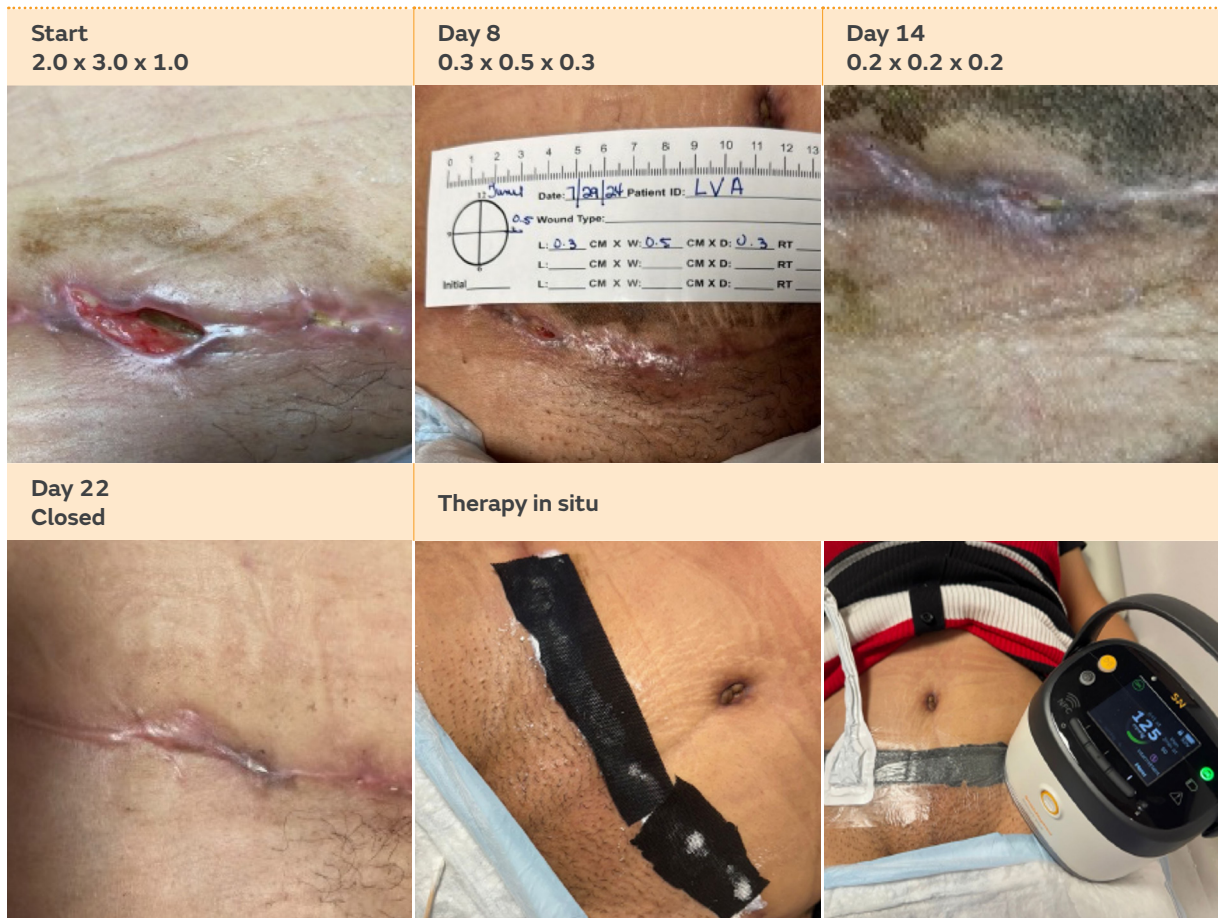

Figure 4: Patient 4 case timeline (days) from initiation of the RENASYS™ EDGE System to conclusion of treatment, dimensions (cm), and imagery

### Presentation:

A 45-year-old female with no relevant medical history or comorbidities presented to a wound clinic 8 weeks status post abdominoplasty with areas of dehiscence along the surgical incision.

### Treatment:

Sulfate powder was applied at the first application of tNPWT, the wound was lined with ACTICOAT™ FLEX Dressing, filled with black foam, and the pump set to deliver variable intermittent pressure.

### Outcome:

Traditional NPWT was discontinued after 14 days, and the wound was closed at the next follow up visit, 22 days after the RENASYS™ EDGE System had been initiated.

## Patient 5 (Figure 5)

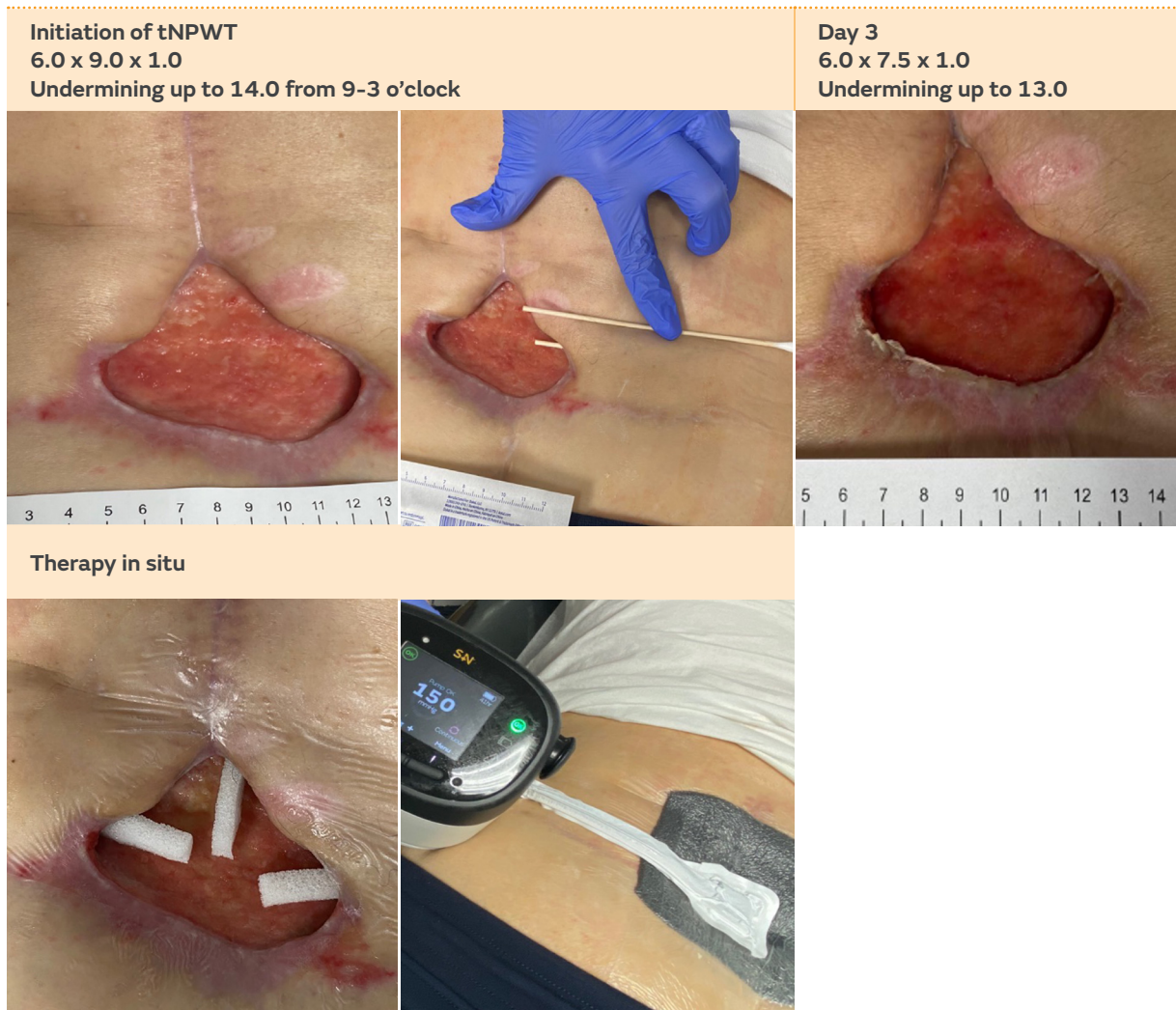


Figure 5: Patient 5 case timeline (days) from initiation of the RENASYS™ EDGE System to conclusion of treatment, dimensions (cm), and imagery

### Presentation:

A 48-year-old male with multiple comorbidities presented to a wound clinic with a chronic post-surgical wound 62 weeks following surgery to the lower back.

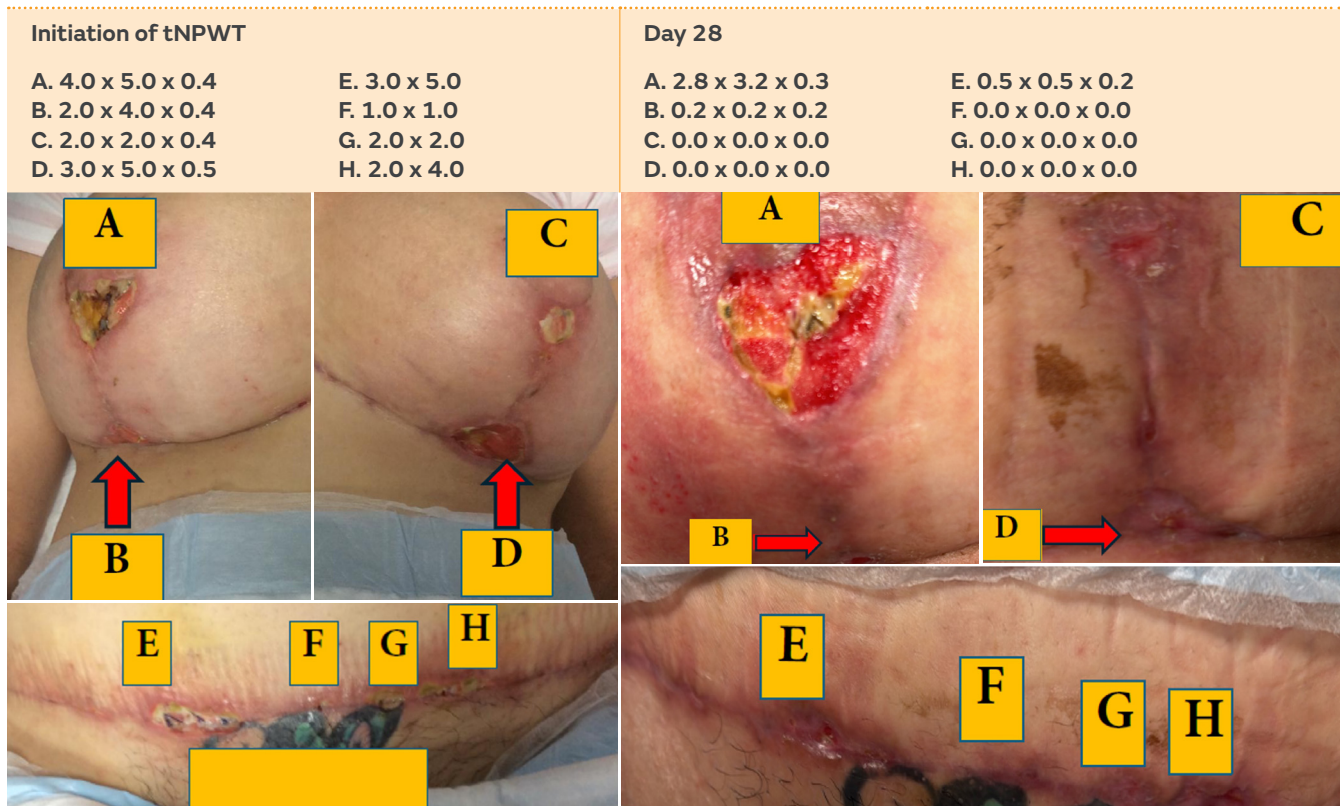
### Treatment:

Sulfate powder was applied at the first application of tNPWT. The undermining was filled with RENASYS™ White Foam, the wound was lined with ACTICOAT™ FLEX Dressing, filled with black foam, and the pump set to deliver variable intermittent pressure.

### Outcome:

After 2 days of therapy the dimensions showed improvement, the color of the wound bed was noted to be progressing from pink to red, and there was an increased amount of granulation tissue.

## Patient 6 (Figure 6)



### Therapy in situ

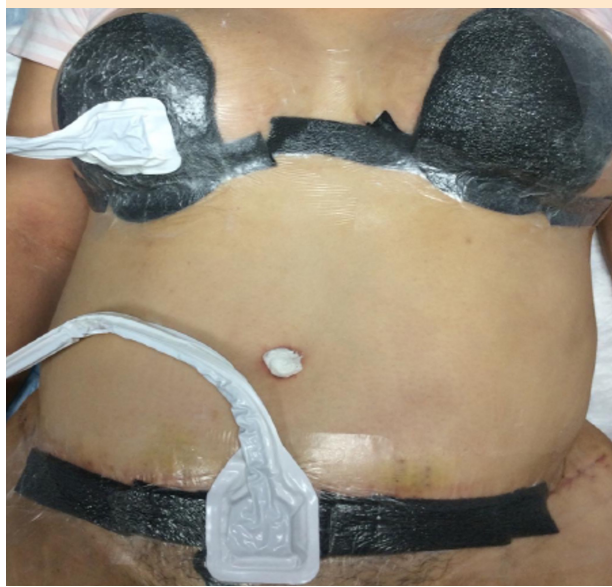

Figure 6: Patient 6 case timeline (days) from initiation of the RENASYS™ EDGE System to conclusion of treatment, dimensions (cm), and imagery

### Presentation:

A 48-year-old female without relevant medical history or comorbidities presented to a wound clinic following breast augmentation and abdominoplasty with a total of 8 non-healing surgical wounds located beneath the nipples, t-junctions, and abdomen.

### Treatment:

Sulfate powder was applied to all 8 wounds at the first application of the RENASYS™ EDGE System. The wounds were lined with ACTICOAT™ FLEX Dressing, filled with black foam, and the pump set to deliver variable intermittent pressure. The 8 wounds were connected through bridging of the dressing and two RENASYS™ Soft Ports were connected to the pump via a RENASYS™ Y-connector. Therapy was held for 4 days after periwound maceration was noted at the routine dressing change, then tNPWT was restarted with no further maceration.

### Outcome:

After 28 days of therapy, the RENASYS™ EDGE System was discontinued and topical dressings applied due to all wounds having progressed or closed.

Table 1 and Figure 7 provide a summary of the aggregated data, demonstrating wound types treated and the outcomes for 6 patients throughout their course of treatment with the new RENASYS™

EDGE Pump. The new tNPWT pump was applied to wounds classified as either a pressure injury or a post-surgical wound, all at different anatomical locations, and with different patient demographics,

comorbidities, levels of chronicity, and durations of therapy. In all cases, the wounds were observed to have fully closed or improved in both tissue quality, area, and volume.

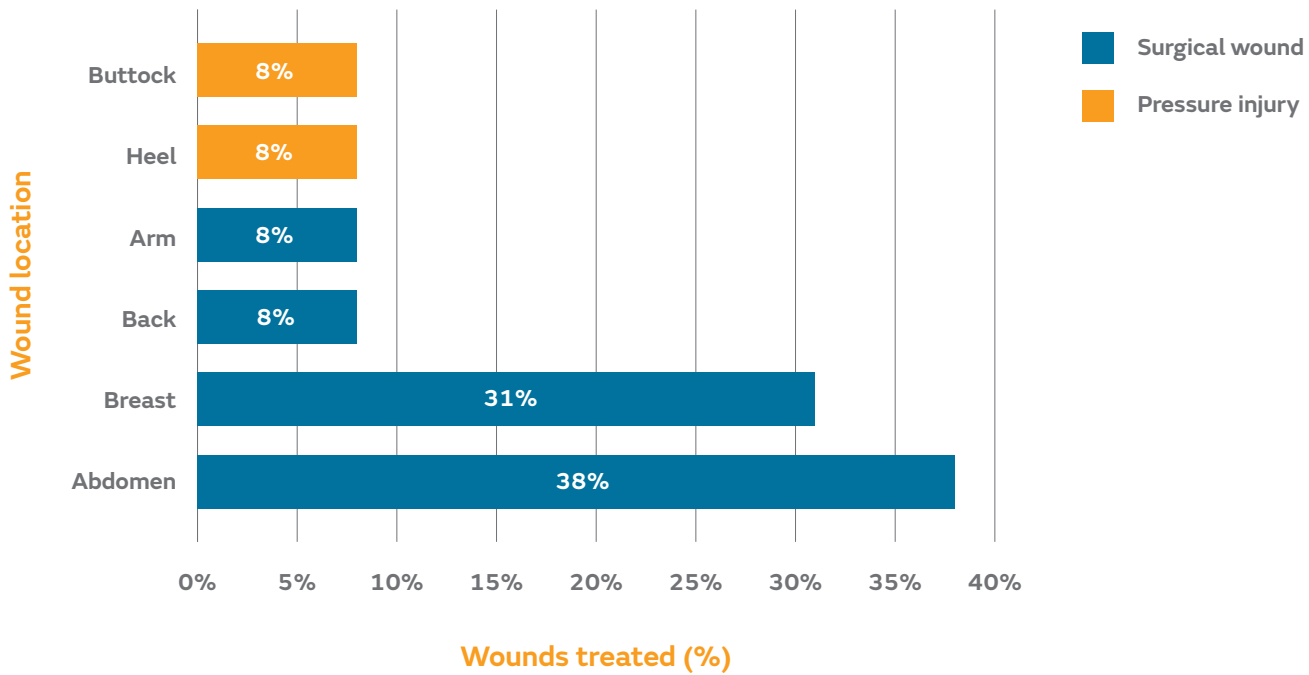
**Table 1: Patient demographics and comorbidities**

Age (years)	Number of patients <sup>a</sup>
40-49	4 (66.66)
50-59	1 (16.66)
60-69	1 (16.66)
Sex	
Male	4 (66.66)
Female	2 (33.33)
Co-morbidities	
Limited mobility	2 (33.33)
Incontinence of bowel or bladder	1 (16.66)
Confirmed or suspected infection	4 (30.77)
BMI >30	1 (16.66)
Nicotine use	2 (33.33)
Hyperlipidemia	1 (16.66)
Hypertension	2 (33.33)
Osteoarthritis	1 (16.66)
Peripheral vascular disease	1 (16.66)
None	2 (33.33)

<sup>a</sup>Percentages may not equal 100 due to rounding.



Figure 7: Wound types and locations

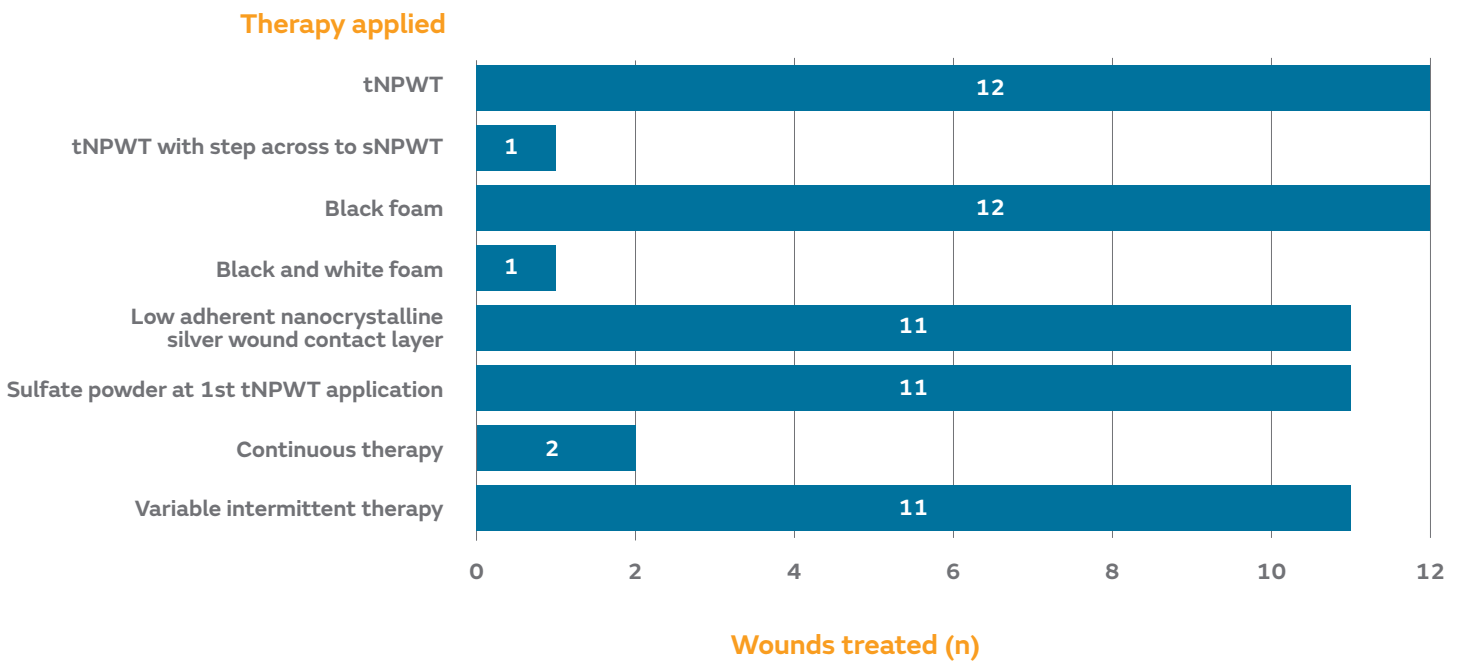


## Discussion

A retrospective analysis of two commonly used tNPWT systems demonstrated no differences in the rate of healing, duration of therapy, or rate of complications, indicating that clinical outcomes are similar across tNPWT systems<sup>25</sup>. Despite the known efficacy of tNPWT, the literature supports that aspects of the therapy delivery, including discomfort with treatment and the physical and social limitations, are burdensome to patients<sup>22</sup>. Additionally, NPWT is delivered across many care settings and monitored by patients and clinicians with varying levels of training. Simplicity of pump design and ease of troubleshooting can therefore impact clinical outcomes by reducing lost therapy hours from inadequate dressing seal, depletion of battery, or a full canister. Therefore, innovations in how NPWT systems are designed may influence concordance with therapy and therefore the clinical outcomes achieved.

This case series demonstrates that this new RENASYS™ EDGE System delivered the desired clinical outcomes, while describing the potential impact of the new tNPWT design features on usability. The cases were collected from 6 patients receiving care in the post-acute setting for 13 chronic wounds that resulted from pressure or surgical wound healing complications. The patients included varied in comorbidities and wound etiologies. The case presentations also provide insight into the numerous approaches that can be taken in the application of tNPWT, as multiple different approved fillers were used, with and without wound contact layers. Different pressure and therapy delivery settings and dressing application techniques were also utilized (Figure 8). Despite the variations in approach, all 13 wounds evaluated in this 6-patient case series either improved or closed throughout the course of therapy with the new RENASYS™ EDGE Pump (Table 2) (Figure 9).

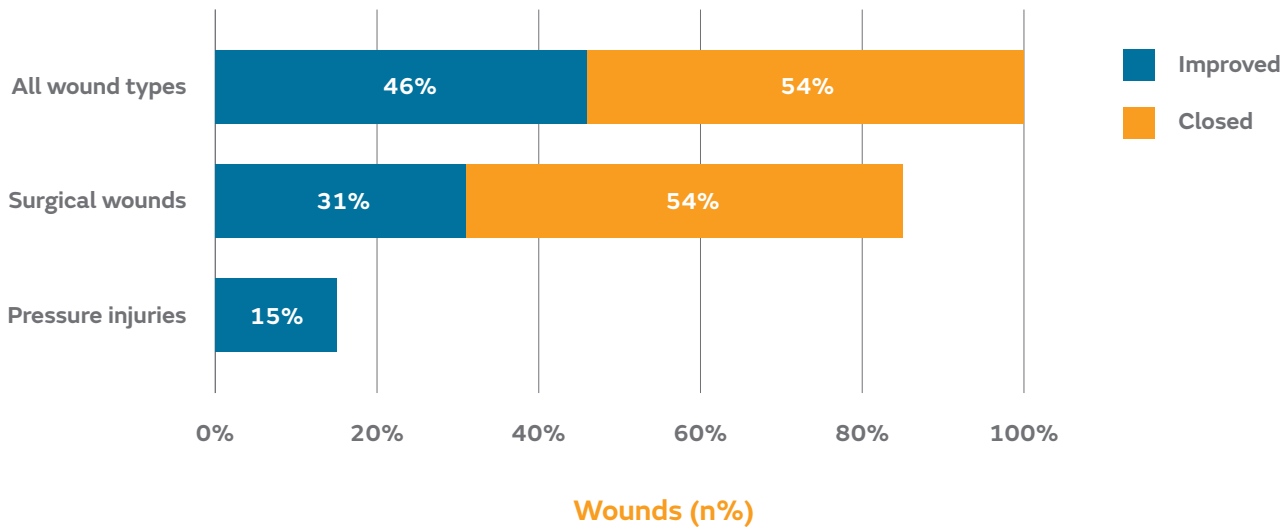
**Figure 8: Therapies applied to the wounds treated**



**Table 2: Mean percentage change in wound dimensions by area (cm<sup>2</sup>) and volume (cm<sup>3</sup>) from start to end of treatment with the RENASYS™ EDGE System**

Patient	Wound Location		Number of NPWT days	Wound dimensions at presentation		Wound dimensions at discontinuation of tNPWT		Percentage wound dimension change (%)	
				Area a(cm <sup>2</sup> )	Volume (cm <sup>3</sup> )	Area (cm <sup>2</sup> )	Volume (cm <sup>3</sup> )	Area cm <sup>2</sup>	Volume cm <sup>3</sup>
1	Buttock		126	42	210	1.4	2.8	96.67%	98.67%
2	Heel		70	36.4	50.96	4.42	2.21	87.86%	95.66%
3	Arm		35	1.5	0.75	0	0	100.00%	100.00%
4	Abdomen		22	6	6	0	0	100.00%	100.00%
5	Back		2	54	54	45	45	16.67%	16.67%
6	A	Right breast	28	20	8	8.96	2.688	55.20%	66.40%
	B	"Right T-junction"		8	3.2	0.04	0.008	99.50%	99.75%
	C	Left breast		4	1.6	0	0	100.00%	100.00%
	D	"Left T-junction"		15	7.5	0	0	100.00%	100.00%
	E	Abdomen		15		0.25	0.05	98.33%	
	F	Abdomen		1		0	0	100.00%	Depth not captured
	G	Abdomen		4		0	0	100.00%	Depth not captured
	H	Abdomen		8		0	0	100.00%	Depth not captured

**Figure 9: Wound improved or closed, total and by wound type (%)**



## Limitations

The authors would like to acknowledge that this was not a controlled clinical study, but rather an analysis of routine real-world practice whereby data was extracted from patient medical records. The results detail a small sample of 6 patients from 3 clinical sites with various wound etiologies and comorbidities.

## Conclusion

Negative pressure wound therapy is recognized as an effective adjunctive therapy, known to effectively manage and progress wounds toward closure. Since the inception of NPWT, this therapy has been accepted across a myriad of medical specialties, both for treatment in the acute and post-acute setting. However, it is understood that there are obstacles to the therapy such as cost, availability, ease of use, and the patient's experience living with the therapy. RENASYS™ EDGE Traditional Negative Pressure Wound Therapy System offers on-screen instruction helps guide clinicians through application and troubleshooting, and the pump was designed to improve portability and discretion while using the device. The pump's durable design may improve healthcare efficiency by reducing device repairs and streamlining cleaning and maintenance between patients. This new pump was designed to mitigate many of the hindrances often experienced with this therapy, improving access to and acceptance of this therapy by both clinicians and patients.

## Disclosures

Dr Leticia Vallejo, Angela Arsenault, and Melissa Gosse received compensation from Smith and Nephew for their time spent drafting and submitting this manuscript. Ms Spitzer and Dr Murdoch are employees of Smith and Nephew.

## Acknowledgments

The authors would like to thank Ms Joanne Handsaker and Ms Carmen Corujo at Smith and Nephew for their support in the early start up activities for this case series.

## Funding Source

Smith+Nephew.

## References

1. Falanga V, Isseroff RR, Soulika AM, et al. Chronic wounds. *Nat Rev Dis Primers*. 2022;8(1):50.
2. Eckert KA, Fife CE, Carter MJ. The Impact of Underlying Conditions on Quality-of-Life Measurement Among Patients with Chronic Wounds, as Measured by Utility Values: A Review with an Additional Study. *Advances in Wound Care*. 2023;12(12):680-695.
3. Wallace H, Basehore, BM, Zito, PM. *Wound Healing Phases*. Treasure Island (FL): StatPearls Publishing.
4. Nussbaum SR, Carter MJ, Fife CE, et al. An Economic Evaluation of the Impact, Cost, and Medicare Policy Implications of Chronic Nonhealing Wounds. *Value Health*. 2018;21(1):27-32.
5. Queen D, Harding K. What's the true costs of wounds faced by different healthcare systems around the world? *International Wound Journal*. 2023;20(10):3935-3938.
6. Wound healing is a billion dollar drain on the health system – this discovery hopes to plug it. Monash University. <https://www.monash.edu/news/articles/wound-healing-is-a-billion-dollar-drain-on-the-health-system-this-discovery-hopes-to-plug-it>. Published 2024. Accessed September 7, 2024.
7. Birke-Sorensen H, Malmsjo M, Rome P, et al. Evidence-based recommendations for negative pressure wound therapy: treatment variables (pressure levels, wound filler and contact layer)--steps towards an international consensus. *J Plast Reconstr Aesthet Surg*. 2011;64 Suppl:S1-16.
8. Apelqvist J, Willy C, Fagerdahl A, et al. EWMA Document: Negative Pressure Wound Therapy: Overview, Challenges and Perspectives. *Journal of Wound Care*. 2017;26:S1-S154.
9. Morykwas MJ, Argenta LC, Shelton-Brown EI, McGuirt W. Vacuum-assisted closure: a new method for wound control and treatment: animal studies and basic foundation. *Ann Plast Surg*. 1997;38(6):553-562.
10. Lohman RF, Lee RC. Discussion: Vacuum Assisted Closure: Microdeformations of Wounds and Cell Proliferation. *Plastic and Reconstructive Surgery*. 2004;114(5).
11. Wilkes R, Zhao Y, Kieswetter K, Haridas B. Effects of dressing type on 3D tissue microdeformations during negative pressure wound therapy: a computational study. *J Biomech Eng*. 2009;131(3):031012.
12. Baudouin-Legros M, Paquet JL, Brunelle G, Meyer P. Role of nuclear proto-oncogenes in the proliferation of aortic smooth muscle cells in spontaneously hypertensive rats. *J Hypertens Suppl*. 1989;7(6):S114-115.
13. Labler L, Rancan M, Mica L, Härter L, Mihic-Probst D, Keel M. Vacuum-assisted closure therapy increases local interleukin-8 and vascular endothelial growth factor levels in traumatic wounds. *J Trauma*. 2009;66(3):749-757.
14. Kamolz LP, Andel H, Haslik W, Winter W, Meissl G, Frey M. Use of subatmospheric pressure therapy to prevent burn wound progression in human: first experiences. *Burns*. 2004;30(3):253-258.
15. Hudlicka O, Brown M, Egginton S. Angiogenesis in skeletal and cardiac muscle. *Physiol Rev*. 1992;72(2):369-417.
16. Yuan Y, Niu Y, Xiao W, Qi B, Hu X, Yu A. The Effect and Mechanism of Negative Pressure Wound Therapy on Lymphatic Leakage in Rabbits. *Journal of Surgical Research*. 2019;235:329-339.
17. Negative Pressure Wound Therapy. WoundSource Product Guide Web site. <https://www.woundsource.com/product-category/negative-pressure-wound-therapy>. Published 2024. Accessed September 7, 2024.
18. Brownhill VR, Huddleston E, Bell A, et al. Pre-Clinical Assessment of Single-Use Negative Pressure Wound Therapy During In Vivo Porcine Wound Healing. *Adv Wound Care (New Rochelle)*. 2021;10(7):345-356.
19. Fife C WD. The Challenges of Negative Pressure Wound Therapy in Clinical Practice. *Today's Wound Clinic*. 2012.
20. Smith+Nephew. Post-acute RENASYS™ EDGE System. <https://www.smith-nephew.com/en-us/health-care-professionals/products/advanced-wound-management/renasys-edge-negative-pressure-wound-therapy-system>. Published 2024. Accessed August 23, 2024.
21. Smith+Nephew. Summary of RENASYS™ EDGE pump mechanical and electronic reliability testing. Internal Report. CSD.AWM.22.069. 2022.
22. Miyanaga A, Miyanaga T, Sakai K, Konya C, Asano K, Shimada K. Patient experience of negative pressure wound therapy: A qualitative study. *Nursing Open*. 2023;10(3):1415-1425.
23. RENASYS™ EDGE Negative Pressure Wound Therapy Clinician User Manual. In: Smith & Nephew Medical Limited; 2023.
24. Smith+Nephew. Summary of footprint, portability, wearability, weight and audible noise for the RENASYS™ EDGE system. Internal Report. CSD.AWM.22.067. 2022.
25. Hurd T, Rossington A, Trueman P, Smith J. A Retrospective Comparison of the Performance of Two Negative Pressure Wound Therapy Systems in the Management of Wounds of Mixed Etiology. *Adv Wound Care (New Rochelle)*. 2017;6(1):33-37.