



# Translesional Assessment of Hemodynamics in Patients Undergoing Endovascular Therapy for Lower Extremity Peripheral Arterial Disease

Anand Prasad, MD; Marlene Garcia, MD; Ermias Sori, MD; Ghazwan Elias, MD;  
Badr Harfouch, MD; Christy Luna, BS; Yogamaya Mantha, MD; Anum Asif, MD

## Abstract

**Introduction.** The role of real-time, invasive hemodynamic assessment during endovascular therapy for lower extremity peripheral arterial disease (PAD) has not been well established. The purpose of this study was to examine the feasibility of the Navvus microcatheter coupled to the RXi system (ACIST Medical Systems) to measure lower extremity pre- and post-intervention resting and hyperemic translesional systolic pressure gradients (sTPG) and mean distal to proximal pressure gradients (Pd/Pa).

**Methods.** A total of 22 patients were included with a mean age  $63.2 \pm 10.1$  years. Critical limb ischemia (CLI) was the primary diagnosis in thirteen (59.1%) patients and 9 (40.9%) had claudication. Invasive hemodynamic measurements were obtained using the Navvus microcatheter at baseline and before and after each specific intervention (angioplasty and/or directional atherectomy) without and then with hyperemia using intra-arterial adenosine. **Results.** The mean baseline non-hyperemic sTPG was  $32.0 \pm 18.6$  mmHg. Hyperemic responses for the sTPG and the Pd/Pa ratio were noted at baseline and post-treatment. Mean sTPG decreased over the course of endovascular treatments ( $32.0 \pm 18.6$  to  $10.0 \pm 11.7$  mmHg respectively,  $P < .001$ ). A hyperemic response was demonstrated for the Pd/Pa, with the ratio decreasing at each time point ( $P < .01$ ). Both the non-hyperemic and hyperemic Pd/Pa increased after endovascular treatments as compared with each prior baseline ( $P < .001$ ). Atherectomy alone significantly decreased the sTPGs and increased the Pd/Pa ratio ( $P < .001$ ). **Conclusions.** The Navvus microcatheter demonstrated feasibility in measuring changes in lower extremity hemodynamics during endovascular therapy.

J CRIT LIMB ISCHEM 2023;3(2):E44-E53, Epub 2023 June 6.

Key words: peripheral arterial disease, peripheral artery disease, hemodynamic, endovascular therapy, translesional

## Introduction

The use of invasive hemodynamic measurements such as fractional flow reserve (FFR) and the instantaneous wave-free ratio (iFR) have revolutionized coronary interventions. These techniques allow for the real-time assessment of ischemic severity and help determine the need for intervention. The clinical value of FFR for coronary physiology was derived from a collection of multiple prospective, randomized controlled trials with outcomes data. A similar body of literature is lacking for the lower extremity peripheral arterial vascular bed. Lower extremity peripheral arterial disease (PAD) remains a growing problem globally. Peripheral vessels are characterized by long length and thus, PAD lesions are often diffuse in nature. Lesions may also appear eccentric, involve multiple vessel levels, and are therefore

difficult to assess for hemodynamic severity.

The most common technology to perform FFR in the coronary vessels is via the use of a .014" diameter pressure wire. These wires are advantageous in their ability to cross lesions and subsequently serve as the platform for device delivery. However, repeated measurements after each intervention require detachment and reattachment of the pressure connector and potentially introduce the risk of wire damage and equalization drift. Countering these limitations, the Navvus microcatheter coupled to the RXi system, uses a microcatheter with a fiber optic sensor that can be delivered over any .014" wire using a rapid exchange technique. The system has been validated and used for clinical measurements extensively in coronary vasculature. Given the above-mentioned limitations of the .014" pressure wire platforms and the nature of peripheral lesions, the Navvus

microcatheter may have utility in the lower extremity circulation for assessment of hemodynamics. The system carries an on-label indication for diagnosis of intravascular pressure measurements in PAD patients. Furthermore, the catheter can be delivered over distal embolic filter wires which are not uncommonly used in the context of atherectomy. The purpose of the present pilot study was to prospectively evaluate the feasibility of using the Navvus microcatheter system to track changes in resting and hyperemic translesional hemodynamics during endovascular treatments for PAD.

Methods

**Inclusion criteria and definitions.** Patients undergoing clinically-indicated lower extremity endovascular therapy were enrolled prospectively. The higher of the two brachial pressures was used for the present analysis in all index calculations. For a given limb, *ABI-High* was calculated as the higher of the two pedal pressures divided by the highest brachial pressure and *ABI-Low* was calculated as the lower of the two pedal pressures divided by the highest brachial pressure. We chose to examine both the *ABI-High* and the *ABI-Low* as prior studies have demonstrated that the magnitude of risk factor associations, relationship to ethnicity, and sensitivity for PAD in population studies varies by definition used.<sup>1</sup> Any *ABI* > .9 and ≤ 1.4 was considered normal. Given the diffuse nature of lower extremity PAD, individual lesions were not assessed. Rather, hemodynamic assessment was focused on target segments. Measurements, as described below, were made across segments. The segments were defined as external iliac, femoropopliteal which included the superficial femoral artery and popliteal arteries, popliteal into tibial which encompassed lesions which began in the popliteal and continued into the proximal tibial vessels, and isolated tibial lesions which included any one of the three primary tibial vessels. A single segment was treated for each patient. All patients undergoing non-tibial interventions were required to have at least one inline vessel to the foot at baseline. Procedural success was defined as successful treatment of the lesions within a target segment with <30% residual visual stenosis without complications. Lesion calcification was defined as the presence of visible calcium on fluoroscopy in the target segment.

**Procedural techniques.** Access was obtained using standard micropuncture technique. All interventions were performed via 6 or 7 Fr, 45 or 60 cm length hydrophilic sheaths in the case of contralateral access, and via 25 cm sheaths for ipsilateral access. Heparin was used for anticoagulation. A radio-opaque marking ruler was used for the segment of interest to help with landmark location. Percutaneous transluminal balloon angioplasty (PTA) for femoropopliteal lesions was performed with standard and/or drug-coated peripheral balloons. Stenting, when performed, was done with nitinol self-expanding stents.

Atherectomy when performed was done with the Turbohawk (Medtronic) directional atherectomy catheter using a SpiderFX distal embolic protection (Medtronic). A .014" diameter work-horse wire or filter wire as noted above was used in each case. The choice of specific endovascular treatments was left up to the primary operator.

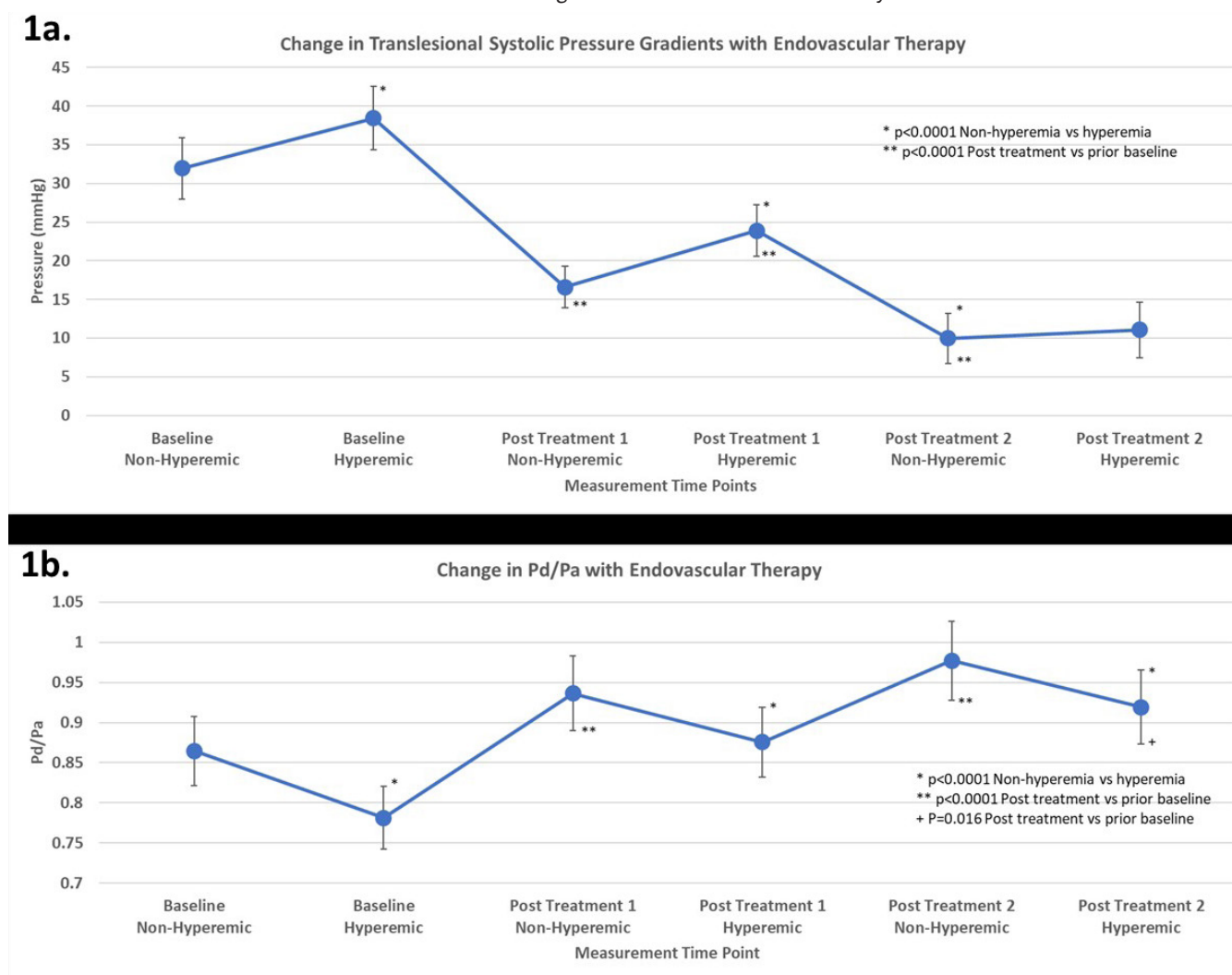
**Hemodynamic measurements.** Invasive hemodynamic measurements were obtained at baseline and before and after each specific intervention without and then with hyperemia. For example, for a patient undergoing atherectomy followed by PTA, non-hyperemic followed by hyperemic measurements were taken at baseline, post atherectomy (treatment 1), and post PTA (treatment 2). Invasive measurements were made with the Navvus microcatheter connected to the ACIST RXi system. The Navvus microcatheter data were also recorded using the catheterization laboratory hemodynamic system (Xper Information Management). The proximal equalization was made at the sheath tip and repeated at each instance of catheter reintroduction. At the start of each case, the sheath was placed and left in place at an angiographically healthy

TABLE 1. SUBJECT CHARACTERISTICS.	
CHARACTERISTIC (MEAN ± SD, COUNTS AND PERCENTAGES)	DATA
CLINICAL CHARACTERISTICS	
AGE (YEARS)	62.4 ± 10.6
BODY MASS INDEX (KG/M2)	30.8 ± 5.0
GENDER (MALE)	15 (68.2%)
DIABETES	20 (90.9%)
HYPERTENSION	22 (100%)
CORONARY ARTERY DISEASE	16 (72.7%)
HEART FAILURE	5 (22.7%)
CHRONIC KIDNEY DISEASE	9 (40.9%)
PAD PRESENTATION	
CRITICAL LIMB ISCHEMIA	13 (59.1%)
CLAUDICATION	9 (40.9%)
RUTHERFORD STAGE 2	2 (9.1%)
RUTHERFORD STAGE 3	7 (31.8%)
RUTHERFORD STAGE 4	2 (9.1%)
RUTHERFORD STAGE 5	7 (31.8%)
RUTHERFORD STAGE 6	4 (18.2%)
MEDIAN ABI-HIGH TARGET LIMB	.81
MEDIAN ABI-LOW TARGET LIMB	.80
PAD = peripheral arterial disease; SD = standard deviation	

(minimal plaque by visual inspection) appearing location. The distal measurement point was selected as an angiographically healthy segment using similar criteria. The specific spot of distal measurement was matched to the radiopaque marking ruler without changing of camera projection for subsequent measurements. In general, for external iliac lesions, the typical distal measurement location was the distal common femoral artery (CFA); for the superficial femoral artery (SFA), it was the P3 segment of the popliteal artery, for the popliteal artery, it was the tiboperoneal trunk or proximal patent tibial artery, and for the popliteal into tibial and isolated tibial vessels, it was the distal healthiest segment of the infrapopliteal vessel. Intra-arterial (through the sheath) nitroglycerin was given prior to measurements (200 mcg intra-arterial). Hyperemia was achieved using intra-arterial administration of 100 mcg of adenosine.<sup>2</sup> Data were recorded for 20 seconds. After a given

measurement, no further measurements were taken for a minimum of 5 minutes or until return to baseline.

Specific measurement variables recorded using the Navvus microcatheter and the ACIST RXi console included nadir Pd (pressure distal), Pa (pressure at the sheath tip) and nadir Pd/Pa, and maximal translesional peak-to-peak systolic gradient (sTPG) using the Xper hemodynamic system. Cuff blood pressure and heart rate were noted at each stage of measurement. Continuous electrocardiographic monitoring was performed. The operator was blinded to the Navvus hemodynamic measurements, and decisions about specific endovascular techniques were made based on angiographic appearance as per routine care. Lesion length was estimated using the radiopaque marking ruler, and percent diameter stenosis was determined by visual estimation by the primary operator. Intravascular ultrasound (IVUS) was not utilized in this study.



**Figure 1. (a)** Change in translesional systolic pressure gradients (sTPG) with endovascular therapy. A hyperemic response to adenosine is shown. Serial endovascular treatments result in reductions in the sTPGs. **(b)** Change in distal to proximal mean pressures (Pd/Pa) with endovascular therapy. A hyperemic response to the Pd/Pa is shown. Serial endovascular treatments increased the Pd/Pa.

TABLE 2. PROCEDURE DETAILS.

Case	Target Vessel Segment	Length of disease within treated segment (mm)	Baseline % diameter stenosis of most severe lesion in segment	Treatment(s) Utilized	Post intervention % diameter stenosis of most severe lesion in treated segment
1	SFA	150	95	DA,DCB	10
2	AT	120	95	DA,PTA	20
3	SFA	200	70	DA,DCB	10
4	SFA-Popliteal	80	70	DA,PTA	10
5	Iliac	20	95	PTA,STENT	10
6	Popliteal-Peroneal	120	95	DA,PTA	30
7	SFA	40	50	PTA,DCB	0
8	PT	150	99	DA,PTA	0
9	SFA	120	70	DA,DCB	20
10	Popliteal-Peroneal	80	95	DA,DCB	10
11	SFA-Popliteal	40	70	DA,PTA	10
12	SFA-Popliteal	20	70	DA,DCB	10
13	Popliteal-PT	100	70	DA	10
14	AT	15	80	PTA	10
15	SFA	40	95	DA,DCB	10
16	SFA	120	80	DCB,STENT	20
17	Popliteal-AT	10	70	DA	20
18	AT	25	95	PTA	0
19	Peroneal	15	95	PTA	10
22	Peroneal	80	99	DES	0

SFA = superficial femoral artery; AT = anterior tibial; PT = posterior tibial; DA = direct angioplasty; DCB = drug-coated balloon; PTA = percutaneous angioplasty; DES = drug-eluting stent

**Follow-up.** In-hospital outcomes including vascular complications (bleeding/hematoma) were collected. Follow-up data were collected at 4 to 6 weeks post-intervention. The timing of follow-up in-person visits and measurement of additional non-invasive testing was left up to the discretion of the treating team. Data were collected by phone calls and chart review on hospitalizations, need for repeat revascularization, unplanned and planned amputations, myocardial infarction, and death.

**Statistical analysis.** Data are presented as mean and standard deviation or as counts and percentages as appropriate. Two group and pre- and post-comparisons were made by use of Student's T-test. Multiple group and time point comparisons of hemodynamic data were made by repeated ANOVA measures. Pearson correlation was used to compare angiographic and hemodynamic variables. A P-value of .05 was considered to be significant. Analyses were done using SigmaPlot/Stat (Systat).

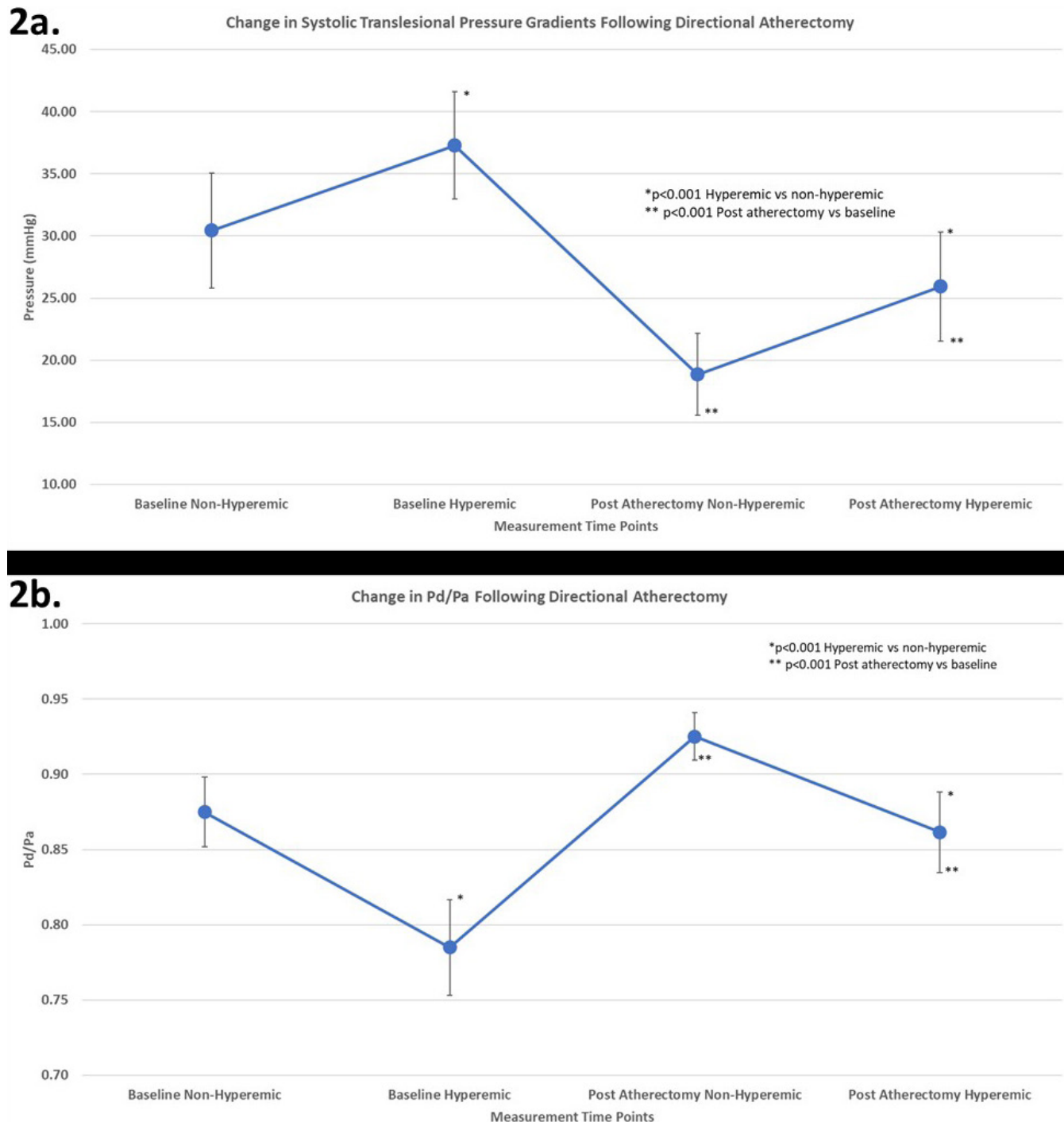
## Results

**Baseline characteristics.** Subject characteristics are shown in **Table 1**. A total of 22 patients were included with a mean age  $63.2 \pm 10.1$  years. Diabetes was present in 20 (91.0%) subjects, 15 (68.2%) were male, 16 (72.7%) had a prior diagnosis of CAD. CLI was the primary diagnosis in 13 (59.1%) patients and 9 (40.9%) had claudication, 11 (50.0%) had unilateral symptoms. Tissue loss was present in 11 (50%) patients and the median ABI-High and ABI-Low of the target limb were .81 and .80, respectively. Median ankle pressure was 35 mmHg. The patients were significantly limited with the majority ( $73.4 \pm 20\%$ ) reporting severe difficulty ( $P < .01$  vs no difficulty) across WIQ assessment categories.

**Procedural and lesion data.** Access was obtained using contralateral approach in 15 (68%) cases and ipsilateral (antegrade access) in 7 (31.8%) cases. A 7 Fr sheath was used in 5 (22.7%) cases and a 6 Fr in 17 (77.2%). Procedural success was 100%. There

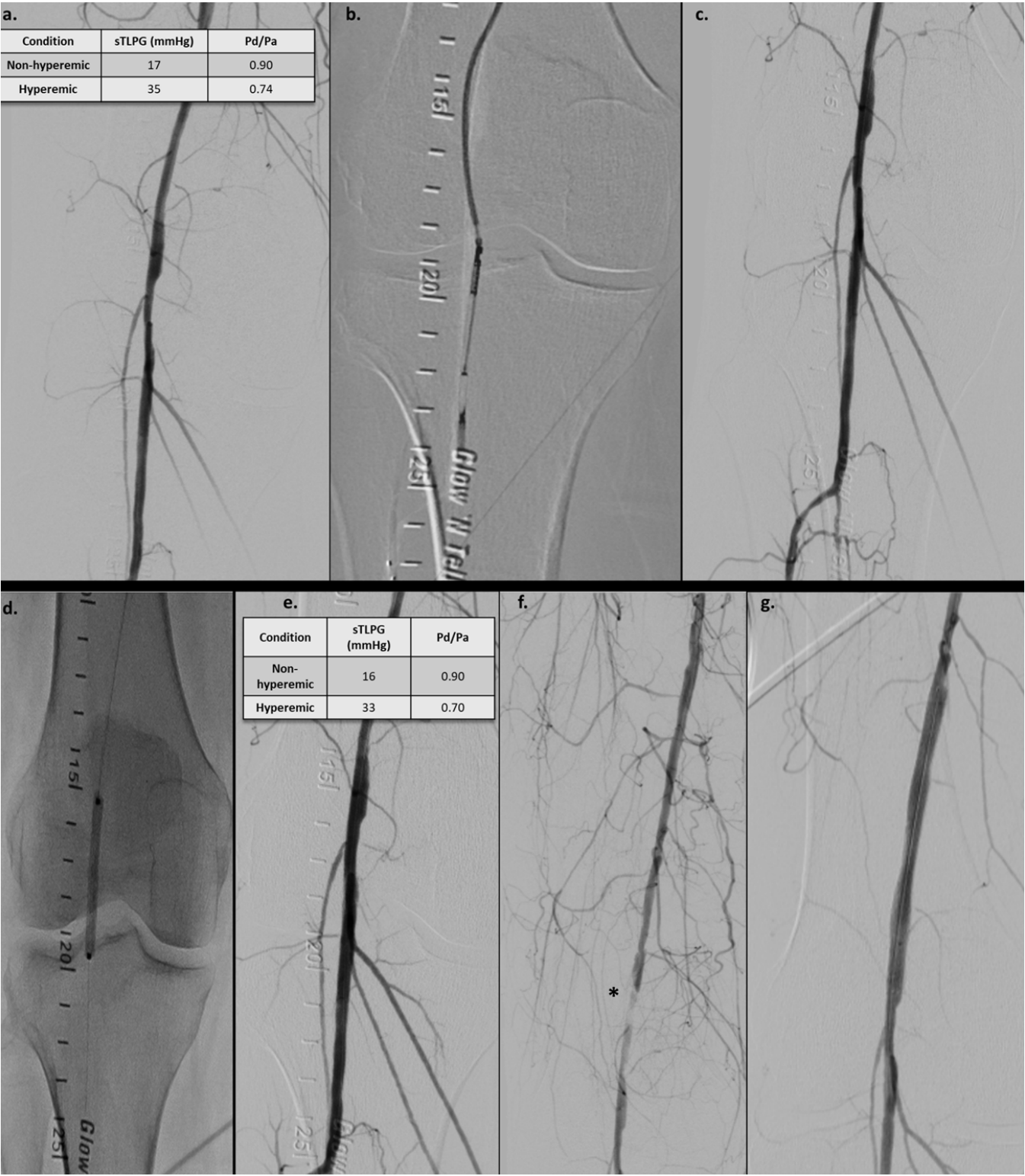
was one post-procedural hematoma successfully managed with manual compression, otherwise no study-related adverse events. There were no Navvus microcatheter-related complications. Total contrast volume used was  $131.0 \pm 57$  ml of iso-osmolar contrast

dye. Procedural time was  $103.6 \pm 29.6$  minutes. The lesion and procedural details are outlined in **Table 2**. Mean lesion length was  $78.9 \pm 56$  mm, pre-intervention stenosis was  $81.7\% \pm 14.2\%$ , and post-stenosis was  $11.4 \pm 7.7\%$  ( $P < .0001$ ). Atherectomy with



**Figure 2.** (a) Change in translesional systolic pressure gradients (sTPG) with directional atherectomy. A hyperemic response to adenosine is shown. Serial endovascular treatments result in reductions in the sTPGs. (b) Change in distal to proximal mean pressures (Pd/Pa) with directional atherectomy. A hyperemic response to the Pd/Pa is shown. Serial endovascular treatments increased the Pd/Pa.





**Figure 3.** Patient with diabetes and Rutherford grade 3 claudication presented with an eccentric popliteal lesion. The hyperemic sTPG was 35 mmHg with a Pd/Pa of .74 (**panel a**). Directional atherectomy was performed of the lesion (**panel b**). The post atherectomy angiogram is shown in **panel c**. A drug-coated balloon (5.0 mm diameter) was used next for percutaneous transluminal angioplasty (**panel d**). No angiographic dissection was noted but the post intervention hemodynamics were notable for a hyperemic sTPG of 33 mmHg and the Pd/Pa was 0.70. (**panel e**). The patient returned 2 days post-procedure with rest pain in the limb and repeat angiography demonstrated a vessel dissection (**panel f**). The dissection was treated with a 6.0 mm diameter self-expanding stent (**panel g**).

distal embolic protection was performed in 14 (63.6%) of the cases, balloon angioplasty alone in 6 cases (27.2%), and balloon angioplasty and stenting in 2 (9%) cases. Two sets of treatments were performed in 15 (68.2%) patients, and a single treatment in 7 (31.8%) patients.

**Hemodynamic data.** The sTPG data are shown in **Figure 1a**. The mean baseline non-hyperemic sTPG was  $32.0 \pm 18.6$  mmHg. A hyperemic response to adenosine for the sTPG was noted at baseline ( $+6.5$  mmHg,  $P < .001$ ) and post-treatment 1 ( $+7.1$  mmHg,  $P < .001$ ), but not after treatment 2 ( $+.2$ ,  $P = .775$ ). Mean sTPG decreased over the course of endovascular treatments as compared to each prior baseline ( $32.0 \pm 18.6$  to  $16.6 \pm 12.6$  to  $10.0 \pm 11.7$  mmHg respectively,  $P < .001$ ). The Pd/Pa data are shown in **Figure 1b**. A hyperemic response was demonstrated for the Pd/Pa, with the ratio decreasing at each time point with adenosine, baseline ( $-.083$ ,  $P < .001$ ), post-treatment 1 ( $-.061$ ,  $P < .001$ ), and post-treatment 2 ( $-.058$ ,  $P = .016$ ). Both the non-hyperemic and hyperemic Pd/Pa increased after endovascular treatments as compared with each prior baseline ( $P < .001$ ).

Given that most of the subjects underwent directional atherectomy, we specifically examined the sTPG and Pd/Pa ratios before and directly after this treatment approach. Mean baseline non-hyperemic and hyperemic TPGs were  $30.4 \pm 17.4$  mmHg and  $37.3 \pm 16.2$  mmHg, ( $P < .001$ ). Non-hyperemic and hyperemic sTPGs immediately post-atherectomy were significantly lower  $18.9 \pm 12.4$  mmHg and  $25.9 \pm 16.4$  mmHg ( $P < .001$ ,  $P = .011$  respectively). Pd/Pa significantly increased post-atherectomy with a baseline hyperemic value of  $.785 \pm .11$  and post-treatment hyperemic value of  $.861 \pm .02$  ( $P < .001$ ). The data demonstrating the change in sTPG and Pd/Pa with atherectomy are shown in **Figures 2a and 2b**.

There were no significant correlations found between the ABI-High, ABI-Low, Pd/Pa, and sTPG — regardless of hyperemia. The highest ankle pressure for the target limb inversely correlated with resting and hyperemic Pd/Pa ( $R = -.582$ ,  $P = .023$  and  $R = -.510$ ,  $P = .052$ , respectively). Resting and hyperemic sTPG did not correlate with the ankle pressure. There was a significant positive correlation between percent visual stenosis and both non-hyperemic and hyperemic sTPGs ( $R = .708$ ,  $P = .0002$  and  $R = .627$ ,  $P = .002$ , respectively). Similarly, there was significant negative correlation between visual stenosis severity and non-hyperemic and hyperemic Pd/Pa ( $R = -.604$ ,  $P = .003$  both measures).

**Follow-up and adverse events.** Follow-up data were available and extracted on 20 patients (2 were lost to follow-up) at  $38.4 \pm 9.4$  days following intervention. One patient was admitted for acute Charcot's neuropathy, 2 patients underwent planned amputations, one patient was hospitalized for worsening foot infection, and one patient was admitted for a non-ST segment elevation myocardial infarction. In addition, one patient had

an unplanned urgent target limb revascularization following initial therapy. This individual's case is outlined in **Figure 3**. The patient underwent directional atherectomy with 3 offset cuts followed by a drug-coated balloon angioplasty using a 5.0 mm diameter balloon of the P2 segment of the right popliteal artery (**Figures 3a-3e**). The pre-intervention stenosis was 70% and the final residual stenosis was 10%. The patient's baseline non-hyperemic and hyperemic sTPGs were 17 and 35 mmHg, respectively, and the Pd/Pa were .90 and .74, respectively. The final non-hyperemic and hyperemic sTPGs were 16 and 33 mmHg, respectively, and Pd/Pa were .90 and .70, respectively. Two days following the procedure, the patient presented to the hospital with rest pain in the leg. Repeat angiography demonstrated a 99% stenosis of the previously treated popliteal artery with evidence of dissection (**Figure 3f**). The occluded segment was crossed with an .014" Workhorse wire, and a 6.0 x 80 mm Protégé (Medtronic) self-expanding stent was placed, restoring flow with no subsequent subacute clinical events (**Figure 3g**).

## Discussion

In the present pilot study: we (1) confirmed prior published findings of a hyperemic response to adenosine in the lower extremity circulation, (2) demonstrated that the Navvus microcatheter and RXi system can safely measure acute changes in translesional peripheral hemodynamics in response to endovascular therapy, and (3) provided a case example of how hemodynamic measurements may be a helpful adjunct during endovascular therapy.

### Hyperemia and lower extremity hemodynamic measurements.

The literature is replete with non-invasive methods to assess hemodynamic significance of PAD, including the ABI at rest and at exercise, toe brachial indices, segmental pressure testing, and Doppler peak systolic velocities. Non-invasive modalities are rarely used during interventional procedures to interrogate lesion severity. Advances in endovascular techniques and equipment have outpaced the ability to perform real-time assessment of hemodynamics during invasive procedures. The performance of invasive lesion evaluations may have several benefits, including the potential for more complete revascularization, the ability to guide operators in decisions regarding length of vessel to treat, and assessment of procedural success.<sup>3</sup>

Evaluation of lesion significance in the limbs poses multiple challenges. PAD is often multi-level and involves long segments of disease thus making determinations of a specific lesion's hemodynamic significance challenging. Furthermore, given the large flow reserve of the vessels feeding the skeletal muscle in the legs, resting gradients on the catheterization table may not correlate with exercise induced changes in arterial hemodynamics. Of note, these same limitations also apply to resting non-invasive tests including the resting ABI and Doppler velocity measure-

ments. Experimental studies have demonstrated that resting blood flow to the lower extremity can be maintained even in the face of severe stenosis by way of a robust collateral circulation. A diameter stenosis severity of more than 75% is required in a proximal limb vessel to result in a significant pressure drop. During exercise, this decrement may become magnified.<sup>4</sup> Using lower limb exercise on the catheterization table poses obvious logistical challenges due to patient comfort and access site safety. Given these limitations, vasodilation by pharmacologic stimulus has been explored as an alternative option to exercise. Nitroglycerin (through endothelium independent vasodilation), adenosine, and papaverine have all been used clinically in the lower extremities. Adenosine, in particular, plays an important role in skeletal muscle vasodilation by means of its action on the adenosine A1 and A2a receptors located on the endothelium of the vascular smooth muscle.<sup>5,6</sup> Furthermore, adenosine induces vasodilation in the lower extremities by activating ATP-sensitive potassium channels and both nitric oxide (NO) dependent and independent pathways.<sup>7,8</sup>

Resting hemodynamic gradients in the peripheral circulation have traditionally been measured using small diameter (4 Fr or smaller) end hole catheters using a pullback technique.<sup>9,10</sup> The cutoff for significance of such a translesional gradient has varied in the literature and has ranged from  $\geq 10$  mmHg mean pressure to  $\geq 20$  mmHg peak systolic pressure.<sup>11,12</sup> The most obvious limitation of this technique revolves around the fact that the very presence of a catheter across a stenosis impairs flow and therefore may artificially elevate the gradient. A pressure wire (PW) offers a low-profile accurate way to measure gradients, however it requires repeat measurements on a single wire. The Navvus catheter allows for measurements to be taken over any workhorse wire — including a filter wire.

Using a PW, Banerjee et al examined the impact of three different pharmacological vasodilator strategies (calf occlusion-release, intra-arterial nitroglycerin, and intra-arterial adenosine) on the TLPs in patients with lower extremity PAD.<sup>2</sup> The investigators correlated the invasive hemodynamic data with changes in clinical variables (walking impairment and the ABI).<sup>35</sup> Using an exercise ABI  $\leq .70$  as the gold standard for limb ischemia, the authors examined the receiver operating characteristics for the various hyperemic stimuli. The results demonstrated that a sTPG  $\geq 11$  mmHg following 100  $\mu$ g adenosine administration was best at identifying patients with symptomatic PAD. The use of 100–200  $\mu$ g of intra-arterial adenosine to demonstrate augmentation of resting gradients has also been shown by other authors and confirmed in the present study.<sup>13</sup>

Papaverine, through its smooth muscle relaxant effects, is also a potent peripheral vasodilator — and is the most thoroughly studied agent in the lower extremities. The dose of papaverine in the literature has varied, however Miki et al demonstrated that blood flow in the SFA increased in a dose-dependent manner with 30 mg noted to produce maximal vasodilation.<sup>14</sup> This drug

has a long history of use by vascular surgeons to vasodilate arteries prior to and following open surgical procedures.<sup>15–17</sup> With respect to endovascular use of papaverine, a handful of studies have incorporated papaverine-induced vasodilation for lesion interrogation.<sup>18,19</sup> In a small proof of concept study, Hioki et al used papaverine in patients with claudication and aorto-iliac lesions to understand the relationship between post-exercise ABIs, peak sTPGs, and peripheral Pd/Pa.<sup>18</sup> The authors noted a significant correlation between post-exercise ABI and Pd/Pa at hyperemia — and a more modest relationship between ABI values and peak sTPGs. With respect to infrapopliteal disease, one of the most thorough studies to date was performed by Ruzsa et al with 39 patients.<sup>20</sup> This study examined translesional hemodynamics in tibial vessels before and after angioplasty — with and without hyperemia using papaverine. The authors correlated the hemodynamic data with angiographic and clinical data and with changes in non-invasive measures of perfusion. The key findings included demonstration of significant increases in both the resting and hyperemic Pd/Pa following intervention. Both of these parameters prior to angioplasty (but not after) also correlated with percent angiographic stenosis and transcutaneous oximetry values — suggesting a link between anatomic stenosis severity and tissue level perfusion.

The correlations in the aforementioned studies between resting non-invasive measures of PAD severity and translesional hemodynamics have been modest, while post-exercise measures have shown a greater degree of correlation with invasive data. In the present study, the ABI values (either ABI-high or low) did not correlate with resting or hyperemic sTPGs or Pd/Pa values. The limitations of the resting ABI include lack of sensitivity for isolated tibial disease, alterations in calcified vessels, and indifference to flow reserve.<sup>21,22</sup> Changes in the ABI after endovascular therapy may not be reliable or may be delayed by days to weeks.<sup>22</sup> Acute measurement of blood pressure changes in the legs does not represent a reliable tool in the catheterization laboratory. In this context, use of invasive catheter-based hemodynamics may be more helpful.

**Challenges with use of invasive hemodynamics during endovascular therapy.** The multi-level nature of PAD, the vessel lengths, and volume of muscle fed by this circulation pose unique challenges for invasive hemodynamics. In the coronary circulation, both upstream and downstream lesions may impact the FFR across a given stenosis. Translating this experience to the limb circulation begs the question of the role of infrapopliteal disease and distal microvascular disease in influencing the hemodynamics across femoro-popliteal lesions and conversely, iliac lesions confounding downstream stenosis interrogation. Furthermore, if significant distal embolization occurs during the endovascular procedure, the microvascular resistance may increase. This increase could in theory impact the ability of the distal bed to vasodilate and therefore impact hemodynamic measurements — including the



Pd/Pa. Localizing disease in the coronary bed is often done using pullbacks of the PW and recording hyperemic Pd/Pa or of newer non-hyperemic ratios such as the iFR. The latter technique has not yet been validated in the non-coronary circulation. During endovascular therapy, pullbacks of the PW require loss of wire position, and use of a PW in conjunction with a filter wire may be technically challenging. A potential means to overcome this limitation is the use of rapid-exchange microcatheters such as the Navvus device, as was done in this study. The Navvus microcatheter allowed multiple serial measurements without loss of wire position. This ability was particularly helpful as 14 of the cases in this study involved directional atherectomy and a filter wire. Of note, this study did demonstrate for the first time in the literature the acute hemodynamic response of directional atherectomy on sTPG. The luminal gain following plaque removal has been previously published and therefore, as may be predicted, this therapy does decrease pressure gradients. Regardless of the type of endovascular therapy, this pilot study provides a case example which highlights that a persistent gradient — despite an adequate angiographic result — may require further investigation. In the case outlined in **Figure 3**, failure to lower the sTPG and raise the Pd/Pa despite no apparent angiographic abnormality was a potential sign of flow limitation, and interrogation with intravascular ultrasound may have been diagnostic. The present pilot study protocol did not involve measurement of pullback hemodynamics. However, such an approach may have also helped localize the level of the complication. In this regard, a baseline and post-final intervention assessment with the Navvus microcatheter for PAD interventions with a pullback, and adjunctive IVUS as needed, might be a potential protocol of interest.

**Study limitations.** This was a small pilot study to demonstrate the feasibility of use of the Navvus microcatheter in the lower extremity circulation. The sample size and lack of detailed follow-up limit the conclusions. While the study noted acute changes in Pd/Pa and sTPG, the precise cutoffs for “significance” based on prospective outcome studies have yet to be defined.

## Conclusions

The Navvus microcatheter provided serial measurements during endovascular therapy of PAD with and without hyperemia. Incorporation of invasive hemodynamics may have a role in determining the acute success of interventions. Correlation of these measurements with prospective outcomes requires further study.

## References

1. Allison MA, Aboyans V, Granston T, et al. The relevance of different methods of calculating the ankle-brachial index: the multi-ethnic study of atherosclerosis. *Am J Epidemiol*. 2010;171(3):368-376. doi:10.1093/aje/kwp403

2. Banerjee S, Badhey N, Lichtenwalter C, Varghese C, Brilakis ES. Relationship of walking impairment and ankle-brachial index assessments with peripheral arterial translesional pressure gradients. *J Invasive Cardiol*. 2011;23(9):352-356.
3. Hong SJ, Ko YG, Shin DH, et al. Outcomes of spot stenting versus long stenting after intentional subintimal approach for long chronic total occlusions of the femoropopliteal artery. *JACC Cardiovasc Interv*. 2015;8(3):472-480. doi:10.1016/j.jcin.2014.09.023
4. Bragadeesh T, Sari I, Pascotto M, Micari A, Kaul S, Lindner JR. Detection of peripheral vascular stenosis by assessing skeletal muscle flow reserve. *J Am Coll Cardiol*. 2005;45(5):780-785. doi:10.1016/j.jacc.2004.11.050
5. Bryan PT, Marshall JM. Adenosine receptor subtypes and vasodilatation in rat skeletal muscle during systemic hypoxia: a role for A1 receptors. *J Physiol*. 1999;514(Pt 1):151-162.
6. Collis MG. The vasodilator role of adenosine. *Pharmacol Ther*. 1989;41(1-2):143-162.
7. Baker CH, Sutton ET. Antagonism of acetylcholine and adenosine rat cremaster arteriolar vasodilation by combination of NO antagonists. *Int J Microcirc Clin Exp*. 1993;12(3):275-286.
8. Kleppisch T, Nelson MT. Adenosine activates ATP-sensitive potassium channels in arterial myocytes via A2 receptors and cAMP-dependent protein kinase. *Proc Natl Acad Sci USA*. 1995;92(26):12441-12445. doi:10.1073/pnas.92.26.12441
9. Tetteroo E, van der Graaf Y, Bosch JL, et al. Randomised comparison of primary stent placement versus primary angioplasty followed by selective stent placement in patients with iliac-artery occlusive disease. Dutch Iliac Stent Trial Study Group. *Lancet*. 1998;351(9110):1153-1159.
10. Tetteroo E, Haaring C, van der Graaf Y, van Schaik JP, van Engelen AD, Mali WP. Intraarterial pressure gradients after randomized angioplasty or stenting of iliac artery lesions. Dutch Iliac Stent Trial Study Group. *Cardiovasc Intervent Radiol*. 1996;19(6):411-417.
11. Garcia LA, Carrozza JP Jr. Physiologic evaluation of translesion pressure gradients in peripheral arteries: comparison of pressure wire and catheter-derived measurements. *J Interv Cardiol*. 2007;20(1):63-65. doi: 10.1111/j.1540-8183.2006.00230.x
12. Abildgaard A, Kløw NE. A pressure-recording guidewire for measuring arterial transstenotic gradients: in vivo validation. *Acad Radiol*. 1995;2(1):53-60.
13. Cavendish JJ, Carter LI, Tsimikas S. Recent advances in hemodynamics: noncoronary applications of a pressure sensor angioplasty guidewire. *Catheter Cardiovasc Interv*. 2008;71(6):748-758. doi: 10.1002/ccd.21479
14. Miki K, Fujii K, Fukunaga M, et al. Assessment of lower limb flow and adequate intra-arterial papaverine doses to achieve maximal hyperemia in elder subjects. *Cardiovasc Interv Ther*. 2015;30(3):227-233. doi: 10.1007/s12928-015-0296-2
15. Archie JP Jr. Some determinants of papaverine-induced femoral artery pressure gradients. *J Surg Res*. 1990;48(3):211-216.
16. Archie JP Jr, Feldtman RW. Intraoperative assessment of the hemodynamic significance of iliac and profunda femoris artery stenosis. *Surgery*. 1981;90(5):876-880.
17. White LRH. *Vascular Surgery: Basic Science and Clinical Correlations*. Blackwell Futura; 2005. p. 652.
18. Hioki H, Miyashita Y, Miura T, et al. Diagnostic value of peripheral fractional flow reserve in isolated iliac artery stenosis: a comparison with the post-exercise ankle-brachial index. *J Endovasc Ther*. 2014;21(5):625-632. doi: 10.1583/14-4726R.1
19. Kobayashi N, Hirano K, Nakano M, et al. Measuring procedure and maximal hyperemia in the assessment of fractional flow reserve for superficial femoral artery disease. *J Atheroscler Thromb*. 2016;23(1):56-66. doi: 10.5551/jat.32385
20. Ruzsa Z, Rona S, Toth GG, et al. Fractional flow reserve in below the knee arteries with critical limb ischemia and validation against gold-standard morphologic, functional measures and long-term clinical outcomes. *Cardiovasc Revasc Med*. 2017;18(8):580-586. doi: 10.1016/j.carrev.2017.05.016

21. Sukul D, Grey SF, Henke PK, Gurm HS, Grossman PM. Heterogeneity of ankle-brachial indices in patients undergoing revascularization for critical limb ischemia. *JACC Cardiovasc Interv.* 2017;10(22):2307-2316. doi: 10.1016/j.jcin.2017.08.023
22. Duerschmied D, Maletzki P, Freund G, Olschewski M, Bode C, Hehrlein C. Success of arterial revascularization determined by contrast ultrasound muscle perfusion imaging. *J Vasc Surg.* 2010;52(6):1531-1536. doi: 10.1016/j.jvs.2010.06.090

From the Department of Medicine, Division of Cardiology, UT Health San Antonio, San Antonio, Texas.

Disclosure: The authors have completed and returned the ICMJE Form for Disclosure of Potential Conflicts of Interest. This study was funded by an investigator initiated grant from ACIST Medical Systems to Dr. Anand Prasad. The remaining authors report no relevant disclosures.

The authors report that patient consent was provided for publication of the images used herein.

Manuscript accepted May 1, 2023.

Address for correspondence: Anand Prasad, MD, FACC, FSCAI, RPVI, Department of Medicine, Division of Cardiology, UT Health San Antonio, 7703 Floyd Curl Drive, San Antonio, TX 78229-3900. Email: prasada@uthscsa.edu