

Negative Pressure Wound Therapy (NPWT) Hands-On Workshop: Innovations, Clinical Applications, and Transitioning Care

Supported by an educational grant from Solventum, Medical Surgical Business

Faculty

- **Karen Bauer, DNP, APRN-CNP, CWS, FAAWC**
President, Society for Vascular Nursing
- **Britney Butt, MCISc(WH), BScN, RN, NSWOC, WOCC(C)**
Keck Medical Center of USC, Los Angeles, CA
- **Kara Couch, MS, CRNP, CWCN-AP, FAAWC**
Director, Wound Care Services, George Washington University Hospital
Associate Research Professor of Surgery, School of Medicine and Health Sciences, George Washington University; Washington, D.C.
- **Michael N. Desvigne, MD, FACS, CWS, FACCWS, MAPWCS**
Plastic & Reconstructive Surgery; Wound Care & Hyperbaric Medicine
Abrazo Arrowhead Hospital & Wound Clinic; Glendale, AZ
- **Napolitano, Jr., DPM, CWSP, FACFAS**
Director, Wound Care and Healing – OrthoNeuro, Columbus, OH
Adjunct Clinical Assistant Professor, Department of Specialty Medicine – Ohio University Heritage College of Osteopathic Medicine, Athens, OH

Faculty Disclosures

- **Karen Bauer, DNP, APRN-CNP, CWS, FAAWC**
Consultant, Speakers Bureau: Solventum, Medical Surgical Business; Urgo Medical
- **Britney Butt, MCISc(WH), BScN, RN, NSWOC, WOCC(C)**
Consultant: Solventum, Medical Surgical Business
- **Kara Couch, MS, CRNP, CWCN-AP, FAAWC**
Consultant, Speakers Bureau: Integra LifeSciences; Organogenesis Inc.; Reaplix;
Solventum, Medical Surgical Business; Urgo Medical North America
- **Michael N. Desvigne, MD, FACS, CWS, FACCWS, MAPWCS**
Advisory Board, Consultant, Speakers Bureau: Sanara Med Tech; Solventum, Medical
Surgical Business; Consultant, Speakers Bureau: Aroa; Integra LifeSciences;
MolecuLight Inc.; MTF Biologics; Smith & Nephew; Urgo Medical
- **Ralph Napolitano, Jr., DPM, CWSP, FACFAS**
Consultant: Engineered Tissue Solutions; Solventum, Medical Surgical Business;
Speakers Bureau: Ortho Dermatologics

Disclosures

- The faculty have been informed of their responsibility to disclose to the audience if they will be discussing off-label or investigational use(s) of drugs, products, and/or devices (any use not approved by the U.S. Food and Drug Administration)
 - Applicable CME staff have no relationships to disclose relating to the subject matter of this activity
 - This activity has been independently reviewed for balance

This CME activity includes brand names for participant clarity purposes only. No product promotion or recommendation should be inferred.

Learning Objectives

- Review the evolution of negative pressure wound therapy (NPWT) and the latest innovations
- Differentiate between various NPWT technologies and apply an algorithmic approach to selecting the appropriate technology based on wound characteristics, patient needs, and care setting transitions
- Explore the science and clinical application of novel peel and place dressings, determining which wound types are most appropriate for this technology
- Apply new therapy application tips toward the use of NPWT with instillation, incision management, and hybrid drapes
- Describe the transition of care for NPWT from the acute to the post-acute setting, emphasizing how portable technology can facilitate this
- Examine case-based scenarios highlighting the components of the NPWT toolkit, and demonstrate the step-down therapies involved in progressing toward wound closure

Evolution and Latest Innovations

Kara Couch, MS, CRNP, CWCN-AP, FAAWC

Director, Wound Care Services

Associate Research Professor of Surgery

George Washington University Hospital

Washington, DC

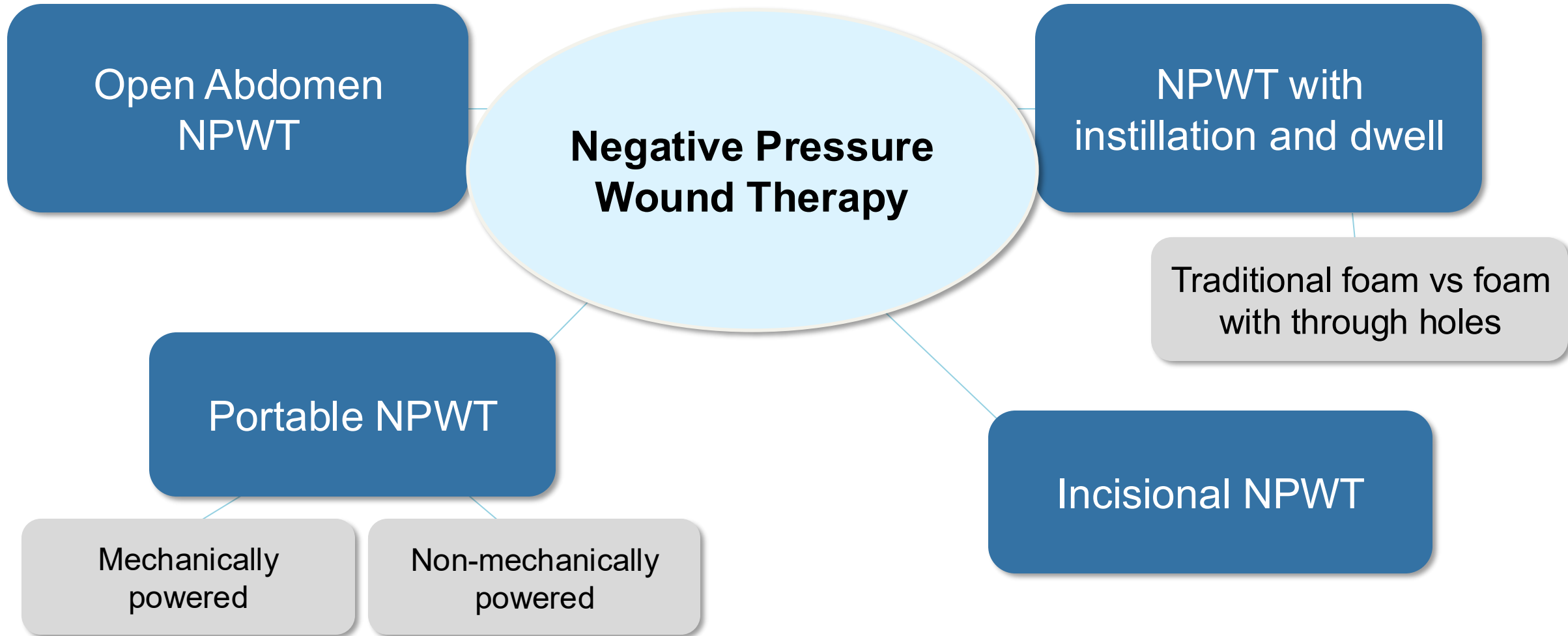
Alphabet Soup of NPWT

NPWT is a broad term that can include a wide variety of different settings, dressing options, and treatment uses.

- Negative pressure wound therapy (NPWT)
- NPWT with instillation and dwell (NPWTi-d)
- NPWT with irrigation (NPWT-I)
- Incisional NPWT (iNPWT) vs closed incisional NPWT (ciNPWT)
- Traditional NPWT (tNPWT) or single use NPWT (sNPWT)
- Open abdomen NPWT (OA-NPWT)
- Extended wear NPWT/novel 7-day dressing system (ewNPWT)

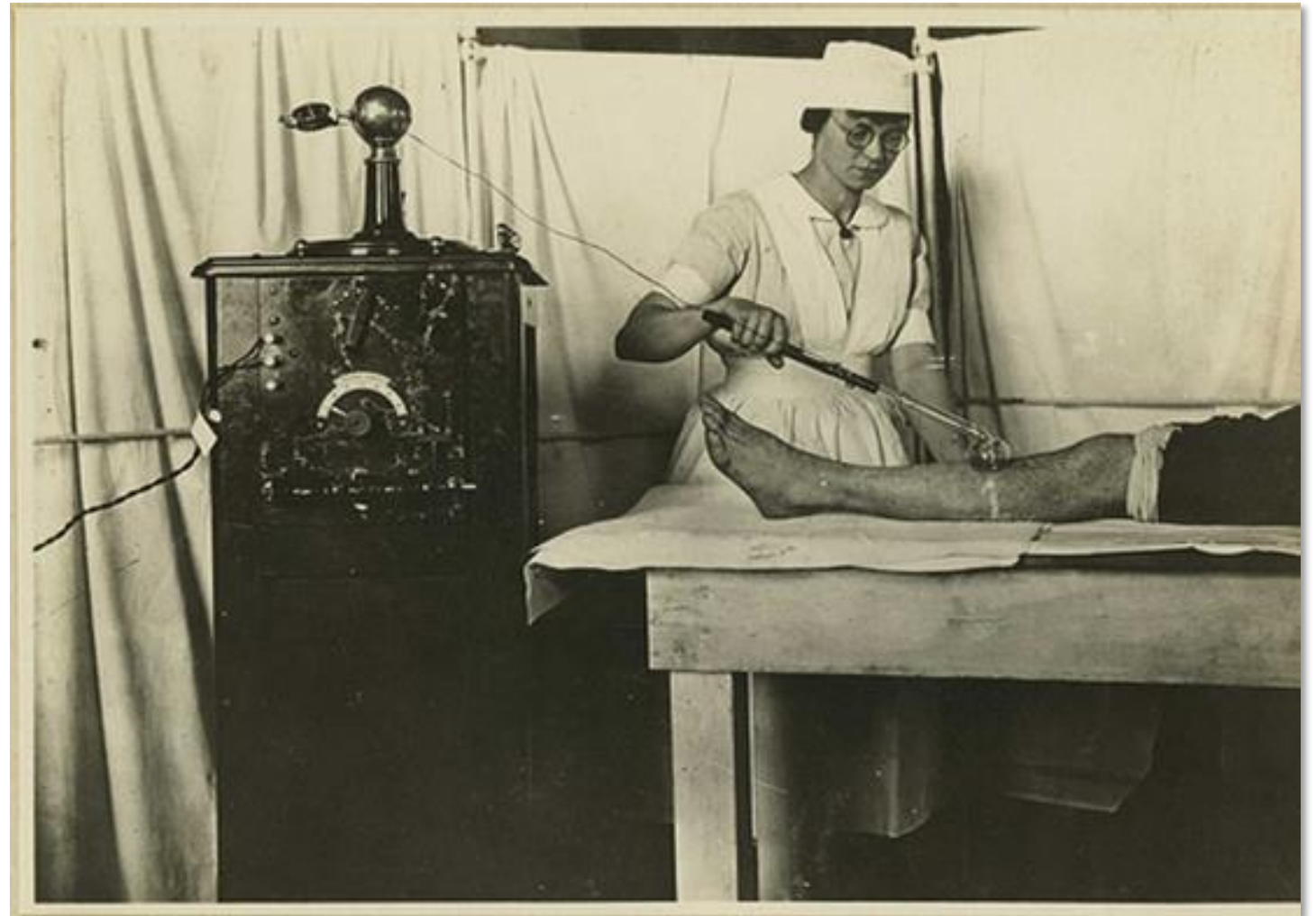Does literature regarding NPWT carry over to all of the different types of NPWT?

Wound Management with NPWT



History of NPWT

- The idea of NPWT is not new in wound care
- There are descriptions of NPWT in the Roman era
- NPWT officially came to medical professionals in the mid-1990s
- There are now a variety of types and options for NPWT



Roman Era

- Medical personnel applied direct suction with their mouths to deep wounds from battle or to poisonous wounds
- Cupping, using glass jars, was used to “draw out” fluid

18th Century

- French surgeon Dr. Dominique Anel created a “wound sucker,” which was a suction syringe with a triangular tip to replace human “lip service”

20th Century

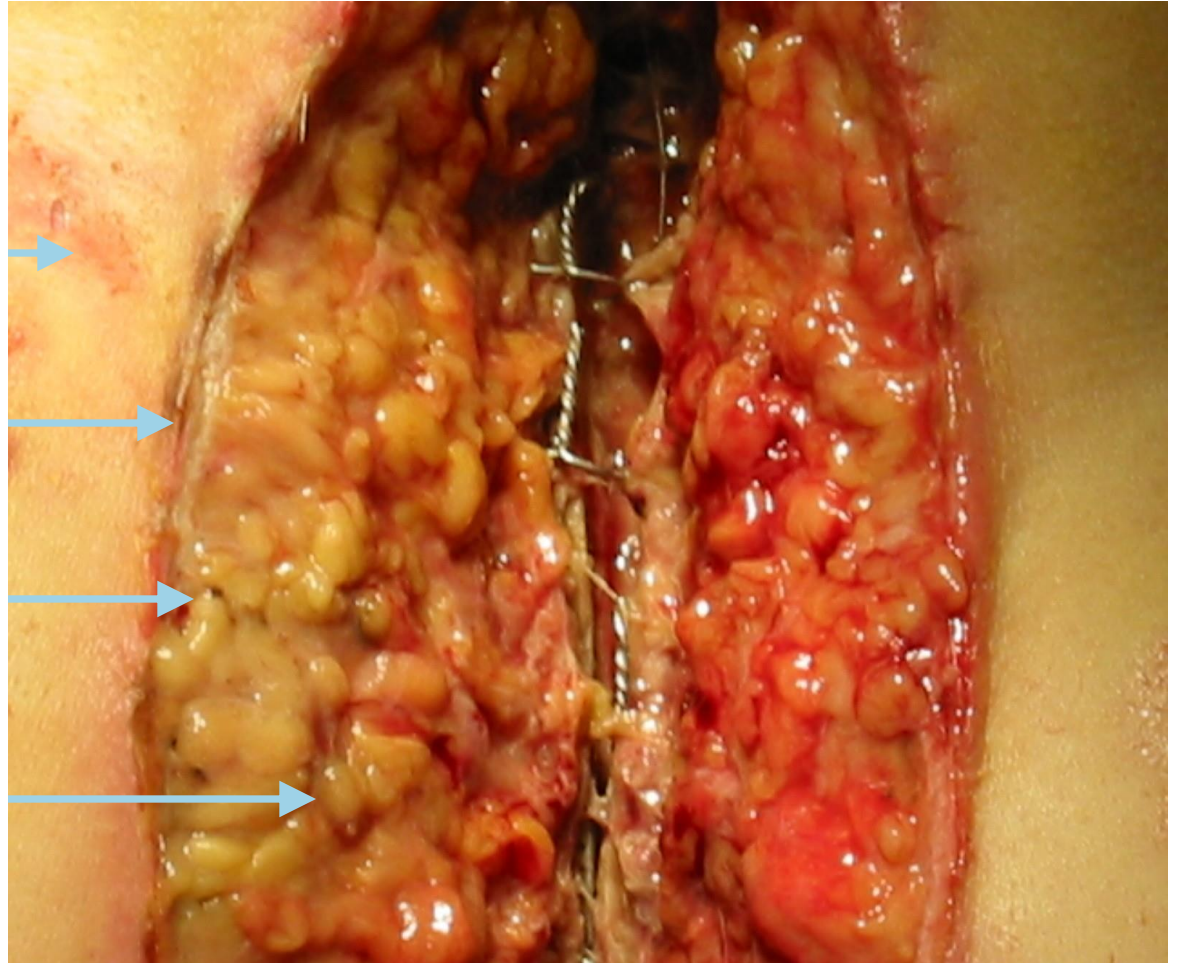
- Soviet surgeon Dr. Nail Bagautdinov began using a negative pressure unit with foam dressings in 1985 to treat infected wounds
- Modern NPWT systems came into being in the 1990s with the use of polyurethane foam and a mechanical vacuum pioneered by Drs. Louis Argenta and Michael Morykwas of Wake Forest University School of Medicine

Standing Out Through Innovation



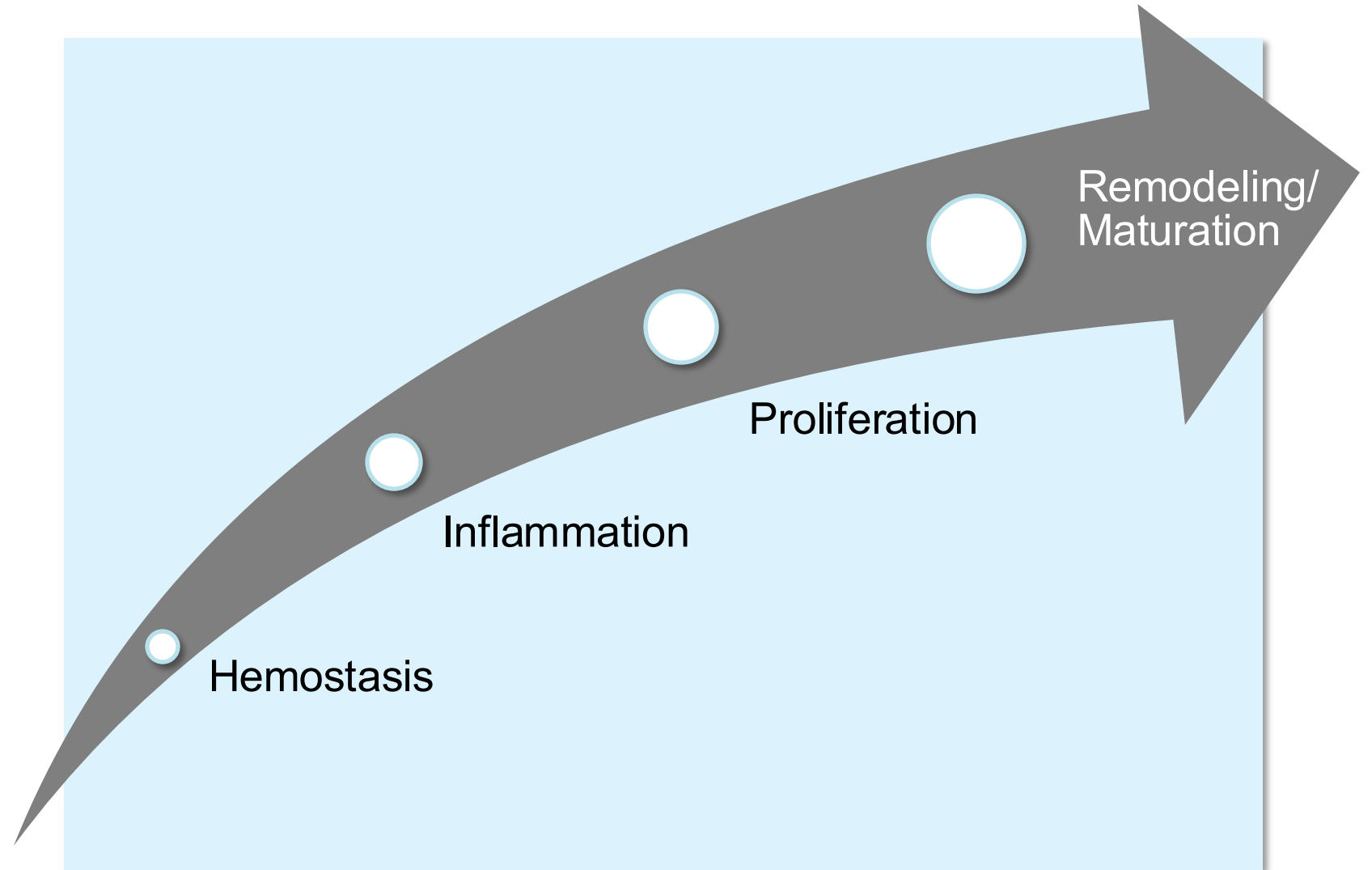
Common Components of Compromised Wound Healing

- Exudate
- Matrix metalloproteinases (MMPs)
- Pathogens
- Edema



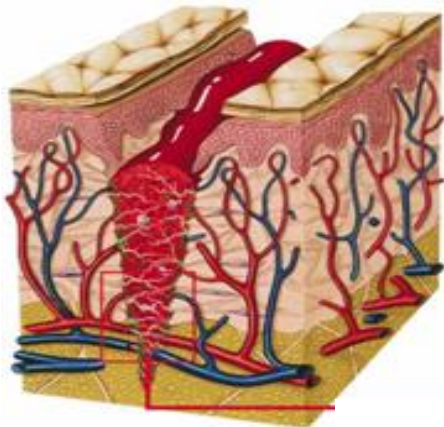Compromised Wound Healing = “Stuck” Between Phases

- Acute Wounds
 - Compromised systems
 - Environmental issues
- Chronic Wounds
 - High level of proteases
 - Degrading matrix

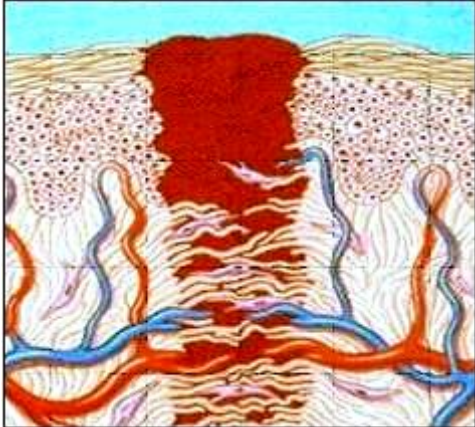


Chronic Wounds Are “Stuck” in the Inflammatory Phase of Wound Healing

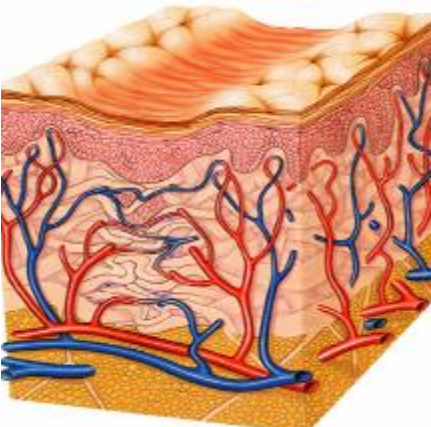
Acute wound



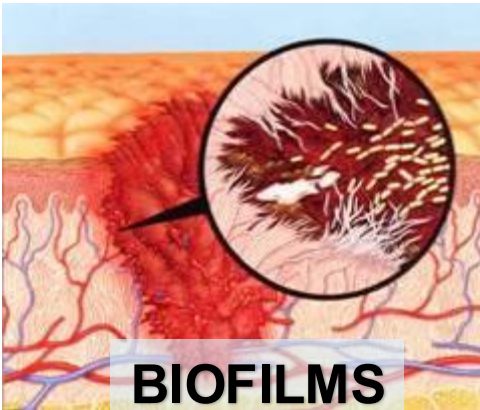
Sequential phases of healing



Healed wound

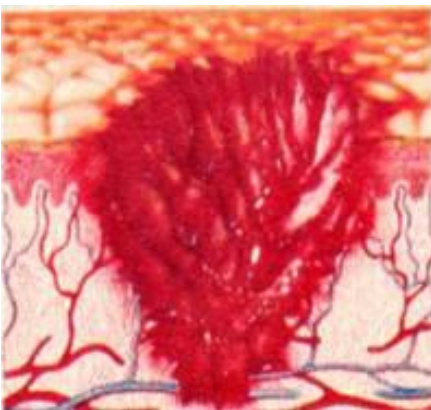


Chronic inflammation

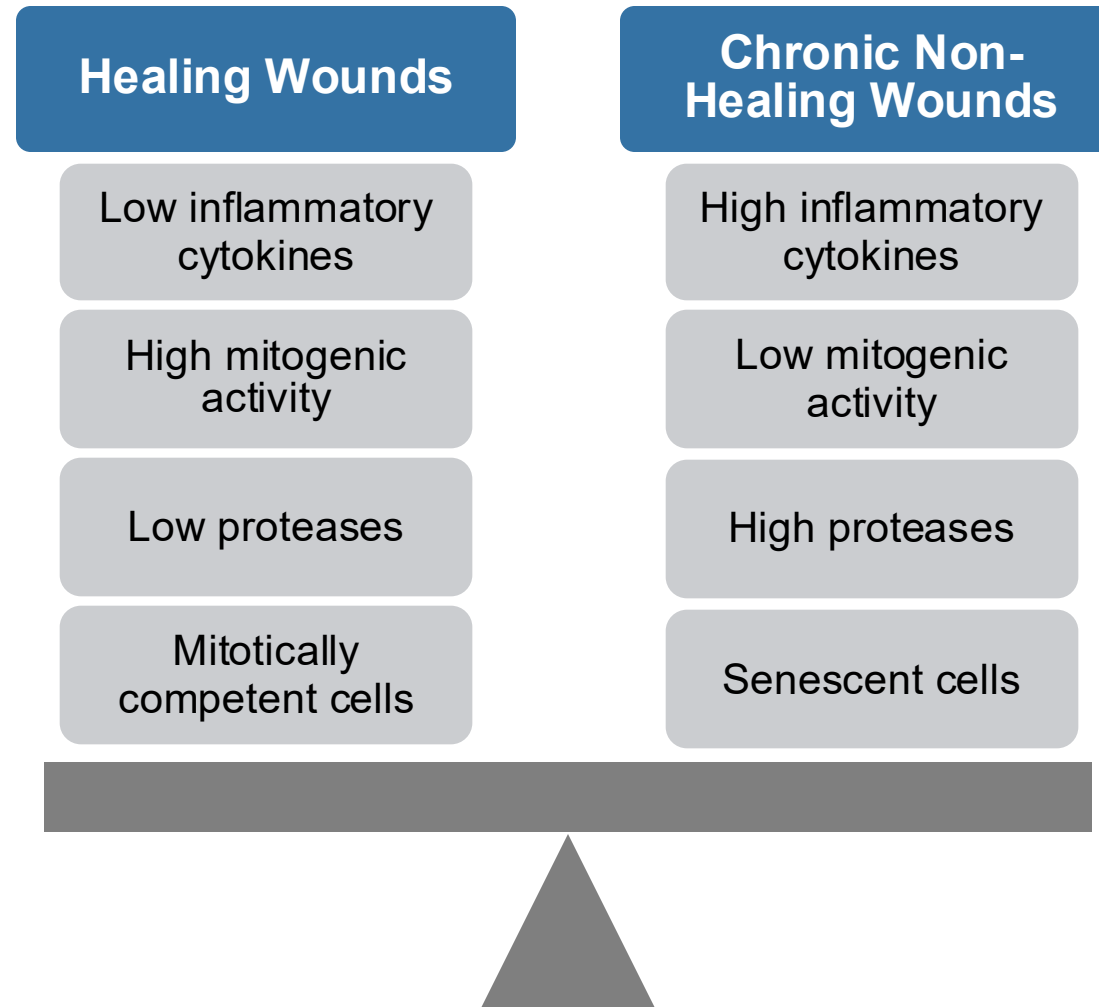


Sequential phases of healing interrupted

Chronic wound



Differences Between Healing and Non-Healing Chronic Wounds

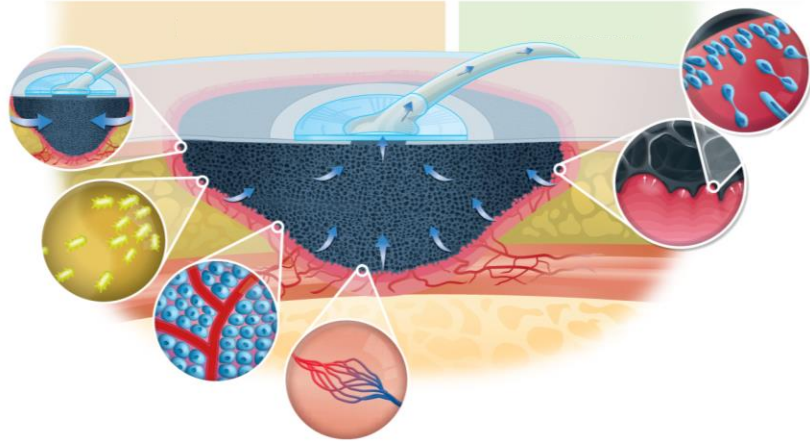


It Starts with the Wound Healing Basics

Traditional NPWT Science

Macrostrain

- Draws wound edges together
- Removes infectious material
- Reduces edema
- Promotes perfusion



Microstrain

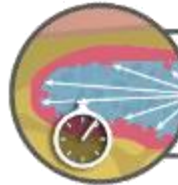- In vitro/in vivo studies show that foam contact with tissue under negative pressure creates tissue micro-deformation that leads to cell stretch
- In vitro studies show that cell stretch under negative pressure stimulates cellular activity that results in granulation tissue formation

NPWT with Instillation and Dwell (NPWT or NPWTi-d)

Instillation & Dwell Phase

Solution Instillation

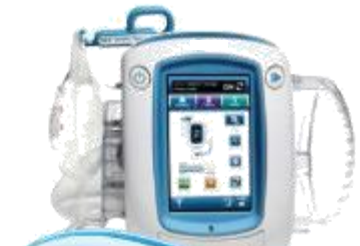
Cleanses wound with cyclic delivery, dwell, & removal of topical wound solutions



Provides thorough wound coverage with topical solution during selected dwell time¹

Solution Dwell

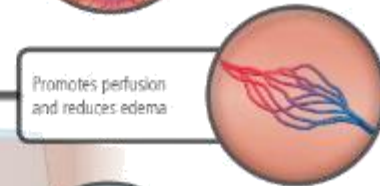
Dilutes and solubilizes² infectious material and wound debris



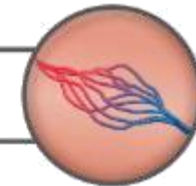
NPWT Phase

Macrostrain

Draws wound edges together



Promotes perfusion and reduces edema



Removes exudate and infectious material

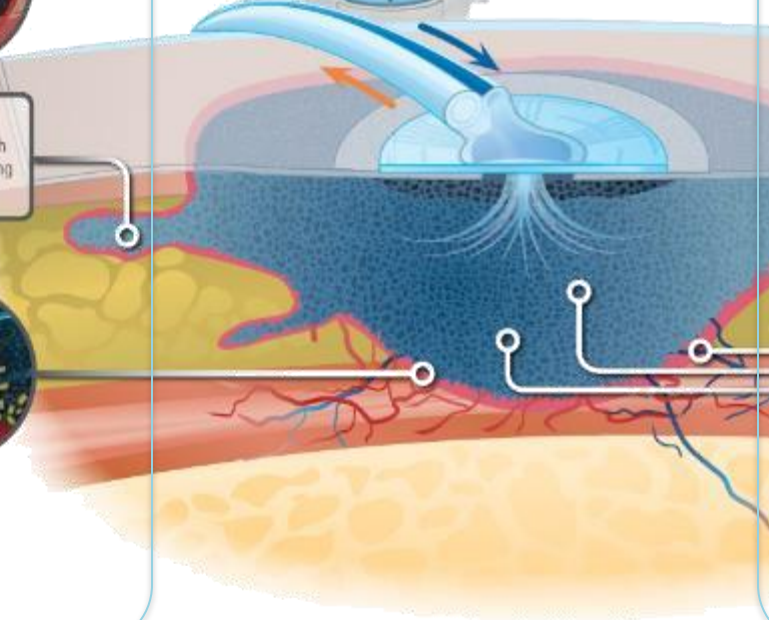


Microstrain

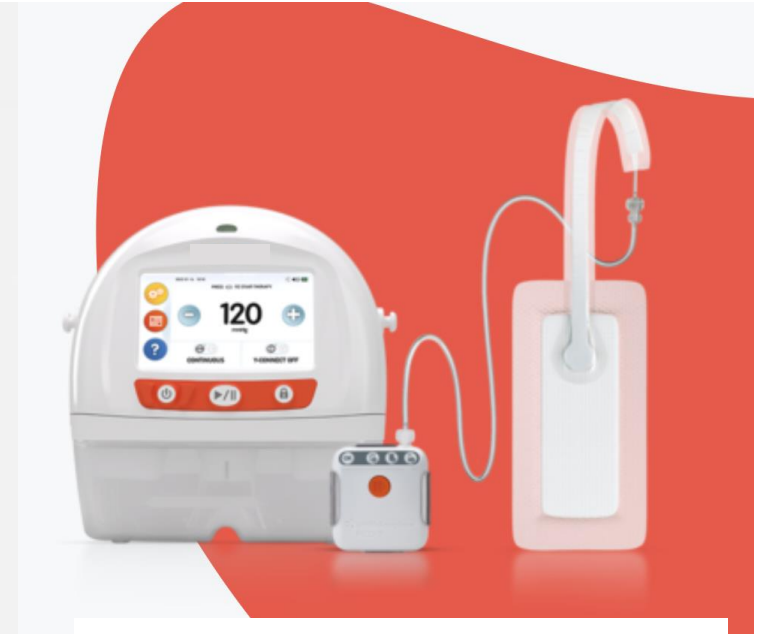In vitro/in vivo studies show that foam contact with tissue creates micro-deformation that leads to cell stretch^{2,3}



Cell stretch under negative pressure stimulates cellular activity that results in granulation tissue formation⁴



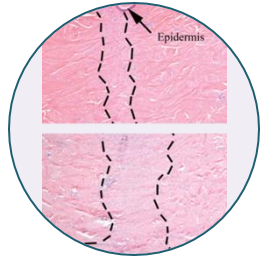
Examples



Incisional Negative Pressure Therapy (iNPT)

Potential Benefits of Expanded Incision And Soft Tissue Coverage

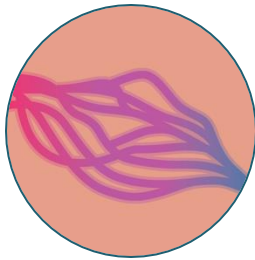
Studies of NPT have observed:



Treated with closed-incision negative pressure therapy (ciNPT)

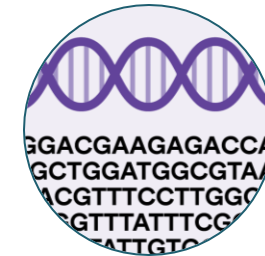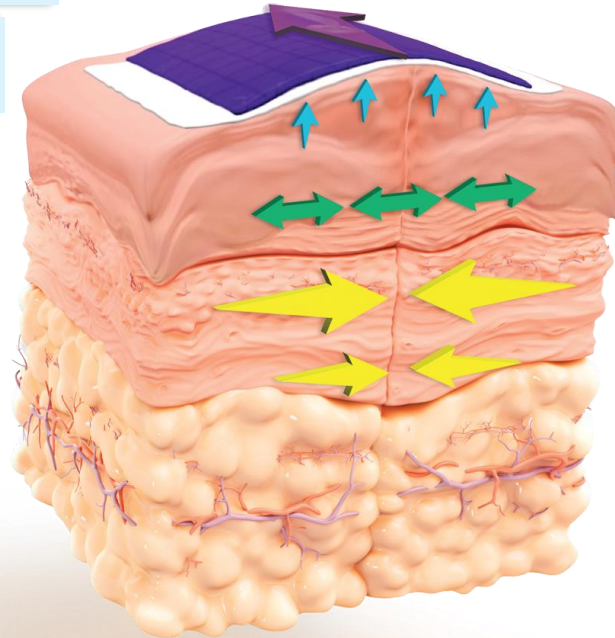
Standard of care

Narrower scar formation*

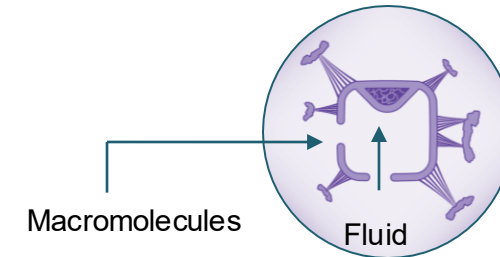


†† Augmented perfusion

- Lymphatic flow
- Tissue decompression
- Direction of fluid
- Appositional force



Improved quality of healed incisions; enhanced gene-expression properties†



Opening of lymphatics to allow fluid clearance††

Disposable NPWT



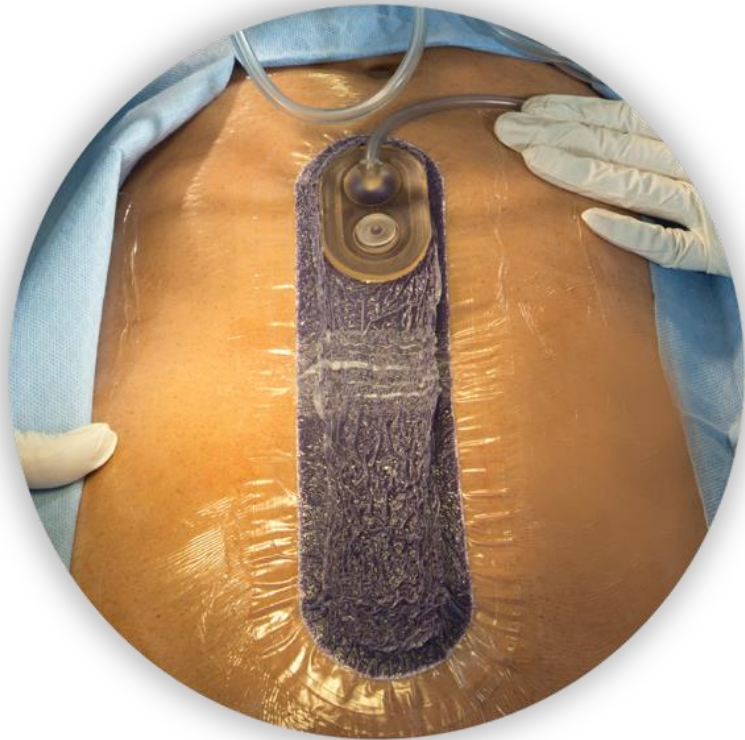- Incisional NPWT
- Many shapes, sizes
- Canister vs no canister system



- Mechanically-powered NPWT
- Different sizes available



- Battery-powered NPWT
- Various styles, sizes



iNPT therapy

- Reduces edema
- Acts as a barrier to external contamination
- Delivers continuous -125 mm Hg up to 7 days
- Helps to hold incision edges together
- Decreases lateral tension of sutured/stapled incisions
- Removes fluids and infectious materials*

The reticulated open cell foam (ROCF) dressing collapses onto its geometric center, under -125 mm Hg, to bring incision edges together, reduce lateral tension, and allow for improved fluid management.[†]

*In a canister. †In computer and bench models.

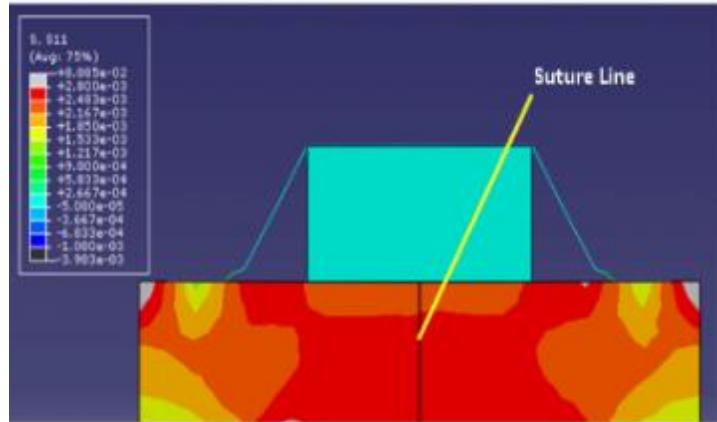
iNPT Helps to Avoid Surgical Site Complications

- iNPT focuses on reducing surgical site complications (SSCs), such as infection, helping physicians and facilities reduce costs associated with these complications
- Data on iNPT has shown reduction in surgical site infections (SSIs) and seromas

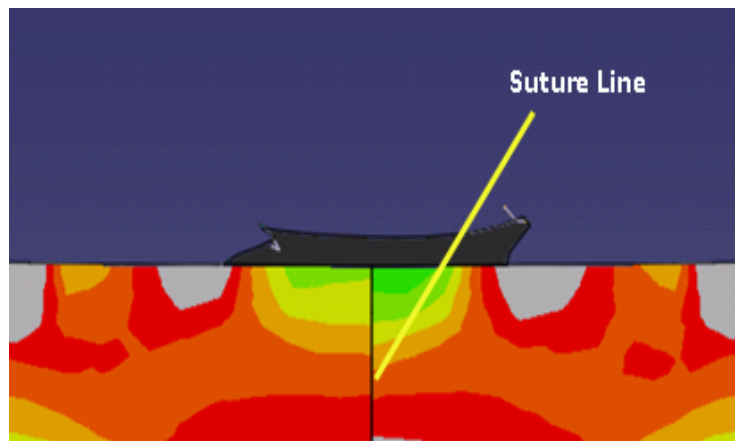
In 2019, clinical evidence resulted in the first medical device indicated by the FDA to

- Aid in reducing seromas
- Aid in reducing superficial surgical site infections in class I and class II wounds in high-risk patients

3D Finite Element Computer Modeling Showed iNPT Can Help Relieve Lateral Tension

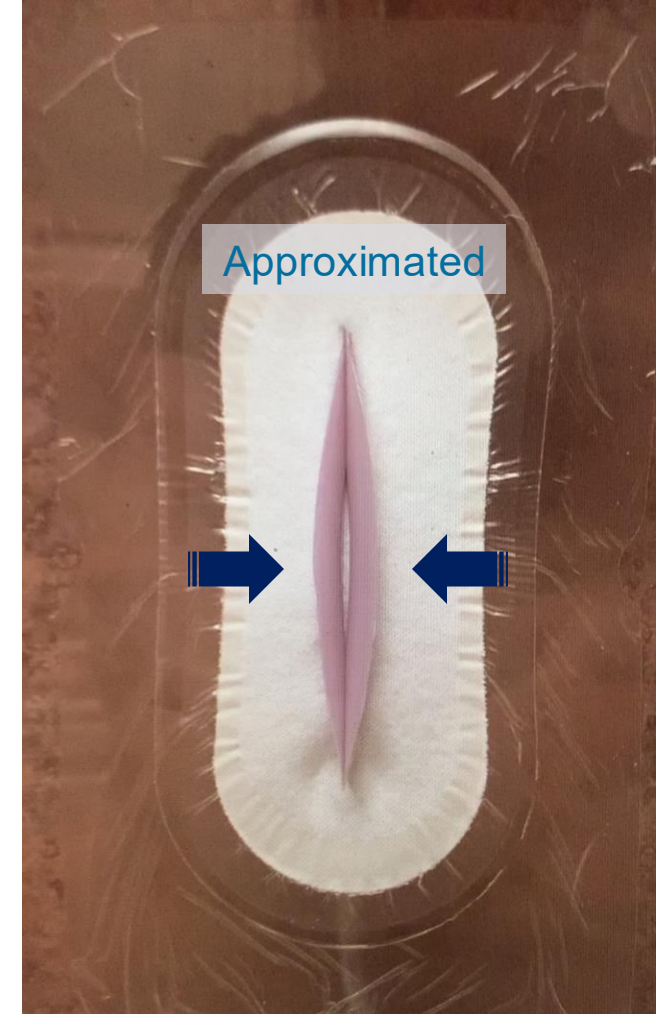
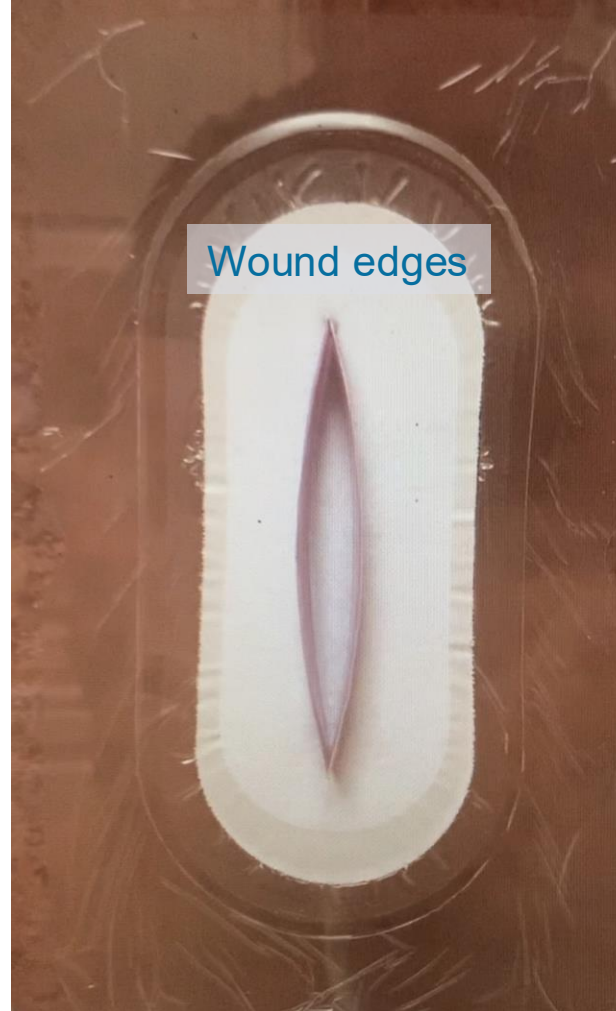


- Lateral stress at 0 mm HG
- Orange color corresponds to areas of relatively high lateral strain



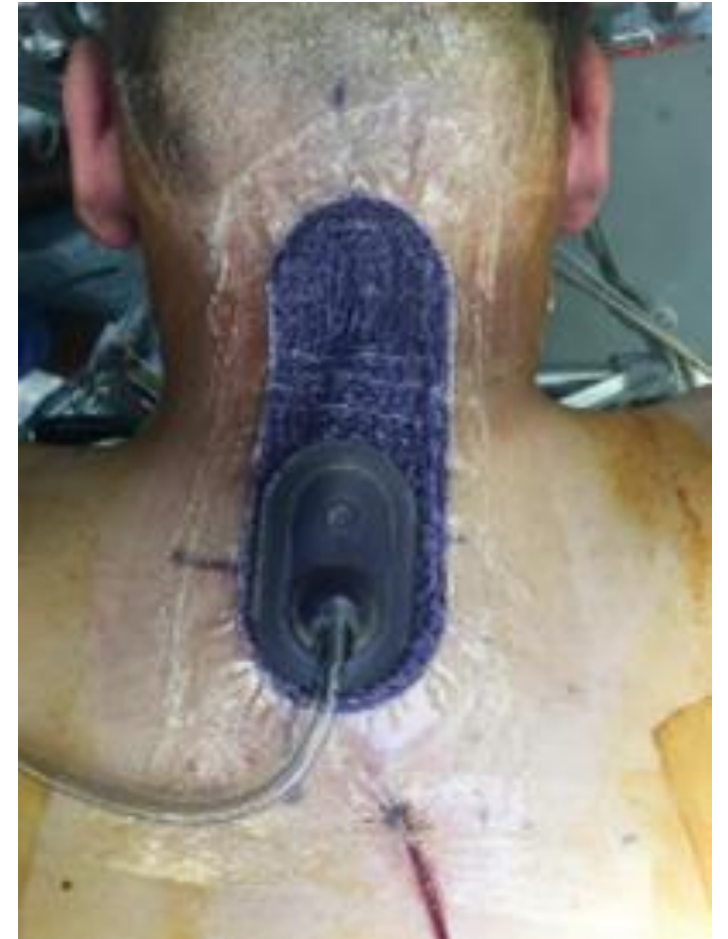- Negative pressure (-125 mm Hg) was applied to the dressing
- Yellow and green colors correspond to areas of relatively low lateral strain
- **Lateral tension around suture line was reduced approximately 50% with closed incision management with NPWT**

ciNPT: Mechanism of Action



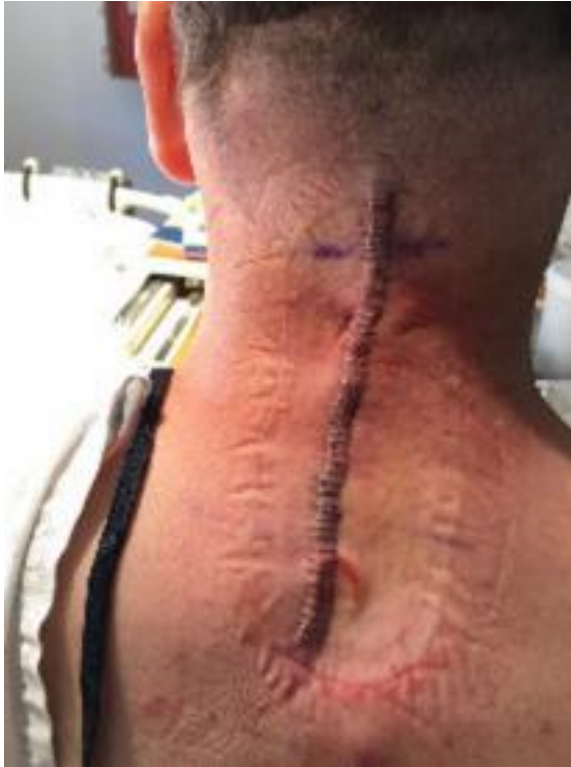Case

- 62y Male, hx of hypertension (HTN), dyslipidemia (DLD), tobacco use, impaired fasting glucose (IFG), degenerative disc disease (DDD) with spinal cord compression (SCC)
 1. C3-7 decompressive laminectomy
 2. C3-7 lateral mass screws and rods
 3. C3-C7 posterolateral fusion (allograft/autograft)
 - He has followed with Respiratory due to smoking hx and recent wheezing, and pre-op clearance was noted under media. He quit smoking \approx 1.5 months ago; prior to that, he had been smoking 6-7 small cigars per day
 - He drinks \approx 4 beers daily

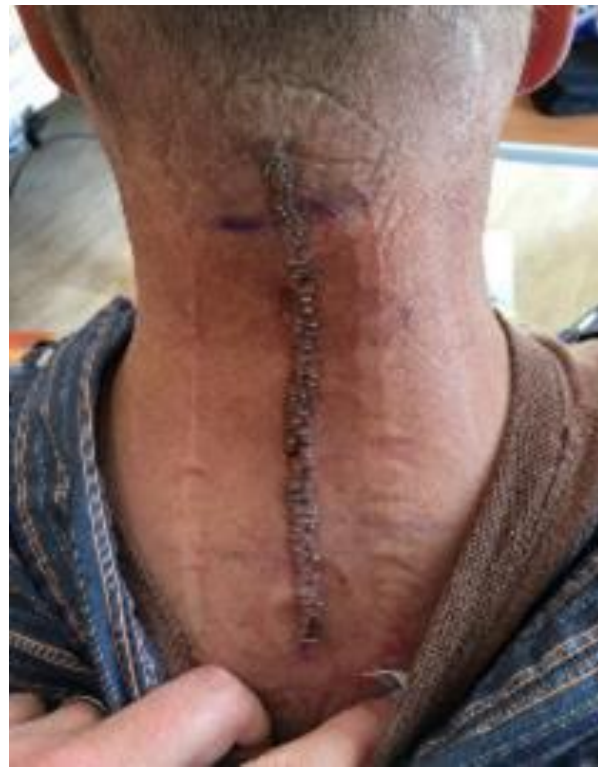

In OR

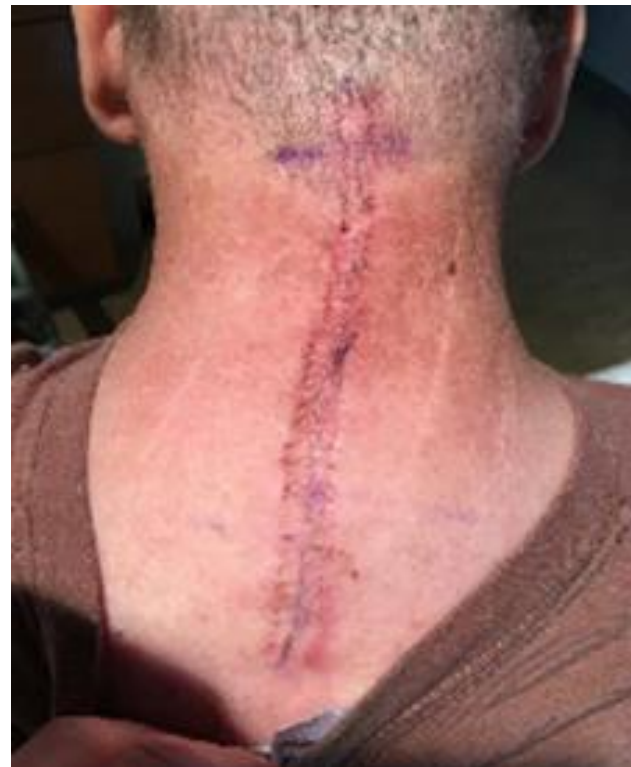Case



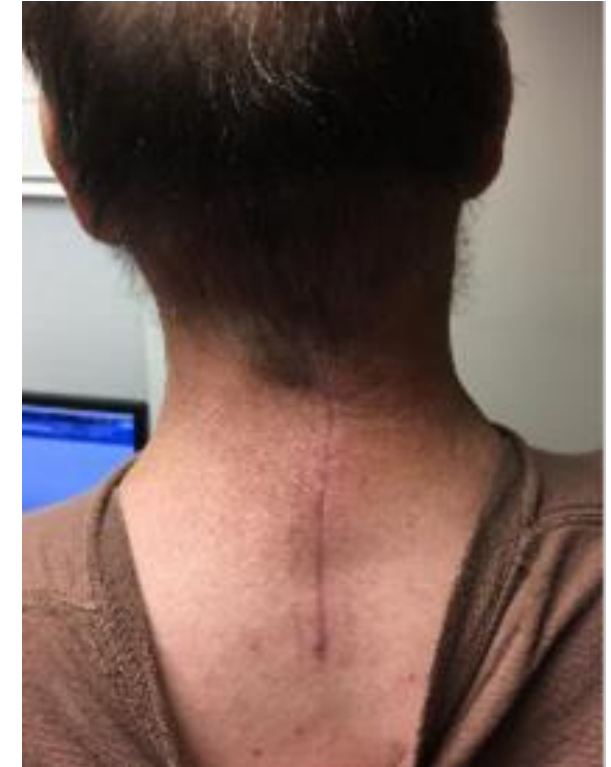POD 3



POD 9













POD 16


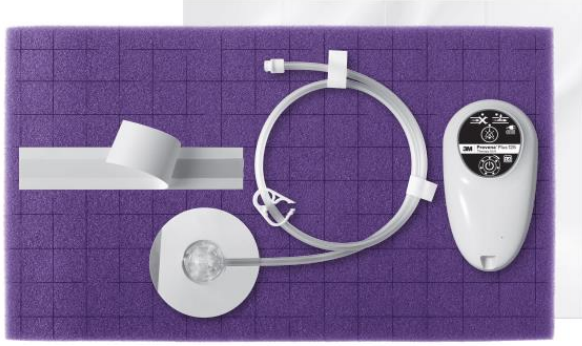




6 wks post-op

Disposable iNPWT

Negative Pressure Therapy Units	Incision Management	Incision & Soft Tissue Management Optimize Surgical Site Healing, Recovery, Outcomes
 <ul style="list-style-type: none"> • Replaceable 45mL canister • Continuous -125 mm Hg • 7 days of therapy • 45mL leak threshold 	<p>Peel and place dressings</p> <ul style="list-style-type: none"> • Ease of use dressings designed for linear incisions up to 35cm  <p>13cm 20cm 35cm</p>	<p>Ease of use dressings for coverage of entire surgical site (incision and surrounding soft tissue)</p>
 <p>7-Day Therapy Unit</p> <ul style="list-style-type: none"> • Replaceable 150mL canister • Continuous -125 mm Hg • 7 days of therapy • 150mL leak threshold 	<p>Customizable Dressing</p> <ul style="list-style-type: none"> • Designed for non-linear and intersecting incisions up to 90cm • Designed for flexibility and user customization 	 <ul style="list-style-type: none"> • 33x30cm and 46x30cm
 <p>14-Day Therapy Unit</p> <ul style="list-style-type: none"> • Replaceable 150mL canister • Continuous -125 mm Hg • 14 days of therapy • 150mL leak threshold 	 <p>Customizable Dressing (up to 90cm)</p>	 <ul style="list-style-type: none"> • 21x19cm, 24x22cm, 29x27cm  <ul style="list-style-type: none"> • 29x28cm  <ul style="list-style-type: none"> • 29x31cm  <ul style="list-style-type: none"> • Larger area coverage, flexibility, user customization • 49x28cm

Disposable iNPWT

	Ease of Use Application (Peel & Place)	Flexibility & Customization
<p>Area Coverage</p>	 <p>33x30cm 46x30cm</p> <p>21x19cm 24x22cm 29x27cm</p> <p>29x28cm</p> <p>29x31cm</p>	 <p>4x28cm</p>
<p>Linear Coverage</p>	 <p>3cm</p> <p>20cm</p> <p>35cm</p>	 <p>6x90cm</p>

iNPWT Dressing System Components




Foam manifold layer:
Uses the same foam and interface layer as disposable iNPWT. Contains slits to allow for conformability



x10

Hydrocolloid strips x10:
Used as the primary means of attaching foam to patient's skin and maintaining seal for 7-14 days

x6



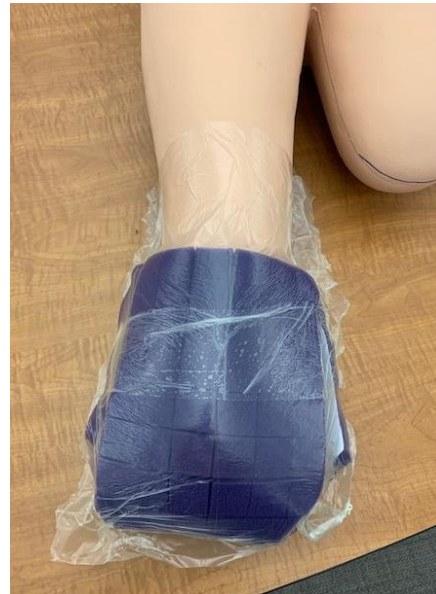Sealing layer: Vacuum assisted closure (VAC) drape; system uses same VAC drape as used with black foam and disposable iNPWT dressing



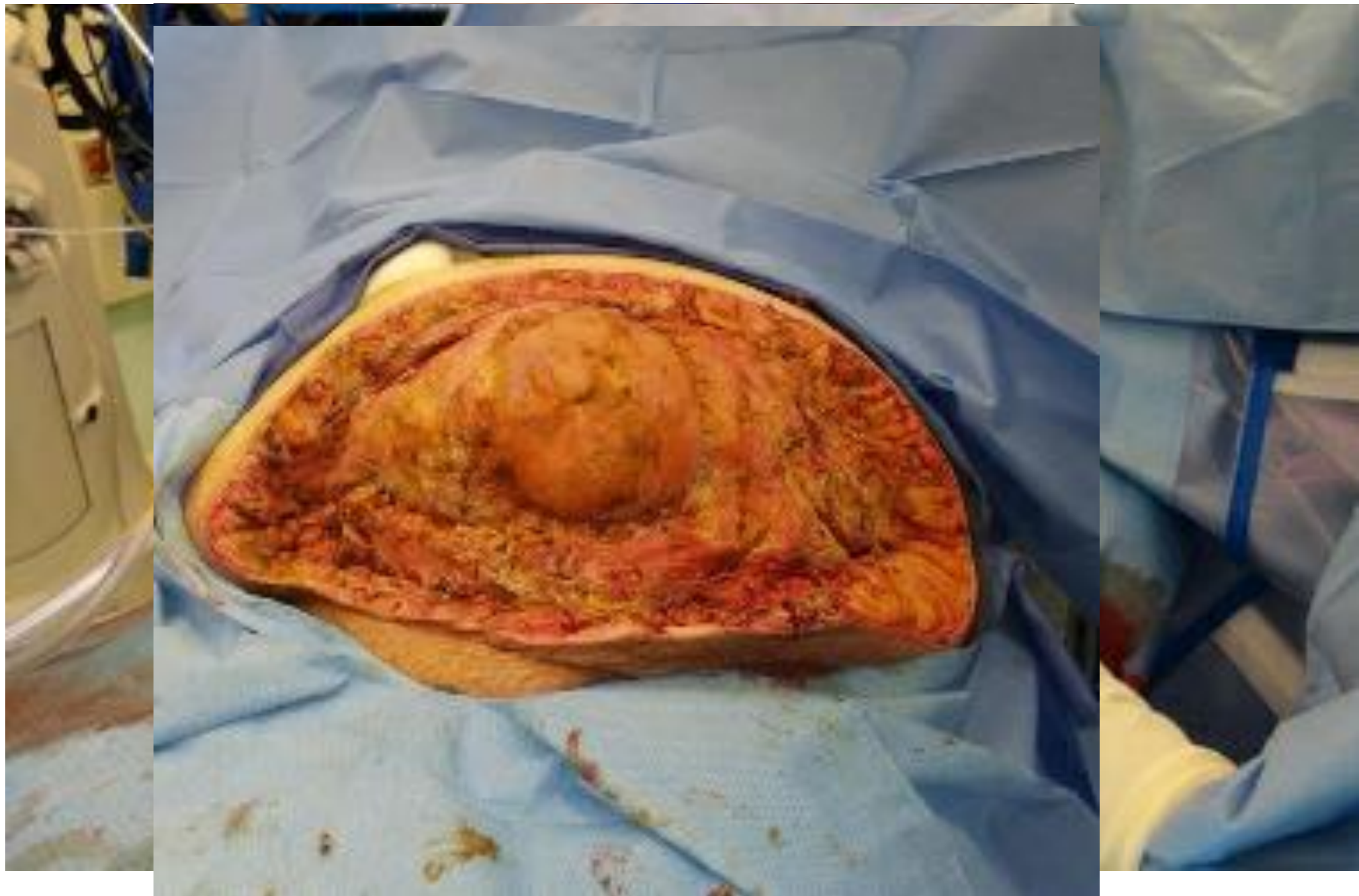
Tubing system used to communicate negative pressure to integrated disposable iNPWT dressing

Lower Extremity Amputation

- “Hourglass” dressing shape
 - It may be helpful to add 2 hydrocolloid strips to the top of the dressing to create anchor-point(s) when placing foam on the stump
 - 4 drapes were used to seal the dressing; pad would be placed on the anterior, superior portion of the dressing



Open Abdomen NPWT (OA-NPWT)



OA-NPWT Dressing

Negative Pressure Unit

- Compatible NPWT unit applies negative pressure

NOTE: Not for use with instillation therapy

Fenestrated Visceral Protective Layer

- Manifolds negative pressure throughout abdomen
- Enhances fluid removal from paracolic gutters and allows rapid access for re-entry
- Placement does not require sutures, which minimizes fascial damage
- Provides separation between abdominal wall and viscera; protects abdominal contents

Drape

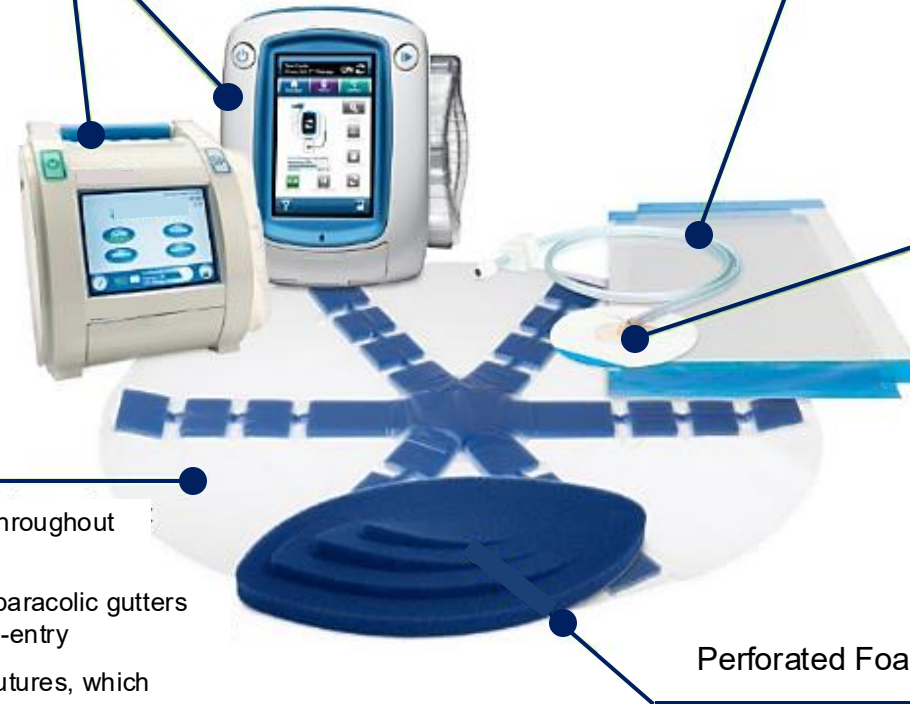- Provides closed system to help isolate and protect abdominal contents from external environment

Pad

- Facilitates fluid removal from dressing
- Provides monitoring of negative pressure during therapy



Perforated Foam

- Promotes active fluid removal
- Provides medial tension to help minimize fascial retraction and loss of domain



OA-NPWT Dressing

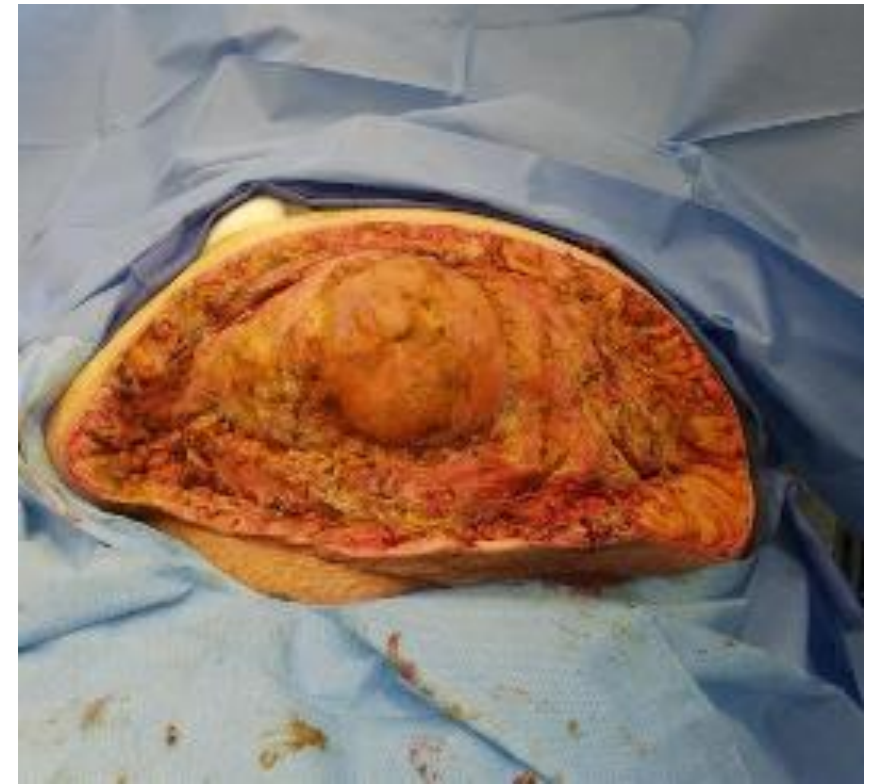
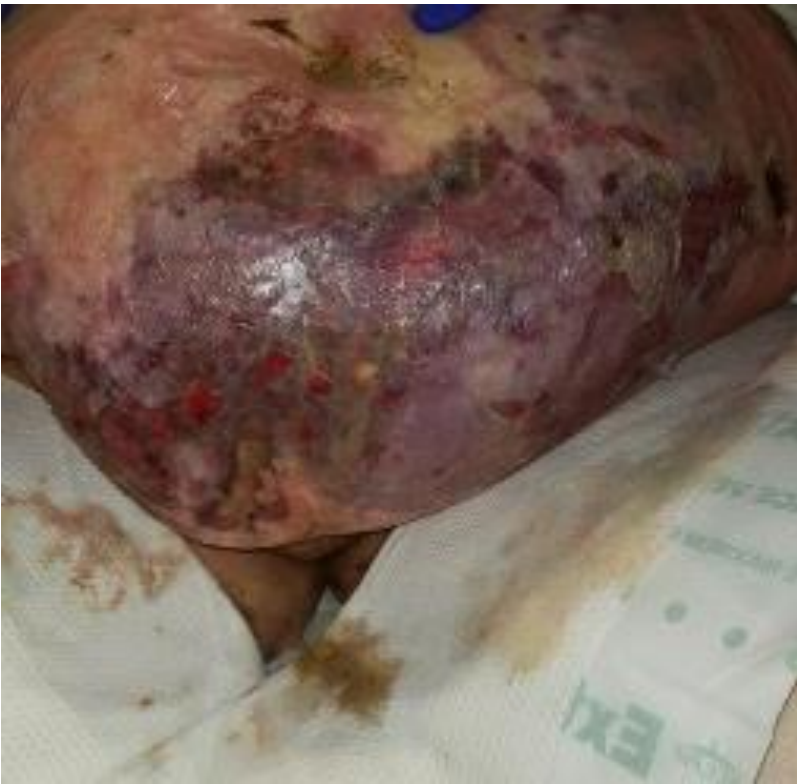- For temporary bridging of abdominal wall openings where primary closure is not possible or repeat abdominal entries are necessary
- Intended use: Open abdominal wounds with exposed viscera (including abdominal compartment syndrome)
- Intended care setting: Closely monitored area within acute care hospital, such as the ICU
 - OA-NPWT dressing is most often applied in the OR



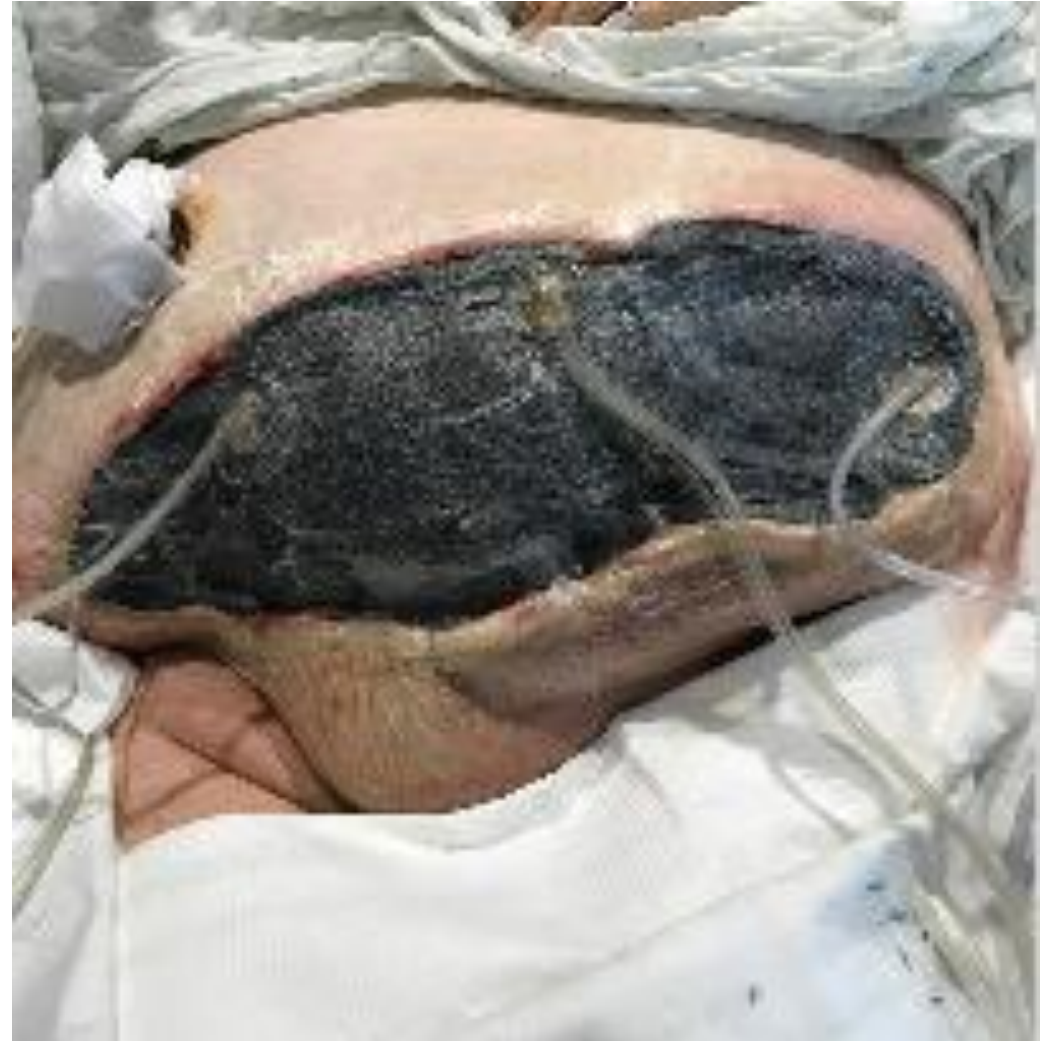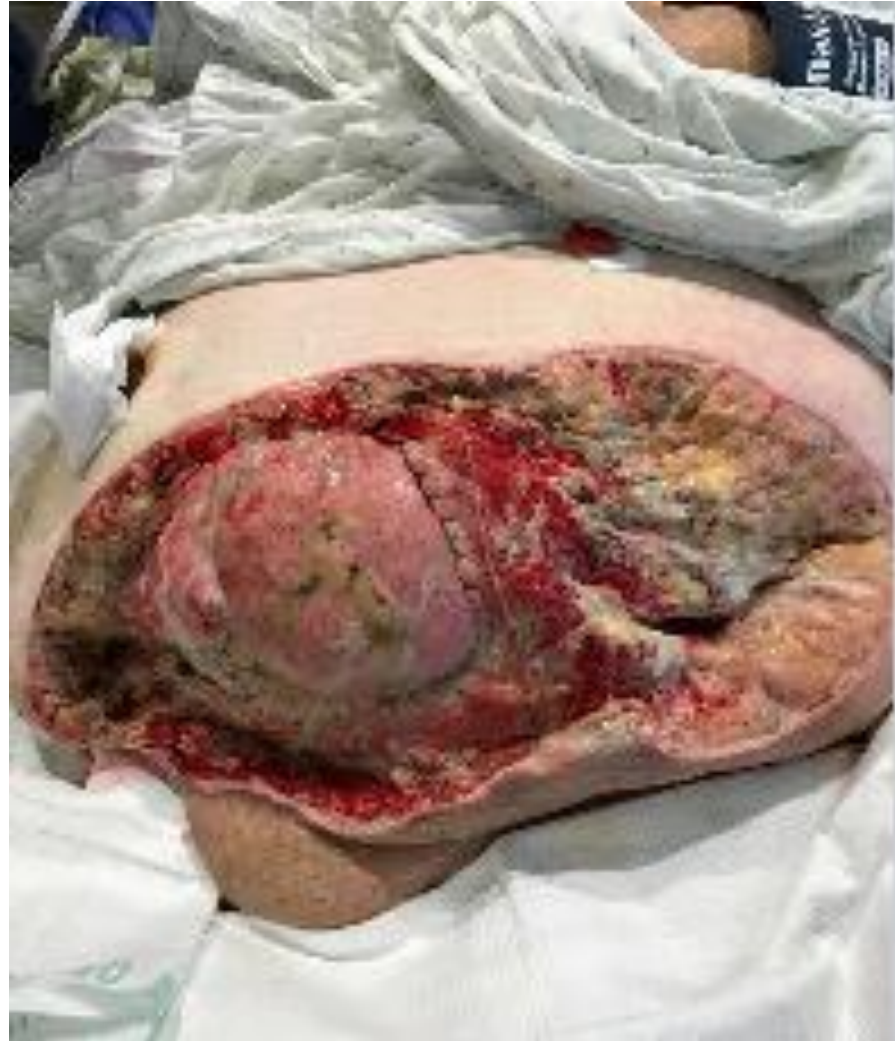Evidence-Based

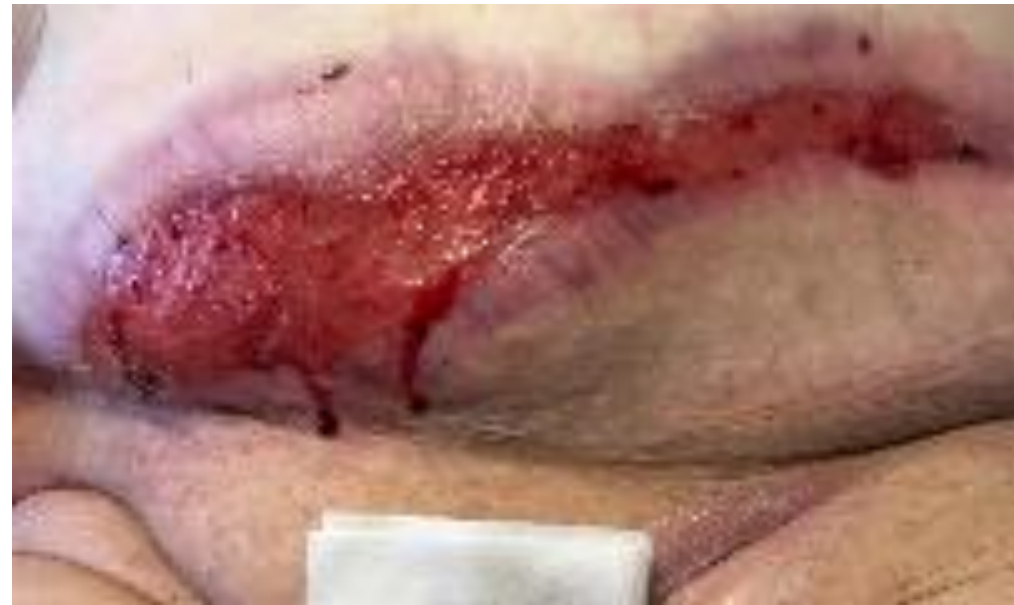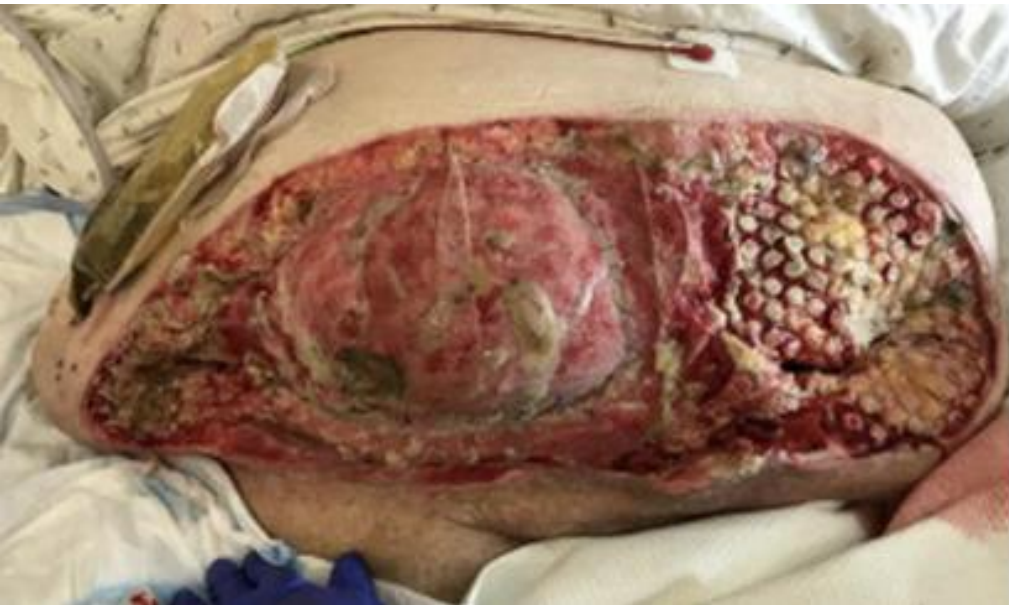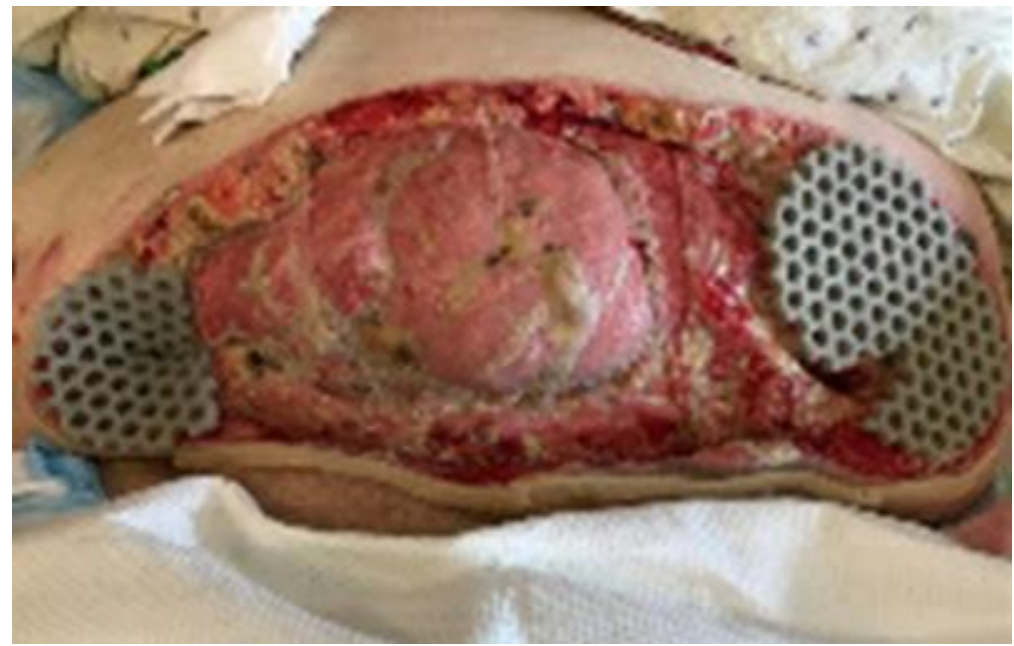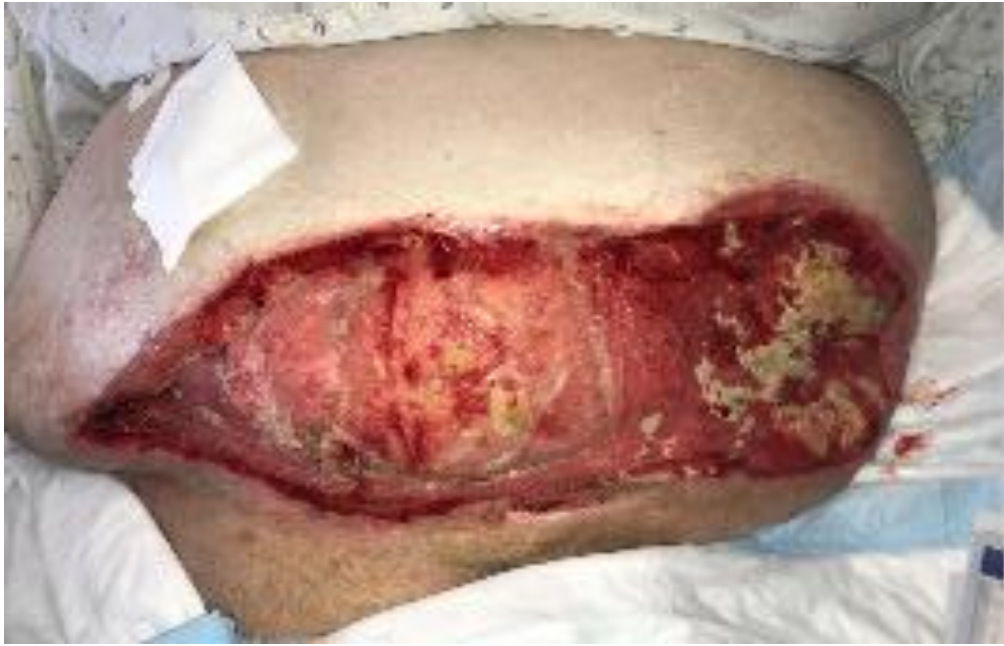- In a 20-center observational study comparing OA-NPWT to Barker's vacuum-packing technique (BVPT) in trauma and surgical patients, OA-NPWT was associated with significantly improved 30-day primary fascial closure (PFC) rate and 30-day all-cause mortality rate ($p=0.03$ and 0.01 , respectively)
- In a retrospective comparison of 37 OA-NPWT vs 37 BVPT patients, PFC rates were 89% with OA-NPWT vs 59% with BVPT ($p<0.05$)
 - The cost of ventral hernia repair in 2006 was \$16,000; the authors estimated that 11 ventral hernias could have been prevented for a potential cost savings of \$176,000
- Actively removes fluid, helping to reduce edema
- In a chronic porcine sepsis and ischemia/reperfusion model, systemic inflammation was significantly reduced in the NPWT group compared to controls with passive drainage
- In the above study, NPWT removed a significantly greater volume of ascites than passive drainage

Necrotizing Fasciitis of the Abdomen



Necrotizing Fasciitis of the Abdomen



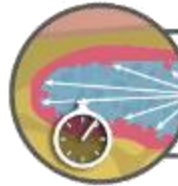

NPWT with Instillation and Dwell (NPWTi-d)

Instillation & Dwell Phase

Solution Instillation


Cleanses wound with cyclic delivery, dwell, & removal of topical wound solutions



Provides thorough wound coverage with topical solution during selected dwell time¹


Solution Dwell

Dilutes and solubilizes² infectious material and wound debris

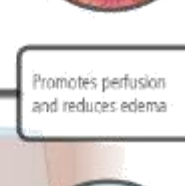

NPWT Phase

Macrostrain



Draws wound edges together




Promotes perfusion and reduces edema




Removes exudate and infectious material

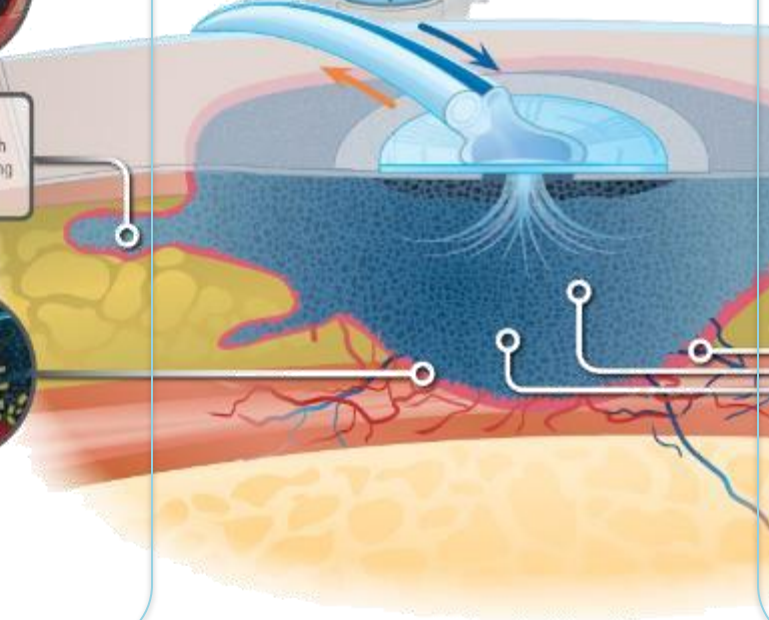
Microstrain



In vitro/in vivo studies show that foam contact with tissue creates micro-deformation that leads to cell stretch^{2,3}



Cell stretch under negative pressure stimulates cellular activity that results in granulation tissue formation⁴

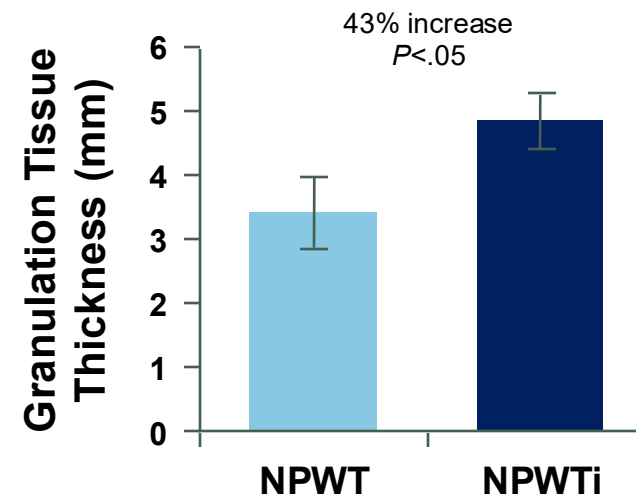
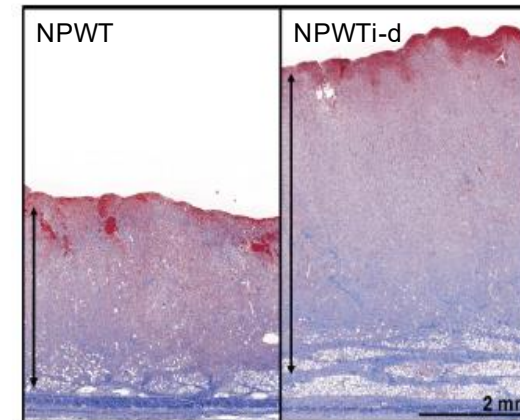


*Topical solution dependent

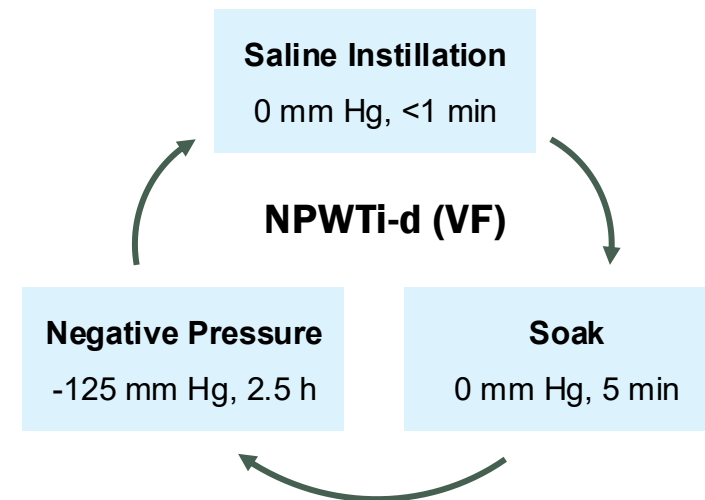
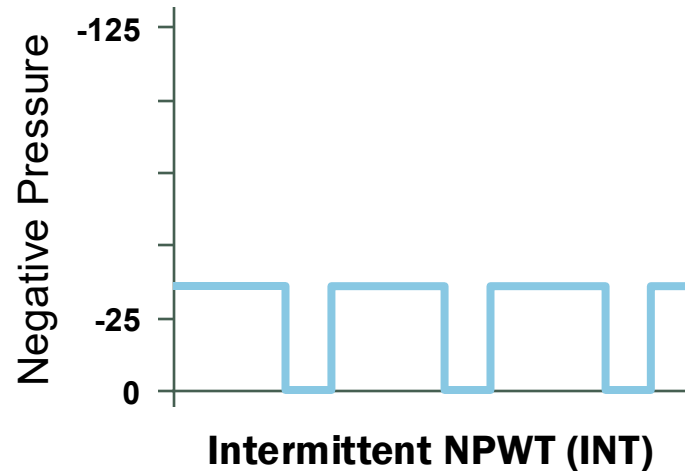
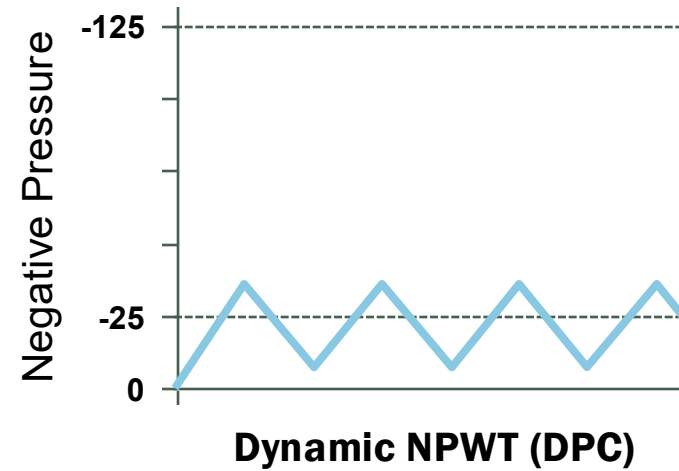
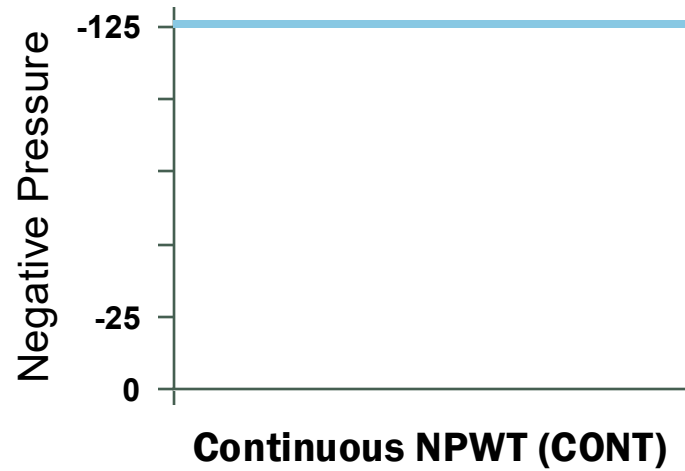
Rycerz AM, et al. *Int Wound J.* 2013;10(2):214-220. Saxena V, et al. *Plast Reconstr Surg.* 2004;114(5):1086-1096. McNulty AK, et al. *Wound Repair Regen.* 2009;17(2):192-199. McNulty AK, et al. *Wound Repair Regen.* 2007;15(6):838-846.

Granulation Tissue Formation Non-Infected Wounds, Study #1

- Porcine wound healing model with 7 days of treatment
 - NPWT (continuous -125 mm Hg)
 - NPWTi-d with saline (5-min soak followed by 2.5 hrs NPWT at -125 mm Hg per cycle)
- Contralateral non-infected wounds
- Wounds treated with NPWTi-d and saline had **43% more granulation tissue** than NPWT wounds after 7 days of therapy

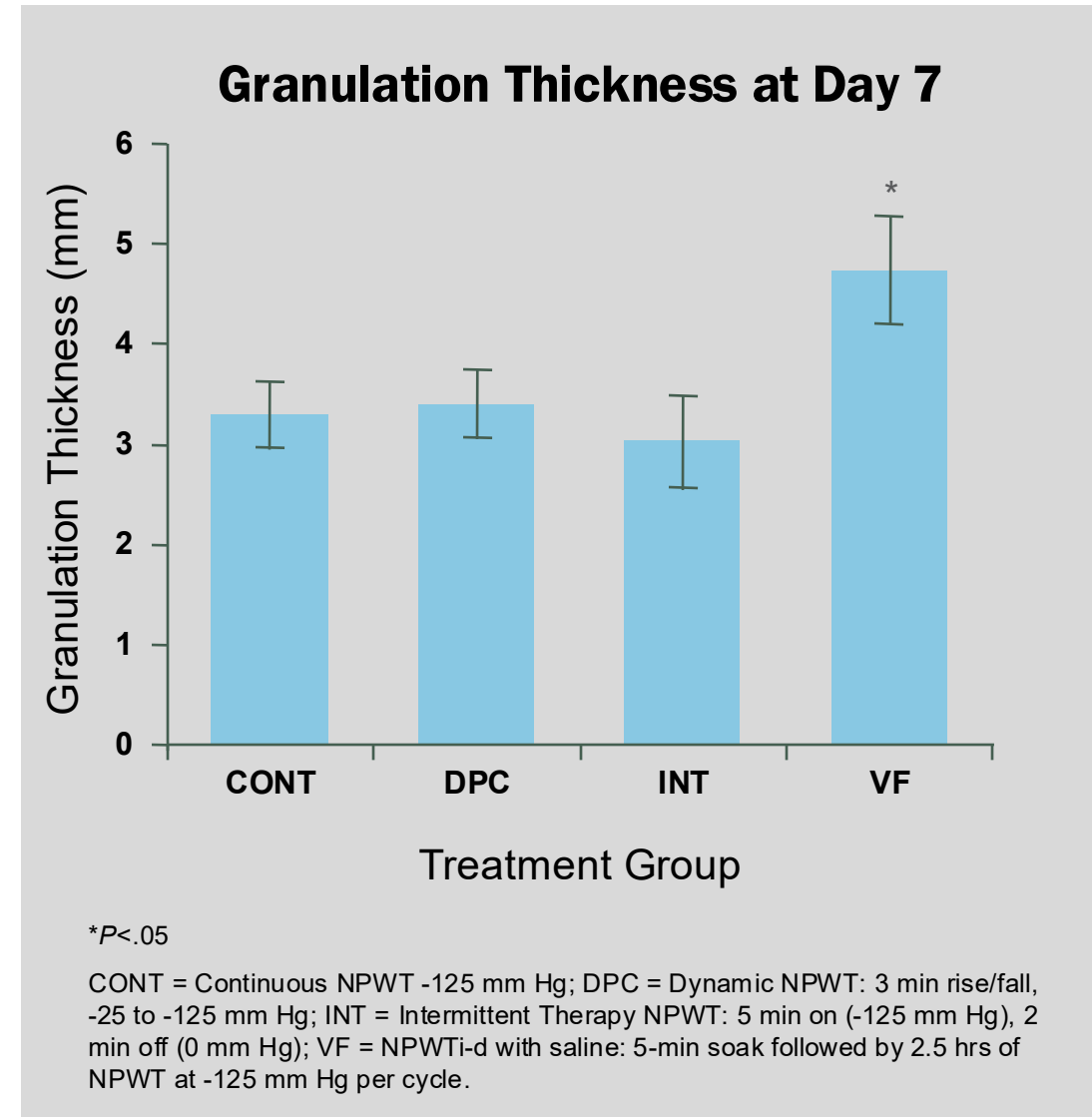


Granulation Tissue Formation Non-Infected Wounds, Study #2




Granulation Tissue Formation Non-Infected Wounds, Study #2


- Porcine wound healing model (acute, non-infected wounds)
 - Continuous NPWT (CONT)
 - Dynamic NPWT (DPC)
 - Intermittent NPWT (INT)
 - NPWTi-d (VF)
- NPWTi-d resulted in 44% more granulation tissue than continuous NPWT after 7 days of therapy
- No statistical difference between continuous, dynamic, and intermittent NPWT



Silicone-Acrylic Hybrid Drape



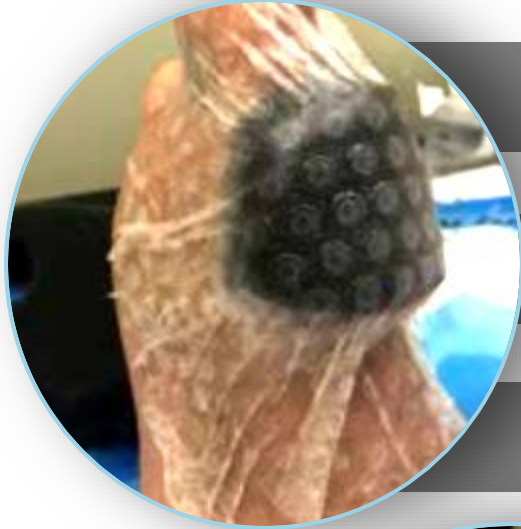- FDA-cleared hybrid drape for NPWT and NPWTi-d



Acrylic (inside the circles) ensures a tight seal to protect wounds on different anatomical locations

Silicone (outside the circles) allows for repositioning upon initial application, easy handling, and gentle removal during dressing changes

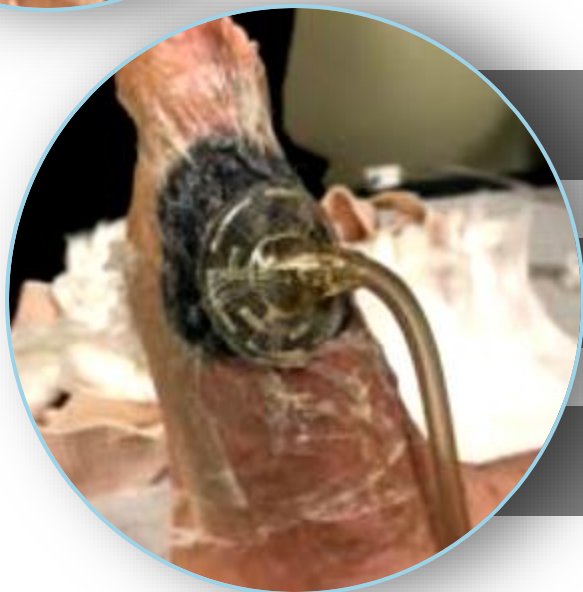Hybrid Drape Benefits



Easy to apply

Repositionable upon initial placement

Skin-friendly, provides patient comfort on removal





Savings (time, waste)

Protects periwound area

Seal strength

Improved Application Requires Changes in Technique




Acrylic Drape		Hybrid Drape
1 – 2 – Blue	➡	Single clear release liner
Window-pane technique	➡	Less need for window paning
Apply skin prep	➡	No need to use ancillary products
Extensive cutting	➡	Less cutting
Use in dry skin conditions	➡	Use in dry or wet skin conditions*


* Hybrid drape is effective in wet conditions but optimal in dry

Hybrid Drape Application

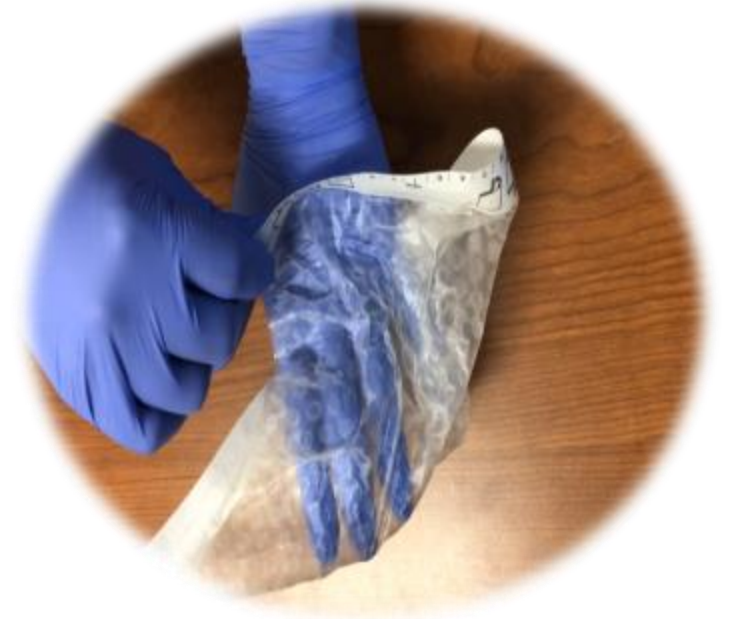Cut drape from handle to handle, leaving at least a 5cm border



Remove single-release liner



If the drape sticks to itself or to gloves, detach and reposition



- Perform thorough wound and periwound cleaning per physician order or institution protocol prior to each dressing application
- The 2 adhesive properties help to achieve effective seal between the drape and body and to eliminate leaks at application without ancillary products

Hybrid Drape Application

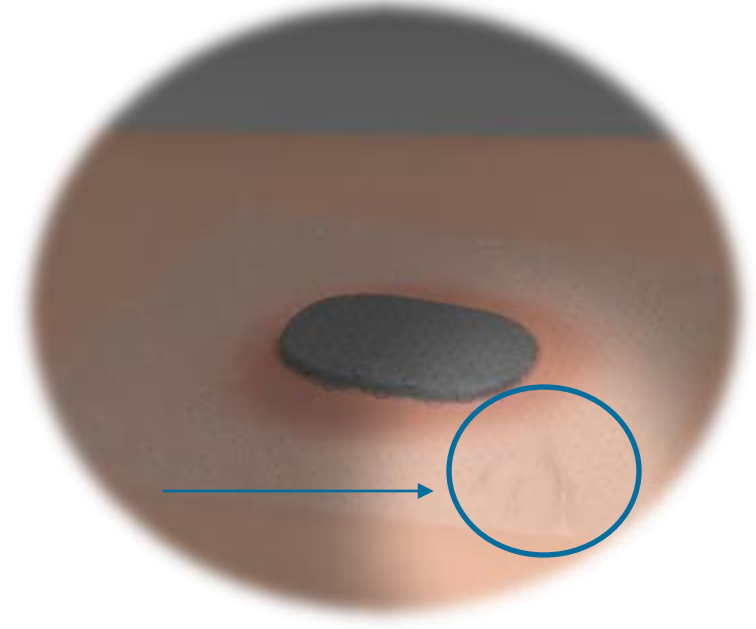


Stretching the drape can lead to tension when NPWT is applied

Reposition using the handlebars (easier to manage drape during initial placement)

Drape can be repositioned without loss of adhesion (cure time \approx 20 min)

Smooth wrinkles, reposition if necessary; remove perforated ends


Reposition again, if necessary







Updated Indication for Use (U.S. Only)


- NPWTi-d with NPWTi-d dressing provides hydromechanical removal of infectious materials, non-viable tissue, and wound debris, which reduces the number of surgical debridements required while promoting granulation tissue formation, creating an environment that promotes wound healing

Dressing Selection Is Based On Wound Characteristics and Goals of Therapy



Wound Type				
Wound Characteristics	Open wounds, including wounds with shallow undermining or tunnel areas where the distal aspect is visible	Large open wounds, including wounds with shallow undermining or tunnel areas where the distal aspect is visible	Wounds with complex geometries, including explored tunnels or undermining where the distal aspect is not visible	Wounds with thick wound exudate, such as fibrin, slough, infectious material
Key Goal(s) of Therapy	<ul style="list-style-type: none"> • Used in conjunction with NPWTi-d to facilitate removal of wound exudate and infectious material • Generation of granulation tissue 	<ul style="list-style-type: none"> • Used in conjunction with NPWTi-d to facilitate removal of wound exudate and infectious material • Generation of granulation tissue in large wounds 	<ul style="list-style-type: none"> • Used in conjunction with NPWTi-d to facilitate the removal of wound exudate and infectious material • Easy application into tunneling and undermining 	<ul style="list-style-type: none"> • Used in conjunction with NPWTi-d to facilitate removal of thick wound exudate to provide wound cleansing option for clinicians prior to OR debridement or when OR debridement may not be immediately available • Hydromechanical removal of infectious materials, non-viable tissue, and wound debris which reduces the number of surgical debridements required, while promoting granulation tissue formation, creating an environment that promotes wound healing

NPWTi-d Dressing




Thick cover layer
(1.6cm thickness)

Thin cover layer
(0.8cm thickness)

Contact layer
- 0.8cm thickness
- 1.0cm circular holes
- 5mm spacing




Mechanism of Action



Reticulated open-cell foam dressing with through holes (ROCF-CC) and development of macro-columns. (A) The ROCF-CC contact layer in wound; (B) cover layer applied over contact layer; (C) side view of macrocolumns formed within the holes of the dressing; and (D) top view of macrocolumns.

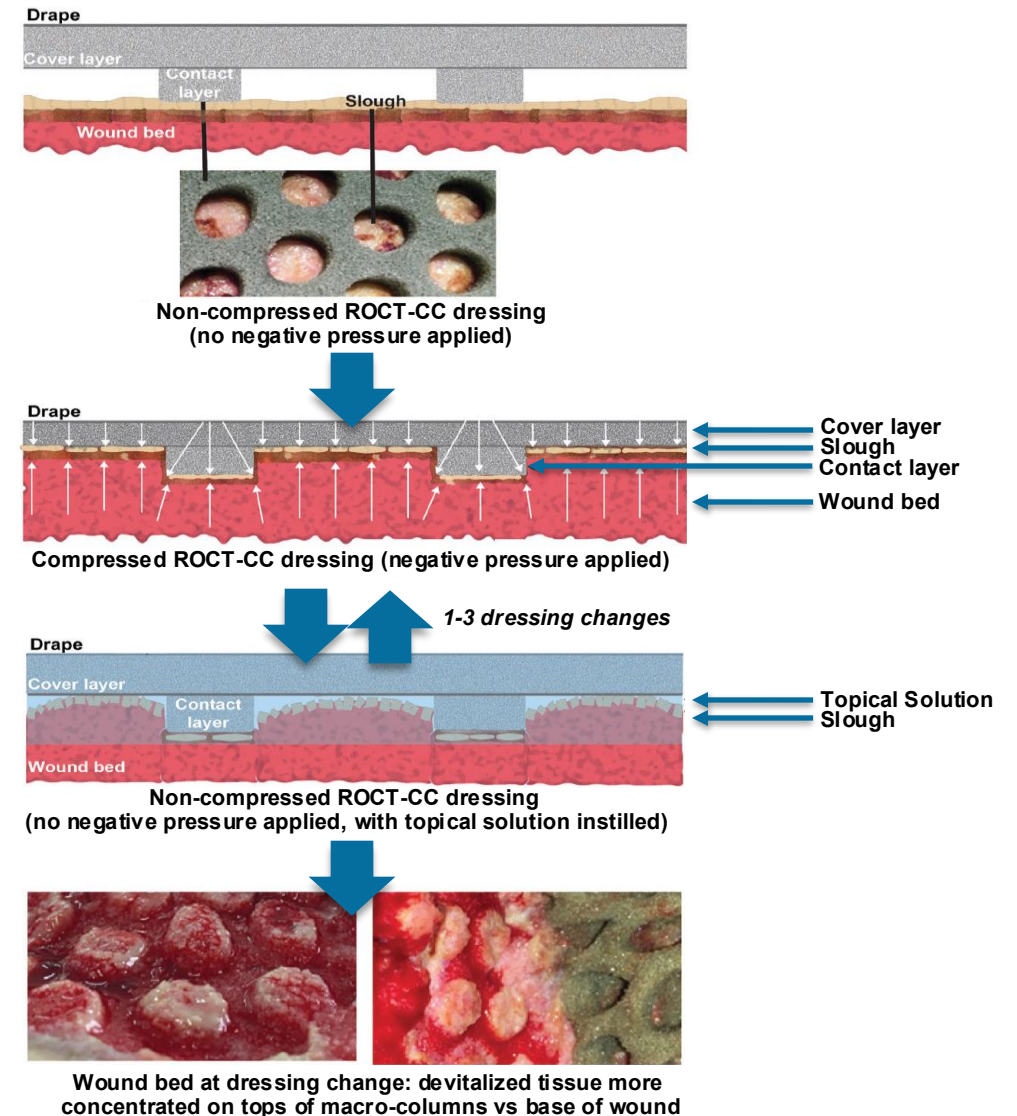
How Does This Dressing Differ From Previous NPWTi-d Dressings?



No-sting barrier film is not included in the dressing kit due to the skin-friendly adhesive properties of the silicone-acrylic hybrid drape

Proposed Mechanism of Wound Cleansing with ROCF-CC

“Cyclic delivery of the topical solution, as well as dwell time and removal of the solution, is hypothesized to produce a mechanical hydrodynamic force on the stressed wound bed, disrupting and helping to soften and solubilize thick exudate and loosen wound debris for removal during NPWT. The presence of larger openings or through holes in the dressing may then accommodate easier passage of thick, fibrinous materials away from the wound bed.”




Equivalency Testing Finite Element Analysis

- The updated version of the ROCF-CC has been studied and shows the **foam–tissue interaction is the same** as the original option

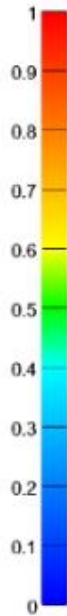
20210301 a3

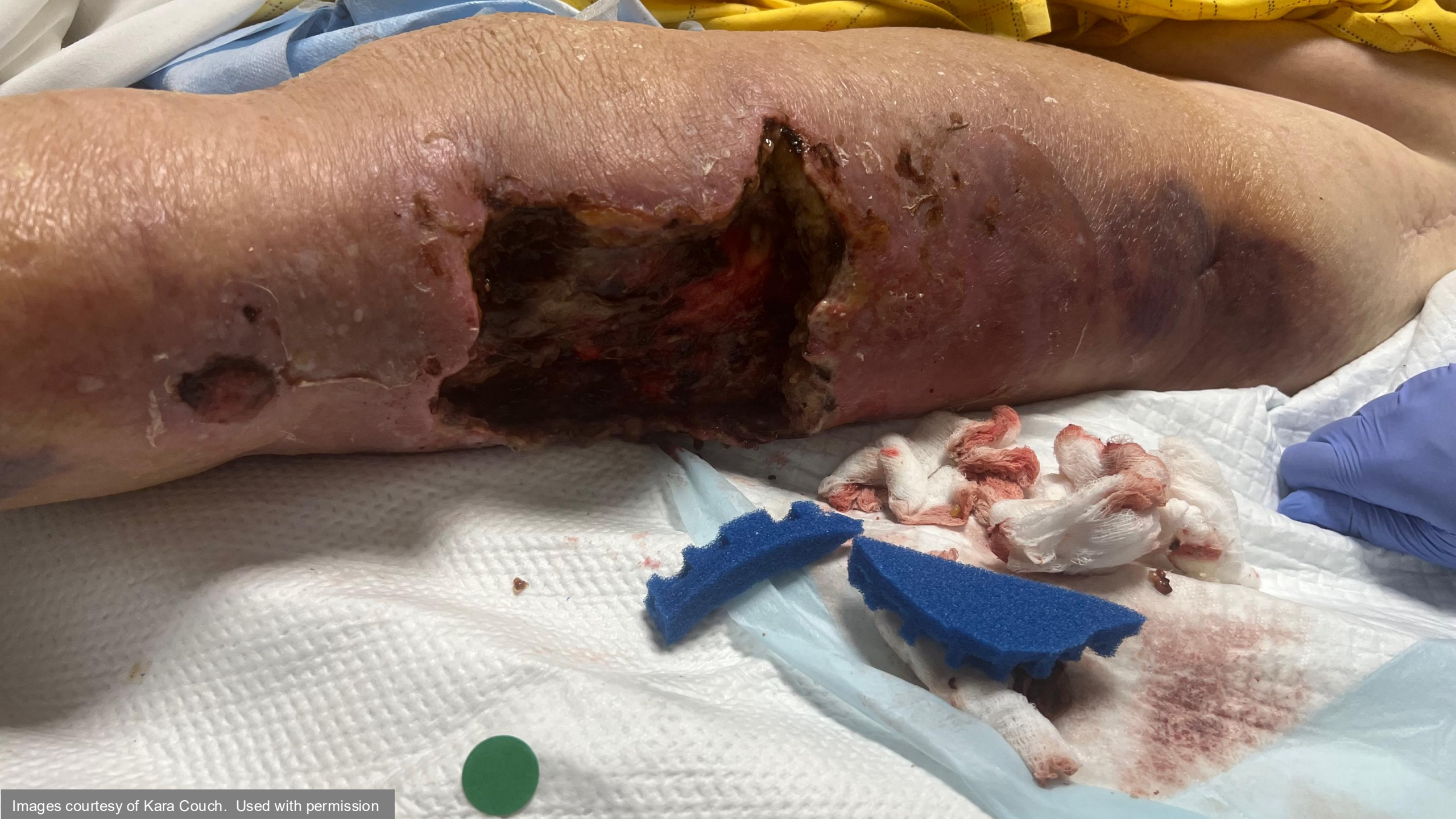Effective Lagrange strain
Time = 0.9878




20210303 a1

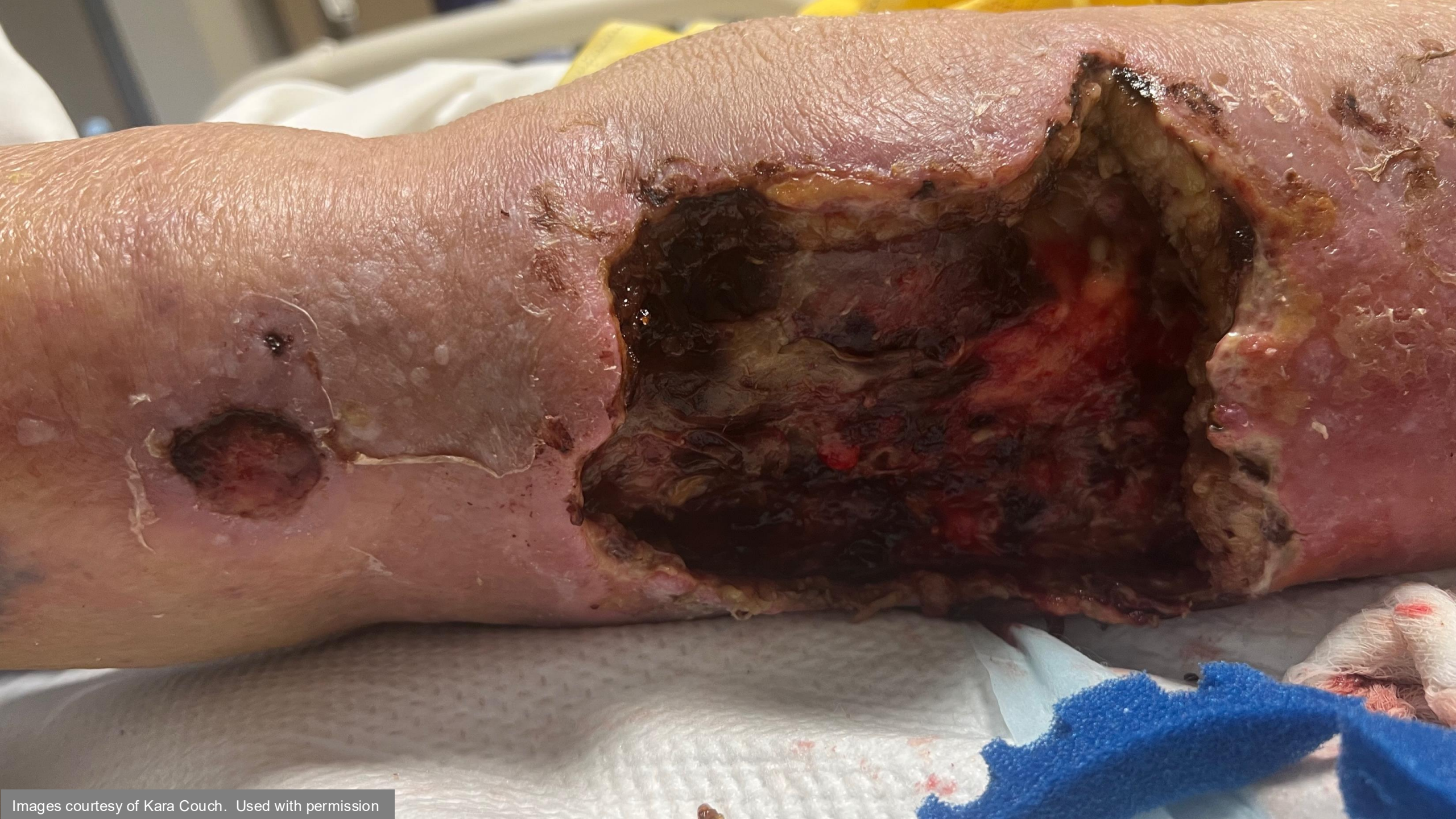Effective Lagrange strain
Time = 0.9867



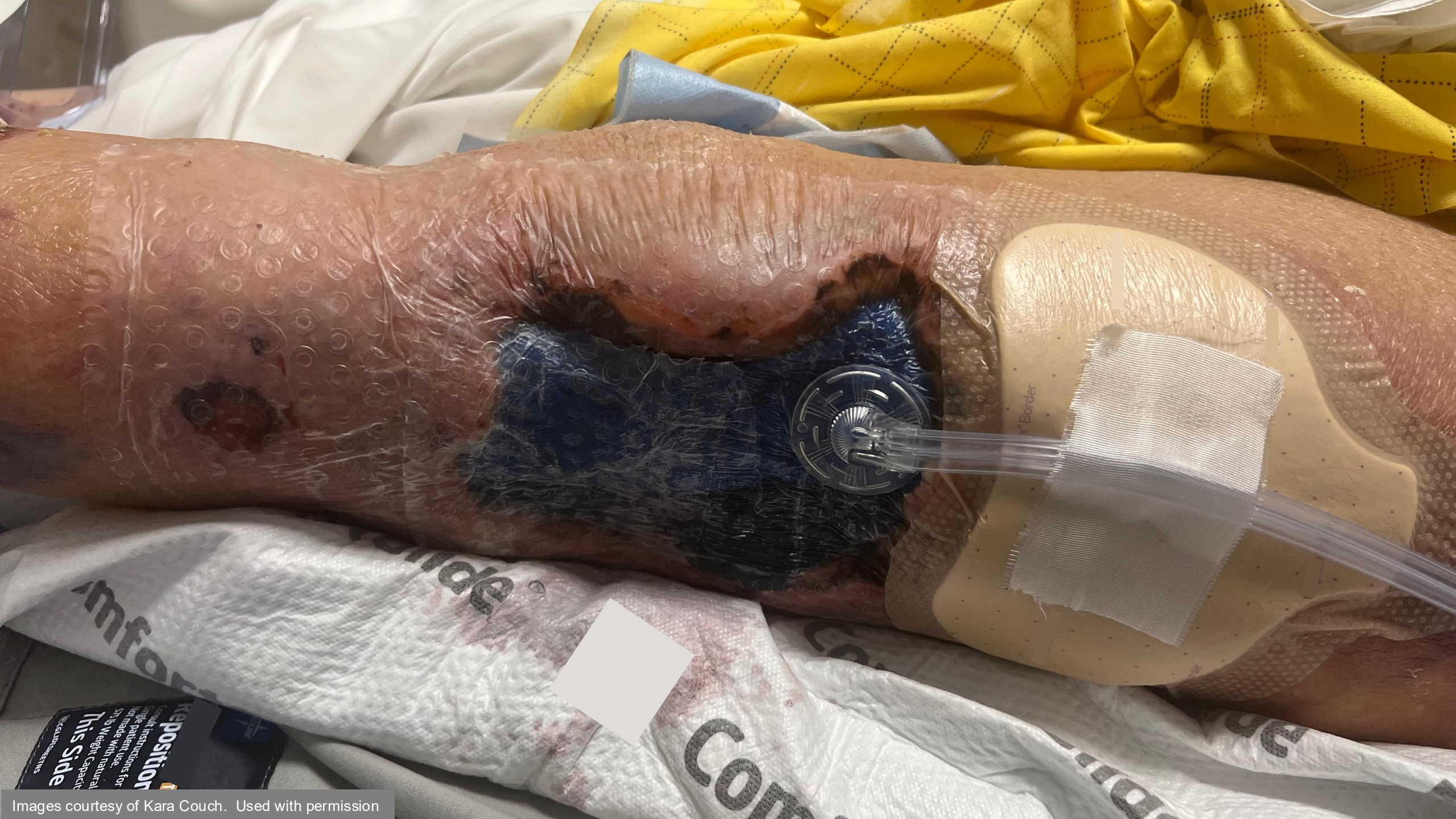

Images courtesy of Kara Couch. Used with permission

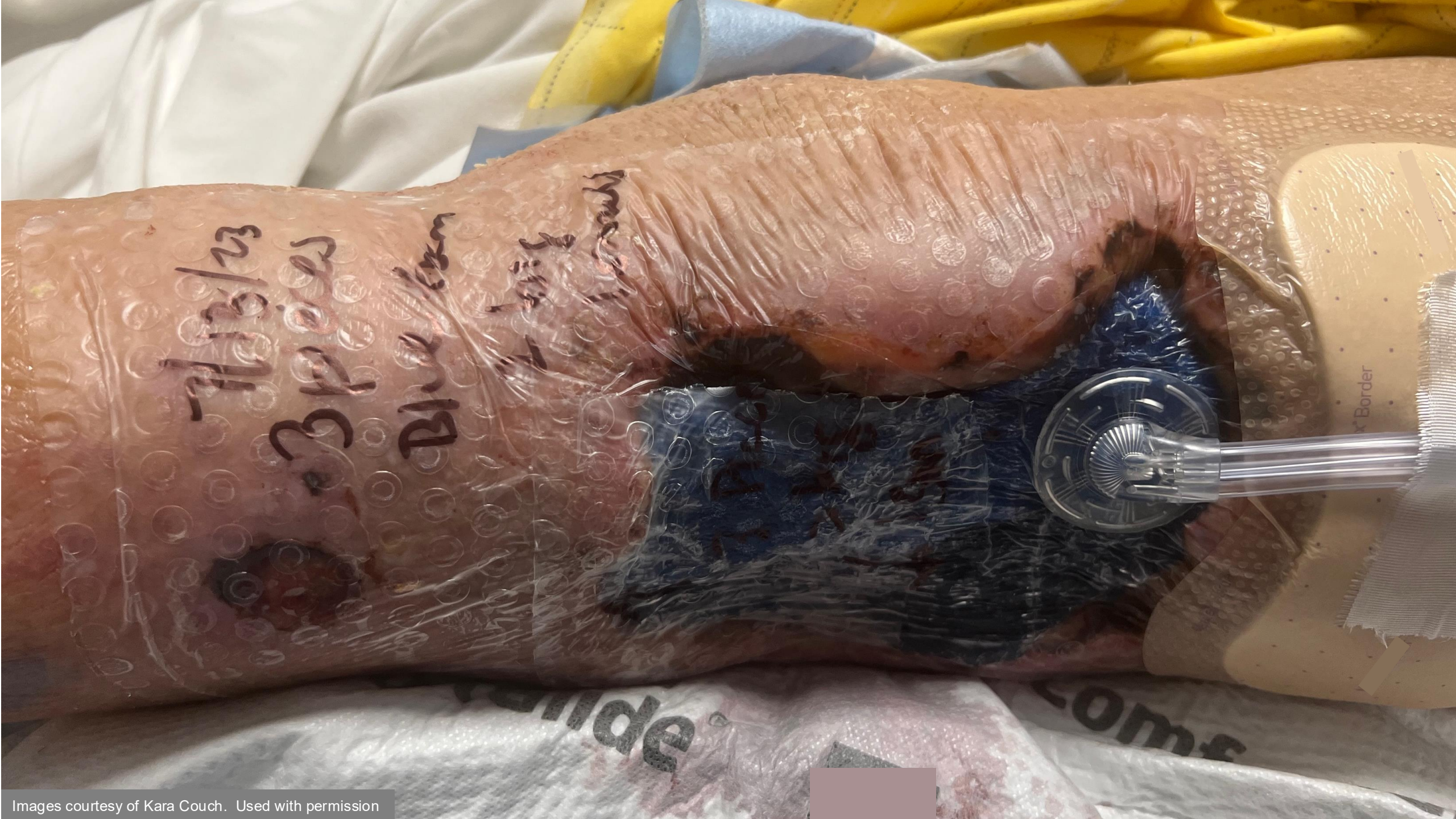



Images courtesy of Kara Couch. Used with permission



Images courtesy of Kara Couch. Used with permission



7/18/23

K. P. Jones

Blud

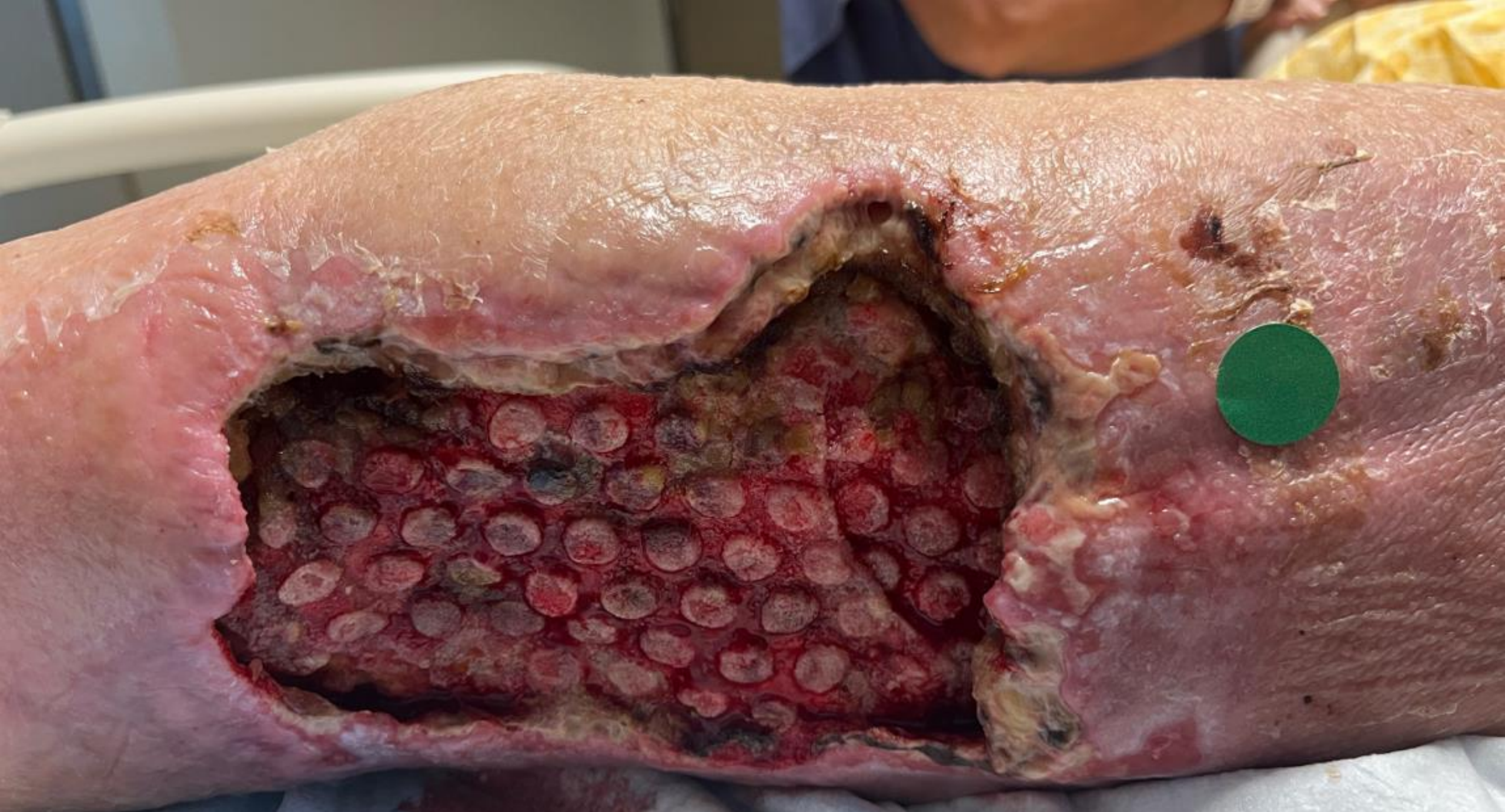Handwritten notes

Border

Slide

Some

Images courtesy of Kara Couch. Used with permission



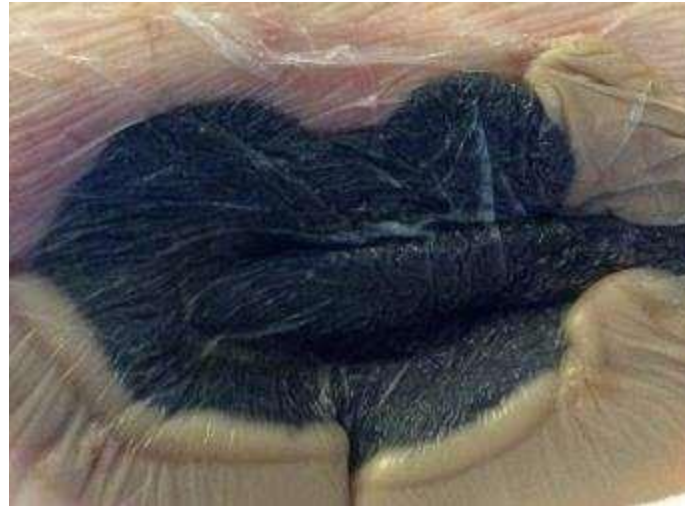Images courtesy of Kara Couch. Used with permission

Fluorescence Imaging and NPWT

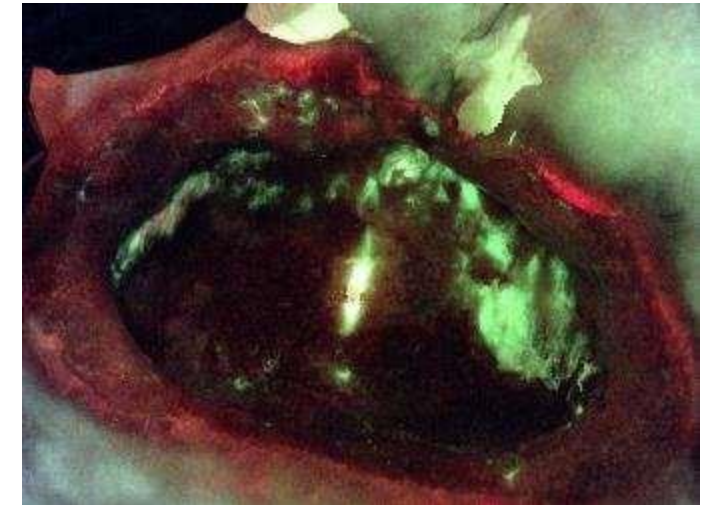
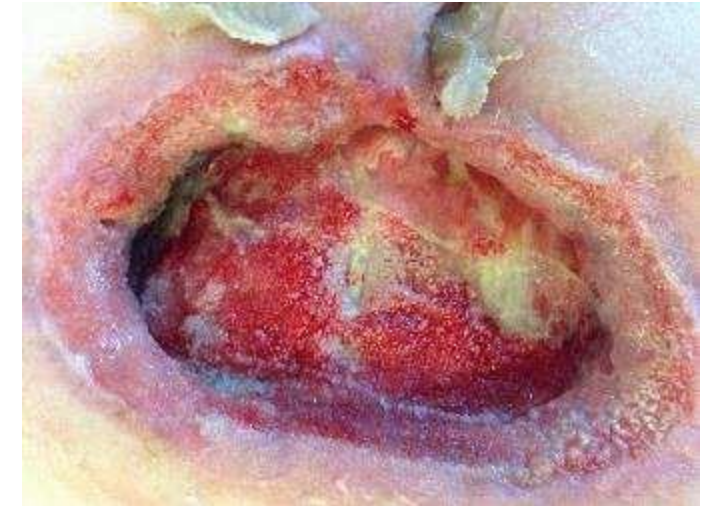Sacrum pressure ulcer

- Detection of red bacterial fluorescence after 2 days prompted an earlier dressing change and a switch to an instillation NPWT device

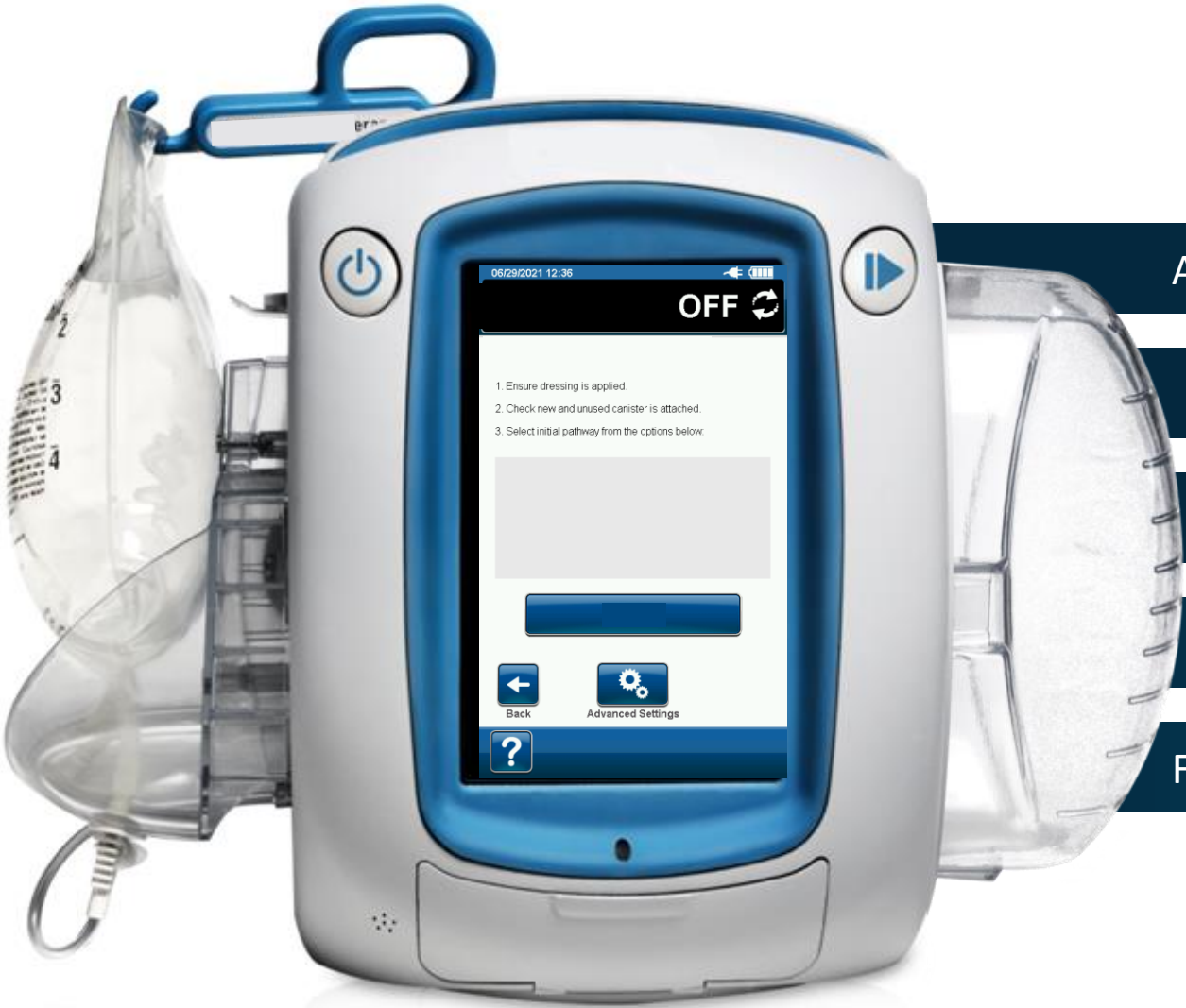Standard NPWT device
under dressing



Wound bed



Benefits of Smart Software



Automatically determines volume to instill

Automatically instills topical solution after clinician confirmation

Helps prevent or reduce over/under filling of dressing

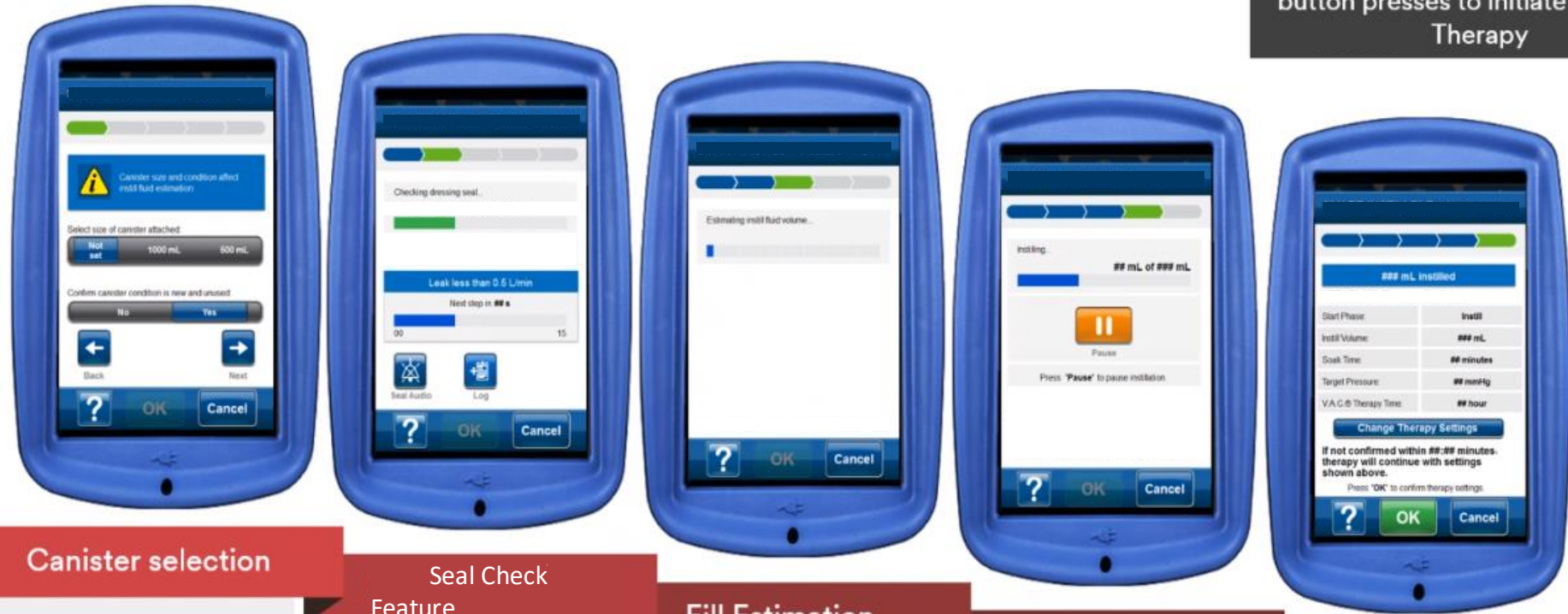
Default therapy cycle recommended by global advisory panel

Feature for manual customization

Therapy Initiation Steps

1 decision and 2 button presses to initiate therapy

1 decision to make and 2 button presses to initiate Therapy



Therapy Initiation Step

Canister selection

Seal Check Feature

Fill Estimation

Instillation

Confirmation

HCP Decision

1. Choose canister (500ml or 1000ml)

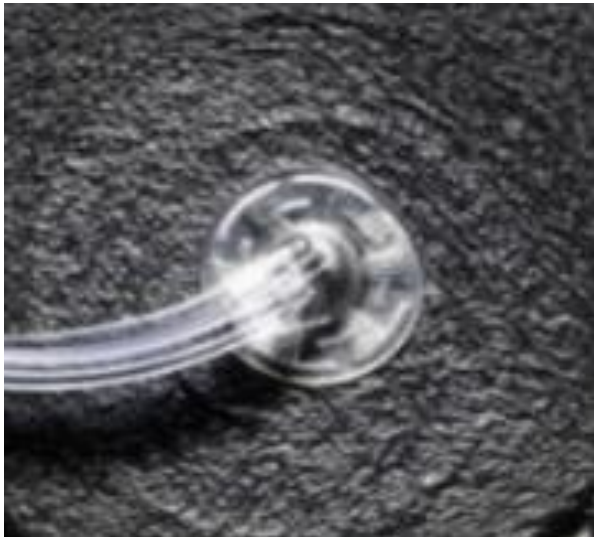HCP Action

1. Select canister size
2. Confirm canister is new

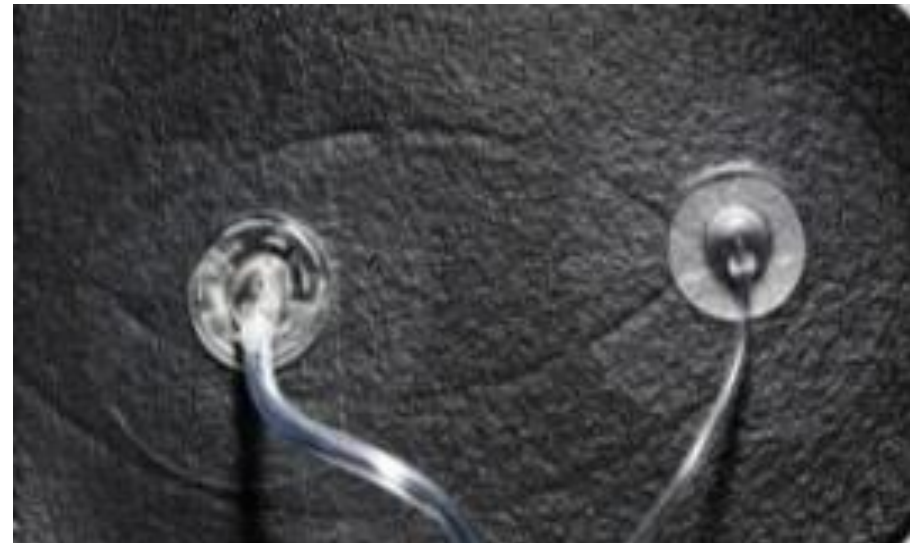Clinical Pearls

Let's Talk Ports for Fluid and Exudate Removal

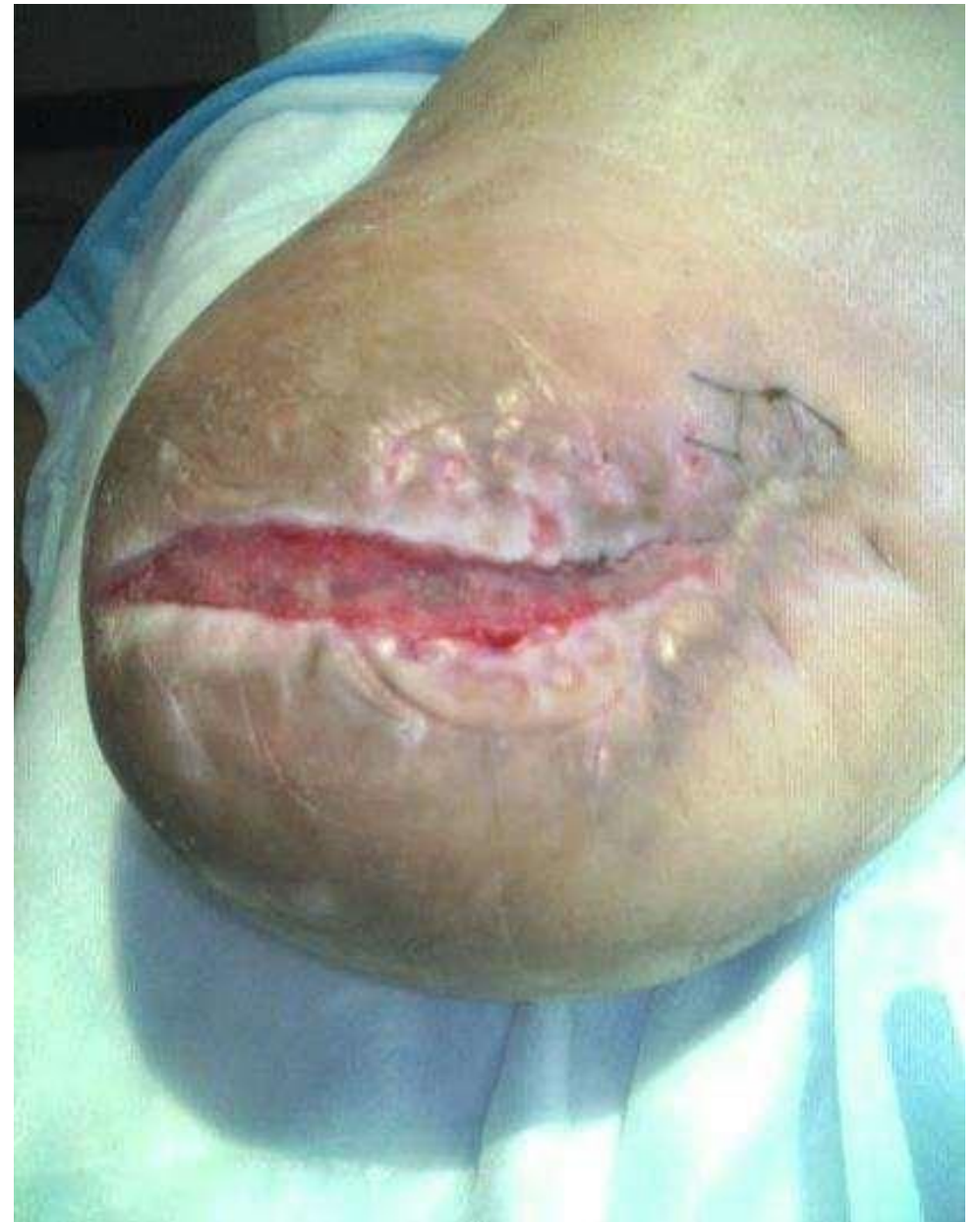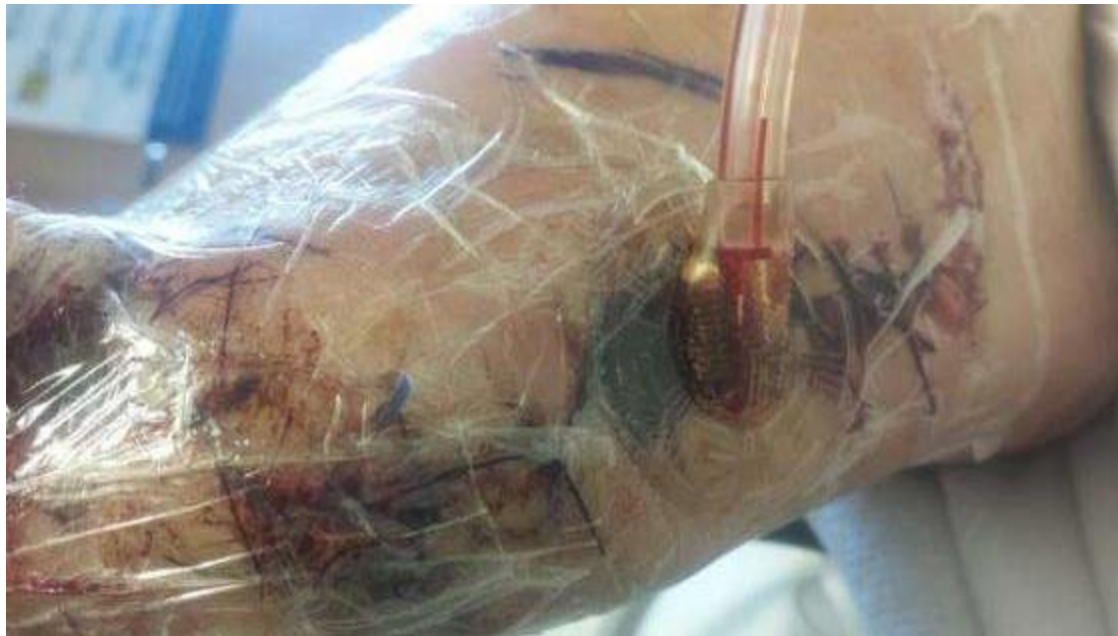Negative Pressure
Single-Lumen Port



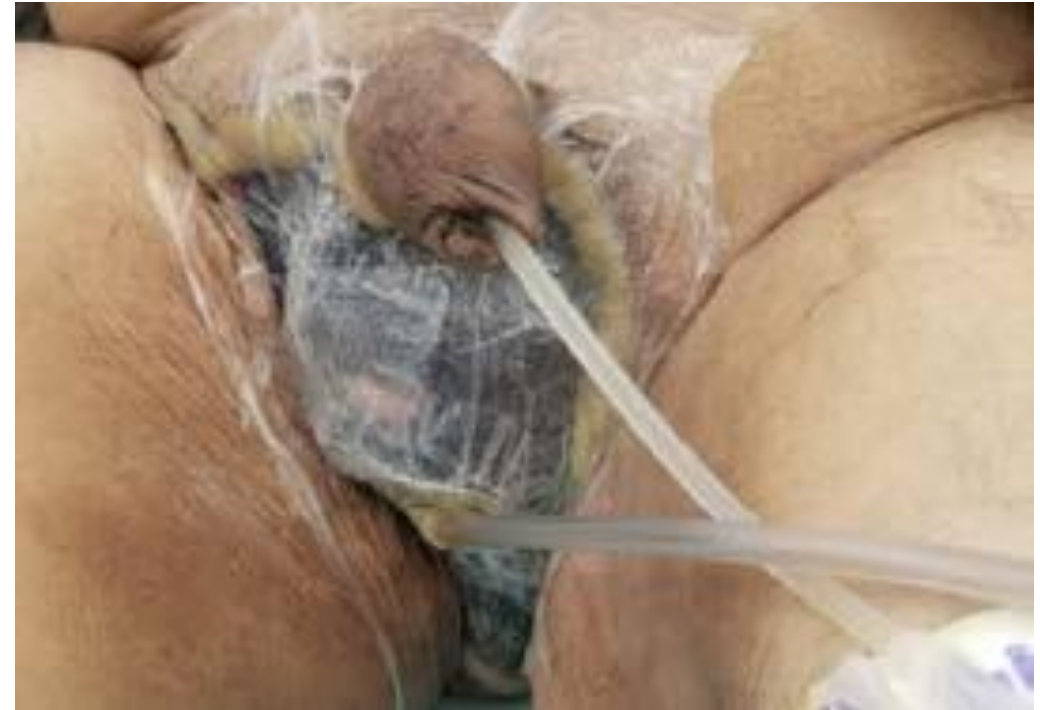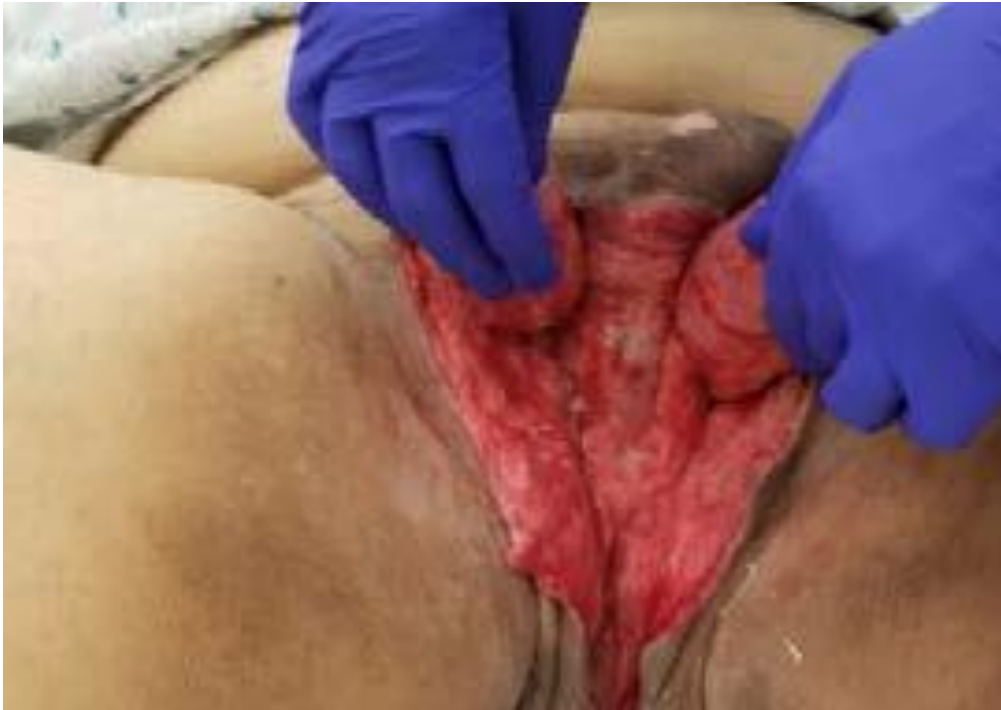Negative Pressure
Dual Port



Don't Be That Guy...



Application on Scrotal Wounds Can Be Challenging



The use of barrier rings and shingling drape application may help obtain a good seal

Use Your Toolbox!



Pastes and Barrier Products

Eakin Cohesive [®] Skin Barrier	Eakin Cohesive [®] Seal
Stomahesive [®] Strips and Paste	Adapt [™] Barrier Ring and Strips
Flextend [™] Skin Barrier	Adapt [™] and Karaya [™] Paste
Brava [®] Moldable Rings and Strip Paste	Brava [®] Elastic Barrier Strips
Coloplast Skin Barrier Rings	Brava [®] Paste
Securi-T [®] Conformable Seal and Skin Barrier	TRIO SILKEN [®] Silicone Stoma Gel

Cohesive is a trademark of T.G. Eakin Limited. Stomahesive is a trademark of E.R. Squibb & Sons, Inc. Flextend and Adapt are trademarks of Hollister Incorporated. Brava is a trademark of Coloplast A/S Corporation. Securi-T is a trademark of Genairex, Inc. Trio Silken is a trademark of Trio Ostomy Care US.

Skin Protection

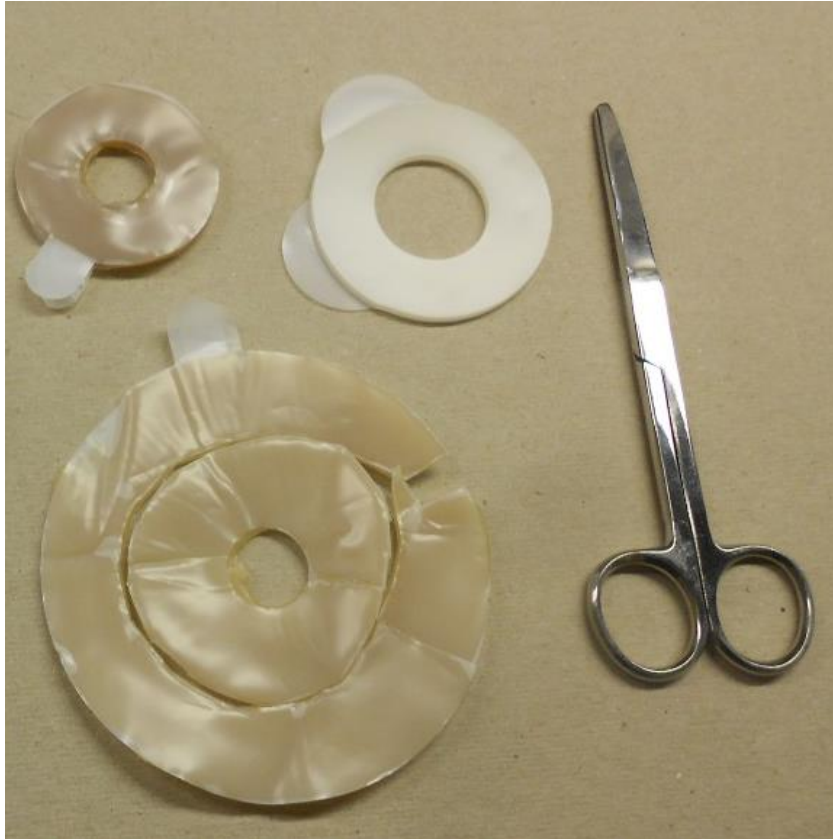


Photo courtesy of Mary Anne Obst

- Ostomy barrier rings
- Polymer-cyanoacrylate
- **Good scissors!**





Polling Question

Can NPWT modalities be changed during the course of treatment?

- A. Yes
- B. No

***Polling was pre-recorded.**



Polling Question

What are contraindications to using NPWT?

- A. Poor hemostasis
- B. Active tumor
- C. Unexplored tunnels
- D. Exposed organs
- E. All of the above

***Polling was pre-recorded.**

Science and Clinical Application of Novel Peel and Place Dressing

Ralph Napolitano, Jr., DPM, CWSP, FACFAS

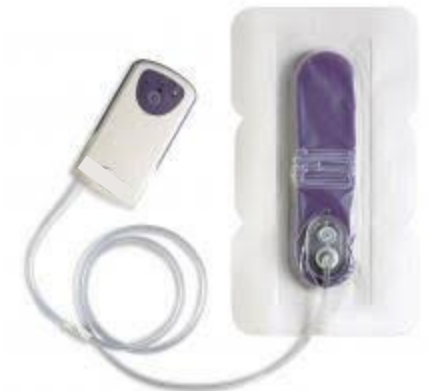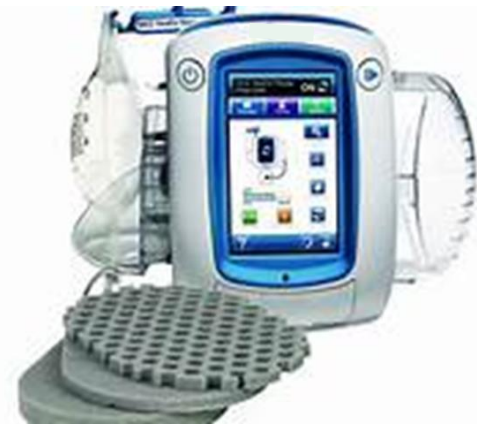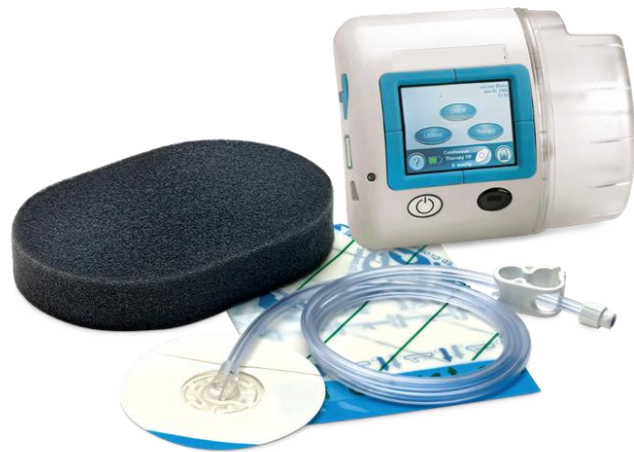Director, Wound Care and Healing – OrthoNeuro, Columbus, OH

Adjunct Clinical Assistant Professor, Department of Specialty Medicine –
Ohio University Heritage College of Osteopathic Medicine, Athens, OH

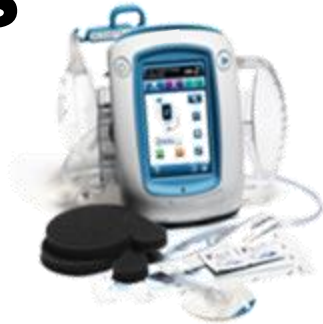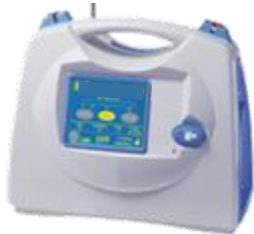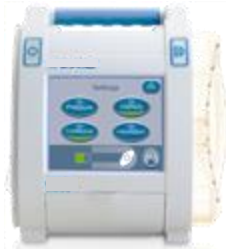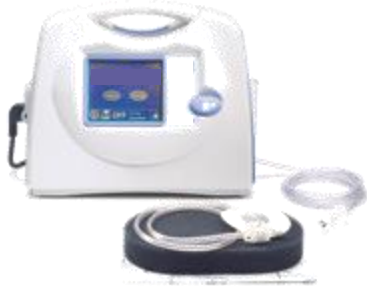IMPORTANT NOTE TO REMEMBER...

Many of the same principles apply to NPWT and NPWTi-d!
...And some principles apply to disposable MP-NPWT and ciNPT, as well!

***This commonality aids greatly in transition across all care settings**



NPWT through the Years



1995

2002

2005

2006

2016



Clinical field trials in Operation Desert Storm prior to V.A.C. Classic



Hurricane Katrina



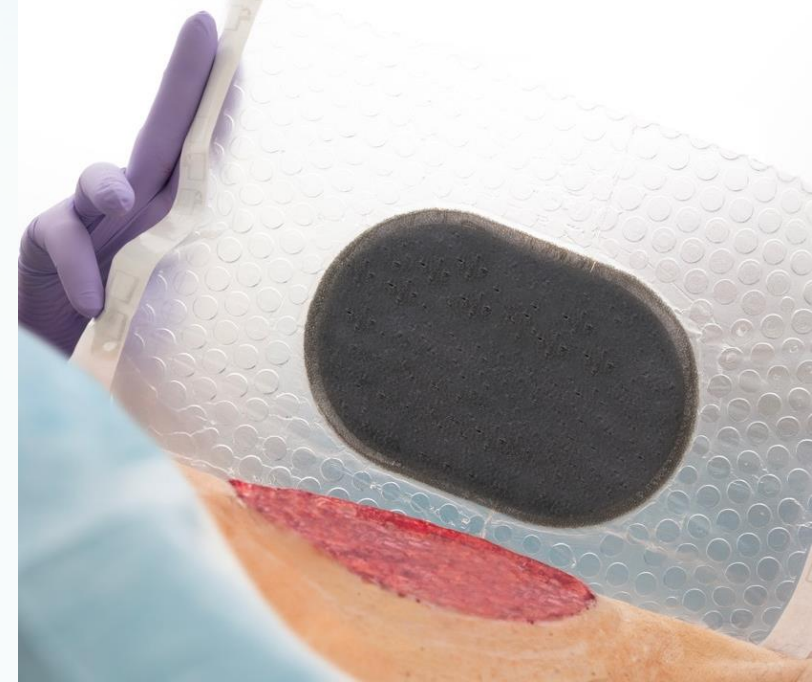
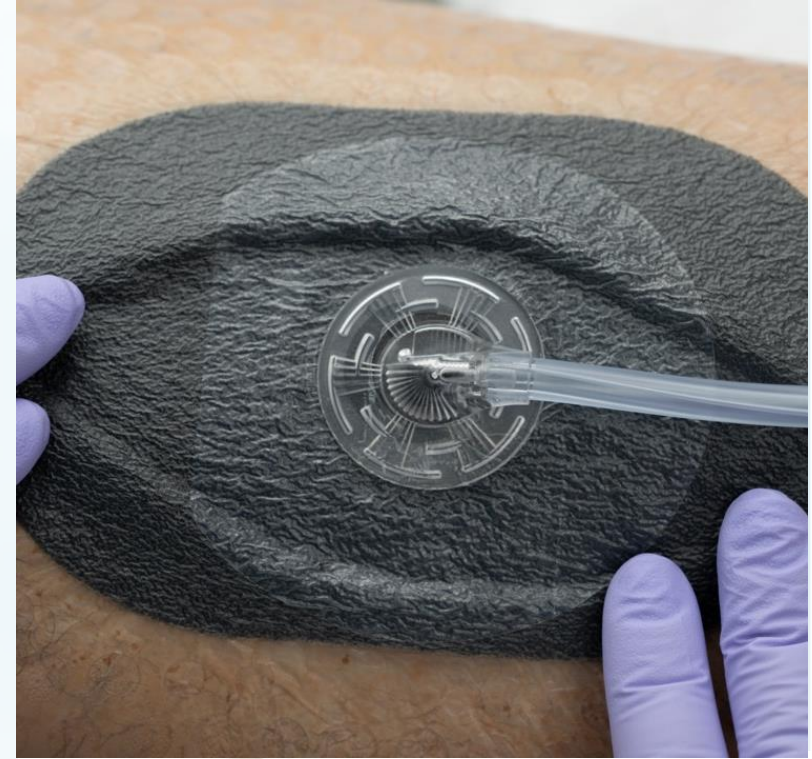What's Next



Peyton Manning leads the Broncos to victory in Super Bowl 50 then retires

Peel and Place Dressing

- Extended wear time up to 7 days
- NPWT from hospital to home
- Ease of application helps to effectively maintain treatment



Bring NPWT to More Patients

FROM

TO

Multiple dressing components

All-in-one, integrated design

Frequency of dressing changes (3/wk)

Up to 7 days of wear time

Need to cut foam to conform to wound bed

No cutting, ready to apply in <2 min¹

Drape maneuverability issues

Repositionable upon initial placement

Separate steps for placement of single layer of non-adherent material

Integrated single non-adherent layer

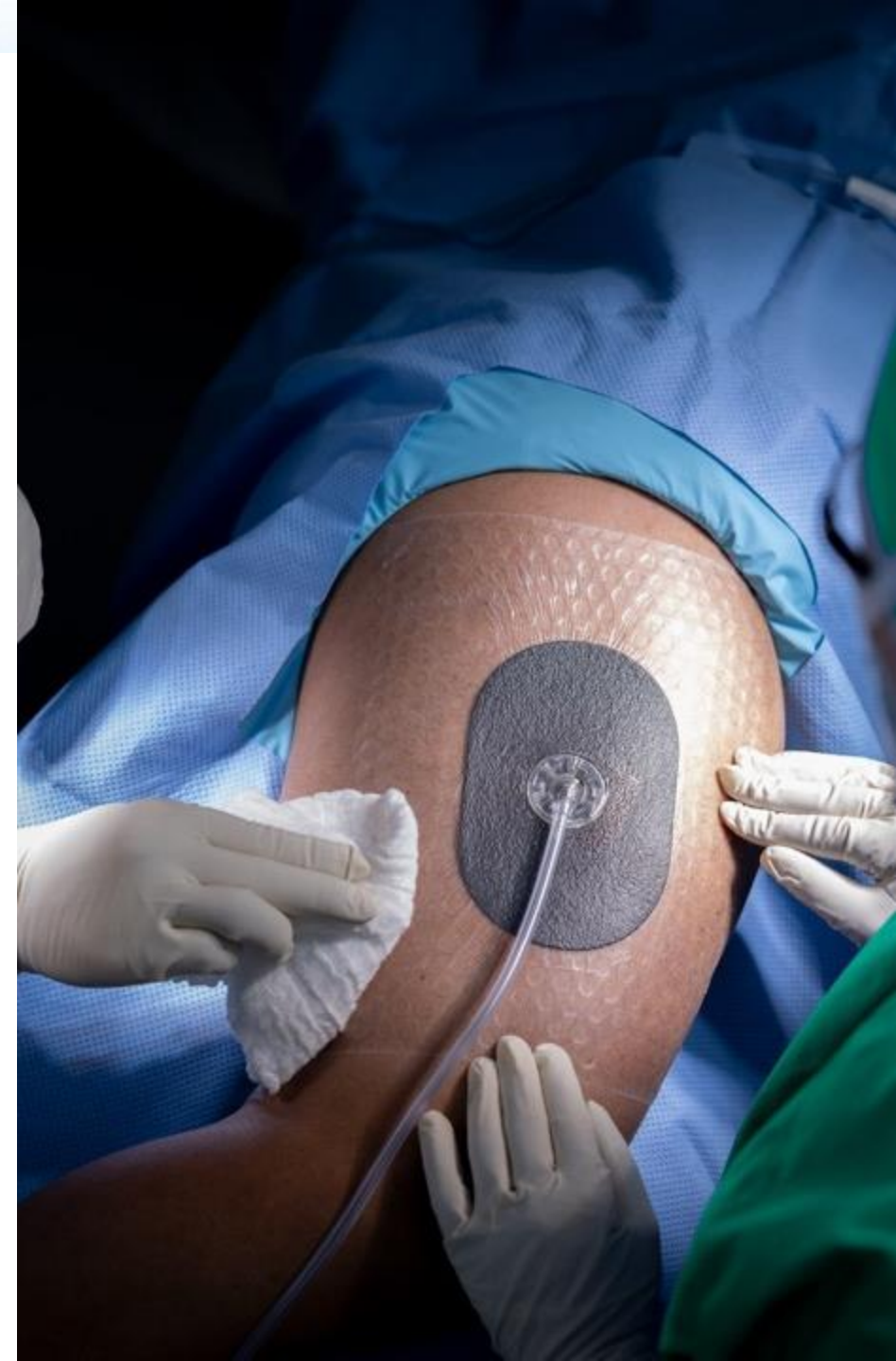
Need to cut hole for trac pad

Pre-cut hole for consistent application

1. In a simulated use test with 12 nurse and surgeon users. Average time of 01:48.

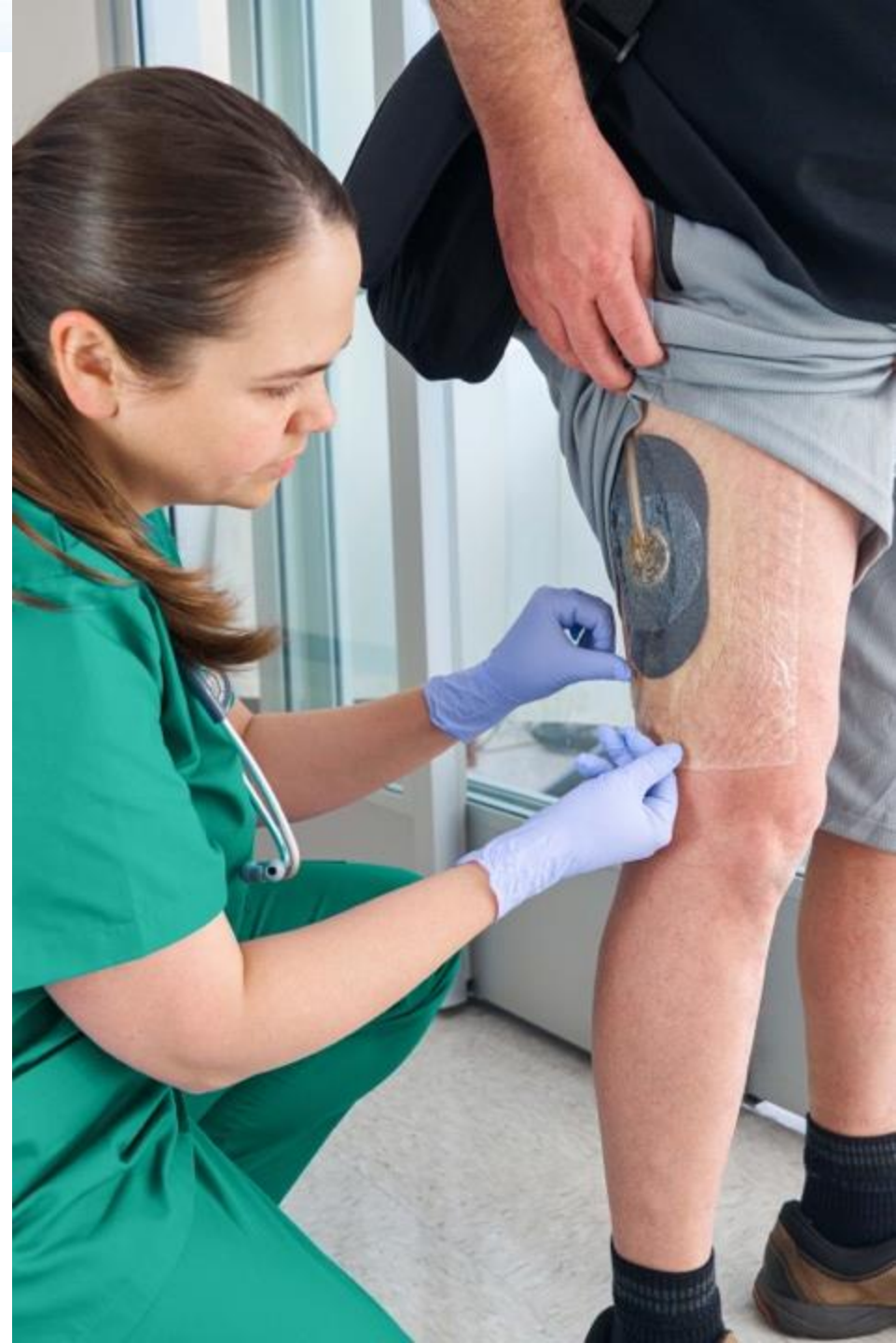Acute Care

- **Up to 7-day wear time** allows critical staffing and resource flexibility while effectively maintaining NPWT
- **All-in-one design** streamlines application and reduces staff training; staff across skill levels can perform dressing changes
- Covers entire wound and surrounding tissue for **less than 2-min application** on average, saving time in the OR
- Faster dressing applications may **reduce costs** for procedures taking place in the OR



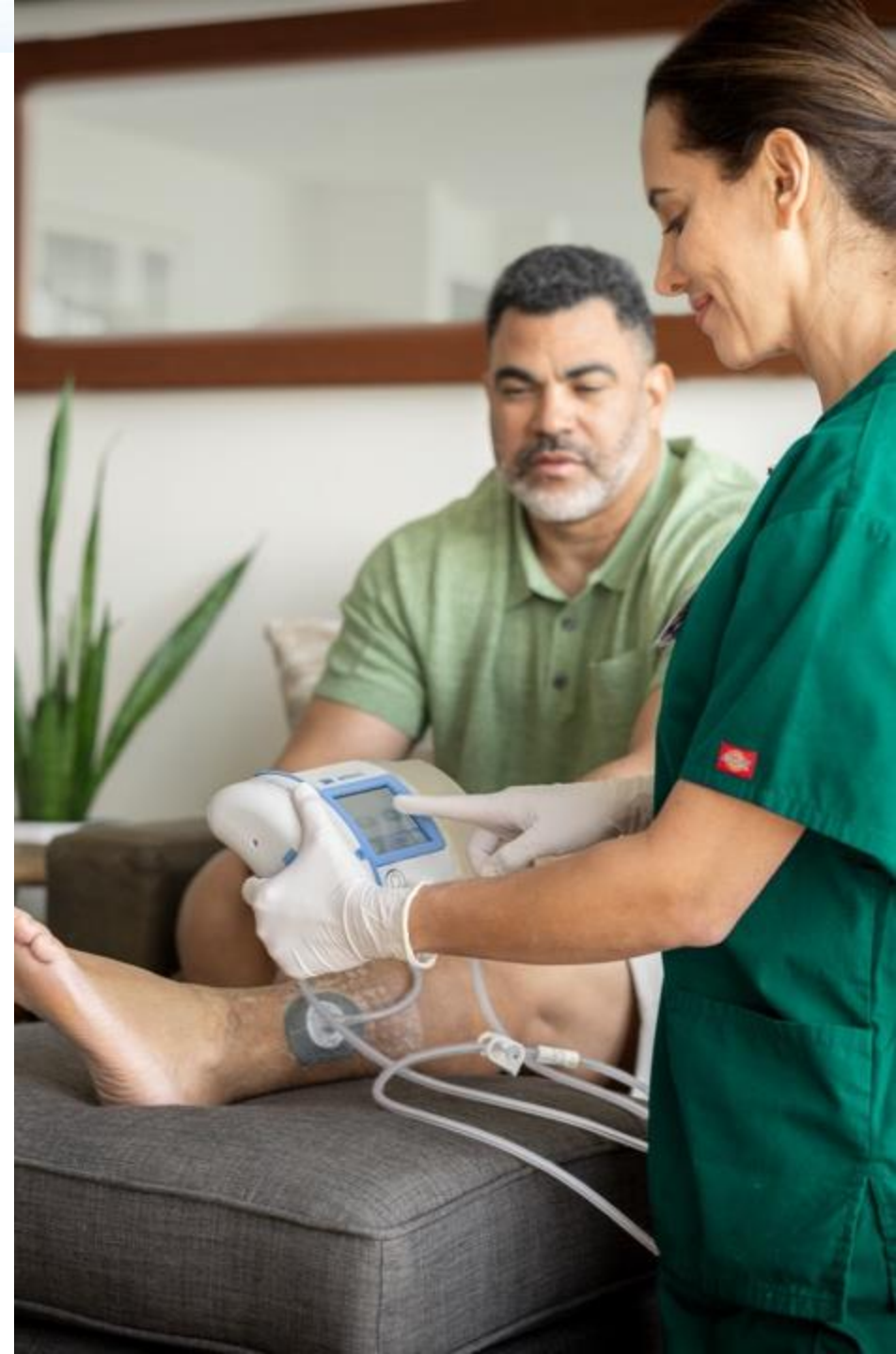Wound Clinics

- **Up to 7-day wear time** provides opportunity for wound clinic patients who are not eligible for home health visits to benefit from NPWT
- **Nurses** surveyed rated the dressing as **easy to use**
- Less than 2-min average application time is significantly faster
- Available at **no additional cost for at-home patients**; billed to patient's insurance under same code as other NPWT dressings

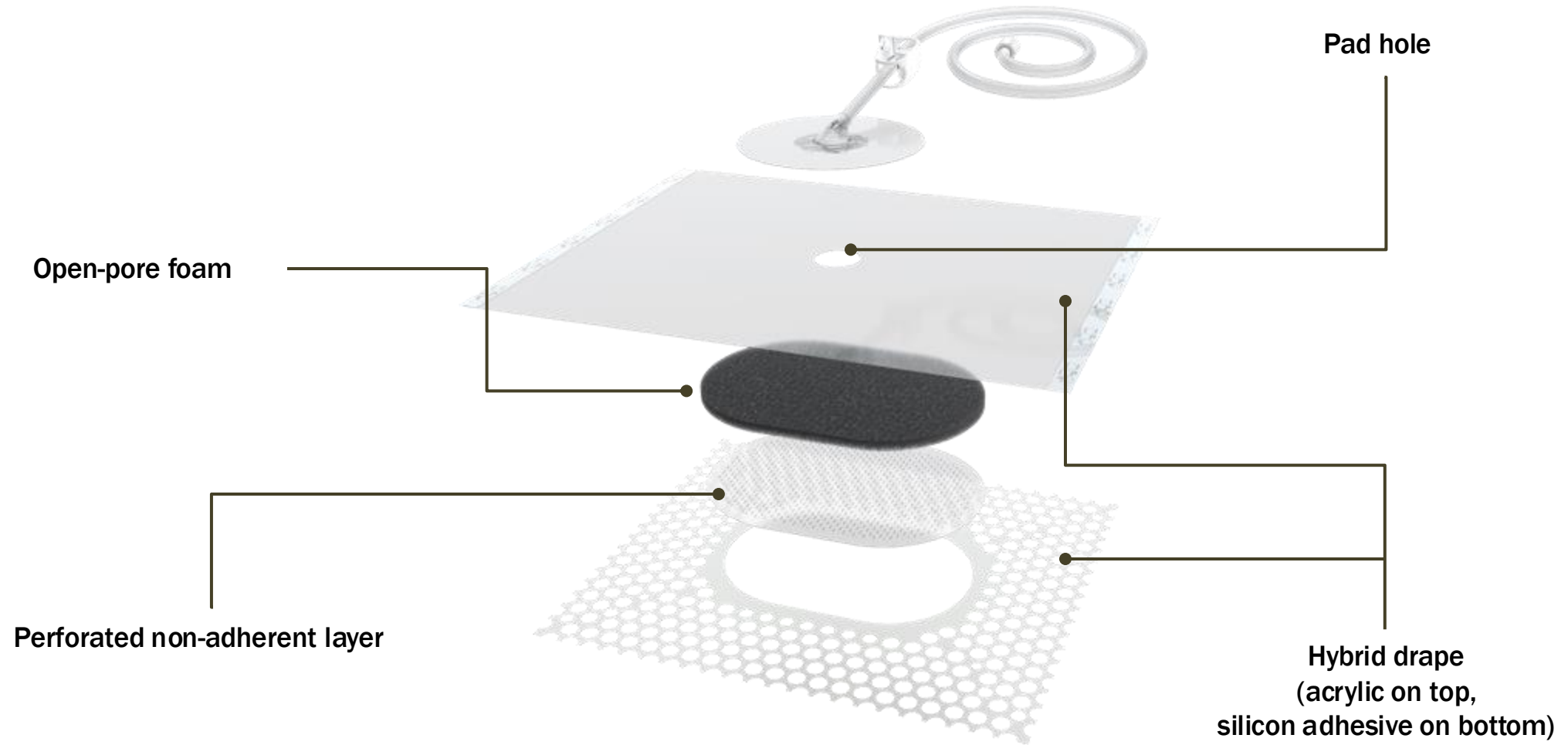


Home Health

- 3x the wear time; 1/3 of the nursing visits
- Can reduce number of nursing visits
- Fewer dressing changes mean home health agencies could **manage more patients per month** that require NPWT
- **Easier application** for clinicians who may not have experience applying NPWT on more complex wounds
- Available at **no additional cost for at-home patients**; billed to patient's insurance under same code as other NPWT dressings




All-in-One Design



The Bottom of the Dressing


Perforated, non-adherent bottom layer allows up to 7 days of wear by mitigating tissue ingrowth and reducing foam adhesion to the wound and pain upon removal.



Mechanism of Action (MOA) Overview

Used in conjunction with NPWT unit, peel and place dressing promotes wound healing by:

- Removing exudate and infectious materials
- Reducing edema
- Promoting granulation tissue formation and perfusion
- Preparing the wound for closure

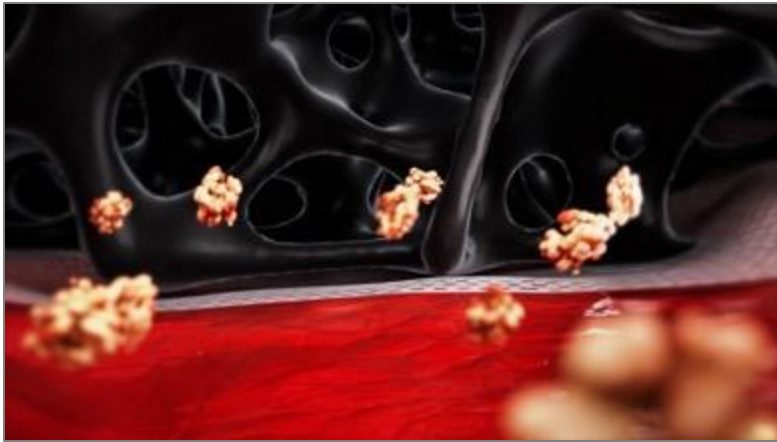


Artistic rendering.

Use an alternative V.A.C.® Therapy Dressing for wounds with tunneling, undermining greater than two centimeters, or depth greater than six centimeters.

MOA: Macrostrain


Macrostrain facilitates removal of exudate that may inhibit wound healing and assists in reduction of edema, facilitating blood flow into the wound bed by providing oxygen and nutrients for healing.



Facilitates removal of exudate and infectious material



Facilitates blood flow into the wound bed, which provides oxygen



Enables perfusion to the wound bed

MOA: Microstrain

Finite element analysis suggests that peel and place dressing induces microstrain at the wound bed surface, but also more deeply in the underlying and surrounding soft tissue.

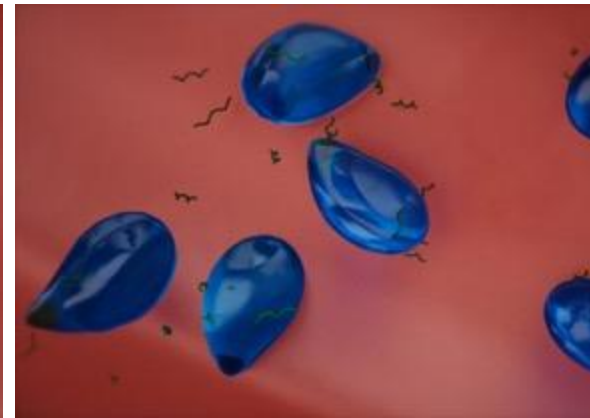
Pre-clinical studies demonstrated increased key biomarkers indicative of pro-wound healing*




Deep tissue
micro-deformation



Stimulates
cellular activity



Increase biomarkers
indicative of
pro-wound healing



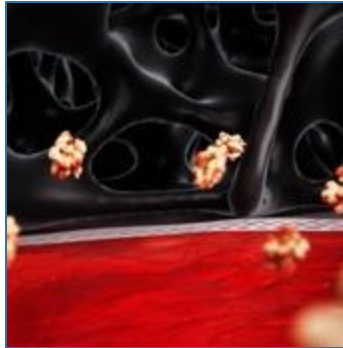
Mechanical forces extend
beyond the wound bed

* In porcine model on open wounds. Information contained within conducted animal studies has not been evaluated on humans.


MOA

Macrostrain


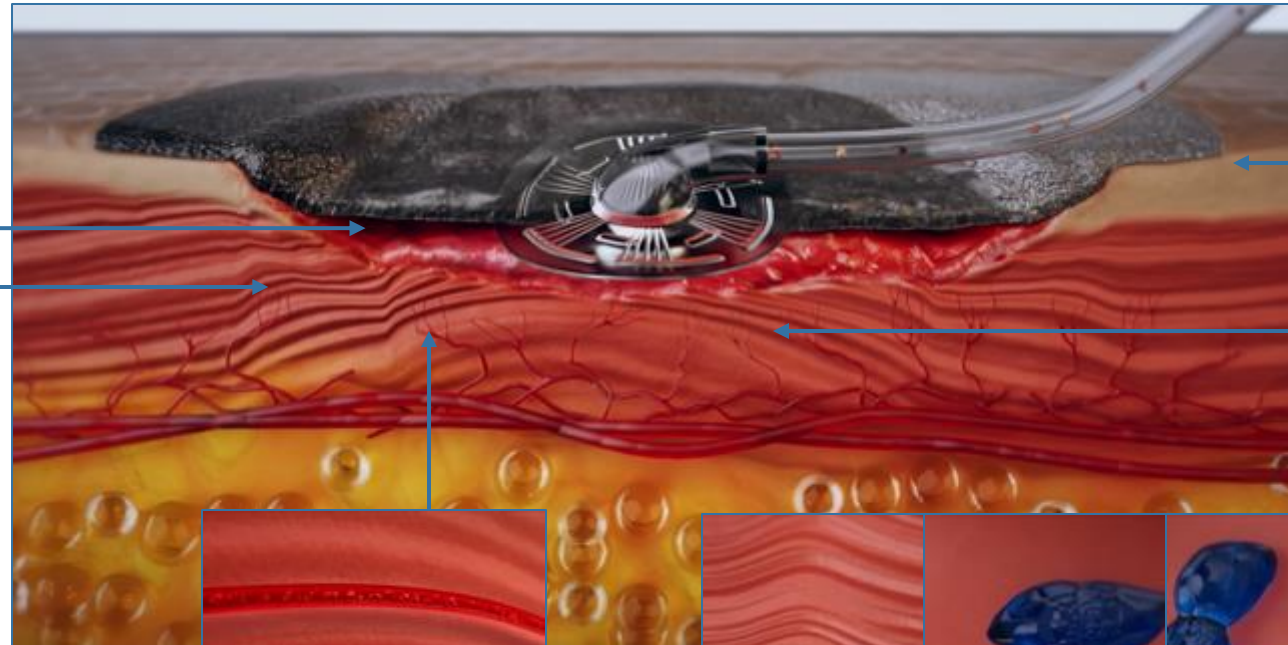
Microstrain




Removes exudate and infectious material




Reduces edema



Mechanical forces extend beyond the wound bed



Promotes perfusion



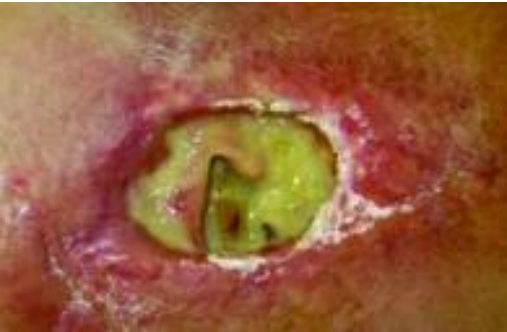Deep-tissue micro-deformation

Stimulates cellular activity

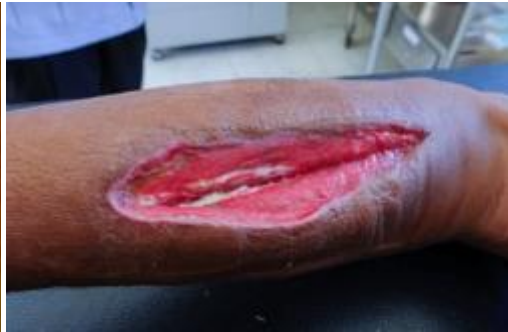Increase biomarkers indicative of pro-wound healing

Wound Types that Benefit from Peel and Place Dressing

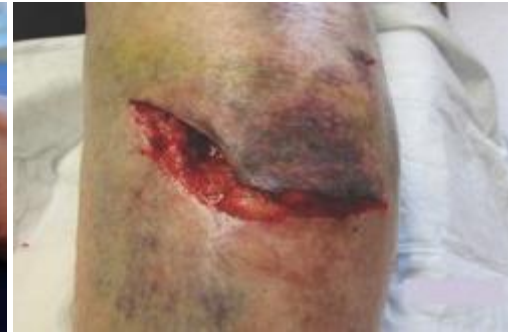Chronic



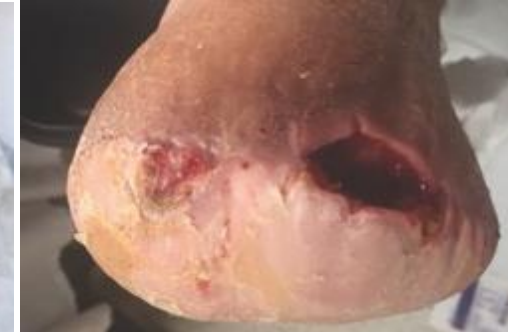Acute



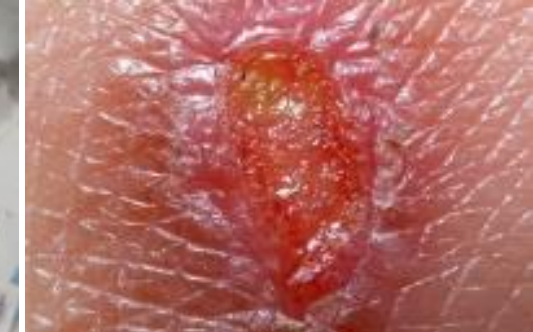Traumatic



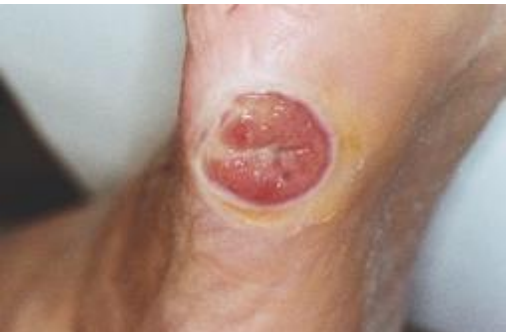Subacute/Dehisced



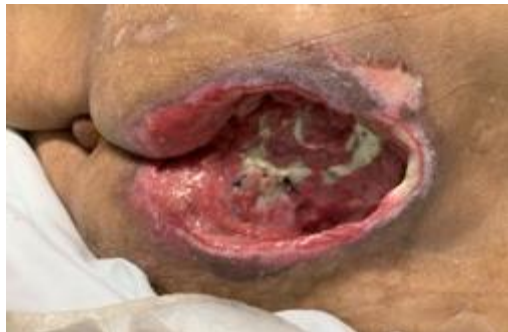Partial-thickness Burns



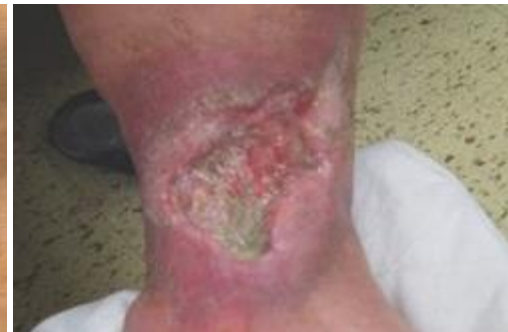Diabetic Ulcers



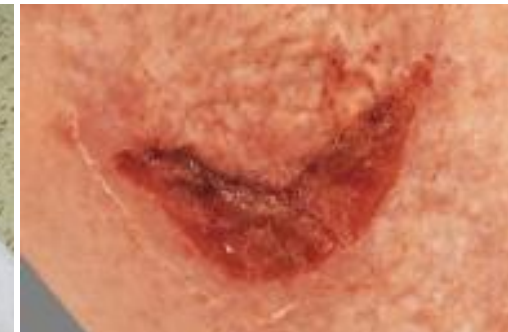Pressure Ulcers



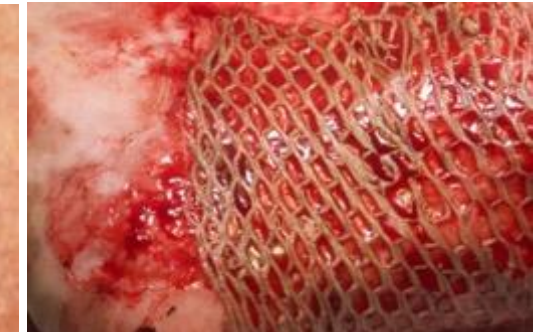
Venous Ulcers



Flaps



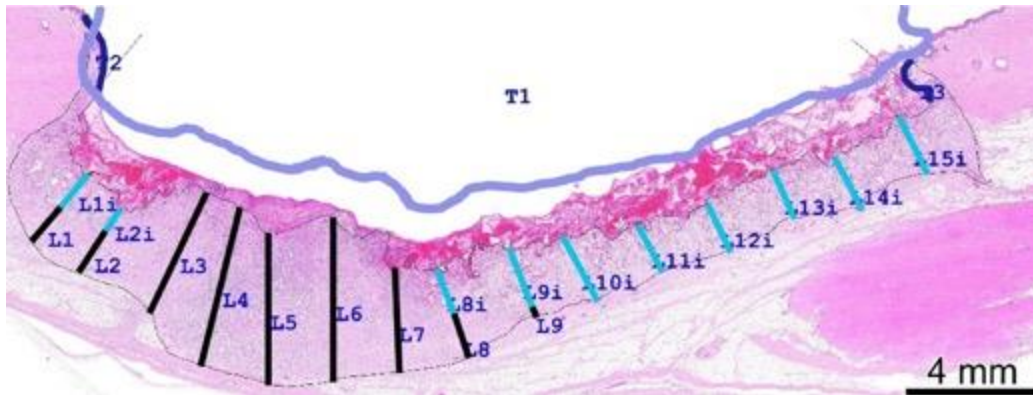
Grafts



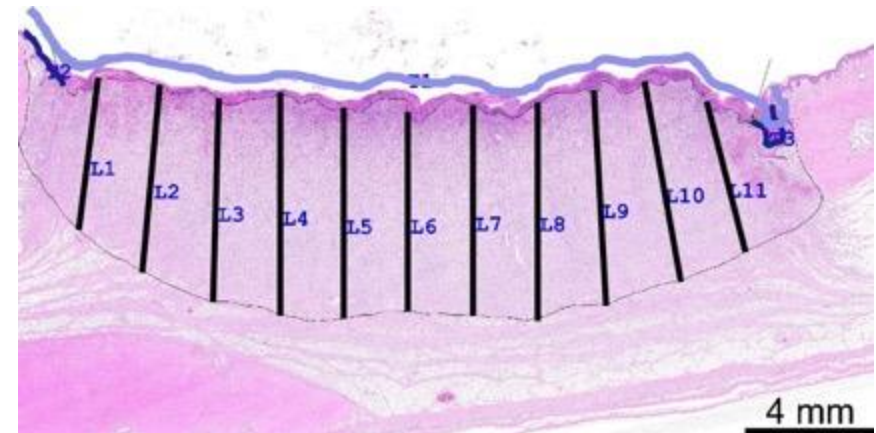
Clinical Benefits Compared to Traditional Foam Dressing

33% greater wound volume reduction*¹

2.4 greater granulation tissue thickness*¹



Percent wound volume fill (mean \pm SEM), n=at least 9



Mean granulation tissue thickness (mean \pm SEM), n=10 or 11

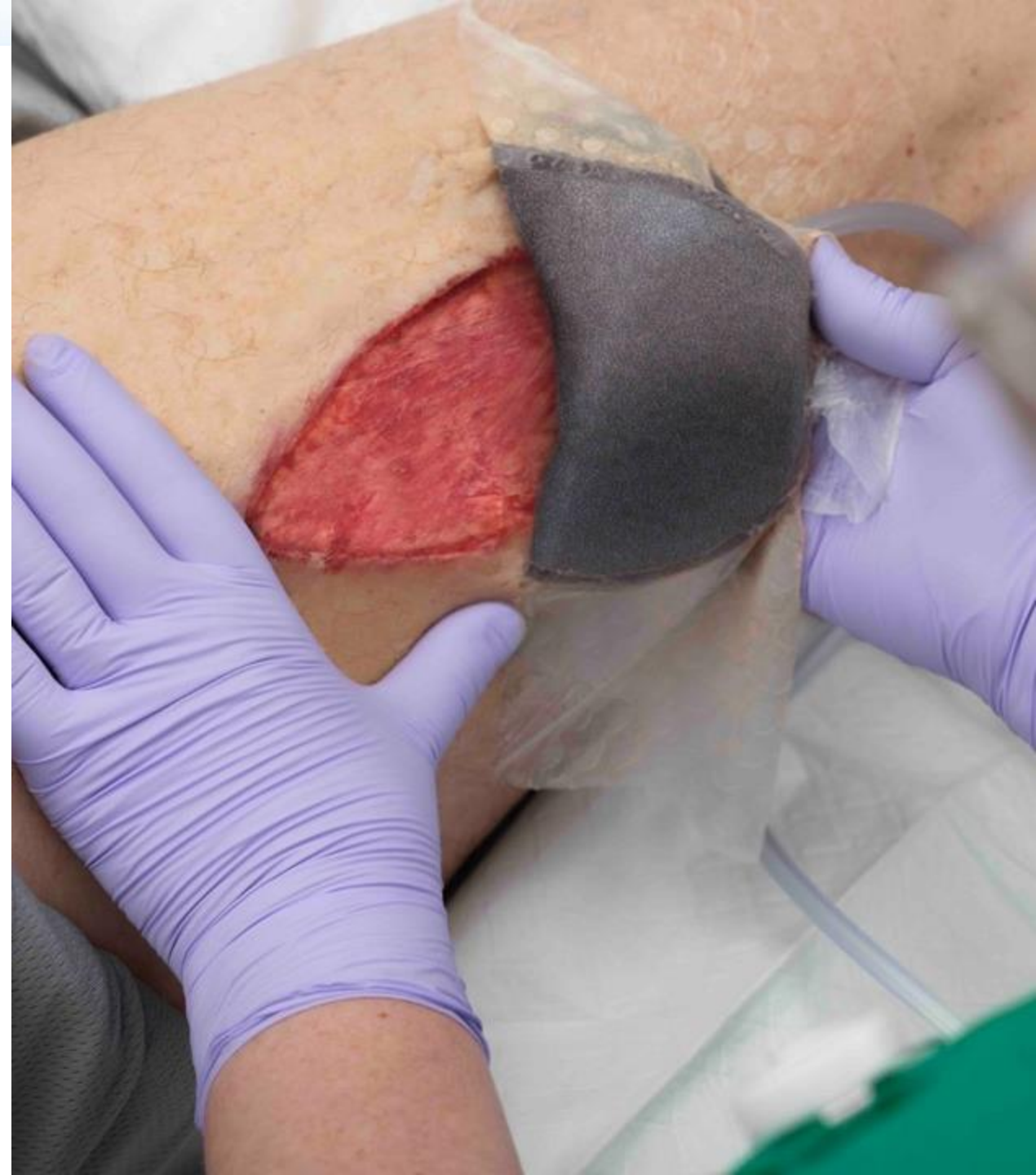What Are People Saying?

Patient experience

Subjects experienced significantly less pain¹ with removal of the incorporated hybrid silicone-acrylic drape than a traditional acrylic drape. 100% of patients surveyed (10/10) **reported no pain on removal²** of the peel and place dressing.

Clinician experience

10/10 nurses surveyed rated the peel and place dressing **easier to use than traditional NPWT foam dressing** and a separate hybrid acrylic-silicone drape.³

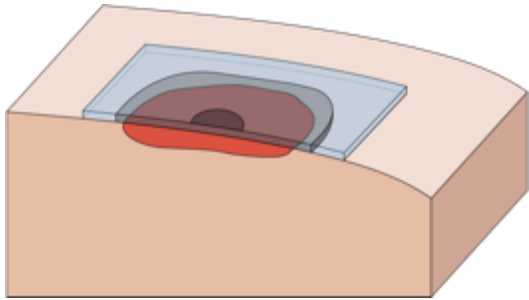


¹ In-person survey (2020): Customer preference test of 10 users providing feedback about their experience in a hospital in Chile. Dressings were worn between 4 and 7 days before removal. ² SAT-DOC-0000052106. 8005 Ganymede Customer Preference Test Post Market Customer Survey Report. 2021.³ In a simulated use test with 12 nurse and surgeon users where the average rating was 5.8 out of 7 on a 7-point Likert scale, compared to reticulated open cell foam and a separate hybrid acrylic and silicone drape where the average rating was 4.6 out of 7 on a 7-point Likert scale (p=0.02, Wilcoxon signed rank test). 2023.

Where Peel and Place Dressing May Be Appropriate

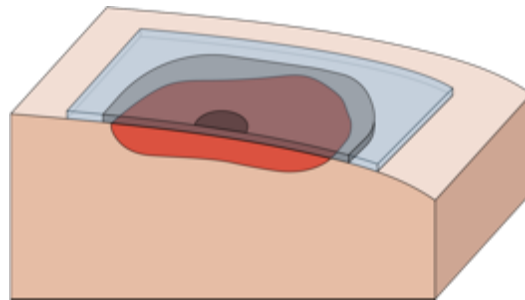
3 sizes to cover a variety of wound depths

Small



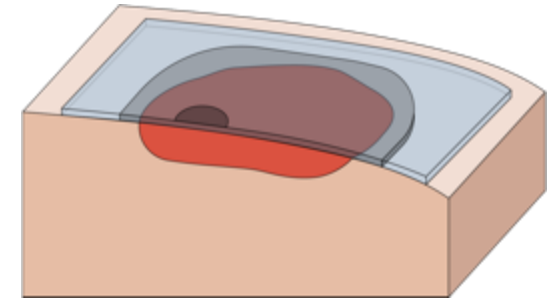
- **Foam:** 6.1cm x 8.6cm
- **Overall Dressing:** 16.9cm x 20.6cm
- **Max Wound Depth:** 2cm

Medium



- **Foam:** 11.1cm x 16.6cm
- **Overall Dressing:** 23.7cm x 29.2cm
- **Max Wound Depth:** 4cm

Large

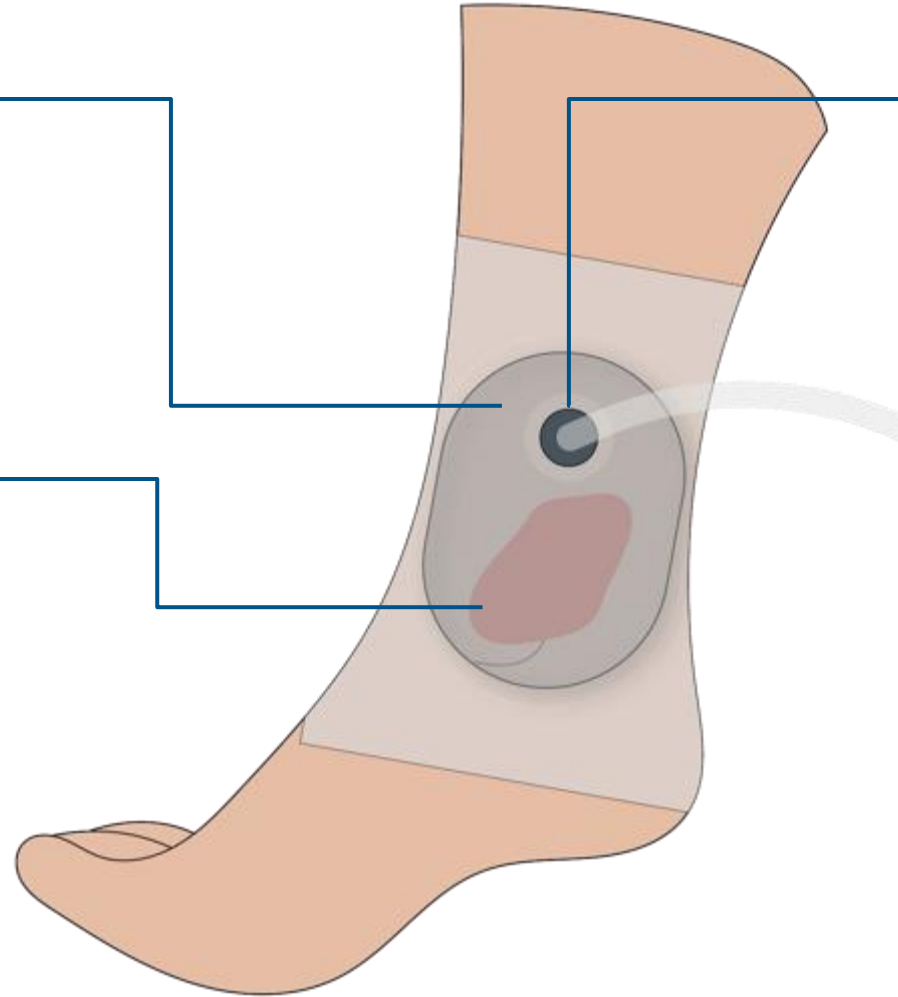



- **Foam:** 13.6cm x 24.2cm
- **Overall Dressing:** 26cm x 35.6cm
- **Max Wound Depth:** 6cm

Considerations

1. Foam should extend beyond wound and touch periwound skin.

3. Undermining must be ≤ 2 cm; no tunneling can be present



2. To offload, select the Large dressing size

4. Don't mix with other dressings. The use of additional foam fillers is prohibited.



Application Tips

No longer need to

- Cut foam to fit wound
- Count and document number of foam pieces
- Pre-drape or windowpane to protect intact skin
- Cut holes

Do NOT

- Use skin barriers/protectants as this may reduce adhesive properties
- Use with other NPWT dressing kits or foams, as they have a shorter wear time
- Push foam portion of the dressing down. Allow the dressing to draw down and conform to the wound bed as negative pressure is applied
- Stretch dressing

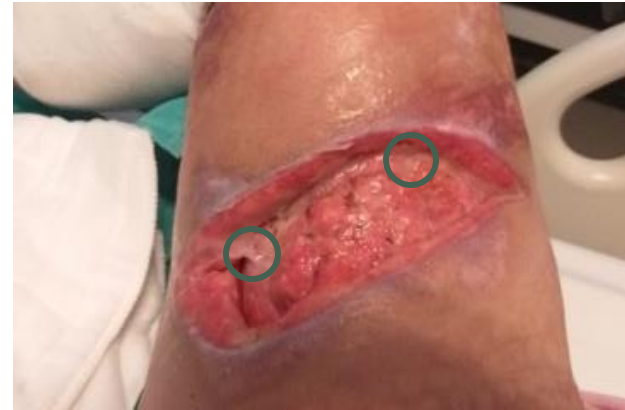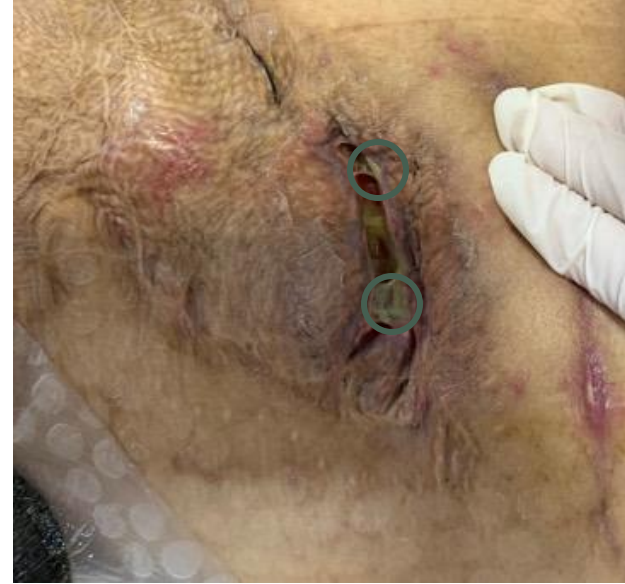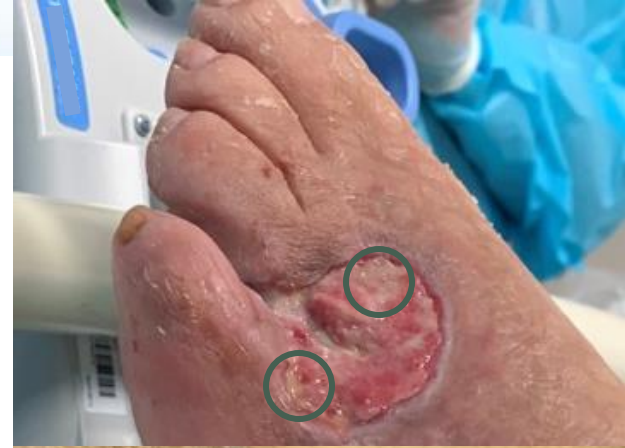Drape tips

- Apply loosely over the wound area
- Leave at least 5cm border of drape whenever possible
- For curved anatomy, slits may be cut in the drape portion of the dressing to help reduce overlap, drape folds, or remove wrinkles

- **The dressing can stay in place when switching between approved NPWT units**
- **Never leave an NPWT dressing in place for more than 2hrs without active NPWT**

Proteinaceous Materials In the Wound Bed

- Upon dressing removal, the wound bed may show some proteinaceous or fibrinous materials. Cleanse the wound according to your facility protocol or clinical order
- In the pre-clinical porcine and Customer Preference Evaluation, the proteinaceous or fibrinous material was not removed. This material was observed to reduce over time with subsequent dressing changes



By design and IFU, we know that this dressing is not for every wound. BUT...

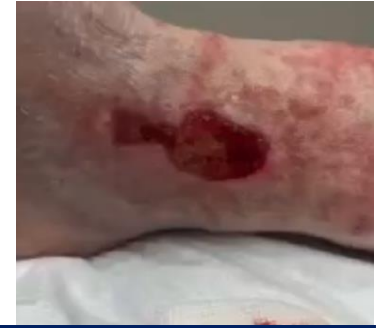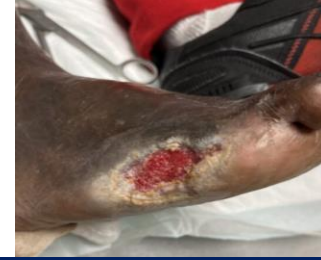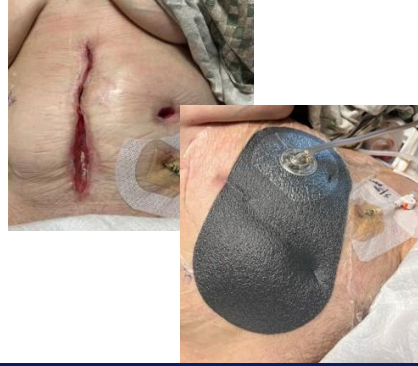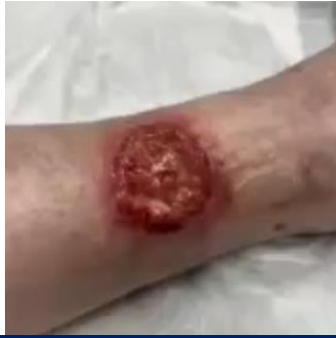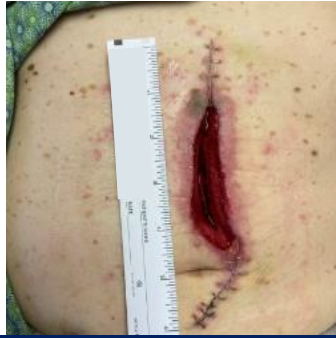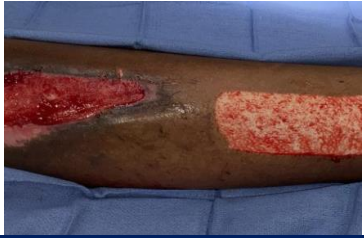We have found it beneficial to consider this dressing for every patient as their wound(s) move through the healing continuum based on trajectory and disposition.

We have also found it occasionally beneficial to step down in dressing size incrementally, or less commonly, step up in size based on trajectory and disposition.

Best Practice: Survey Response Results

- Go for the easy wounds first, where you know application will be simple and the dressing will perform well
- Remember: Wound appearance will be different than with other NPWT dressings
- When in doubt, size up!
- Pay attention to the minimum and maximum wound sizes and depths for each dressing
- Be mindful of narrow and deep wounds; ensure dressing can conform adequately
- Blockage alarms may be noticed due to thinner foam or active bleeding
- Is it maceration, or is it wetness? Consider options for protecting periwound skin, especially if the wound is progressing well. Keep therapy on!
- Adjust the pressure settings up (-150 mm Hg max) if seeing too much fluid in the dressing

Most Ideal Wounds for Initial Dressing Placements



Grafts

Why:

Time savings, including reduced OR time, fewer supplies needed

Dehisced Surgical Wounds

Why:

If only part of the wound is dehisced, can easily cover and treat the whole incision

Less complex wounds

Why:

Help ensure success, not your train wrecks or super complicated placements

Multiple wounds

Why:

Even greater efficiency – dressing can be placed over intact skin between wounds

Wound clinic patients who can't get home health

Why:

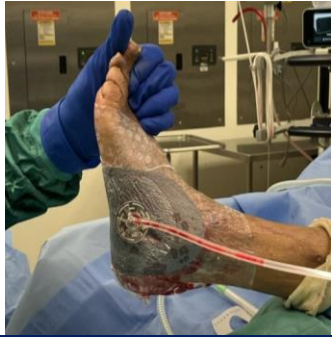Patients can follow up in WCC weekly

Irregular shapes

Why:

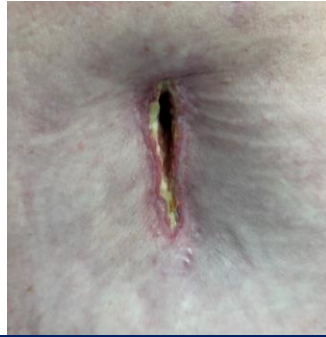Can be placed over intact skin; no need to cut, big time savings

Less than Ideal for Initial Dressing Placement



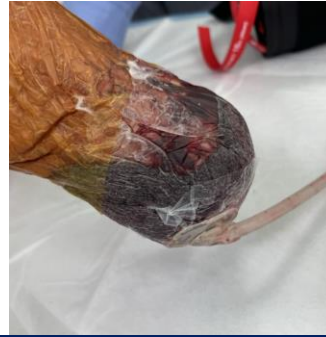High exudate in dependent position

Why:
Exudate sometimes pools and may cause maceration on the skin



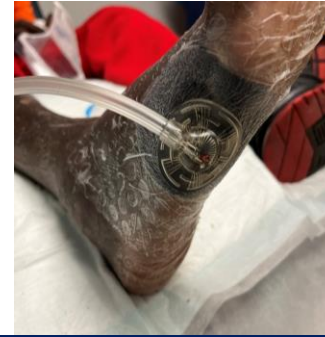Skinny and deep

Why:
Dressing is unable to conform to the bottom of the wound bed and can result in exudate pooling



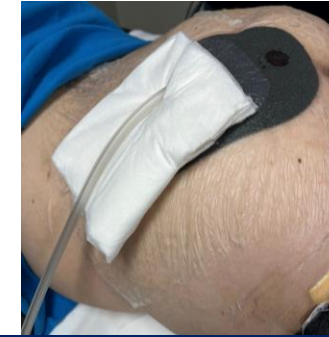Active bleeding or lack homeostasis

Why:
All VAC dressings require hemostasis to be achieved; and may cause blockage



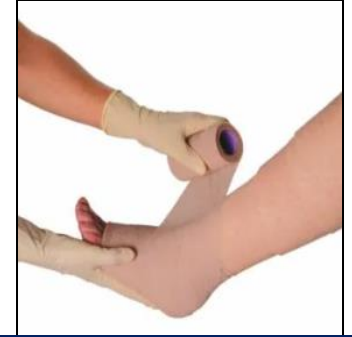DFU with inadequate offloading

Why:
Exudate squeezed out of the tissue may over-wet or macerate periwound skin (eg, bedrest, scooters, etc)



PI with inadequate offloading

Why:
Source of the injury is not addressed, so wound is not likely to progress (eg, turning, positioning, padding, etc)

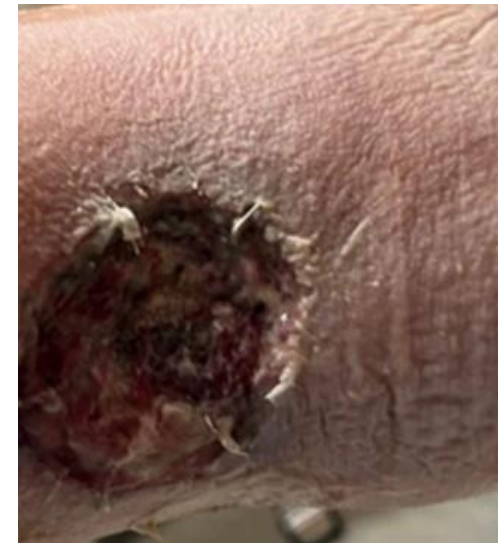
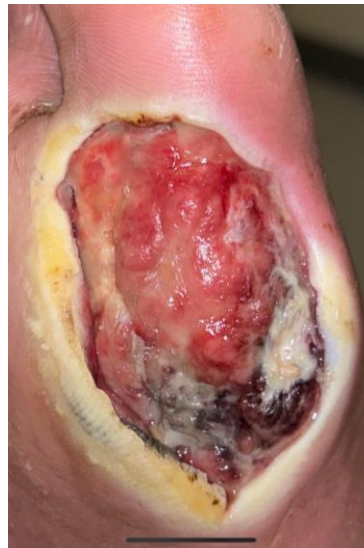
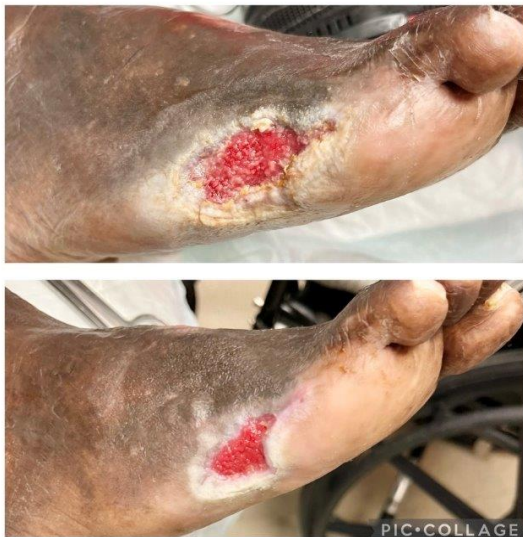Wounds receiving compression

Why:
Not indicated together; compression may lead to reduced exudate removal and maceration or a pressure point

Setting the Right Expectations

- The new goal is wound fill, not color/colour
- Color/colour will be more pink, less red
- There may be some proteinaceous material on the surface
- There may be significant improvement in appearance of periwound tissue
- There may be over-wetting or maceration in periwound tissue
- There may be some temporary tissue distortion under the trac pad
- There may be more odor/odour at 7 days





Polling Question

When considering dressing size for the new all-in-one NPWT dressing, it is better to select the smaller size if “in between” size indications.

- A. True
- B. False

***Polling was pre-recorded.**



Polling Question

The foam layer in the new all-in-one NPWT dressing should not extend past the wound borders.

- A. True
- B. False

***Polling was pre-recorded.**



Polling Question

When applying the new all in one NPWT dressing, leave at least a 5cm border whenever possible.

- A. True
- B. False

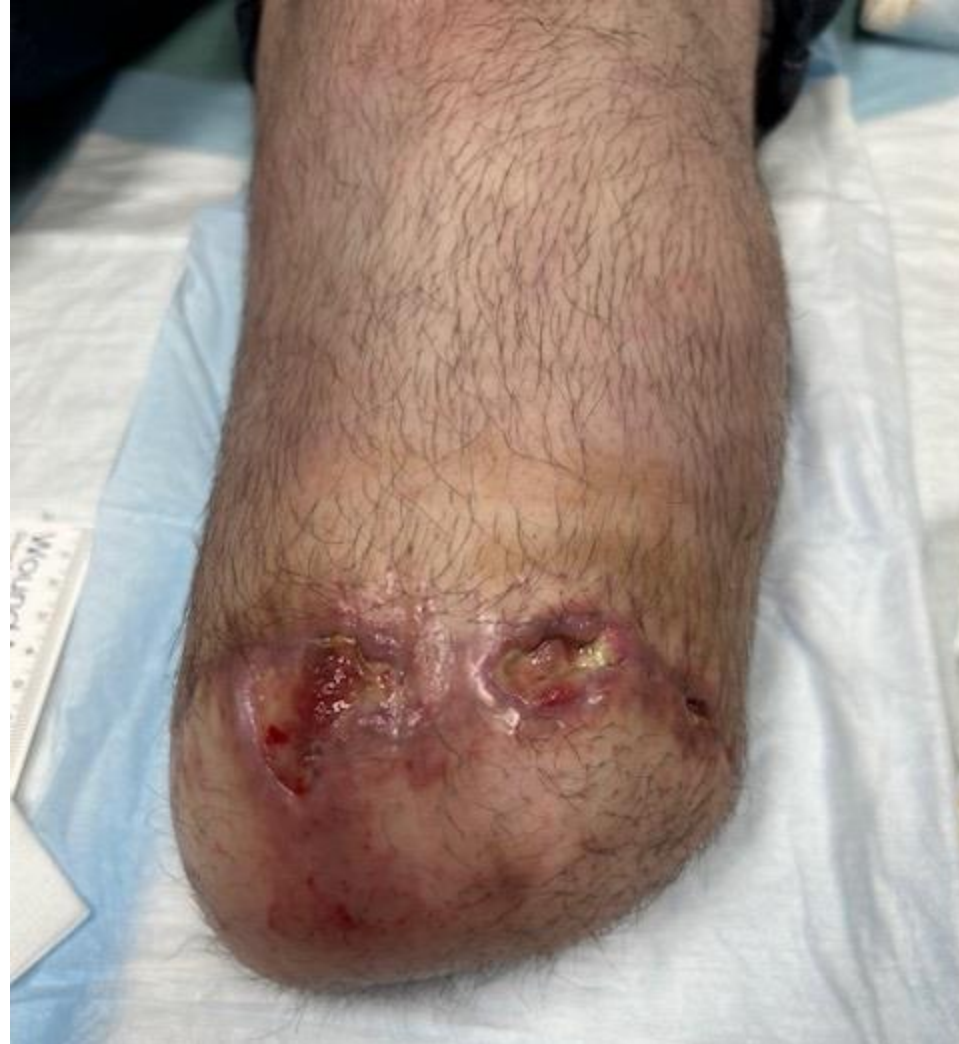***Polling was pre-recorded.**

Case Examples: Peel and Place Dressing

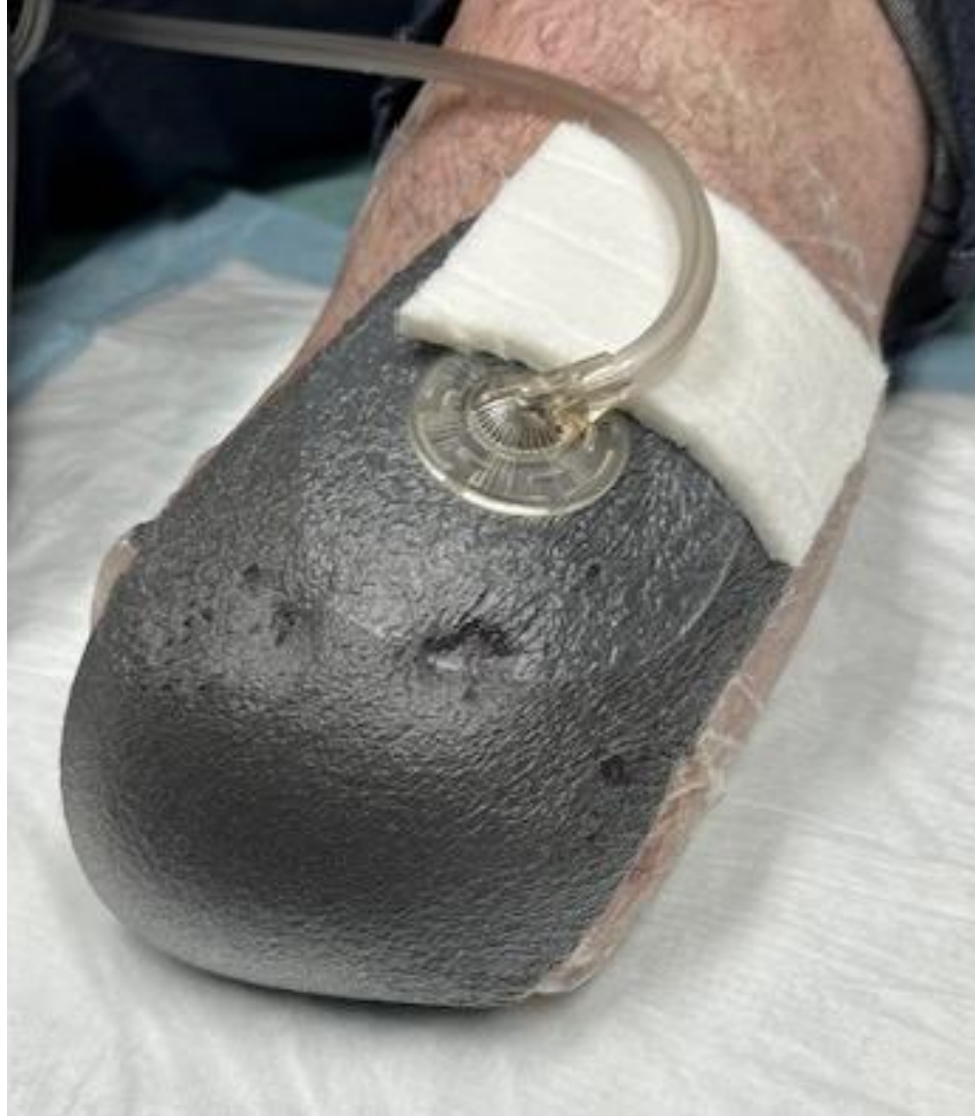Case 1: Below-Knee Amputation Dehiscence

- 28y Male presented to a practice partner with a long history of post-traumatic arthritic deformity of the left lower leg and foot
- Had attempts at reconstruction prior to presentation; ultimately, limb was deemed beyond salvage orthopedically, and a below-knee amputation was elected
- Delayed surgical healing occurred and was sent to me for advanced wound care
- Agreed to VAC therapy with peel and place large dressing at -125 mm Hg

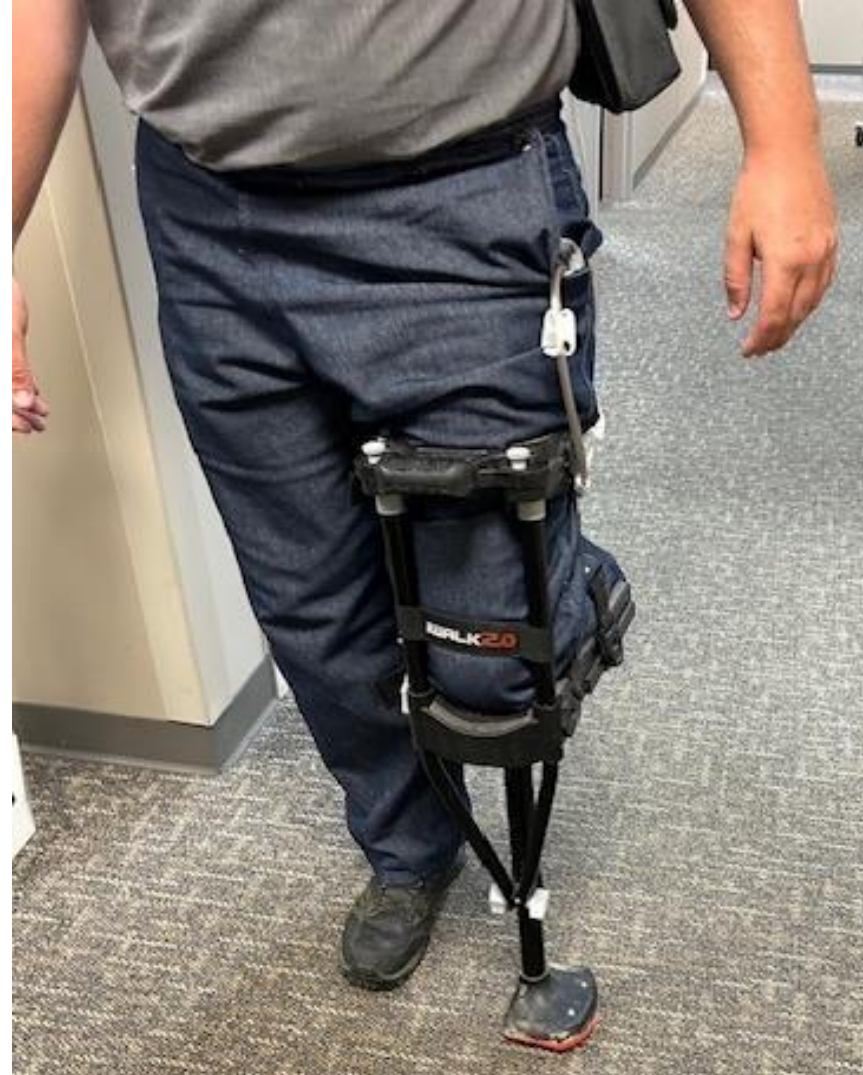Case 1: Initial Presentation



Case 1: Initial Placement

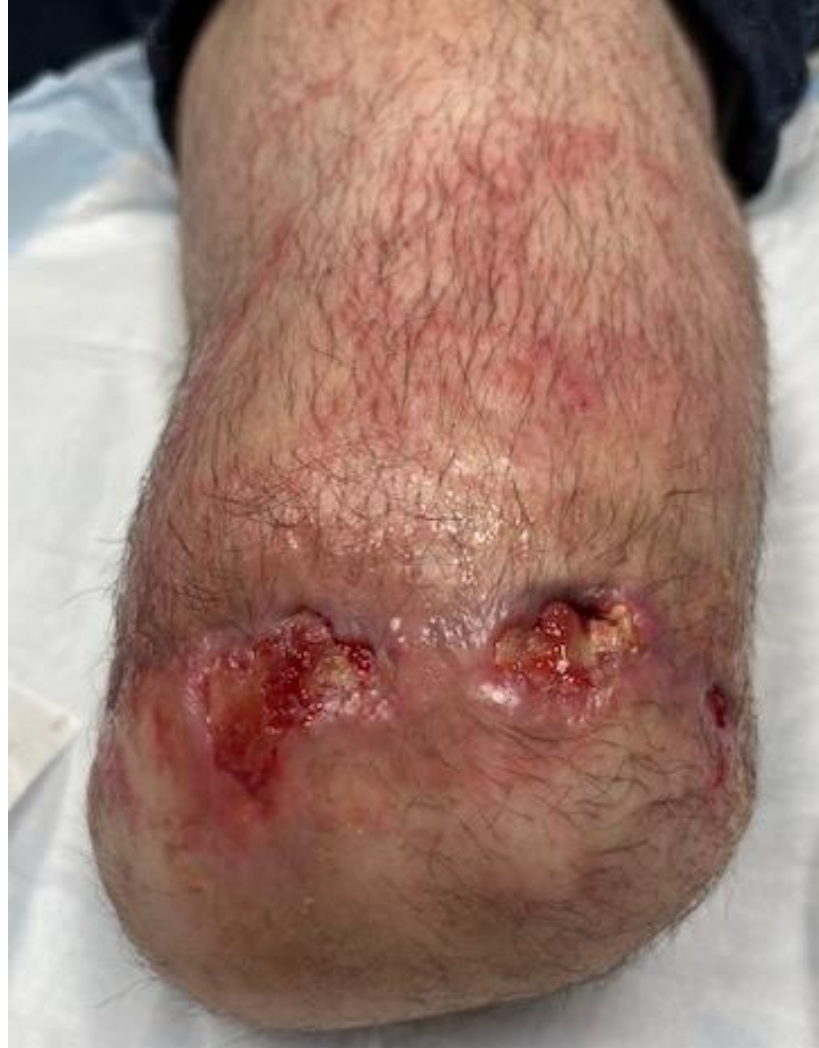

Case 1: Knee Crutch Ambulatory Aid

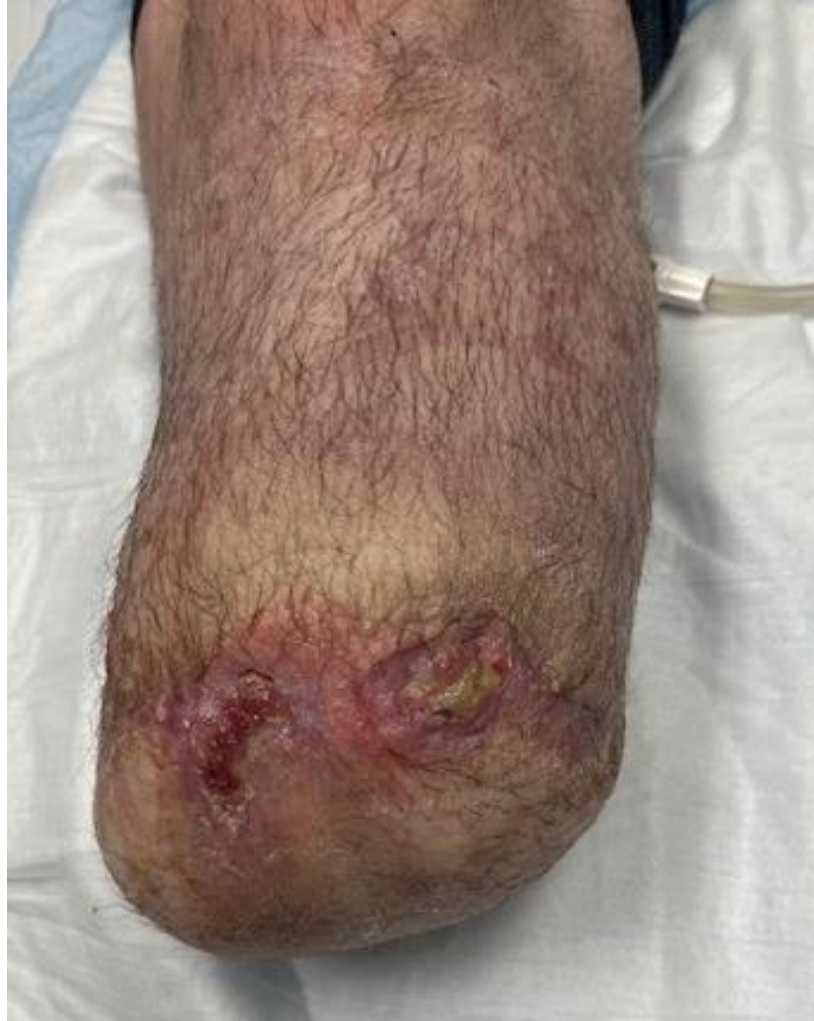

Case 1: After 1 Wk of Peel and Place

- *Pressure increased to -150 mm Hg in light of increased moisture and periwound irritation



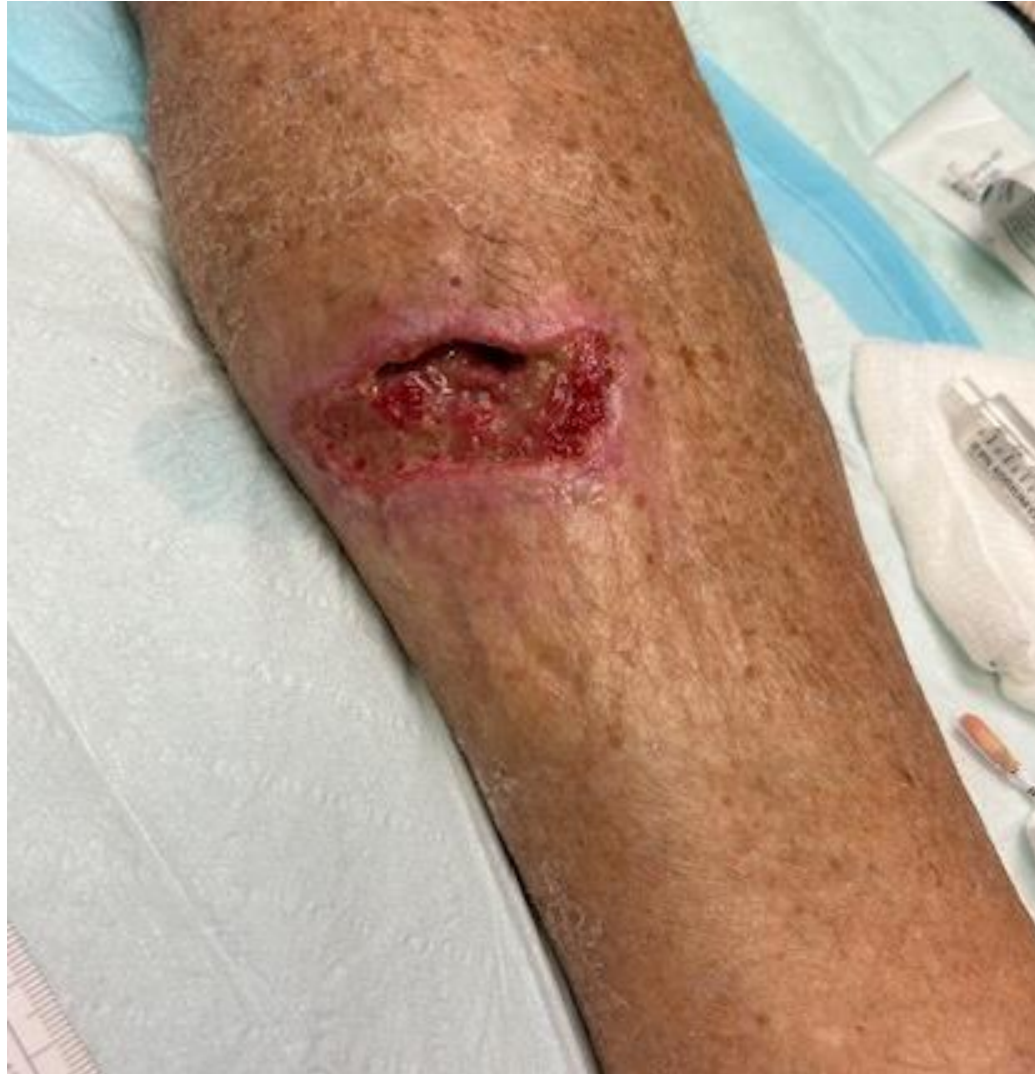Case 1: After 2 Wks, Therapy Discontinued



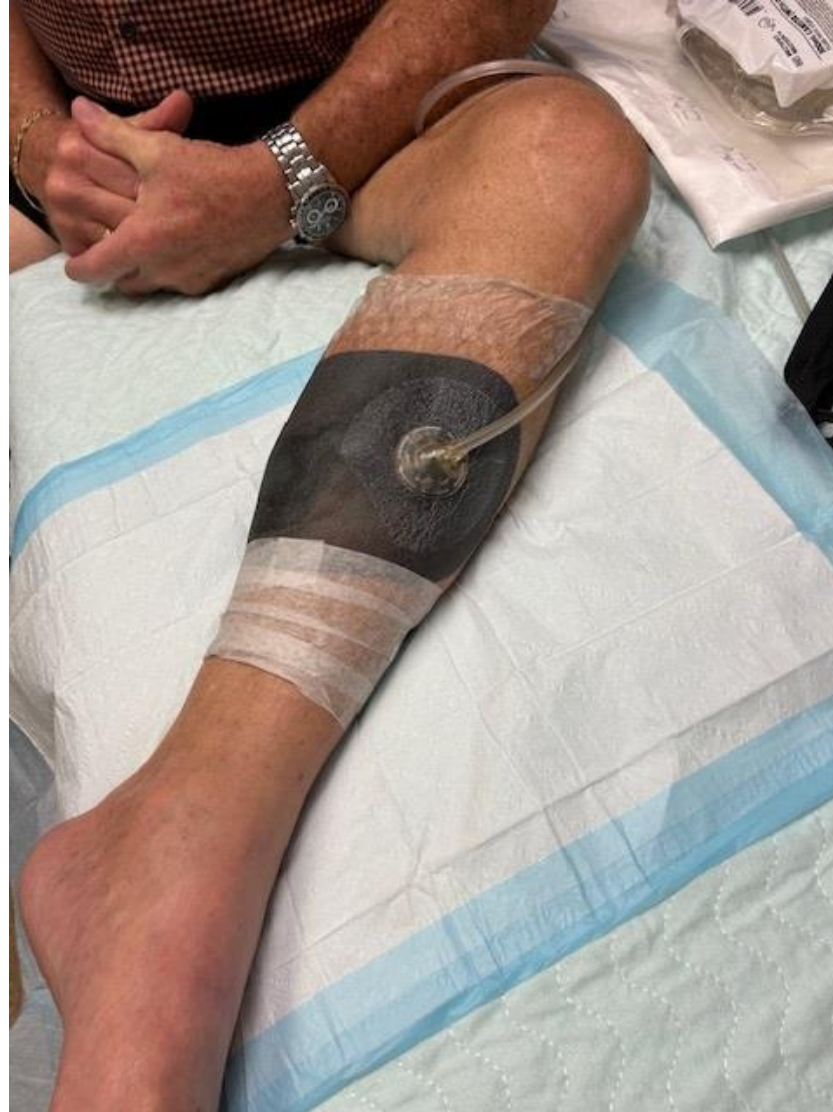Case 2: Lawnmower Injury of Lower Leg

- 77y Male presented with a lawnmower blade laceration, left medial calf
- Was seen at a local ED, basic care initiated, and referred for more advanced wound care
- Initial debridement carried out; agreed to NPWT with peel and place
 - Large dressing at -125 mm Hg

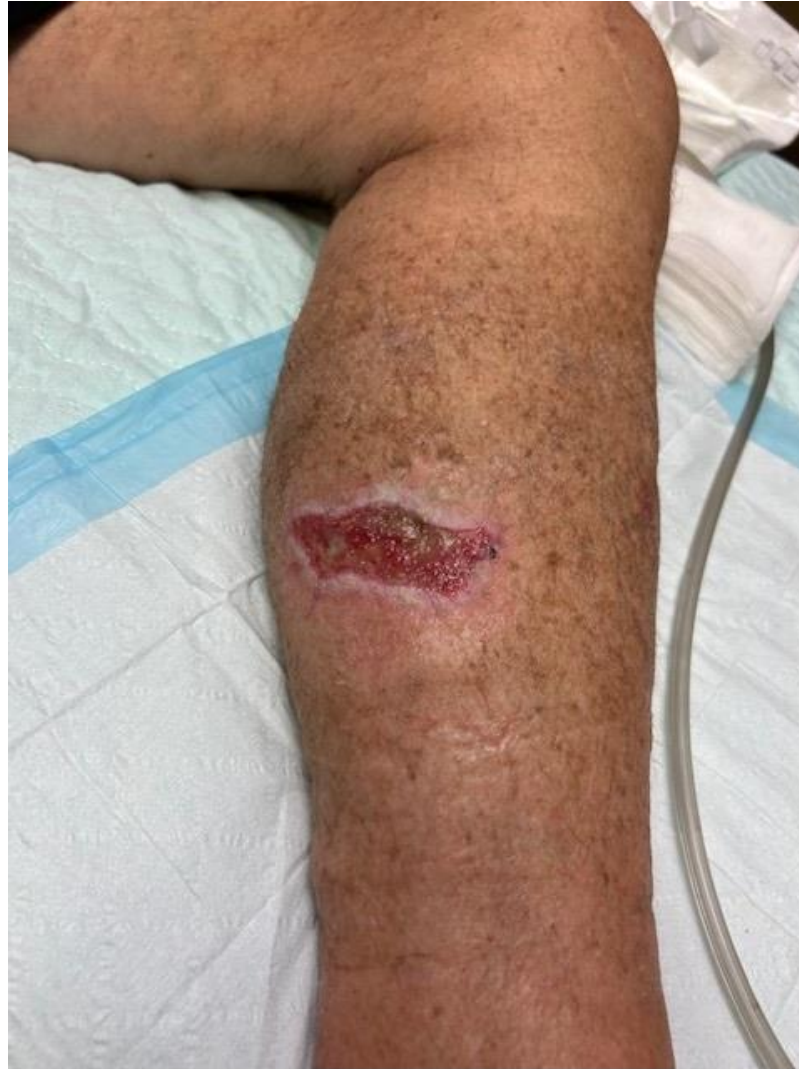Case 2: Initial Presentation



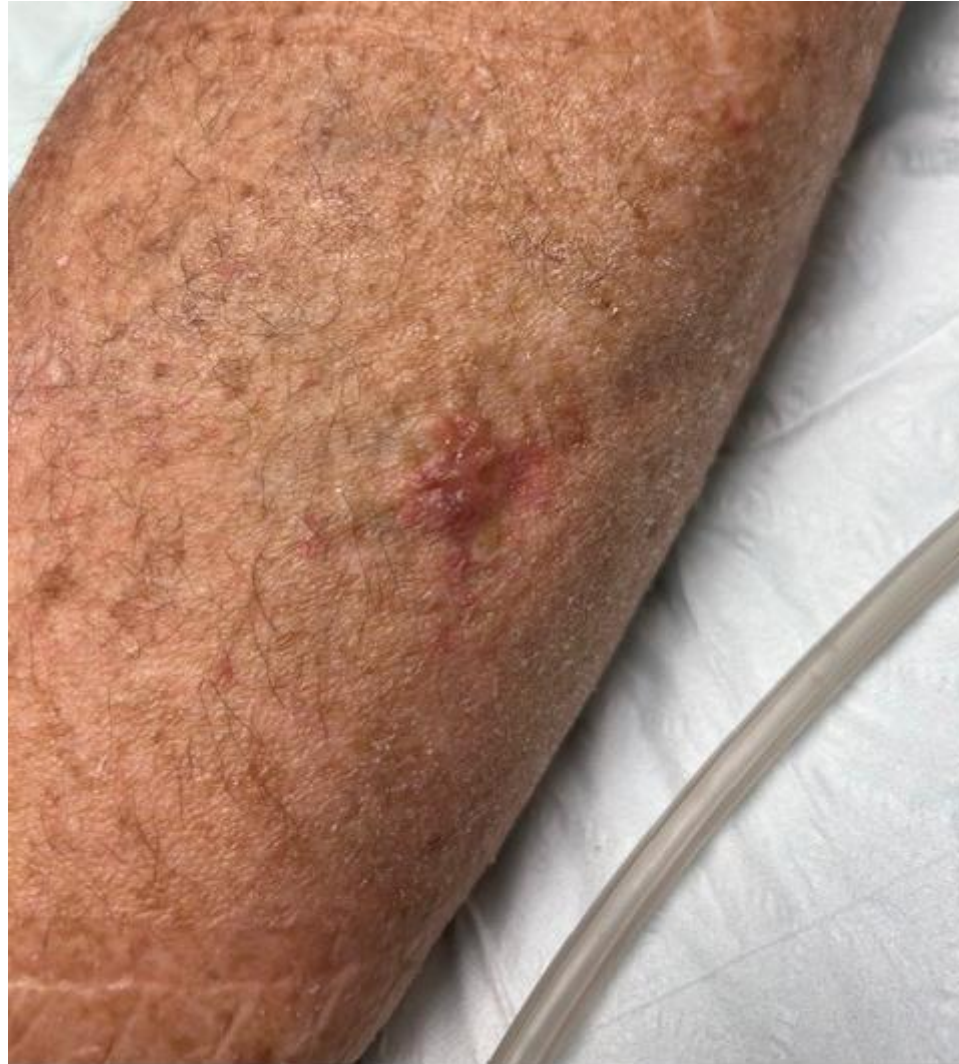Case 2: Follow-up 1 Wk; Dressing before Take Down



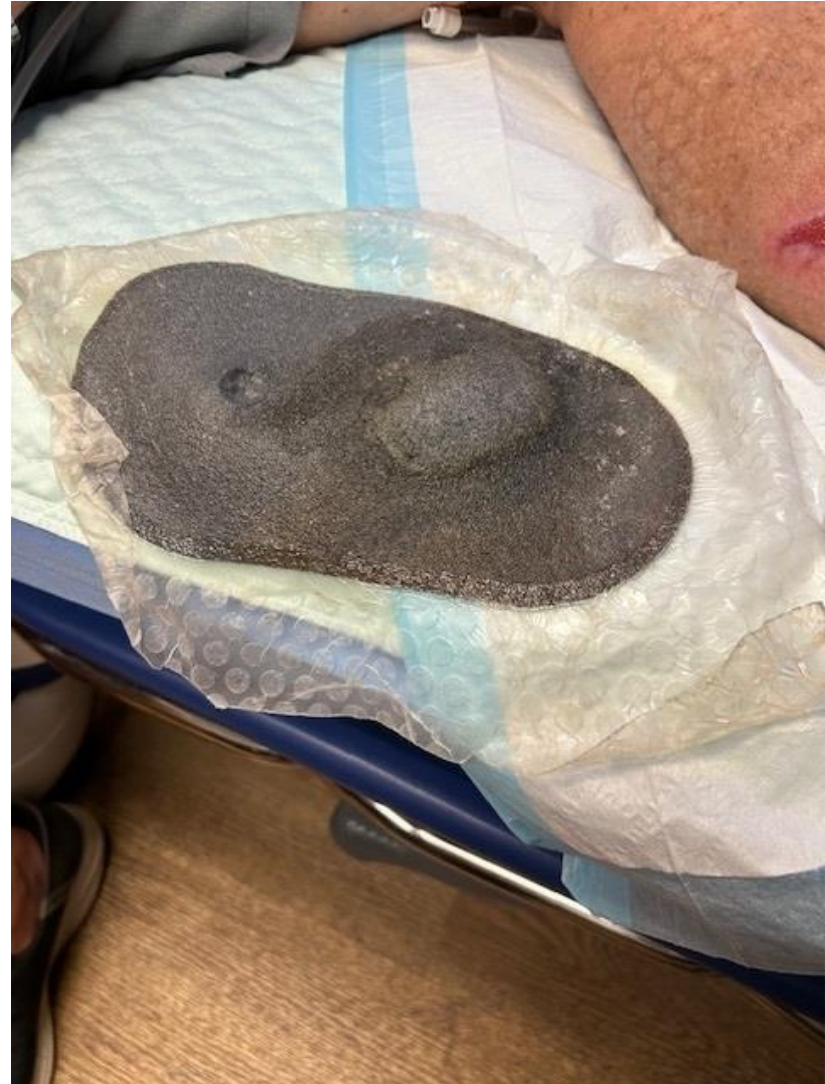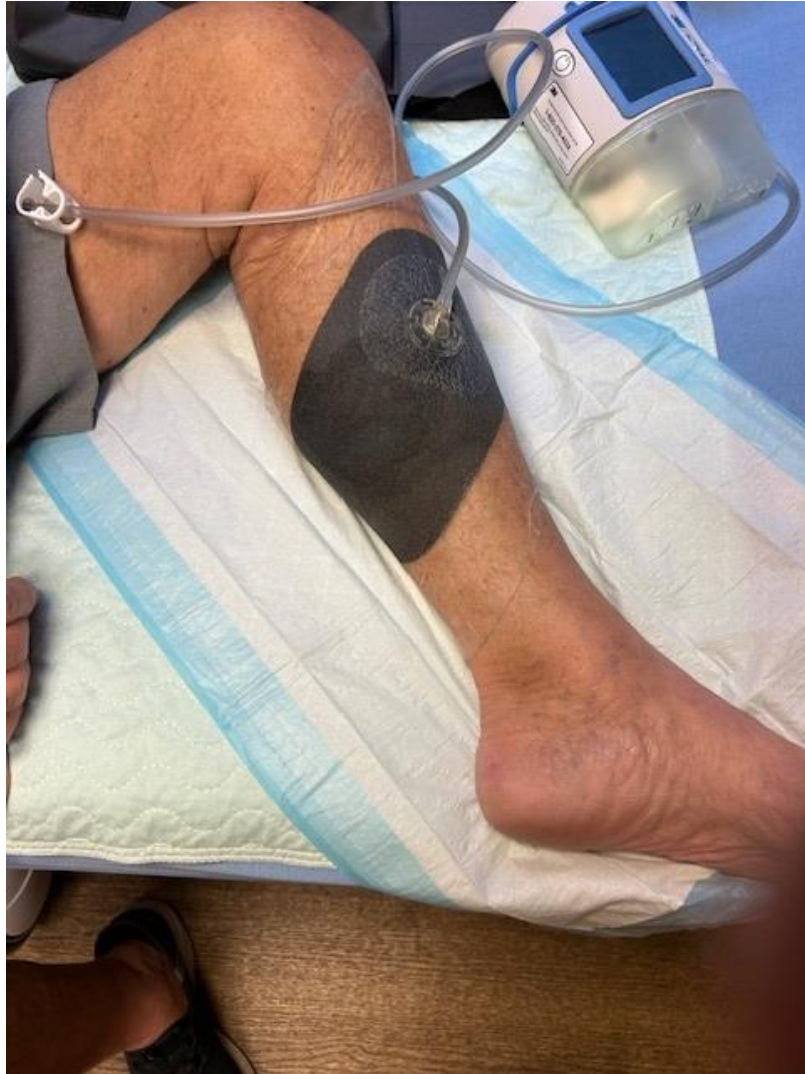Case 2: Follow-up 1 Wk with NPWT Peel and Place



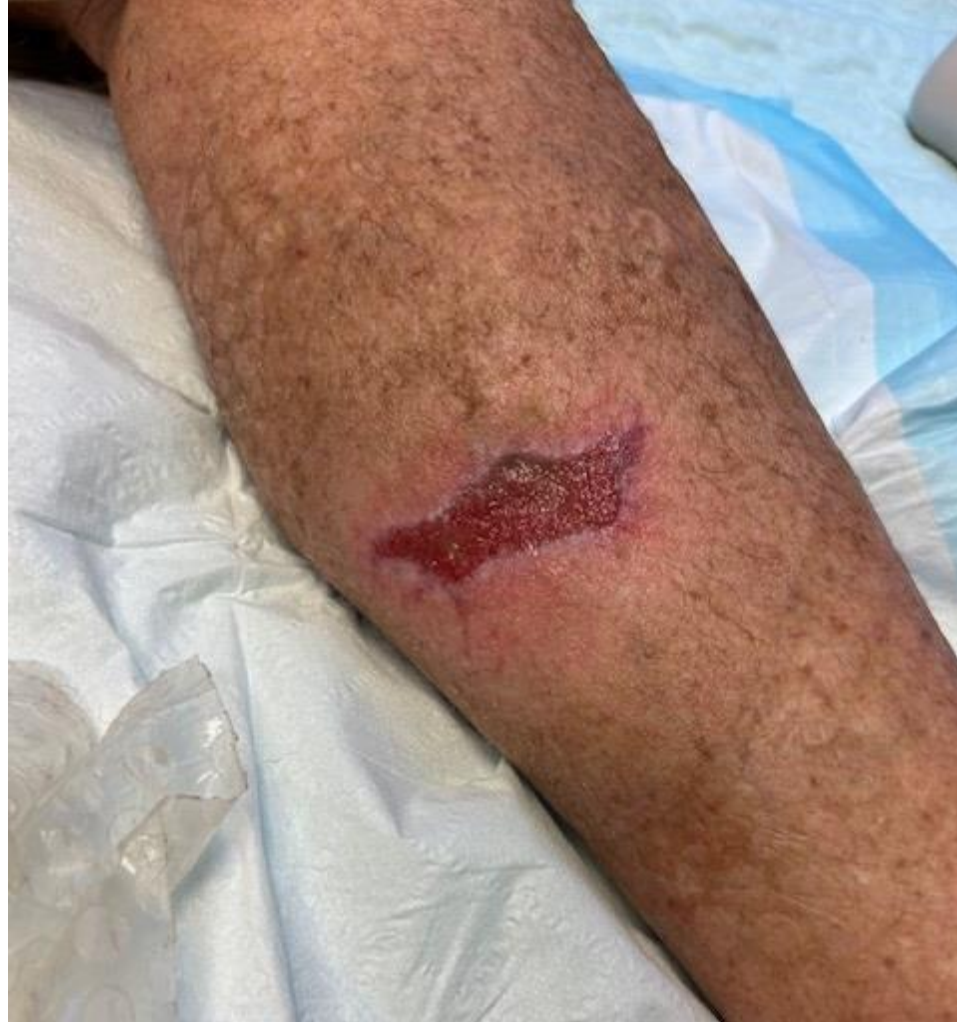Case 2: Transient Dermal Deformation (TDD)



Case 2: Follow-Up 2 Wks with NPWT Peel and Place

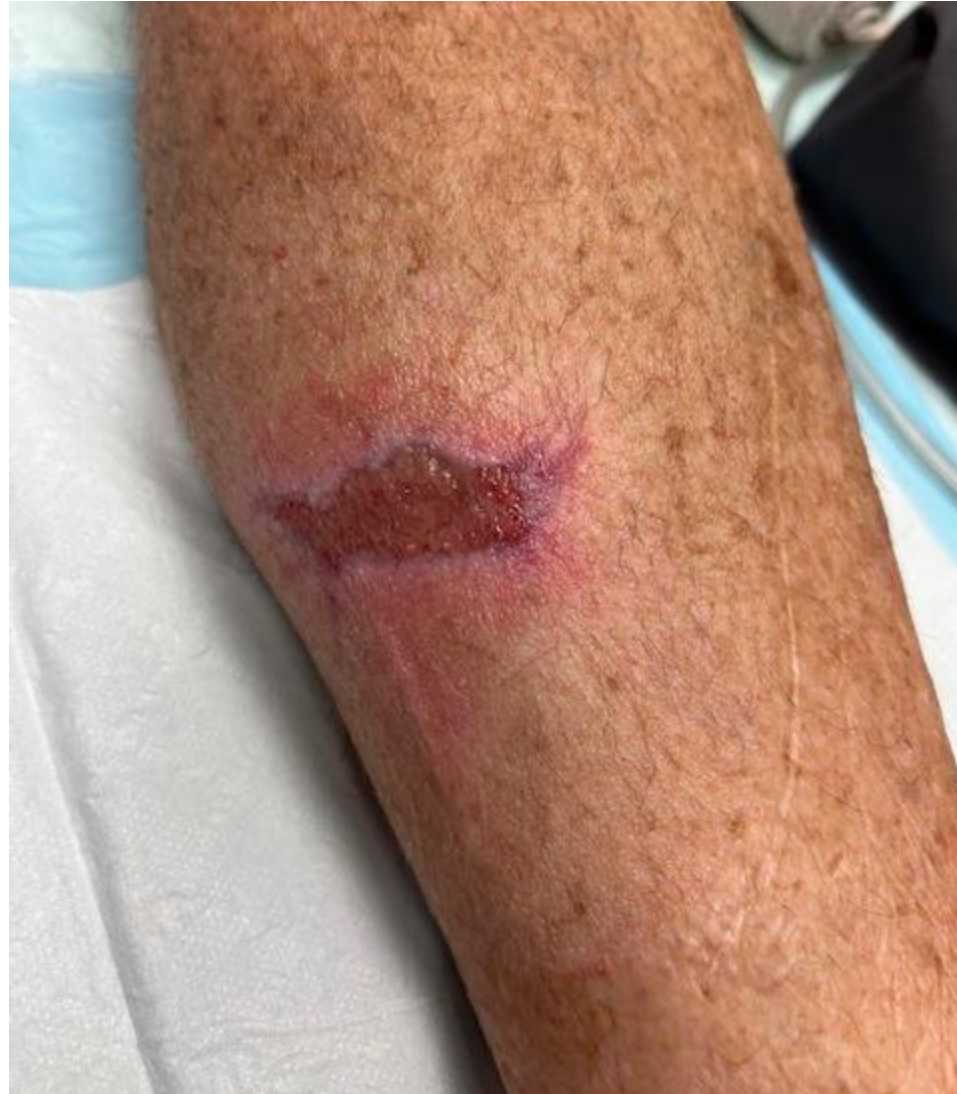

Case 2: Follow-Up 2 Wks with NPWT Peel and Place



Case 2: Follow-Up 3 Wks with NPWT Peel and Place

- VAC therapy discontinued

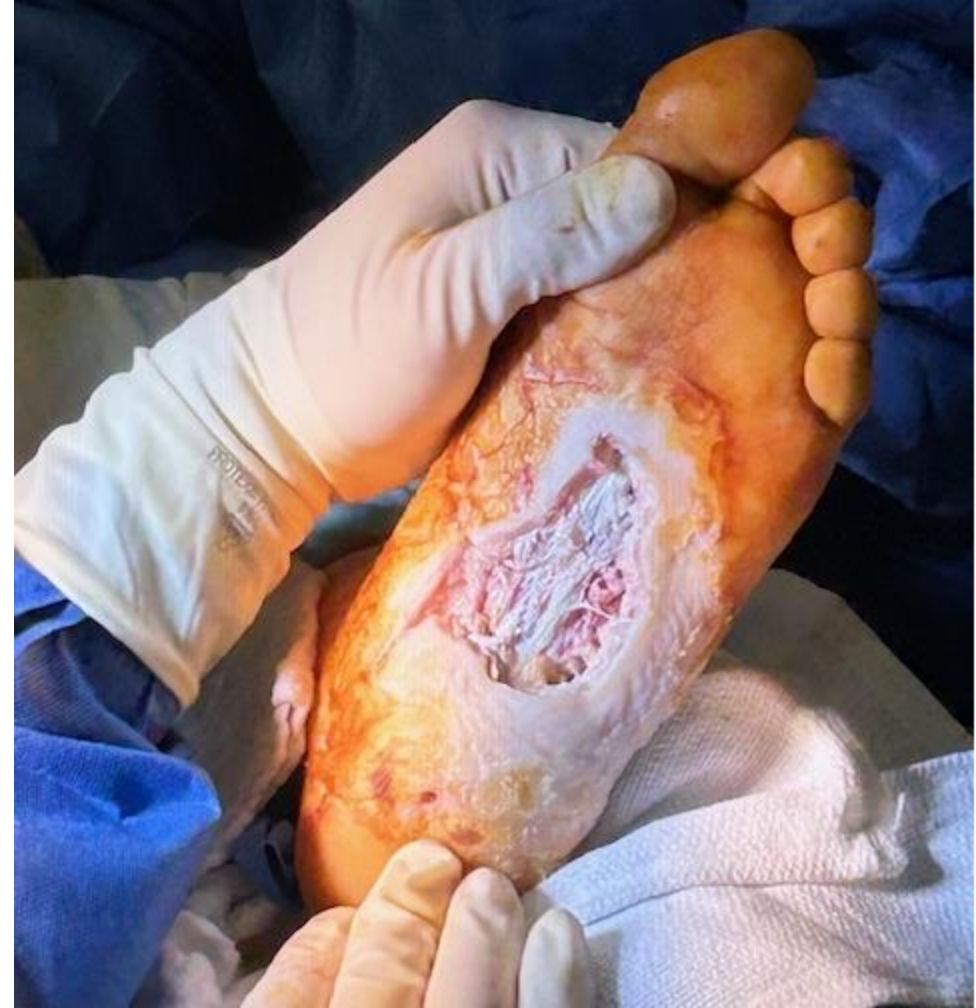
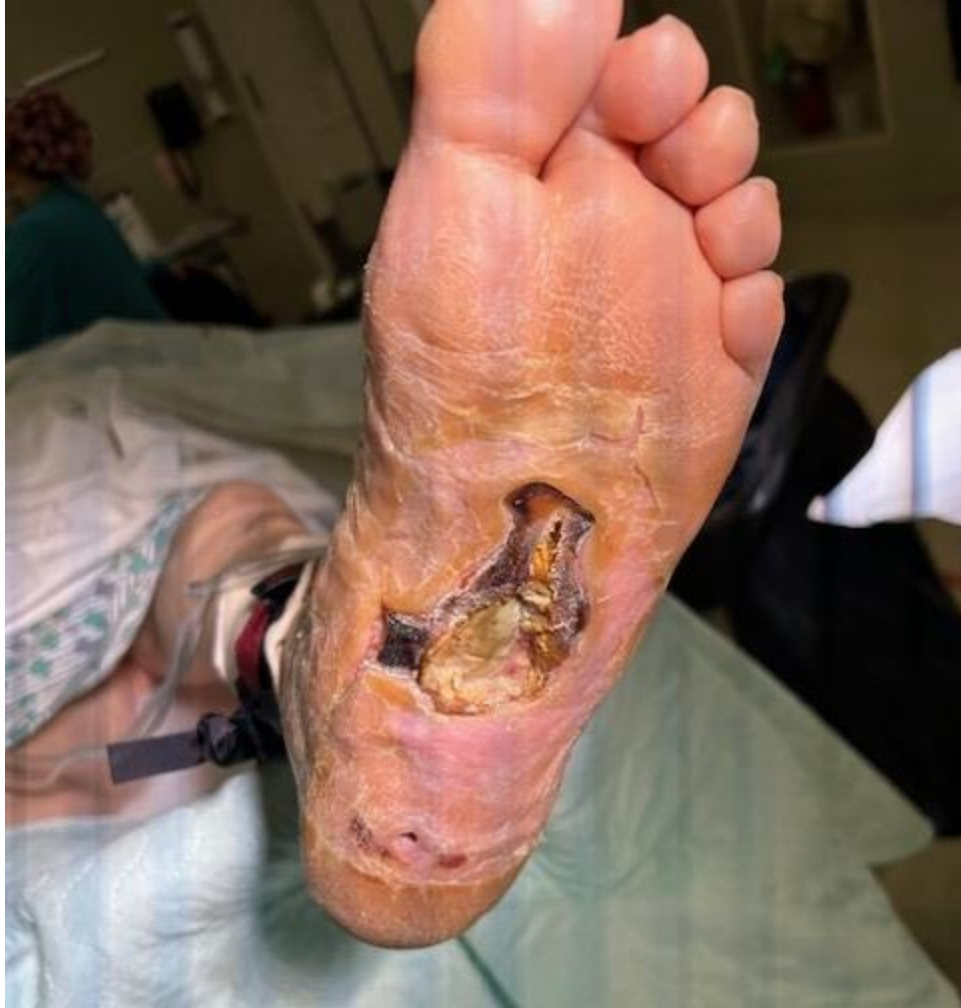
Case 3: Diabetic Foot Infection/Surgical Wound

- 65y Male presented with a severe foot infection as a result of a puncture wound and retained foreign body; was found to be diabetic previously undiagnosed with vasculopathy
- Had initial emergent debridement and foreign body removal at the hands of a practice partner and was referred over for additional specialty wound care
- Optimized vascularly and underwent debridement with NPWTi-d; transitioned to traditional VAC with peel and place, large dressing at -150 mm Hg

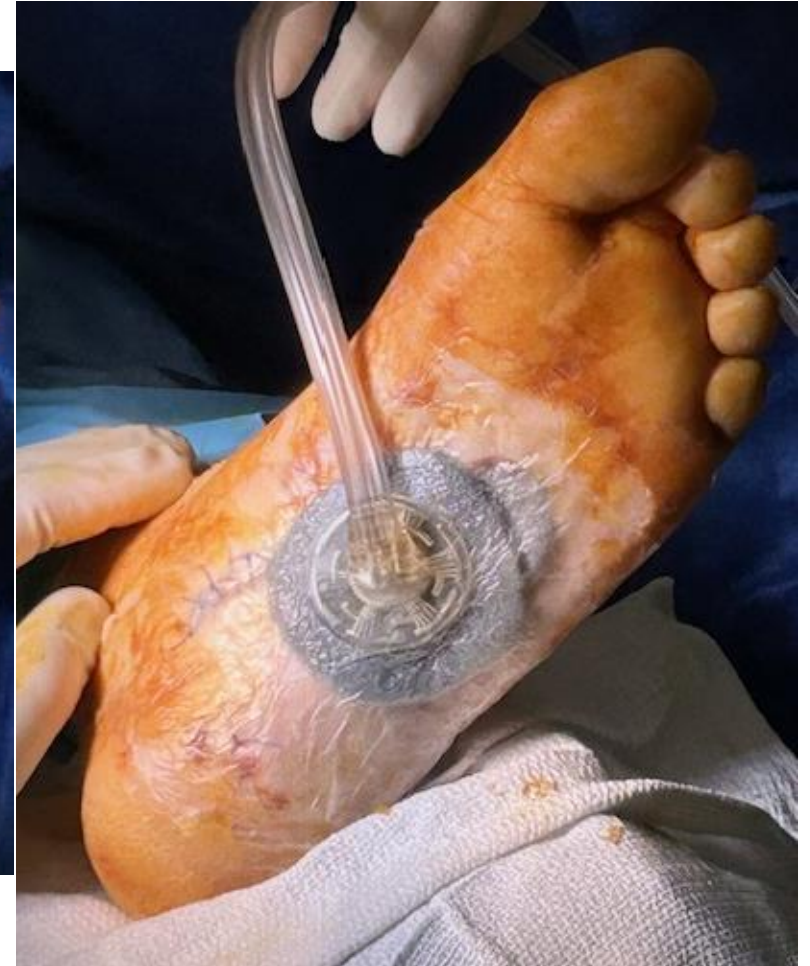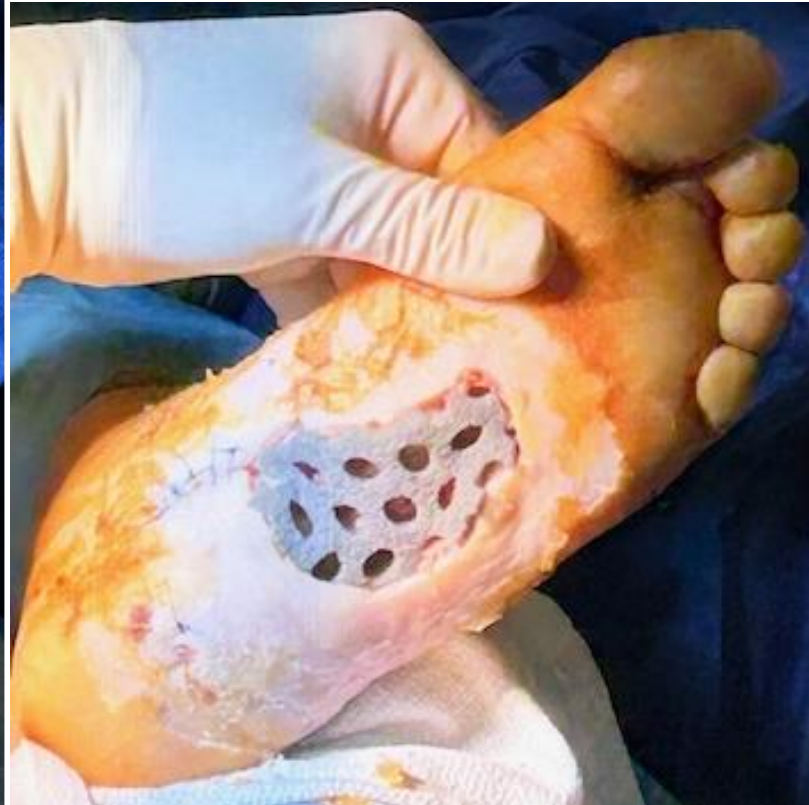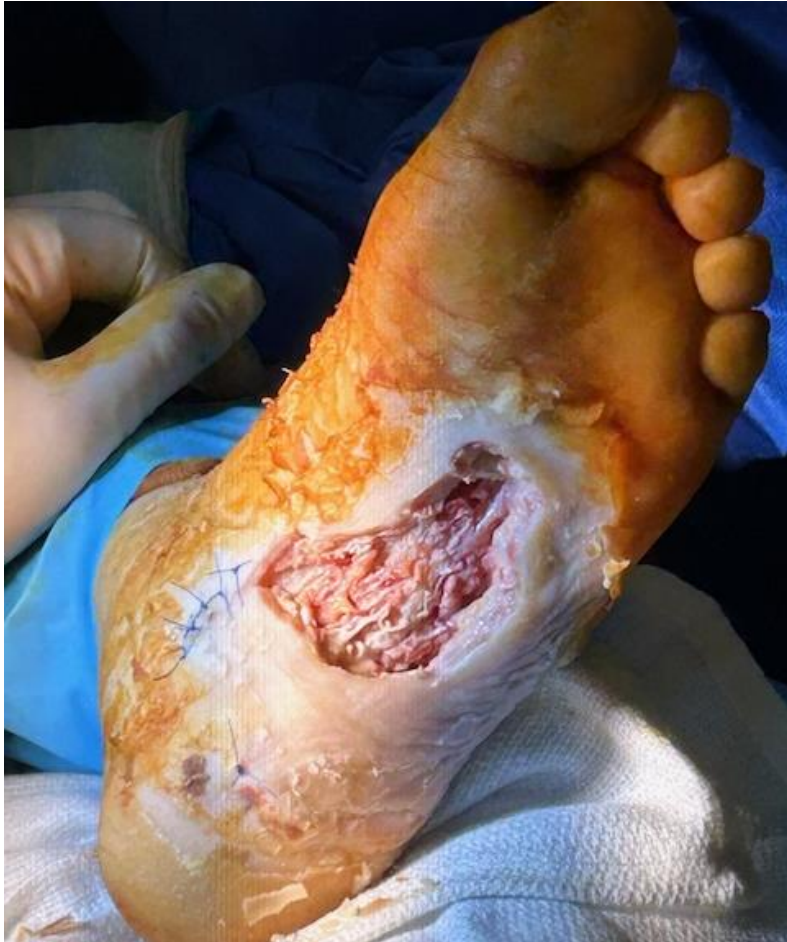Case 3: Diabetic Foot Infection/Surgical Wound

Intra-Op Photos



Case 3: Diabetic Foot Infection/Surgical Wound

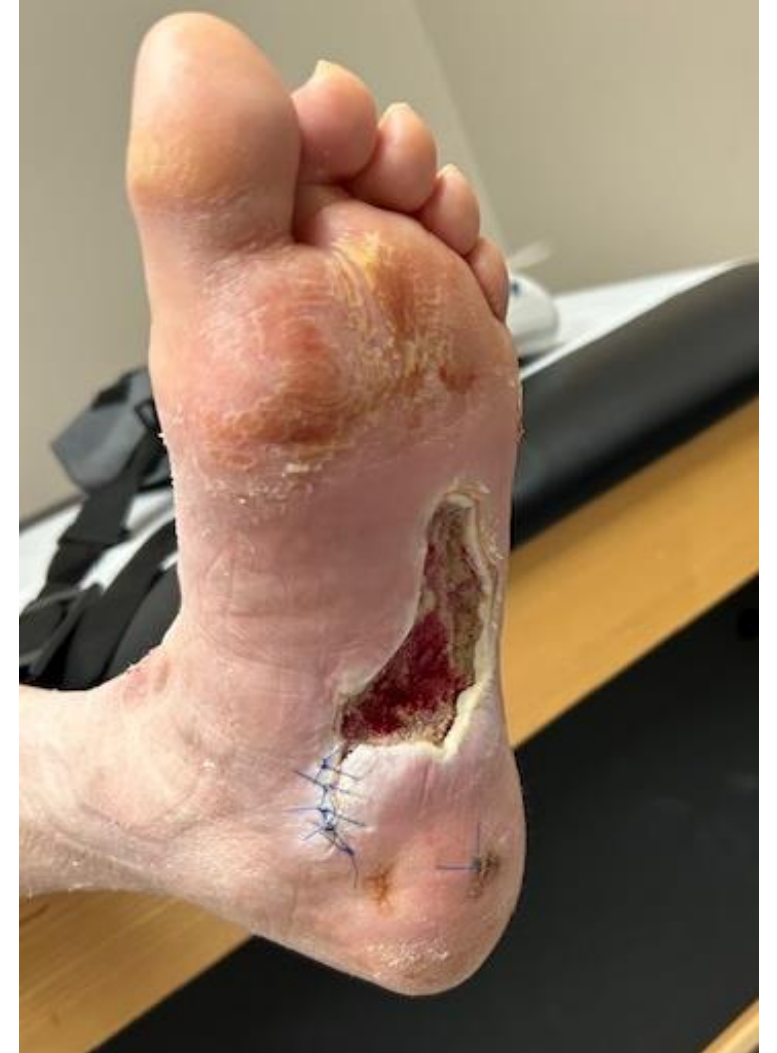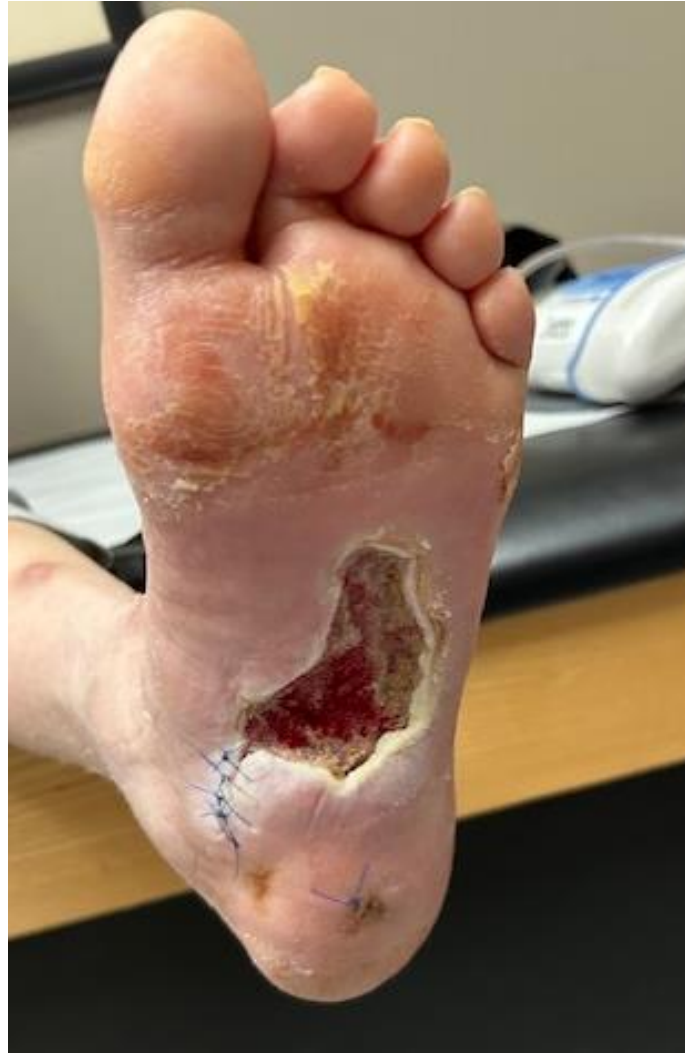Intra-Op Photos



Case 3: Diabetic Foot Infection/Surgical Wound

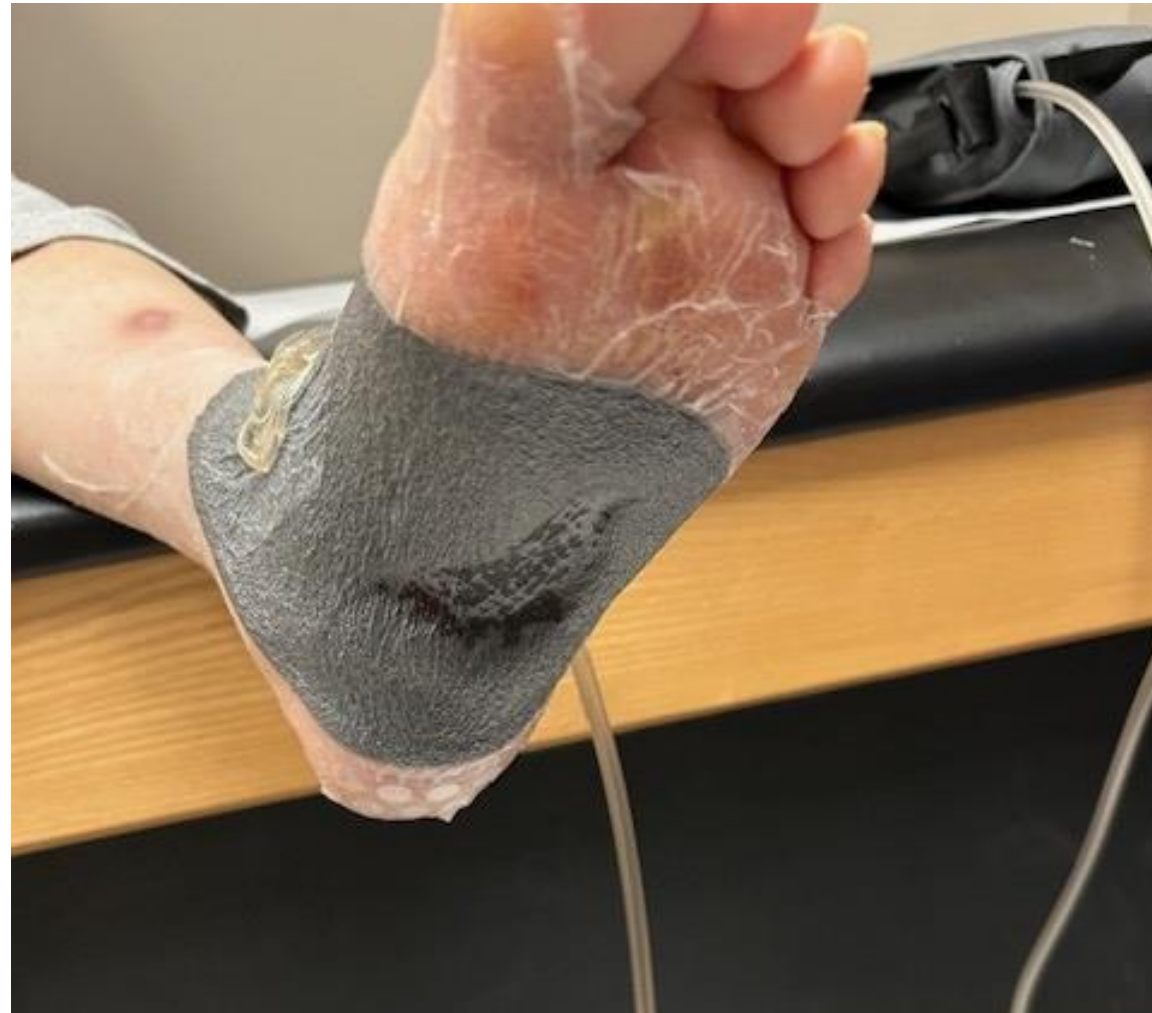After 1 Wk of NPWTi-d

- After NPWTi-d, patient had a few days of “standard” VAC therapy prior to peel and place



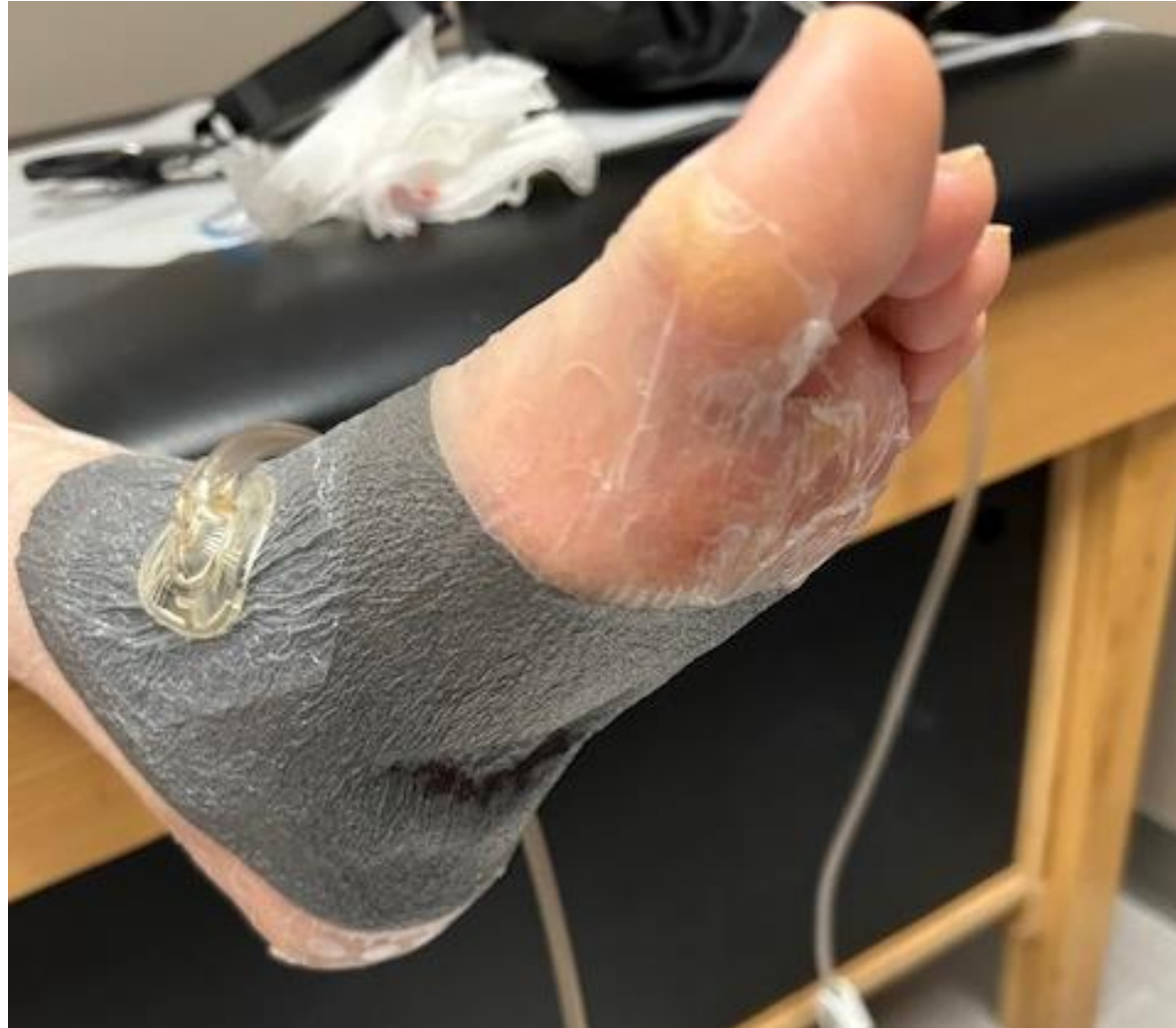Case 3: Diabetic Foot Infection/Surgical Wound

Initial Peel and Place Application

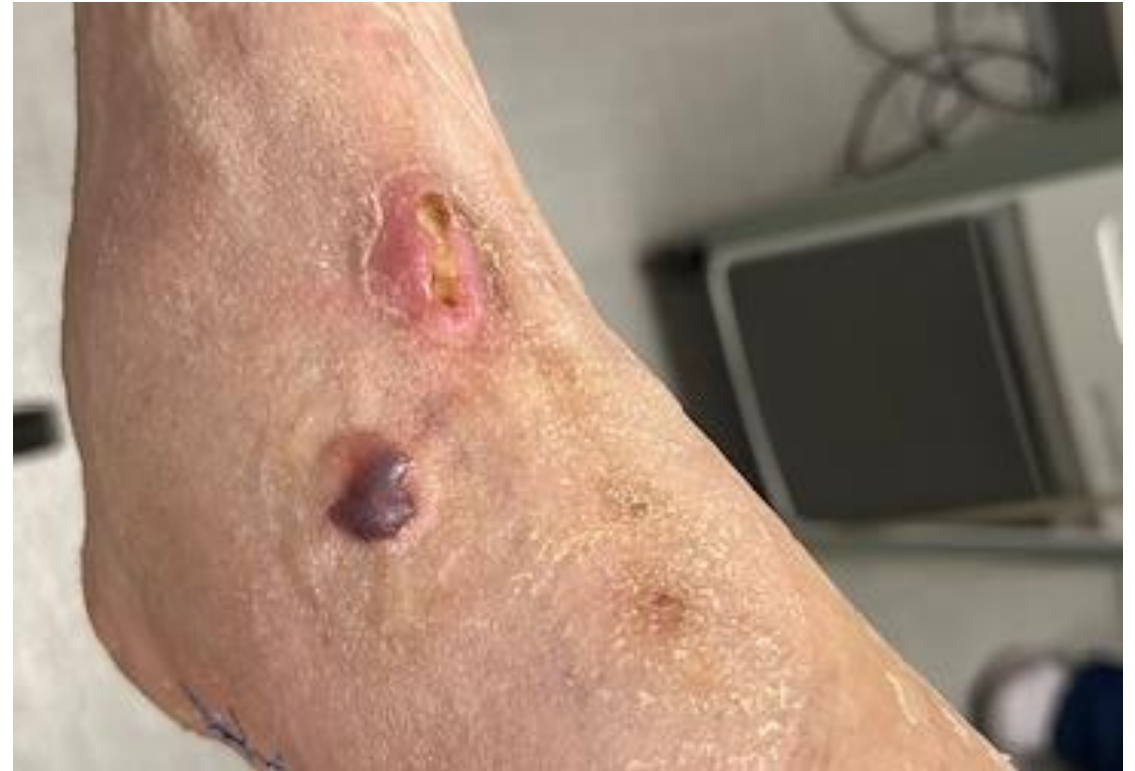
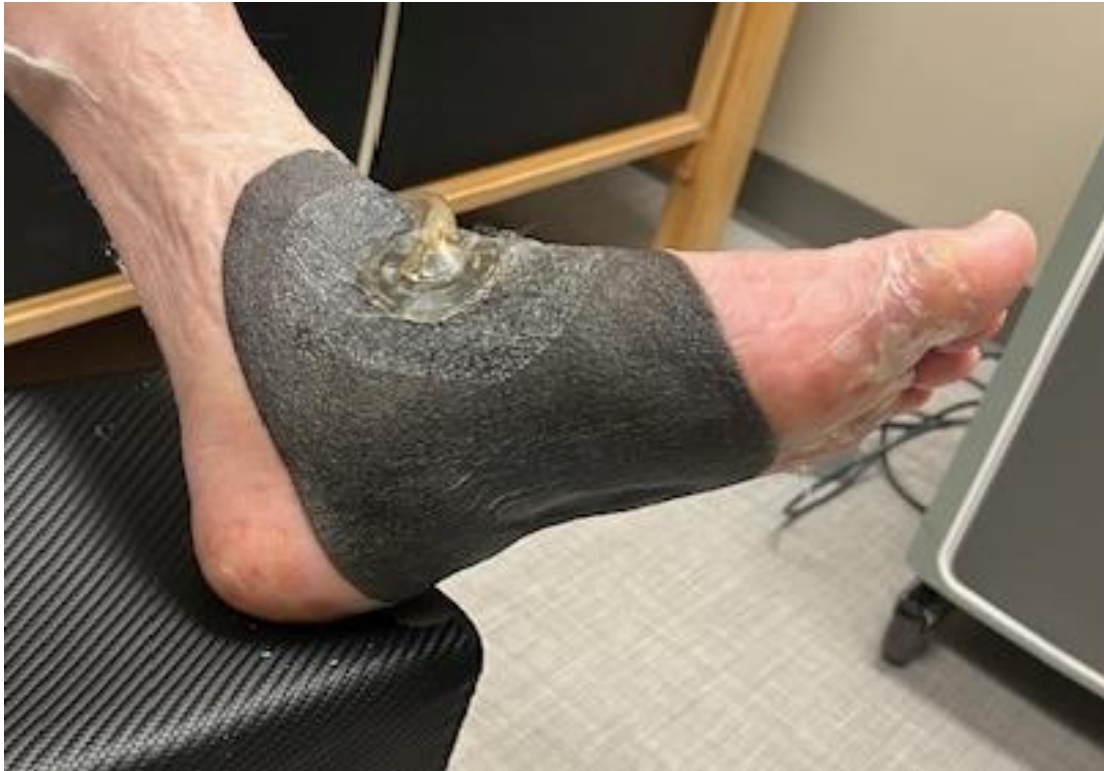
Case 3: Diabetic Foot Infection/Surgical Wound

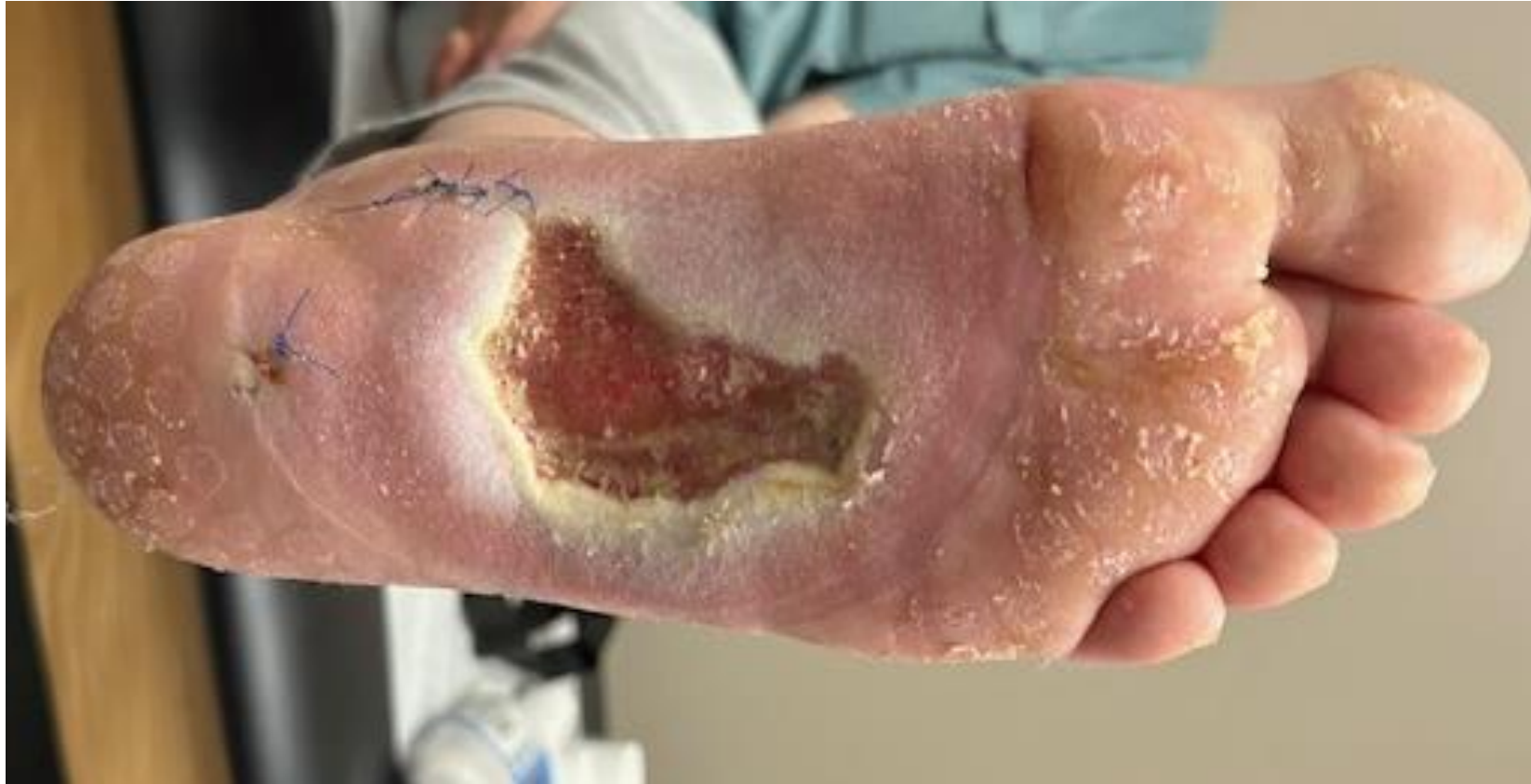Initial Peel and Place Application



Case 3: Diabetic Foot Infection/Surgical Wound Follow-Up at 1 Wk

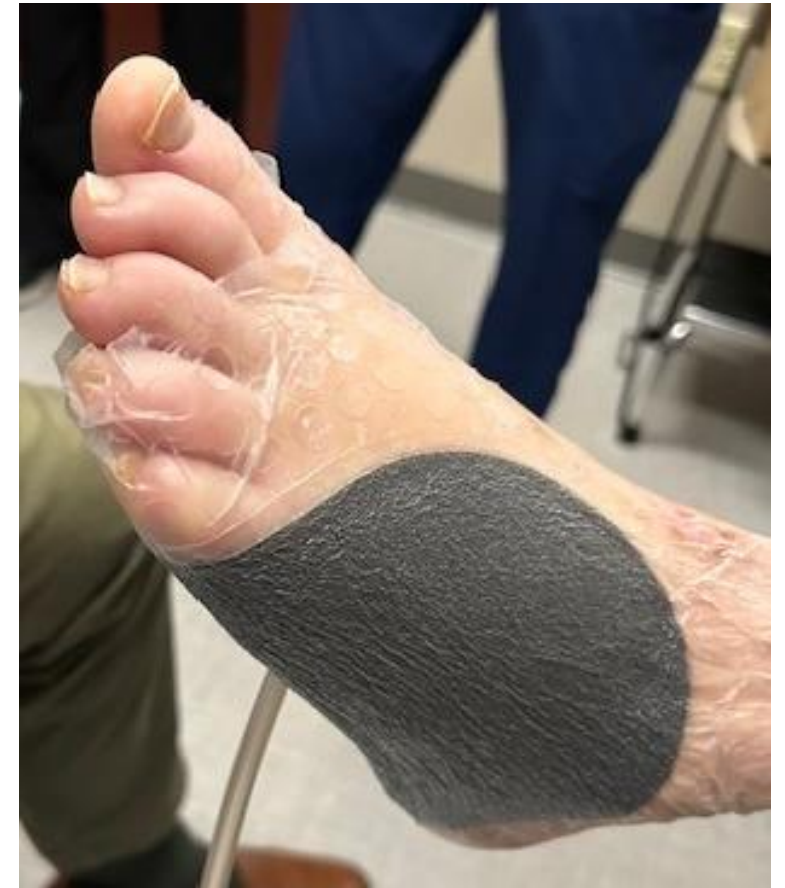
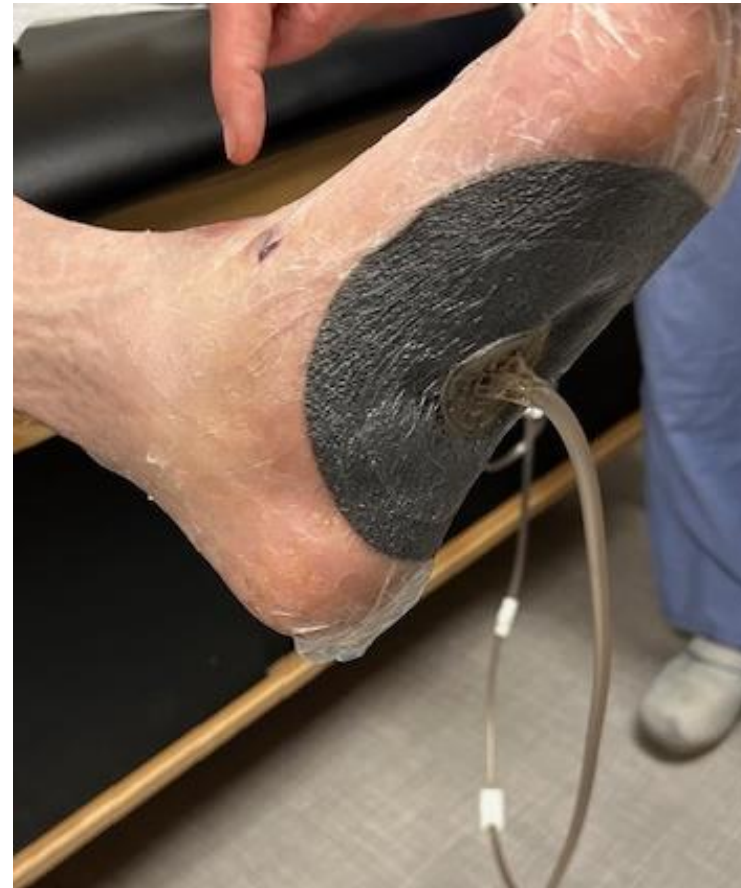
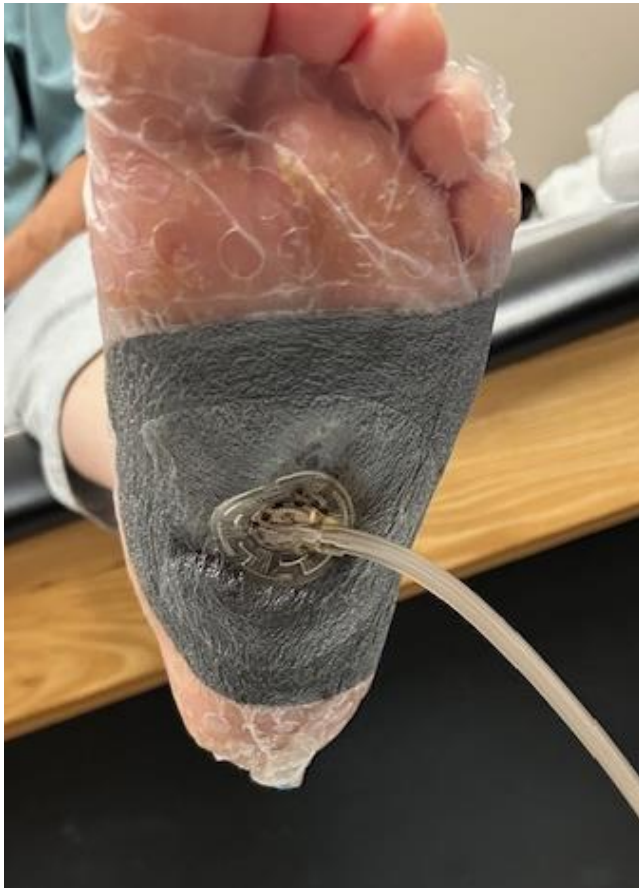Case 3: Diabetic Foot Infection/Surgical Wound Follow-Up at 1 Wk

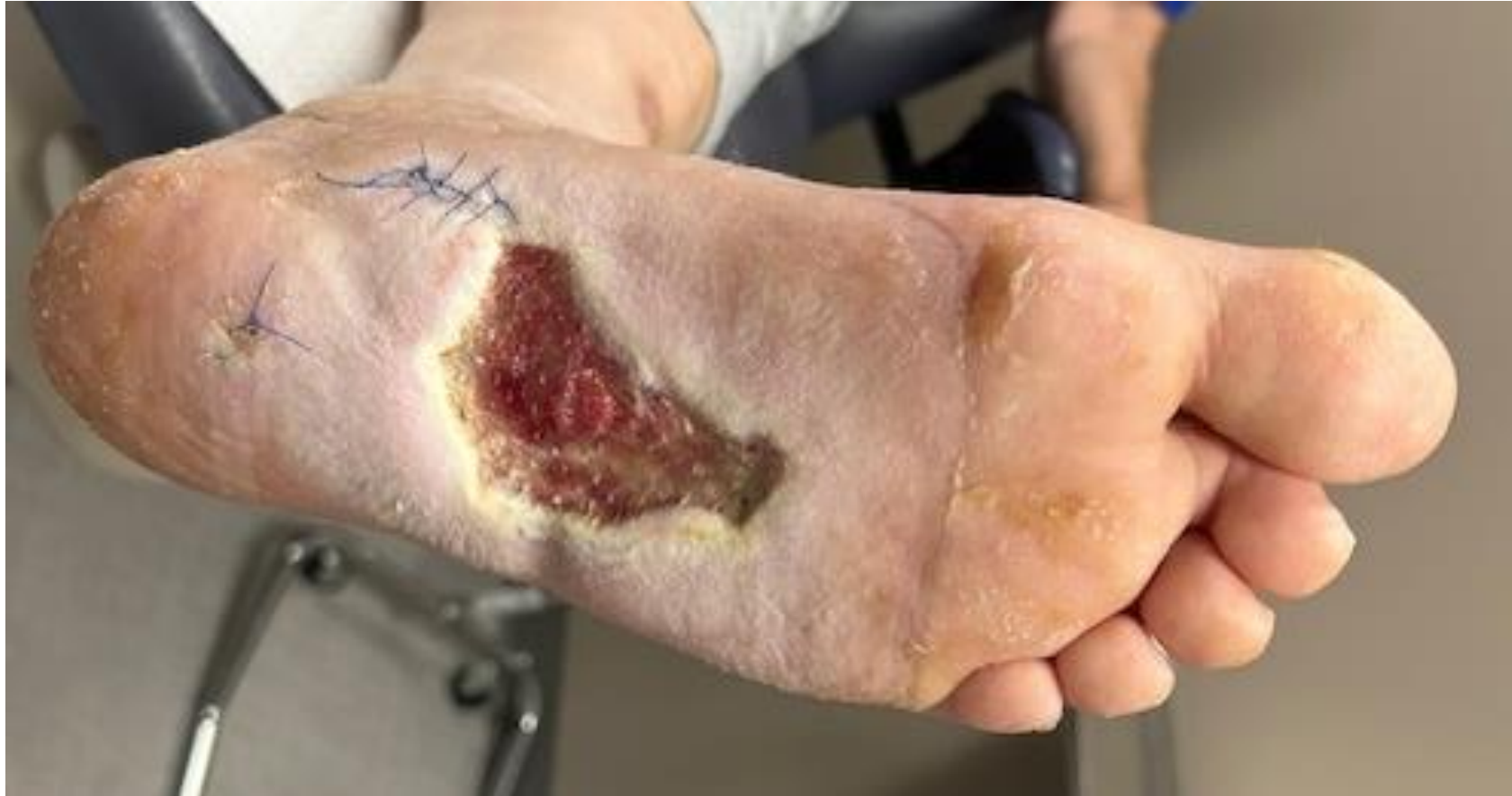

Case 3: Diabetic Foot Infection/Surgical Wound

Follow-Up at 1 Wk

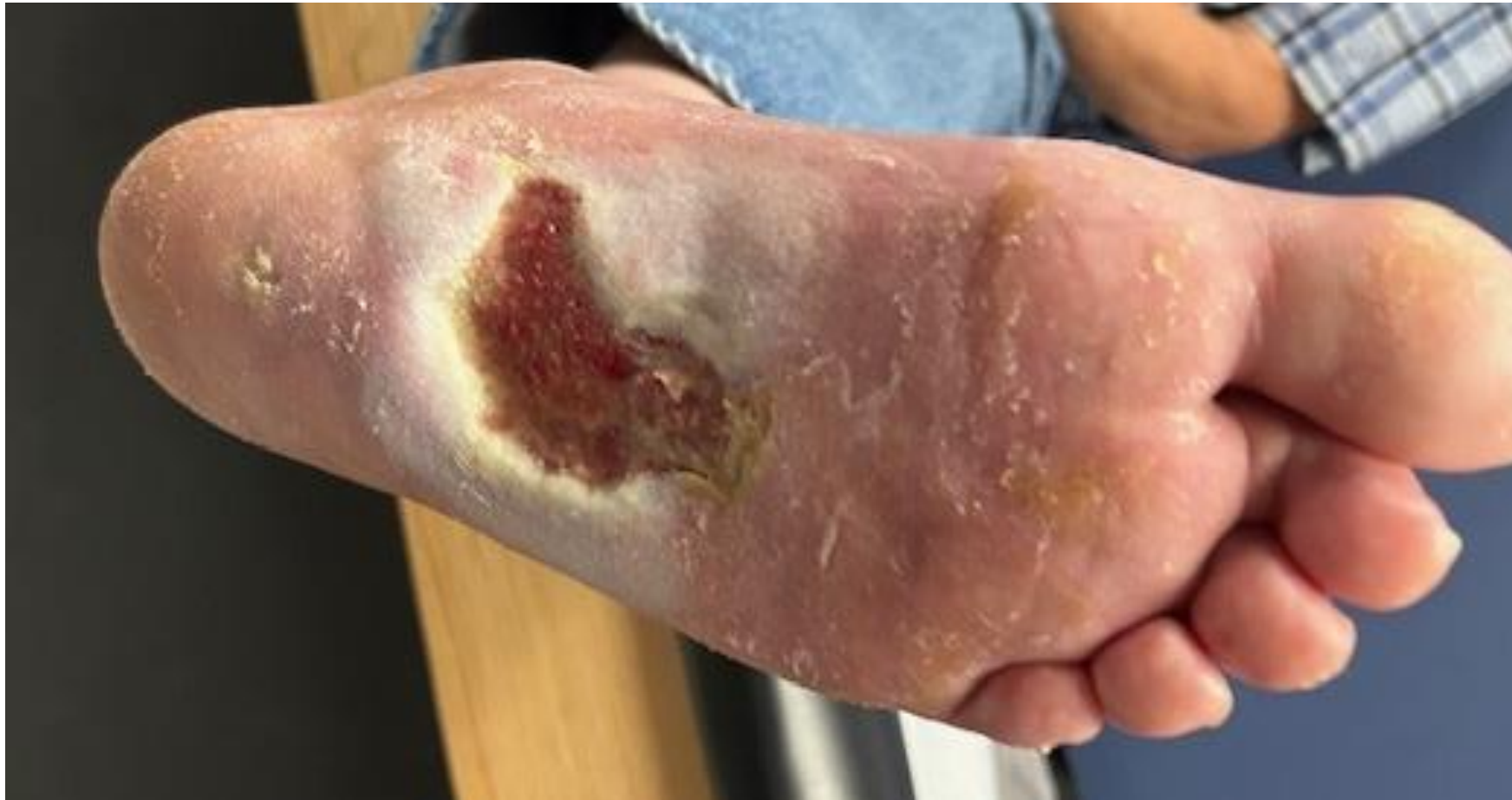

Case 3: Diabetic Foot Infection/Surgical Wound After 2 Wks of Peel and Place



Case 3: Diabetic Foot Infection/Surgical Wound After 3 Wks of Peel and Place

- Note persistent moisture

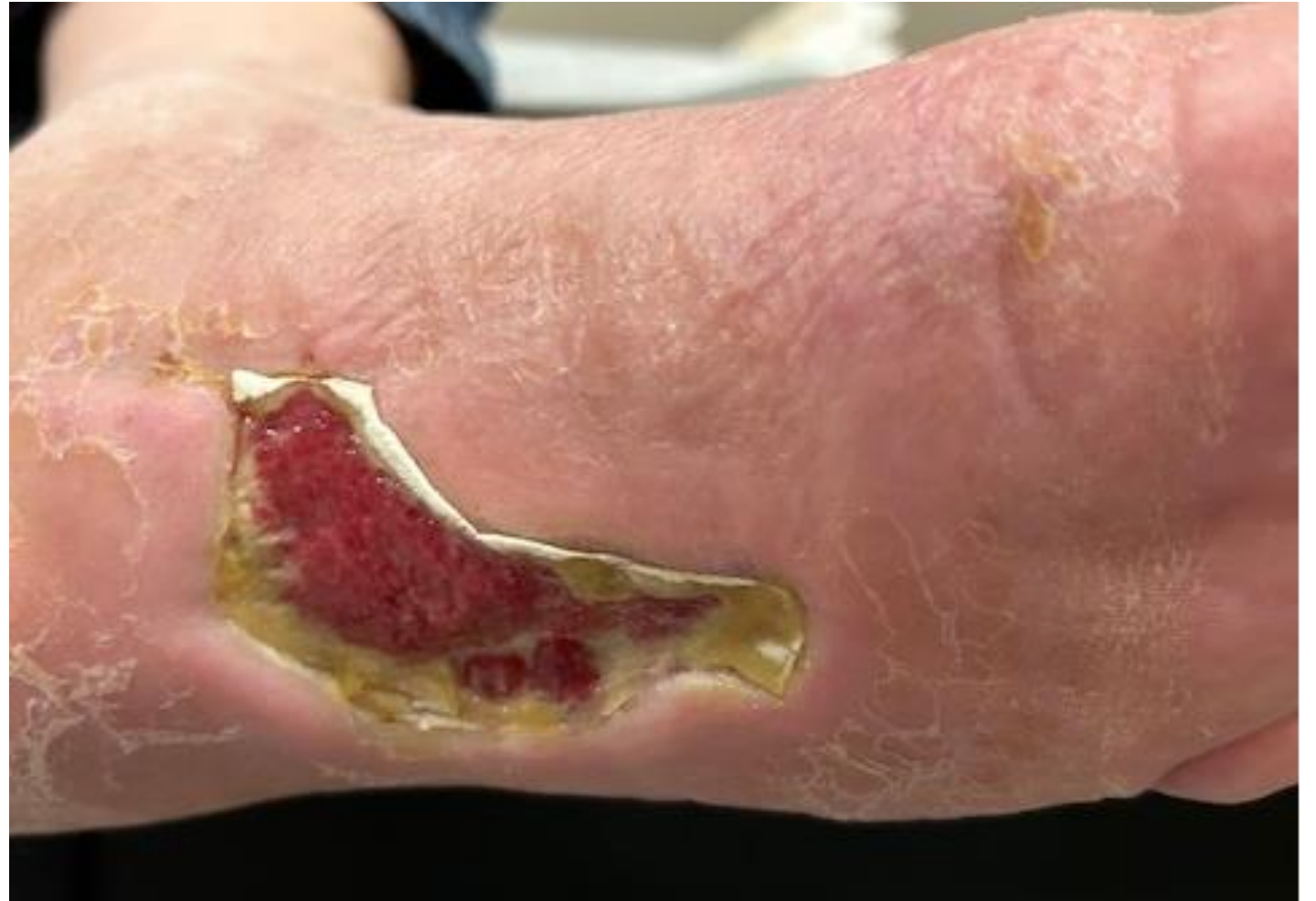

Case 3: Diabetic Foot Infection/Surgical Wound

After Peel and Place VAC “Holiday”

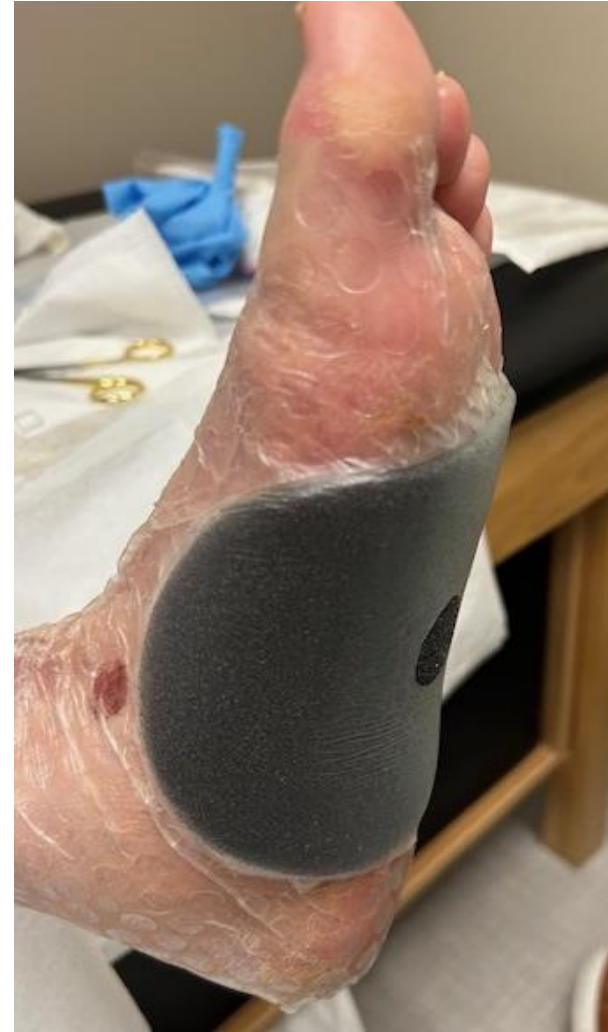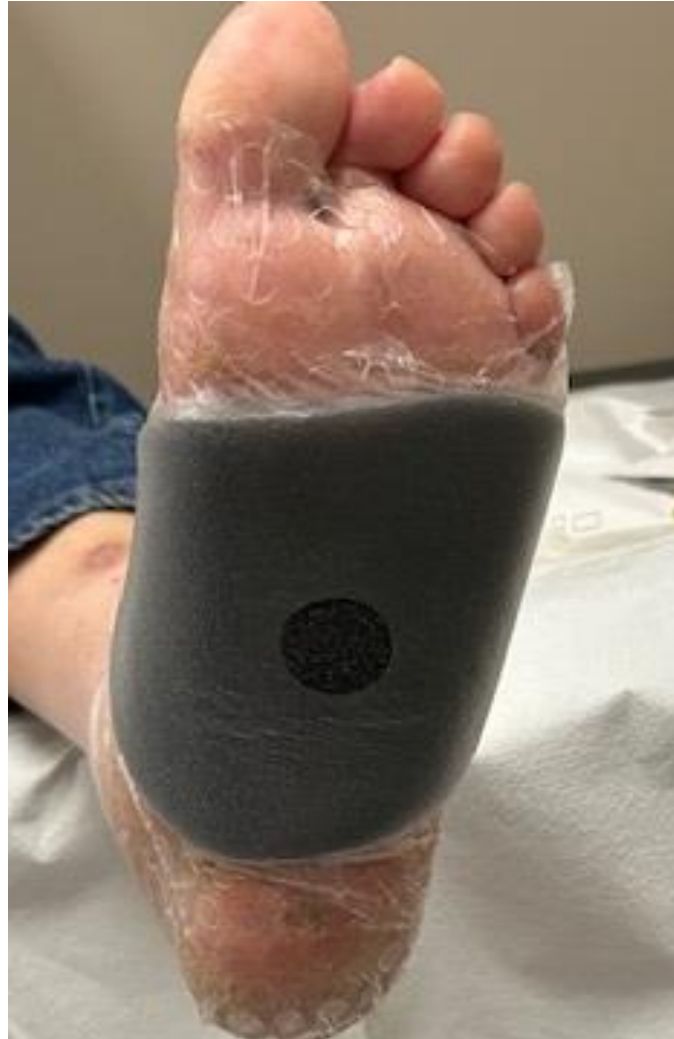- 1 wk of ORC, collagen, and silver-ORC matrix; changed every other day

***Although not easily seen in photo, slight increase in swelling noted during VAC holiday**



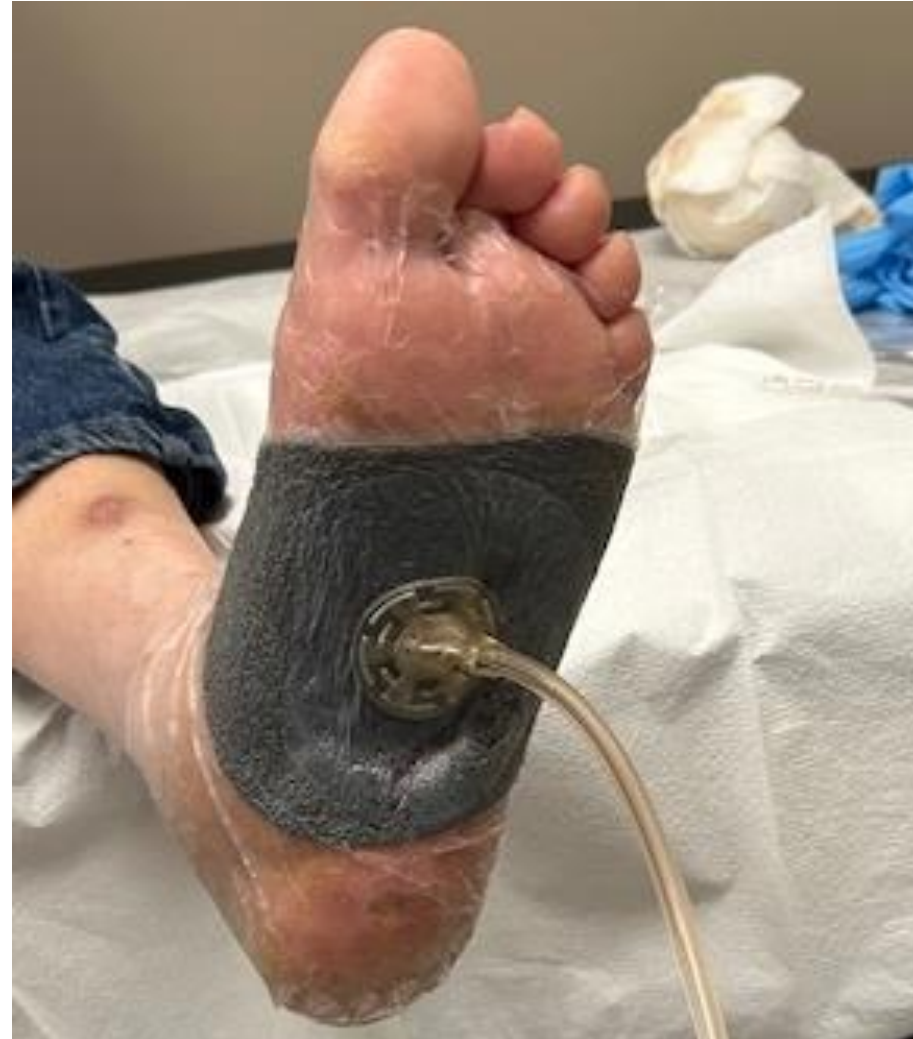Case 3: VAC Peel and Place Resumed

Medium Dressing Step Down from Large



Case 3: VAC Peel and Place Resumed

Medium Dressing Step Down from Large



Initial Experience with a Novel Negative Pressure Wound Therapy Peel and Place Dressing in Lower Extremity Wounds

Ralph J. Napolitano, Jr., DPM, CWSP, FACFAS

OrthoNeuro, Columbus, OH; Heritage College of Osteopathic Medicine, Ohio University, Athens, OH

Introduction

- The application of negative pressure wound therapy to support healing of lower extremity wounds is well-documented.¹
- A recently available multilayer peel and place dressing (MPPD) incorporates a perforated non-adherent layer, reticulated open cell foam dressing, and a hybrid acrylic and silicone drape, which enable it to be placed over the wound and surrounding intact skin.

Purpose

- In this case series, we report the outcomes of application of NPWT with MPPD* in 4 patients with lower extremity wounds.

Methods

- Deidentified data was collected after obtaining informed patient consent and stored in accordance with federal regulations.
- Patients had injuries to the foot or lower leg and received NPWT with MPPD at -125 mmHg for 10-21 days.
- Dressings were changed every 5-7 days.

Results

- Three male and one female patient, ages 28 to 77 years old, were included in the study.
- Wound etiologies included surgical wounds, a traumatic injury, and a decubitus ulcer.
- After 10-21 days of therapy, the wounds showed notable improvement and there was a significant reduction of periwound edema.
- Patient outcomes are shown in Figures 1-4.

Representative Cases

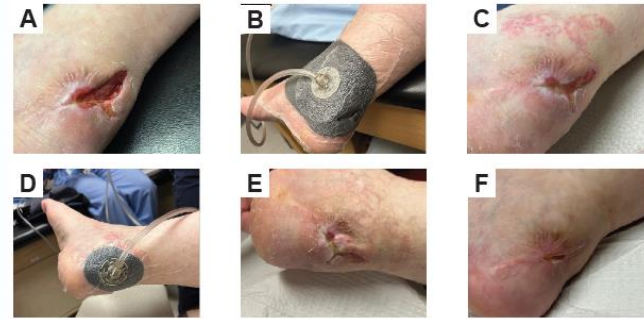


Figure 1. A 40-year-old female with a history of chronic Achilles tendonopathy of the right foot underwent staged repair including adjunct anchor hardware removal. Primary closure was not possible. A) Initial presentation. B) Application of NPWT with MPPD. C) Appearance at first dressing change. D) Application of NPWT with smaller MPPD. E) Appearance at second dressing change. F) Resolution of wound after discontinuation of NPWT.

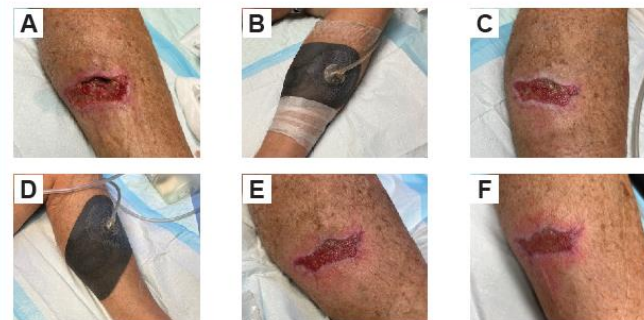

Figure 3. A 77-year-old male presented with a lawnmower blade laceration in the left medial calf, and was referred for advanced wound care. The wound underwent initial debridement before NPWT. A) Initial presentation. B) Application of NPWT with large MPPD. C) Appearance at first dressing change. D) Application of NPWT with MPPD. E) Appearance at second dressing change. F) Appearance at third dressing change; therapy goals met and NPWT discontinued.

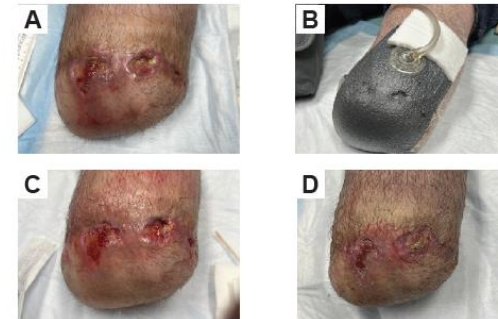

Figure 2. A 28-year-old male presented with a long history of posttraumatic arthritic deformity of the lower leg and foot. A below knee amputation was elected after unsuccessful reconstruction. Delayed surgical healing occurred. A) Initial presentation. B) Application of NPWT with large MPPD. C) Appearance at first dressing change. Pressure increased to -150 mmHg. D) Appearance after second dressing change.

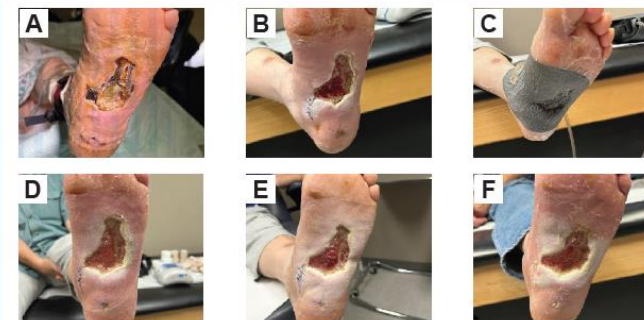


Figure 4. A 65-year-old male presented with a severe foot infection resulting from a puncture wound and retained foreign body. He was found to be diabetic previously undiagnosed with vasculopathy. A) Initial presentation B) Appearance after emergent debridement and foreign body removal, followed by 1 week of NPWT with irrigation and dwelling.† C) Application of NPWT with MPPD. Appearances shown at first (D), second (E), and third (F) dressing changes.

Results (cont'd)

- We observed no periwound maceration in 3 patients.
- In the fourth, maceration was noted at the first dressing change and resolved after negative pressure was increased to -150 mmHg.

Discussion

- We have found it beneficial to consider this dressing for every patient as their wound(s) move through the healing continuum based on trajectory and disposition.
- We have also found it occasionally beneficial to step down in dressing size incrementally, or less commonly, step up in size based on trajectory and disposition.
- Trimming and shaping of drape was helpful with challenging anatomy and in avoiding circumferential drape application.
- Pay attention to the minimum and maximum wound sizes and depths for each dressing.

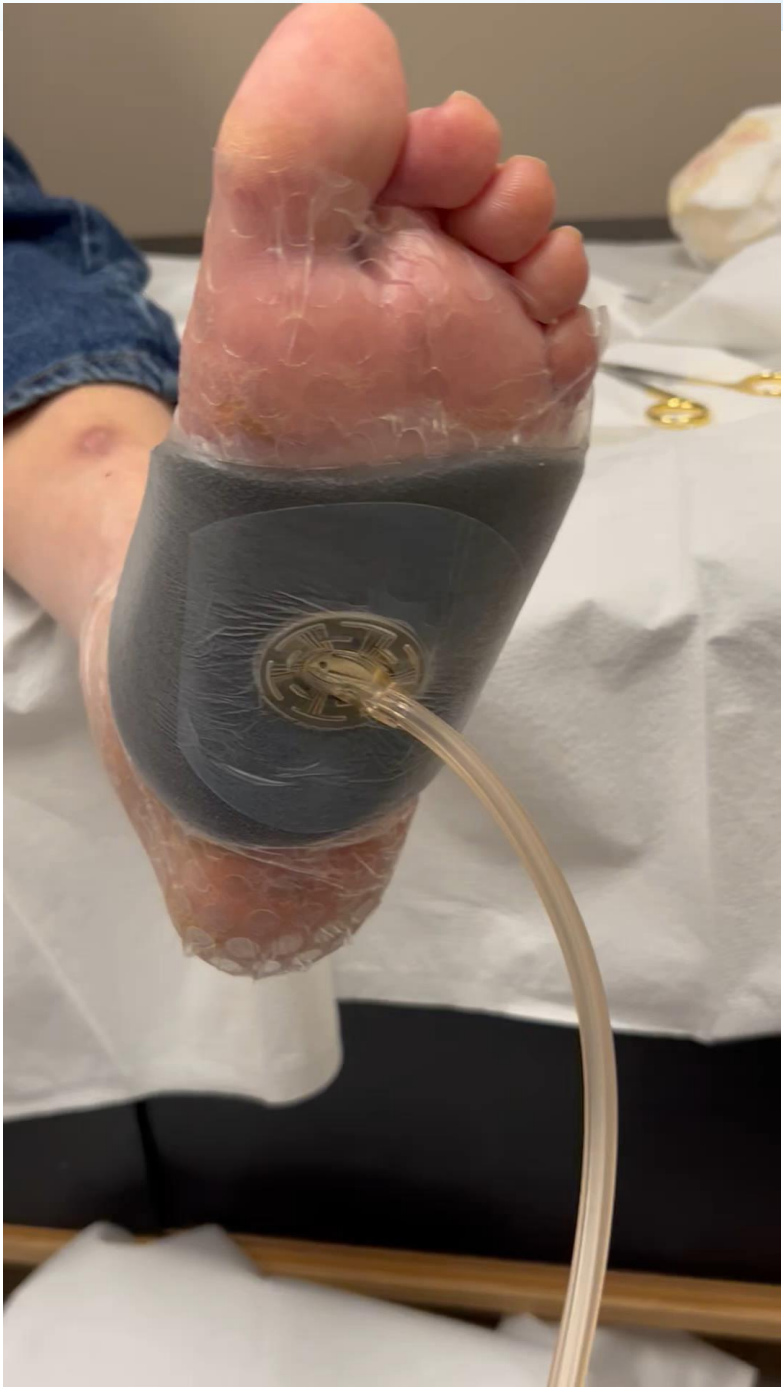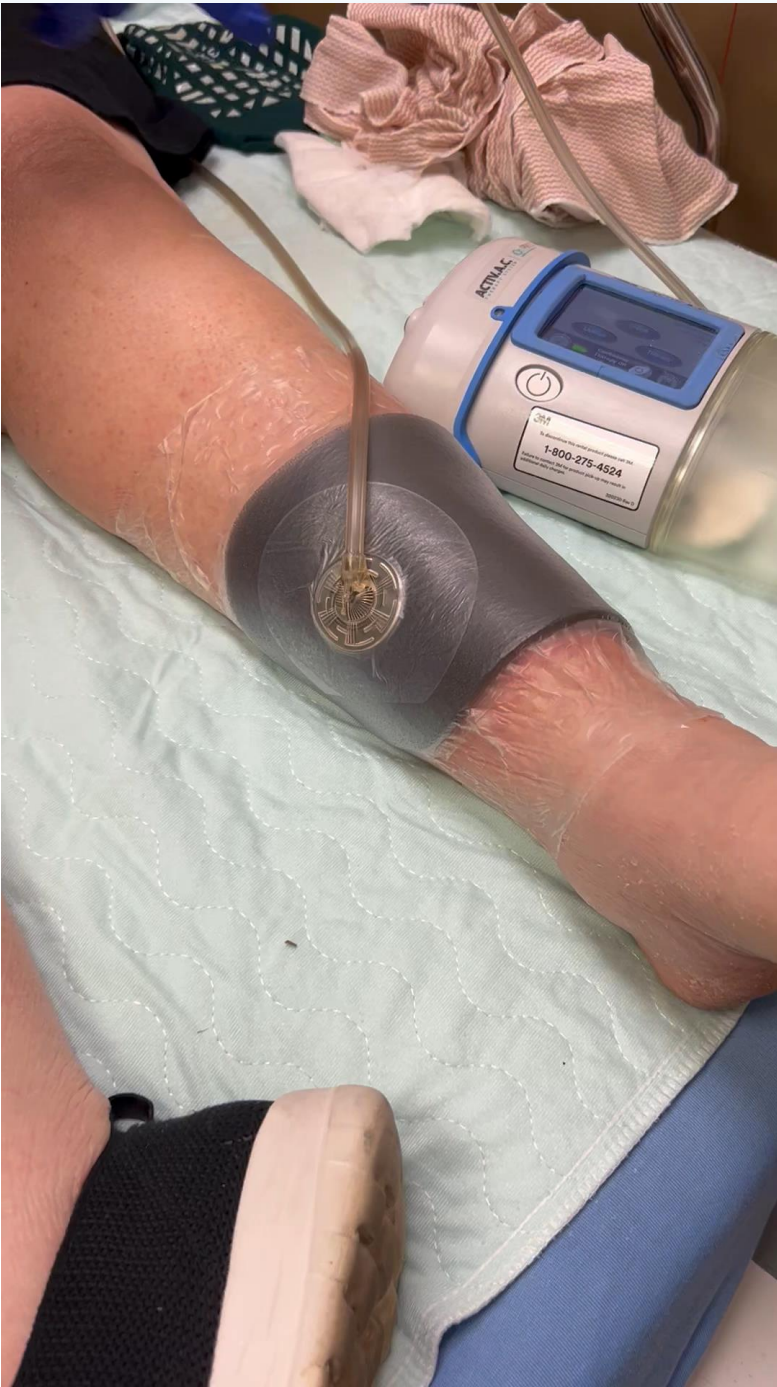Conclusions

- The new NPWT dressing performed as expected, removing exudate and creating an environment conducive to wound healing.
- Application of the MPPD dressing was quick and easy, requiring only minimal trimming or shaping of the drape.

References

1. Capobianco CM, Zgonis T. An overview of negative pressure wound therapy for the lower extremity. *Clin Podiatr Med Surg.* 2009;26(4):619-631.

Peel and Place Draw Down Video Examples



Clinical Pearls

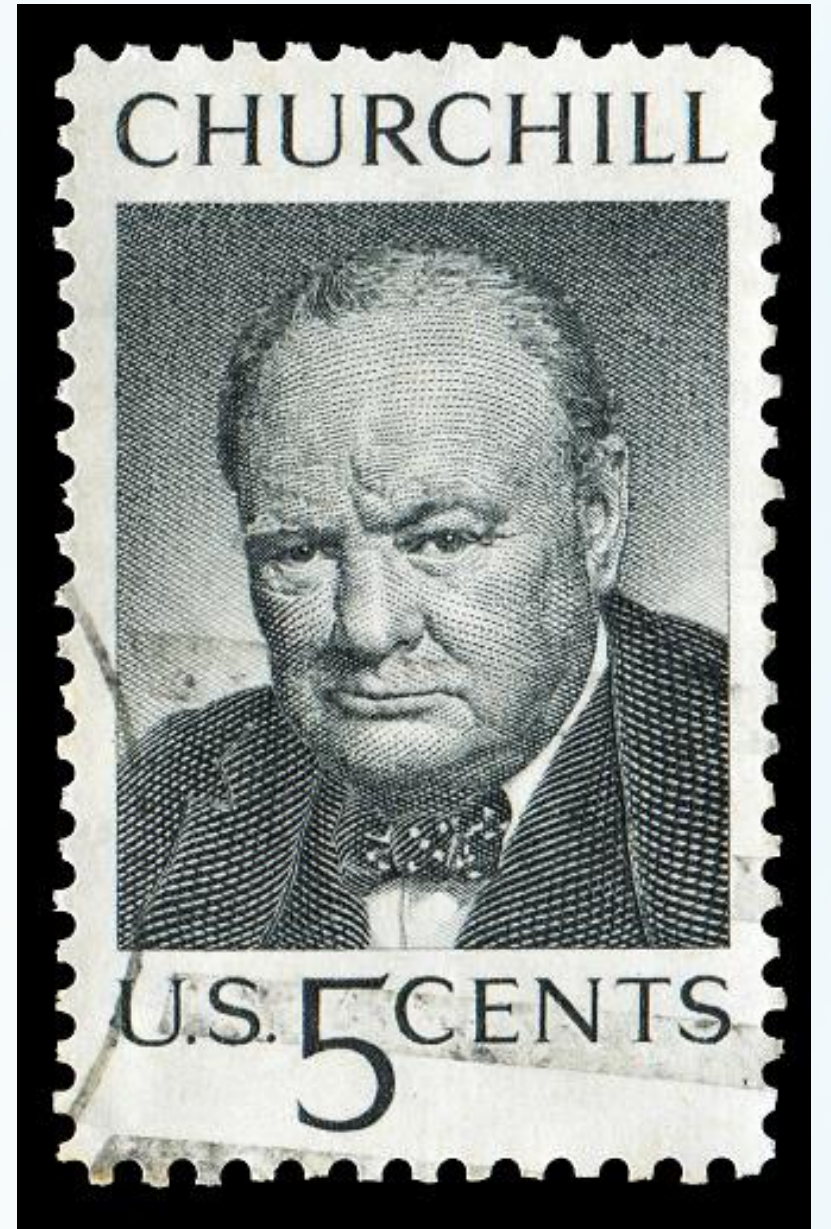
- To date, our region has taken care of several patients with peel and place, utilizing all dressing sizes. *Bravo Central Ohio-based team! Thank you!*
- Less effort than anticipated required for seal creation
- Patient self-guided “drape repairs” were easily executed
- Trimming and shaping of drape was helpful with challenging anatomy and in avoiding circumferential drape application
- For plantar foot wounds, the large dressing with offset aperture allows for trac pad dorsal placement (*pseudo bridge*)
- If necessary, plantar foot wound trac pad placement is feasible
- Low threshold to increase pressure to -150 mm Hg based on wound disposition and periwound appearance

Clinical Pearls

- “Transient dermal deformation” (TDD) at trac pad site was seen on occasion, but with more frequency at -150 mm Hg; in our experience, these changes persisted for several days, but largely resolved (**can lessen effect by changing orientation of trac pad placement at subsequent re-applications*)
- **Marked decrease** in periwound swelling was evident
- In patients who transitioned from “standard VAC” construct to peel and place, marked pain decrease was noted
- Notable canister volume decrease without concomitant dressing saturation was seen compared to traditional VAC construct (*local lymphatic periwound recruitment or some other mechanism*)
- Although hard to quantify fully at this time, healing trajectory seems slightly more robust with peel and place compared to traditional VAC construct (***decreased total time of therapy, wound volume decrease, etc.***)

“To improve is to change; to be perfect is to change often.”

Winston Churchill



Transition from Acute to Post-Acute Setting Using Portable NPWT Technology

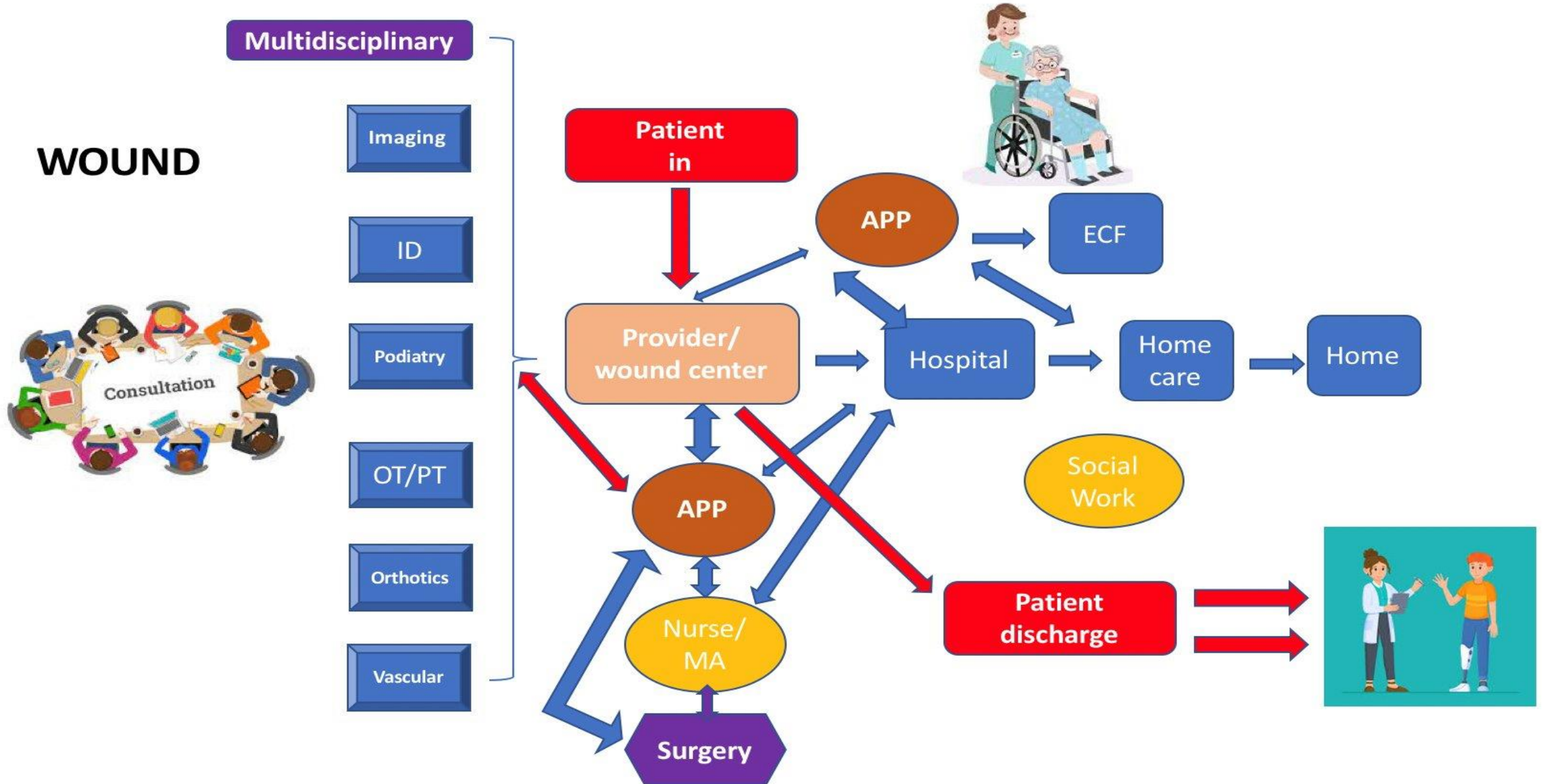
Karen Bauer, DNP, APRN-CNP, CWS, FAAWC

President, Society for Vascular Nursing

Roadmap Overview

- Care setting transition
 - Collaborative and careful planning
 - Focus on patient education, staff training
- **NPWT can improve patient satisfaction, reduce cost, and allow for a comfortable environment**
- **No clear “best” answer for many specific patient-wound scenarios**
- **Needs diligent and HOLISTIC care**
 - **Outpatient:** Reduce readmission, optimize healing, manage exudate, reduce infection risk
 - Home health vs ambulatory clinic
 - **SNF/ECF:** Reduce readmission, optimize healing, manage exudate, reduce infection risk

A Not-So-Linear Trip




Driving Toward Success

- **Reduced Hospital Stays:** Shorter hospitalizations, quicker transitions
- **Improved Patient Outcomes:** Promote healing, reduce surgical needs, improve QoL



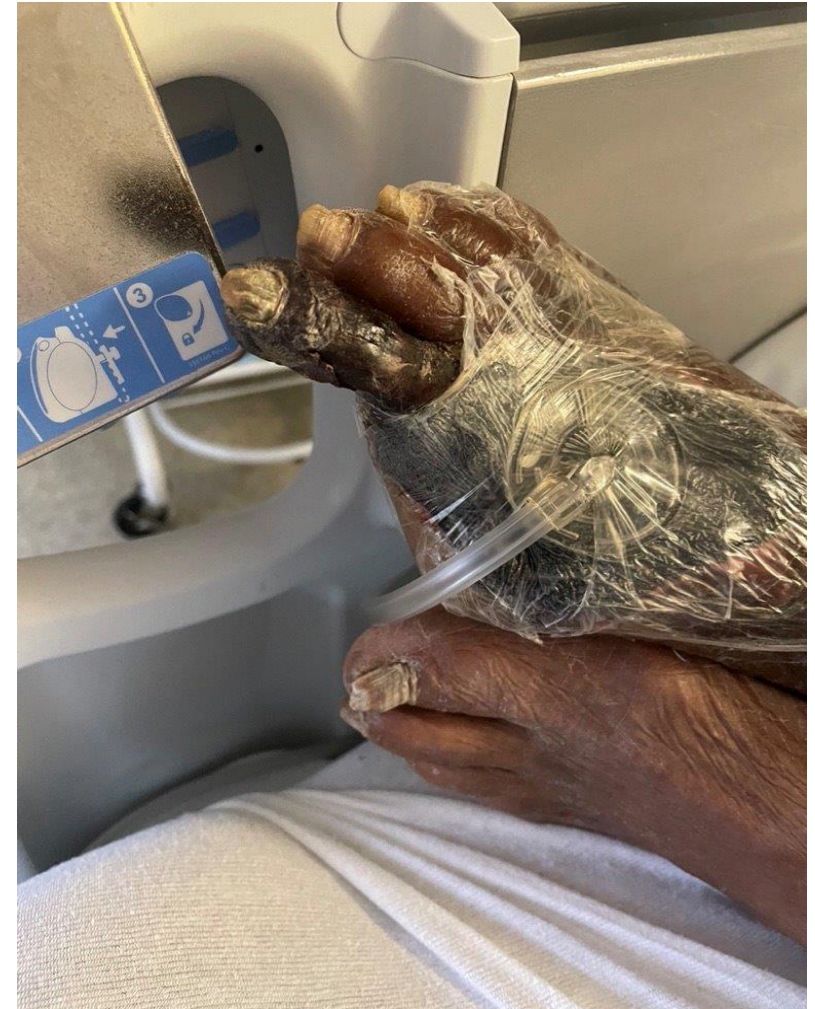Cost Reduction



Mobile NPWT Systems: Easier to manage wounds in outpatient setting

Roadblocks and Detours

- **Training:** NPWT, proper wound care techniques, troubleshooting
- **Logistics:** Access to supplies, equipment, timely communication
- **Patient Education:** Benefits, complications, maintenance
- **Patient Adherence:** NPWT protocols
- **Wound Complexity:** Careful assessment and planning

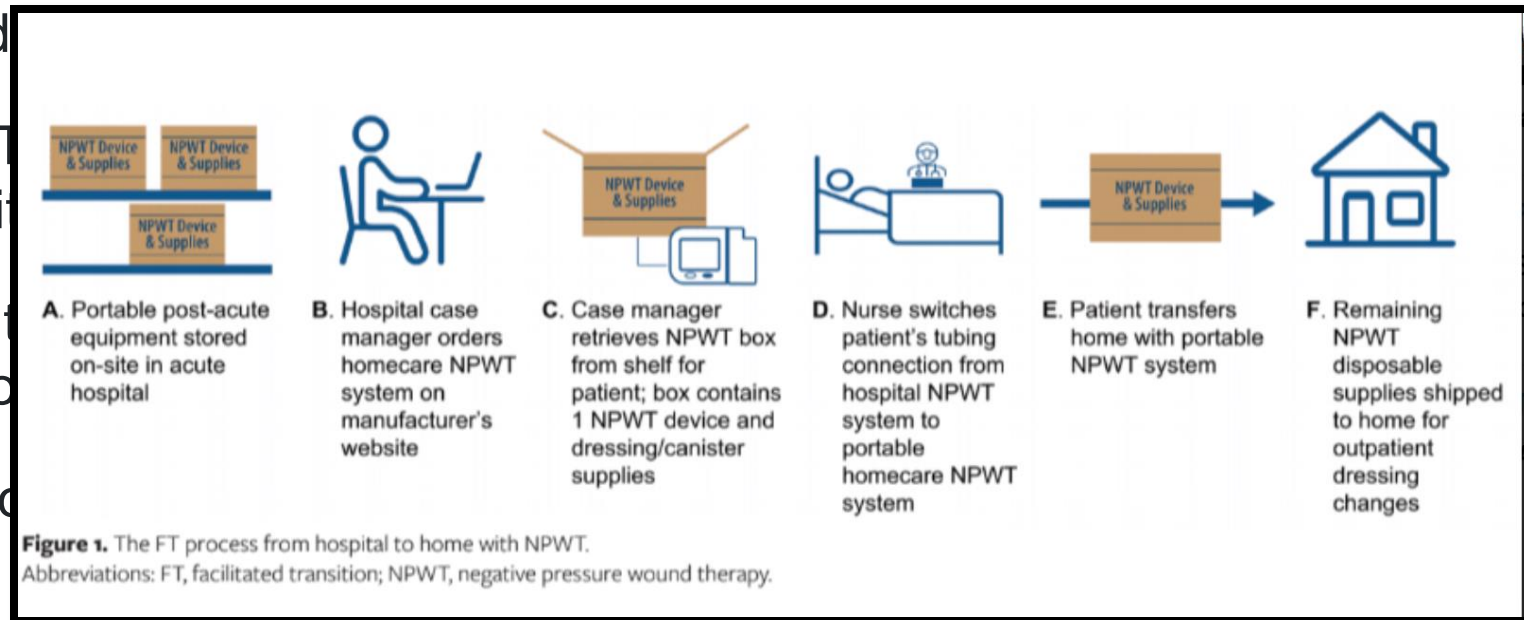


Paving the Path: Tools for the Road

- **Collaborative Care:** Clear communication — written and verbal
- **Patient-Centered:** Assess individual needs, involve patients/families in planning and decision making
- **Comprehensive Training:** Lunch & Learn, shared clinic visits, virtual sessions
- **Standardized Protocols**
- **Access to Resources:** Smart sets, consignment programs, know who has what
- **Consider the use of sNPWT** to assist in transition

Consignment at Discharge

- Discharge processes are complicated and involve many cross-institutional complexities
- Delays in hospital patient discharge are associated with increased cost and risk of infection, lower patient satisfaction, and even mortality
- Study looked at the impact of NPWT on patient discharge
- Inpatient LOT (Line of Transfer) for patient hospital discharge
- Consignment of NPWT at discharge reduces the service burden and cost
- Over 5000 hospital discharges per year




Navigating Patient Education

- Manages fluid
- Removes debris
- Protects the skin
- Can reduce the number of dressing changes
- Can reduce swelling
- What alarms mean
- Don't trip over tubing
- When to call and where
- Odor control
- Camouflage

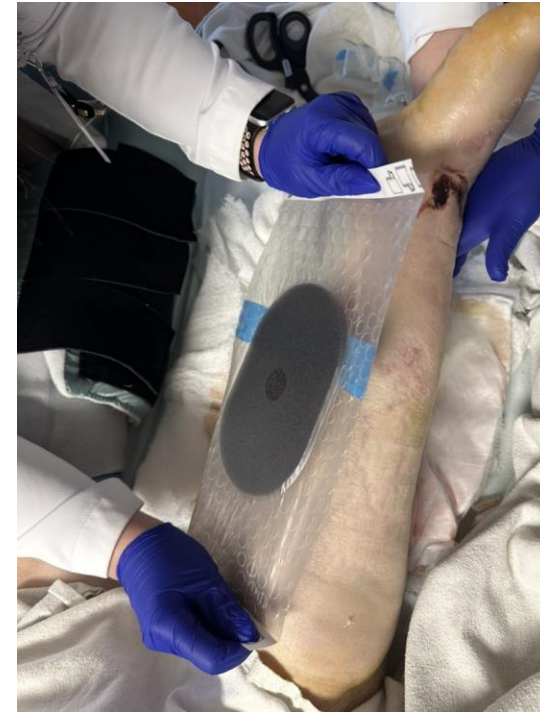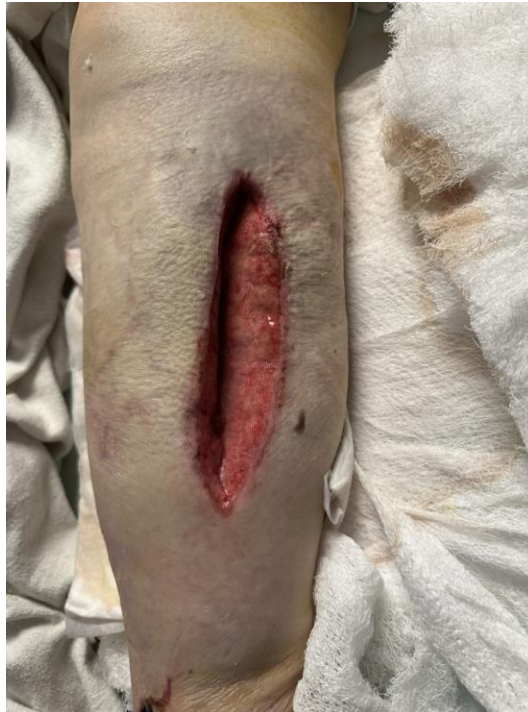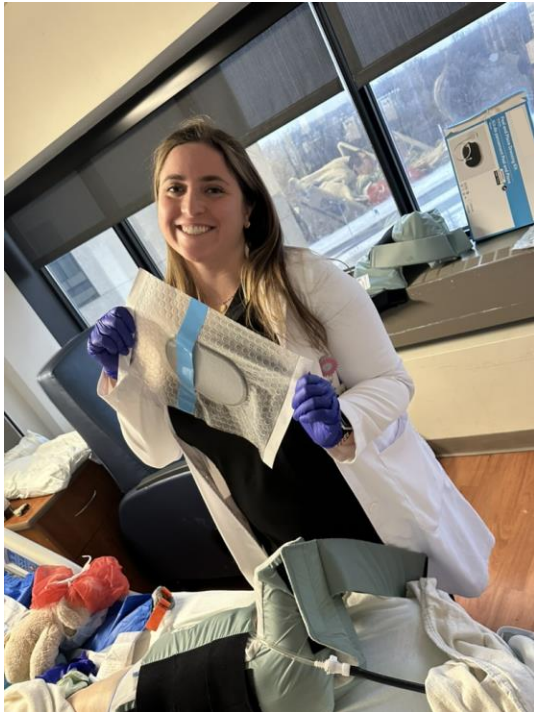Silicone-Hybrid Drape: Best of Both Worlds

- Acrylic (inside the circles) helps provide a tight seal on different anatomical locations
- Silicone (outside the circles) allows for repositioning at initial placement and gentle removal
 - **Easy to use**
 - **No need to use barrier film products**
 - **Less need for window framing**
 - **Single clear release liner**
 - **Less cutting**



Novel NPWT in Acute Care

- **Up to 7-day wear time:** Decreased staff time/supplies with frequent dressing changes
- **All-in-one design:** Reduces staff training and quick application
- Covers entire wound and surrounding tissue for **less than 2min application** on average, saving time in the OR
- Faster dressing applications may **reduce costs** for procedures taking place in OR



Novel NPWT in Ambulatory Care

- **Up to 7-day wear time:** Wound clinic patients who are not eligible for home health visits can benefit
- Available at **no additional cost for at-home patients;** billed to patient's insurance under same code as other NPWT dressings

Home Health

- 3x the wear time; 1/3 of the nursing visits
- Fewer dressing changes mean home health agencies accept more NPWT patients — volume
- Easier application for clinicians who may not have experience or confidence applying NPWT on more complex wounds

Closed Incision

- Support needed
- Conceal tubing/dressing
- Expand involvement and self care
- Individually tailored information is essential for transition from hospital to home and that written information needs improvement

Journal of Vascular Nursing 41 (2023) 171–179



ELSEVIER

Contents lists available at ScienceDirect

Journal of Vascular Nursing

journal homepage: www.sciencedirect.com/journal/journal-of-vascular-nursing

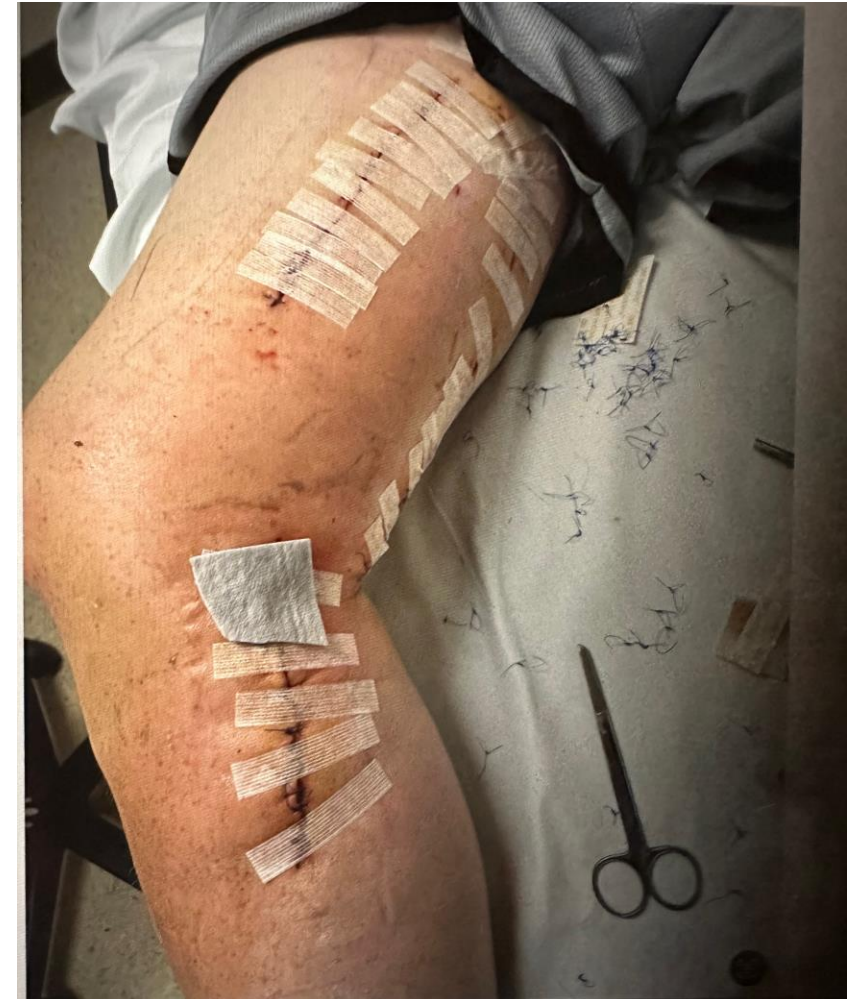

Patient experiences of closed-incision negative pressure therapy on groin incisions after discharge following peripheral arterial surgery: A qualitative study

Camilla Borch Graversen, RN, BScN^a, Malene Missel, RN, MScN, PhD^b, Sally Jakobsen, RN, MScN^{a,*}

^a Department of Vascular Surgery, Copenhagen University Hospital – Rigshospitalet, Inge Lehmanns vej 5, 2100 Copenhagen, Denmark

^b Department of Cardiothoracic Surgery, Copenhagen University Hospital – Rigshospitalet, Inge Lehmanns vej 5, 2100 Copenhagen, Denmark





Polling Question

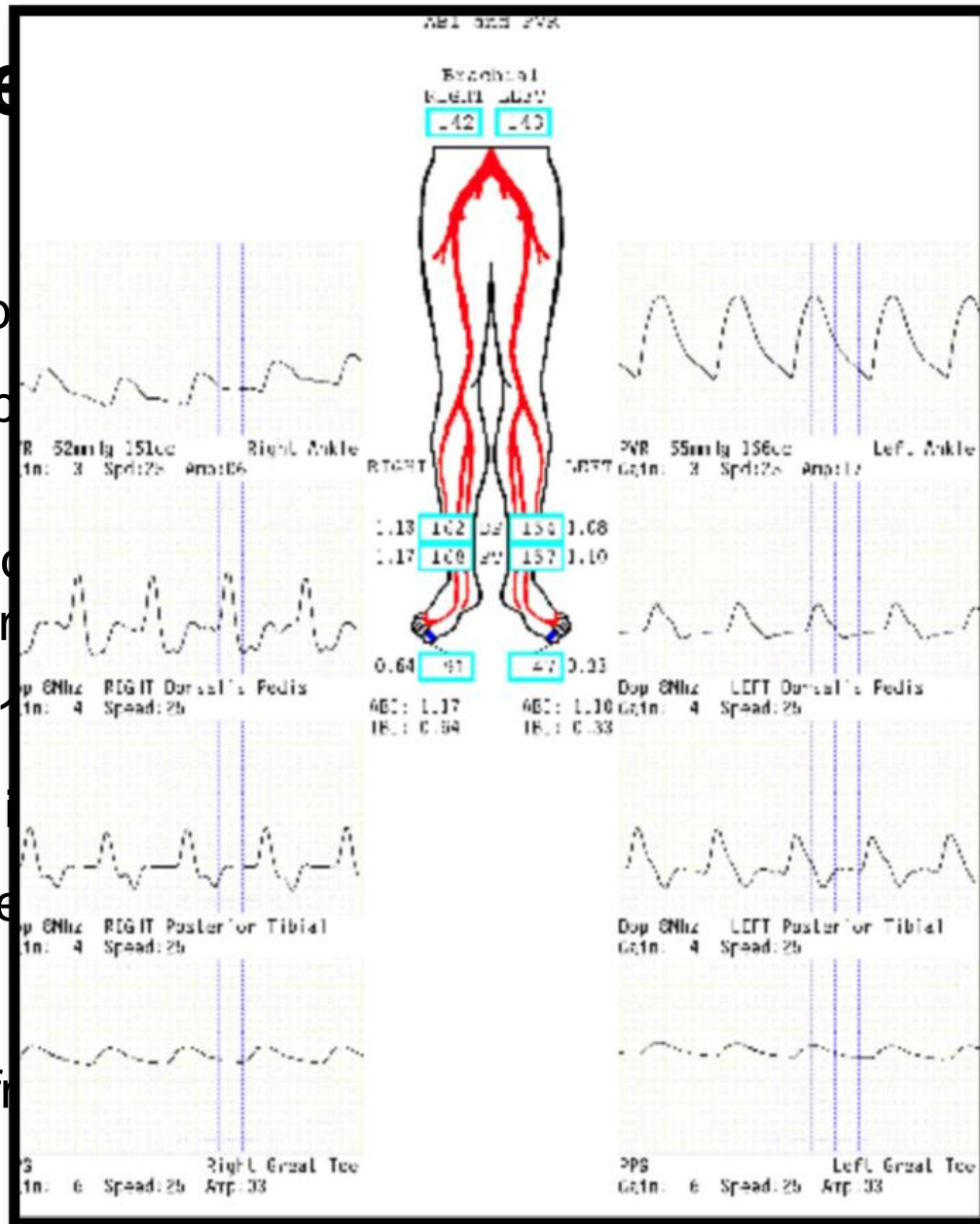
NPWT is standard across the care continuum and doesn't require modifications or flexibility to account for unique patient factors

- A. True
- B. False

***Polling was pre-recorded.**

Case: Unplanned

- 68y Female
- PMH/PSH: Gastric bypass
- Presented 2/2 diffuse body
malaise, anorexia
- CT: Atrophic pancreatic
colitis edema, left pleur
- Lap-assisted ERCP 6/1
- Rheumatology: Vasculi
- ECHO: Noted clot in pe
- Venous DUS negative
- Biopsy of LLE wound fr
(dermatopathology)
- High-dose steroids with taper at discharge

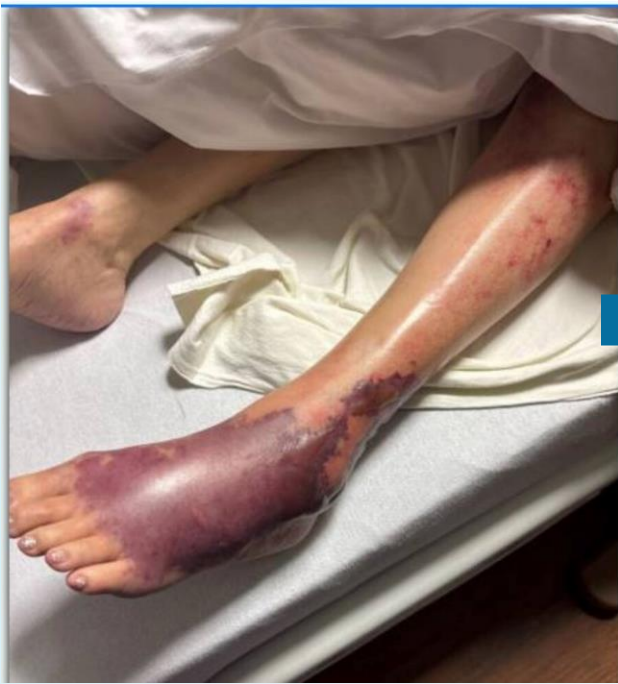

treatment Changes

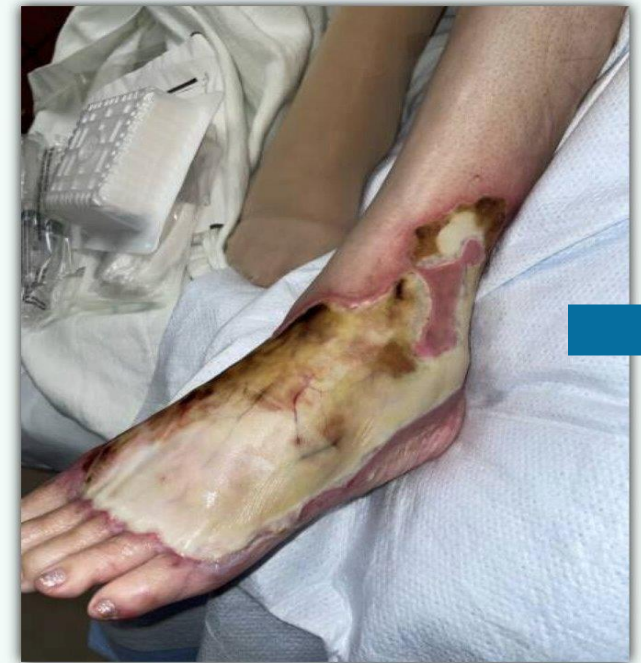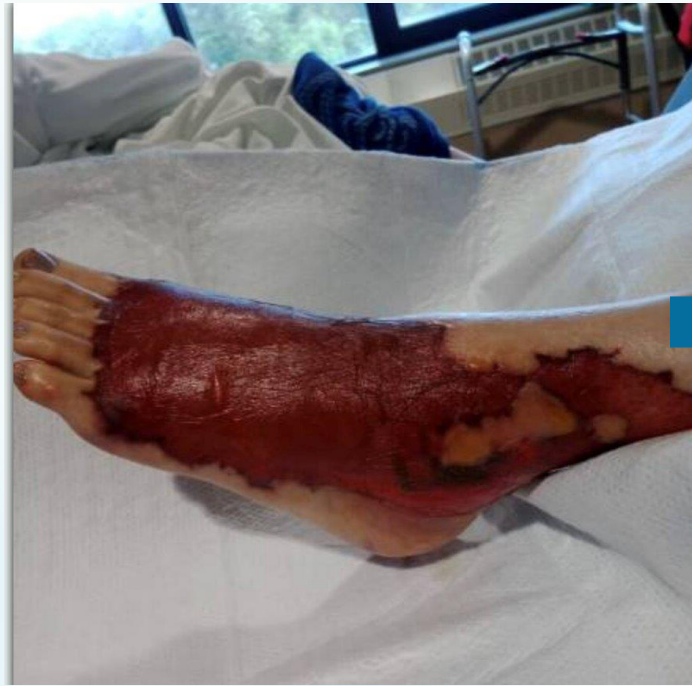ling, blistering, bruising

ejunojejunosomy, nonspecific

non-specific



June

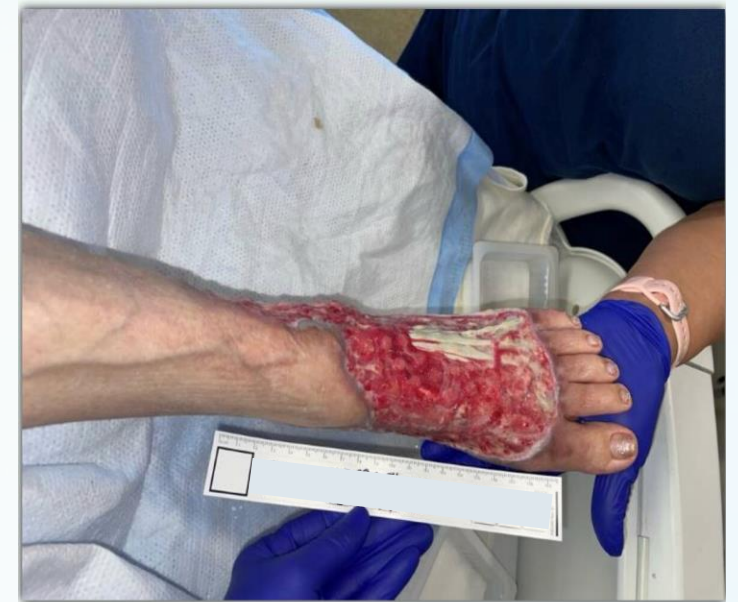
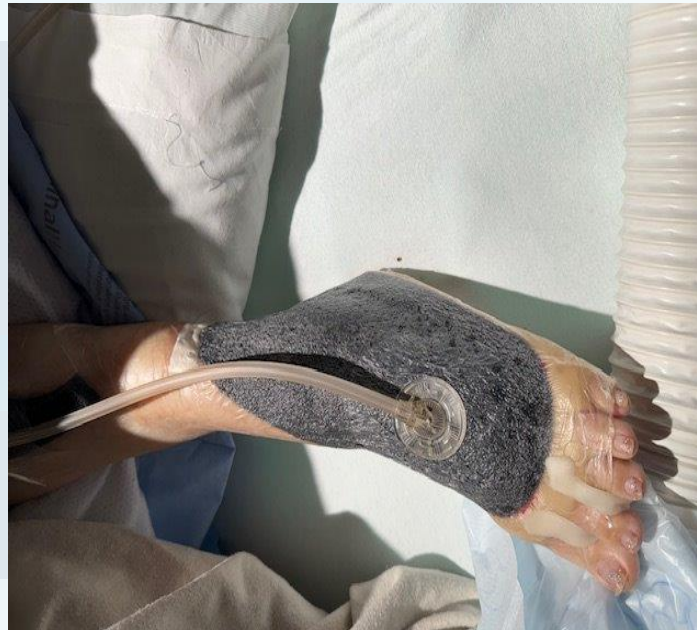
July

NPWTi-d after OR with HOCl

10min dwell time q2hrs at
-125 mm Hg, 3x/wk

Multidisciplinary Coordination
GIM; ID; Rheumatology; Vascular

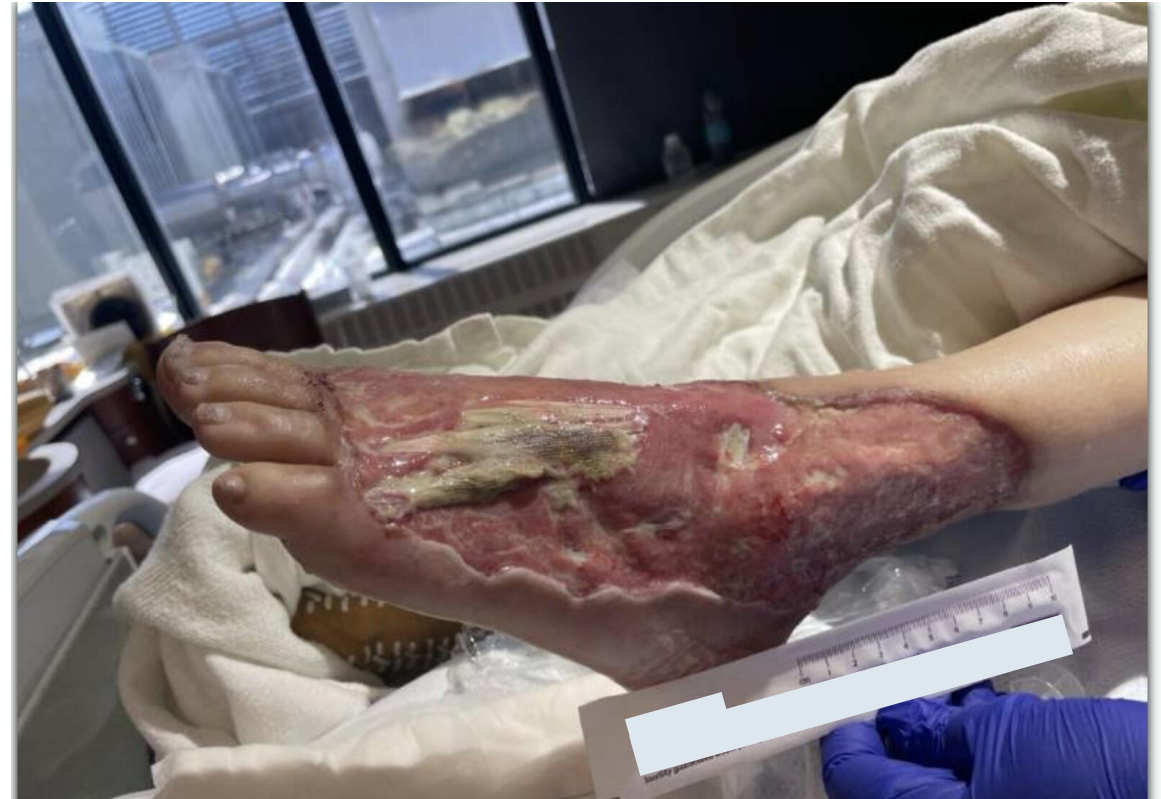

Real-World Obstacles

Challenges

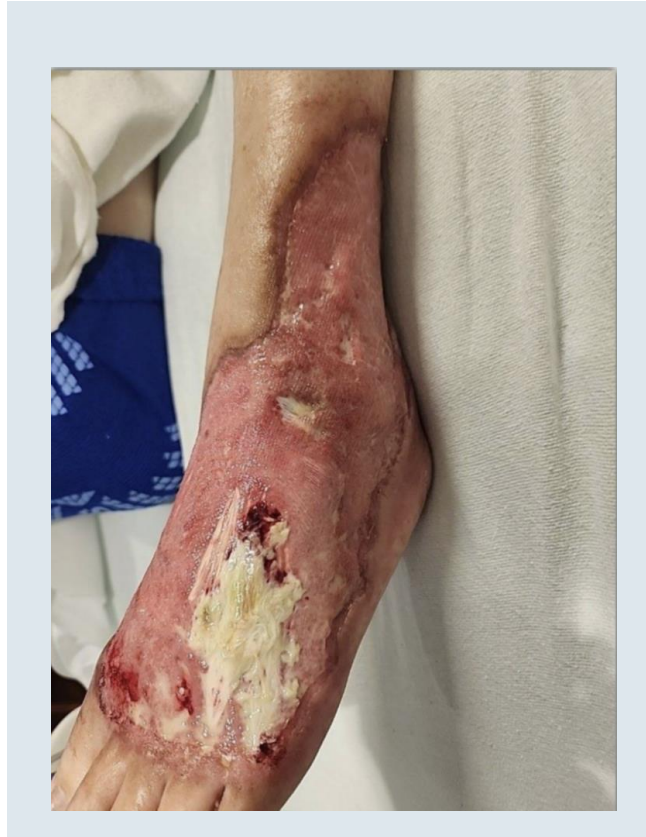- Pain control
- Health literacy
- Isolation
- Ulcer location
- Etiology not fully delineated
- NPWT varied
- **Care transition** 

Portable NPWT with non-adherent over tendon, black foam, 75 mm Hg with titration goal 125 mm Hg, as tolerated



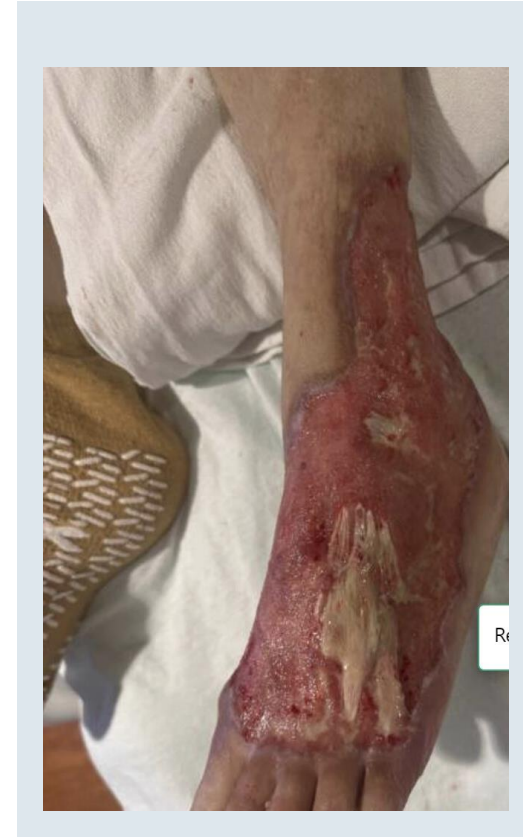August

Interrupted NPWT: Consider Patient Factors!



Sept 10

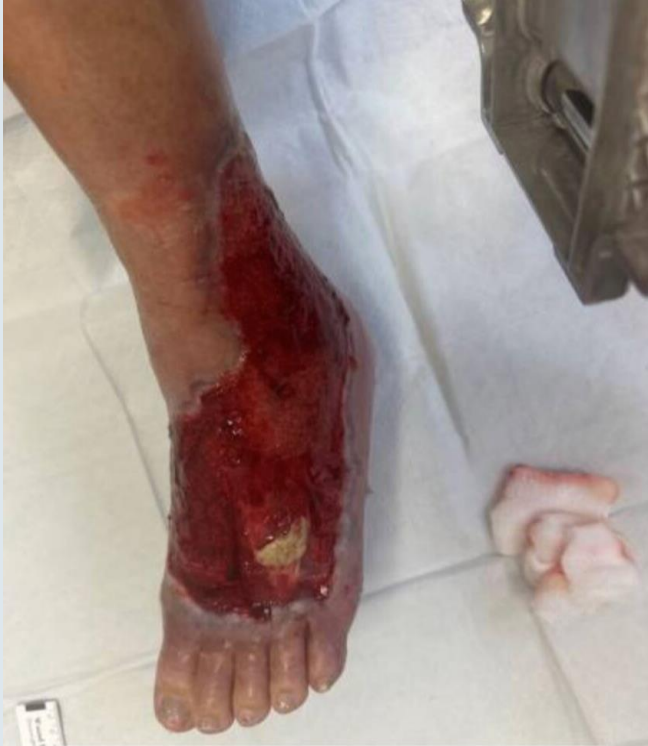NPWT held prior at ECF-
Readmitted, started novel NPWT



Sept 14

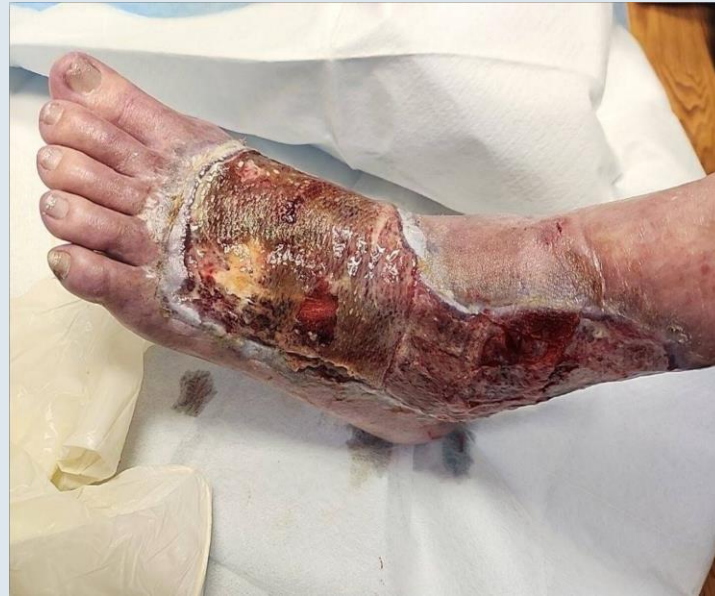Discharged on portable NPWT
Non-adherent, black foam, -75 mm Hg

Multi-Modal Therapy



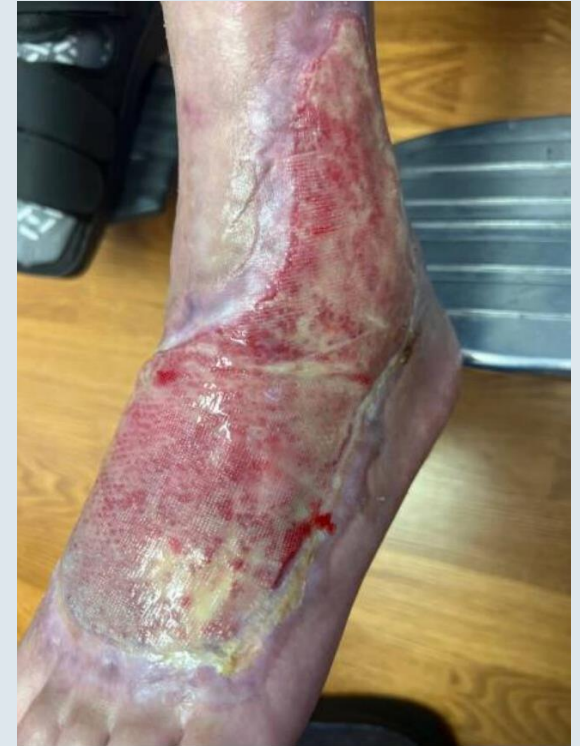Oct 5

CTP/Wash-out booked



Oct 14

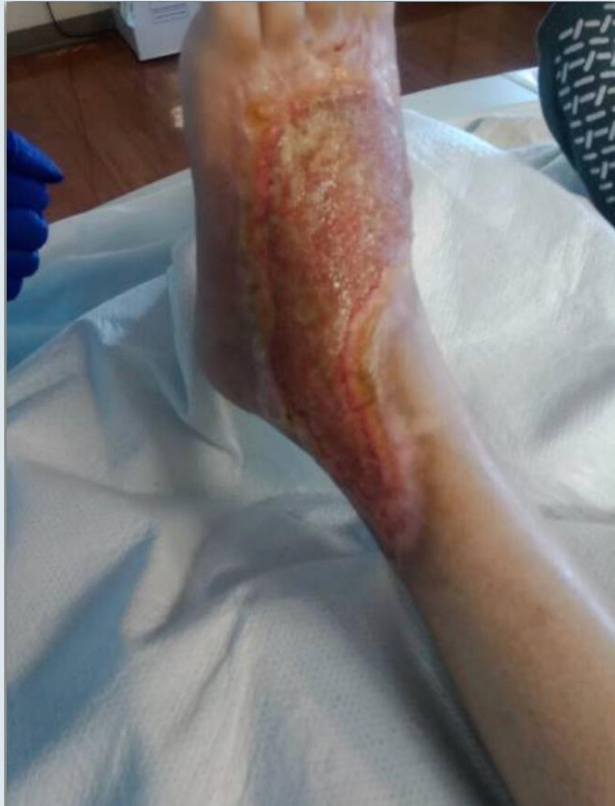1 wk post CTP: portable NPWT
Non-adherent, black foam, -75 mm Hg



Oct 26

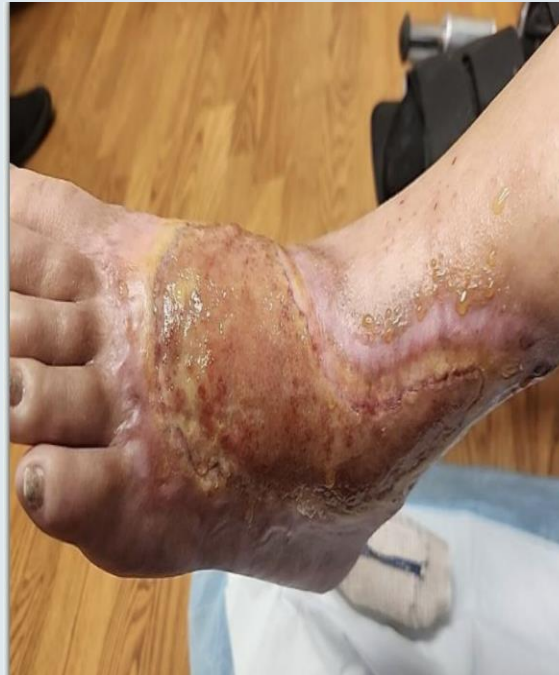Portable NPWT
Non-adherent, black foam,
-75 mm Hg

Inpatient to Outpatient Transitions — Coordination



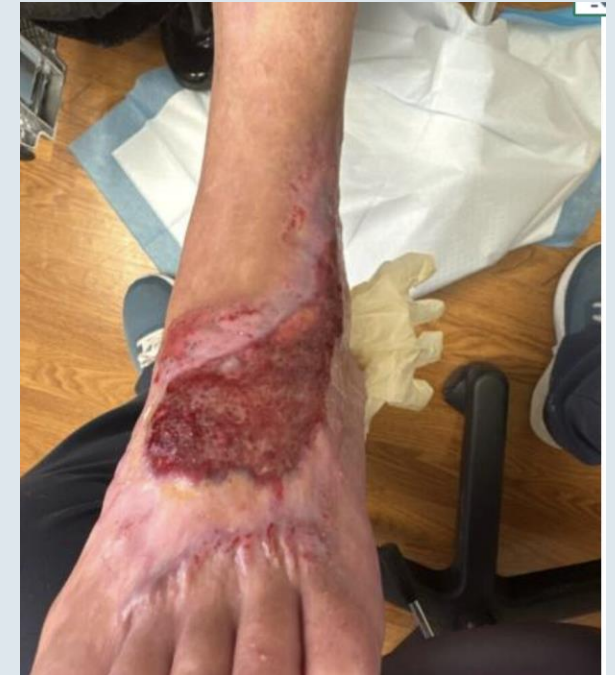Nov 24

Inpatient: Peel and place



Dec 2

**Portable NPWT
Non-adherent, black foam, -75 mm Hg**



Feb 12

Collagen, off dapson



Polling Question

Novel NPWT (peel and place) can be applied in which setting?

- A. Acute care
- B. Ambulatory clinics
- C. Home care
- D. All of the above

***Polling was pre-recorded.**

Clinical Pearls

- Clinical algorithm useful
- Need for flexibility
 - Care setting
 - Skill/training/comfortability of teams
 - Insurance
 - Patient tolerance and needs
- Step down consideration with subsequent monitoring; can backtrack, if needed
- Safety first
- Shared decision making!

TEAMS



Case-Based Exploration: Components of the NPWT Toolkit

Britney Butt, MCISc(WH), BScN, RN, NSWOC, WOCC(C)

Keck Medical Center of USC

Los Angeles, CA



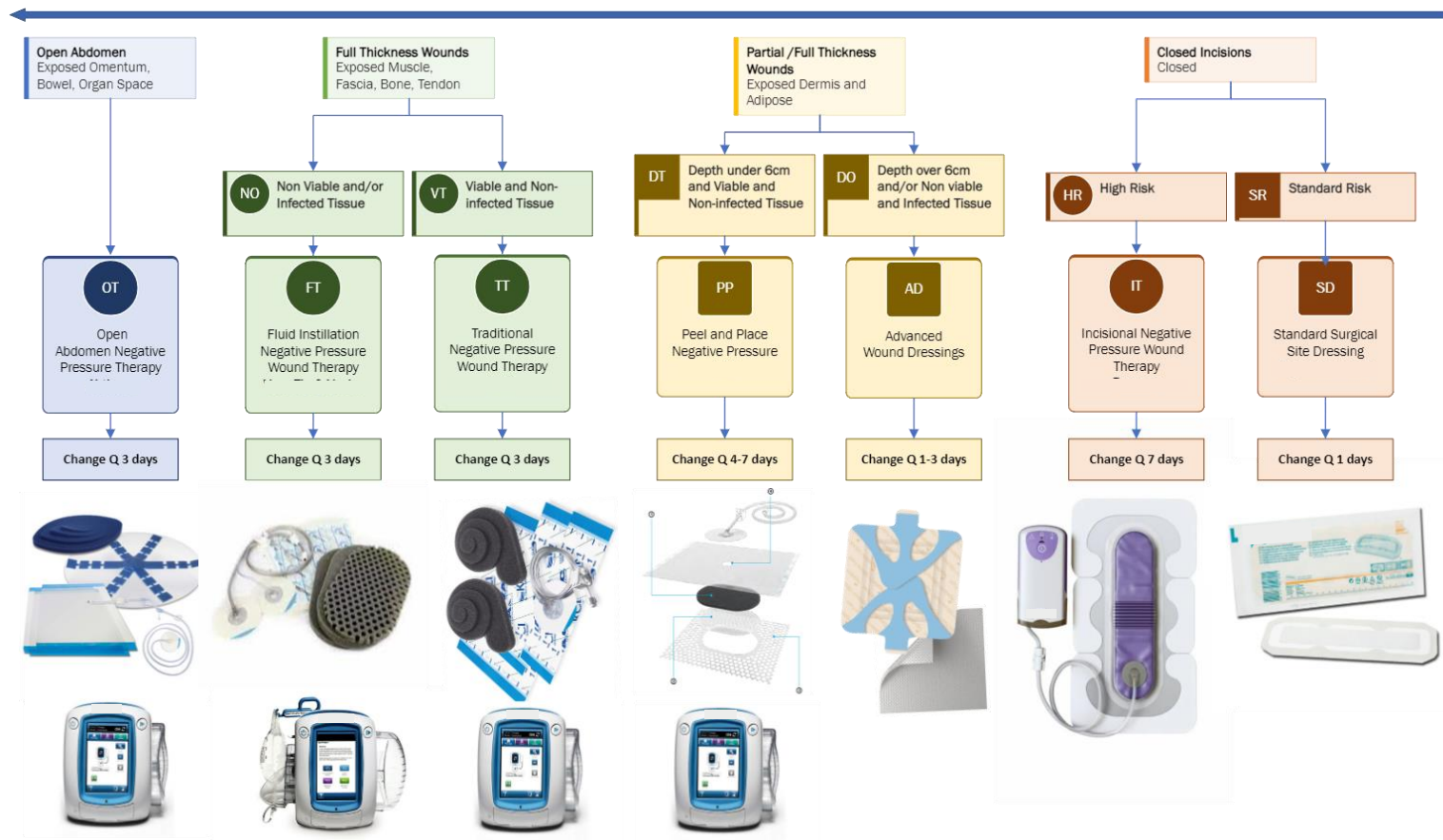
Polling Question

Does your organization have an algorithm for the selection of negative pressure?

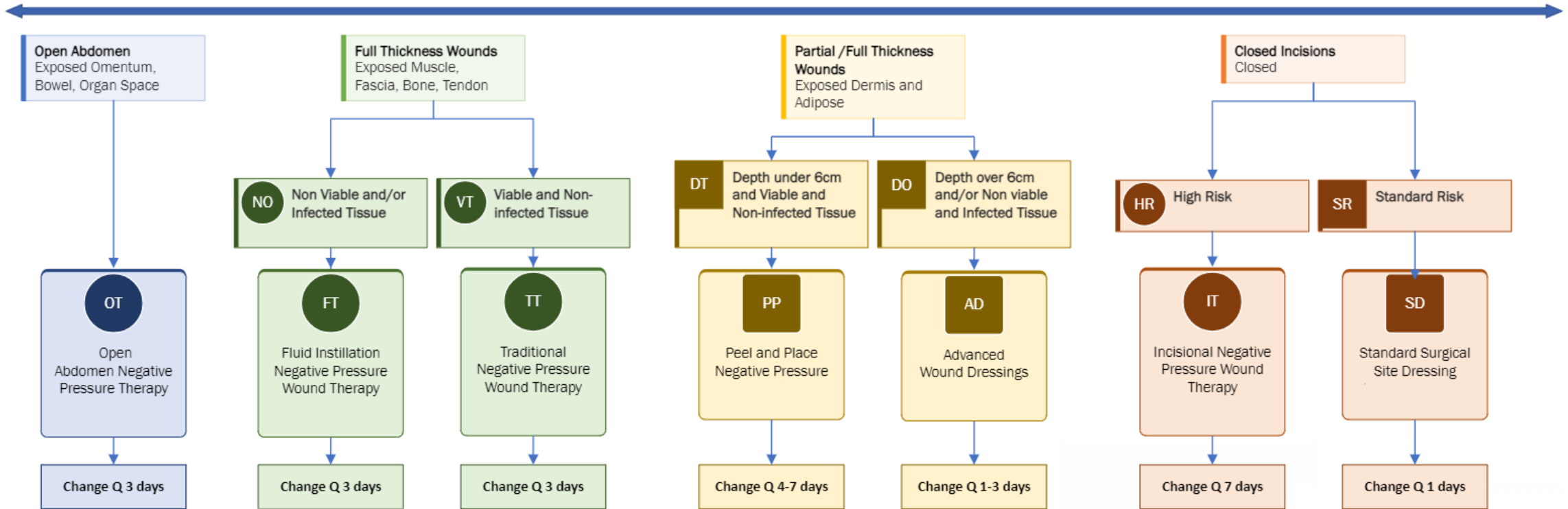
- A. Yes, and we use it!
- B. Yes, but we seldom use it.
- C. No, we do not have one.
- D. I have no idea if we have one.

***Polling was pre-recorded.**

Transitions in Care Needs



Transitions in Care Needs

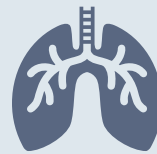

Cases

Sacral Stage 4 Pressure Injury



PMX: Hypertension, Graves'

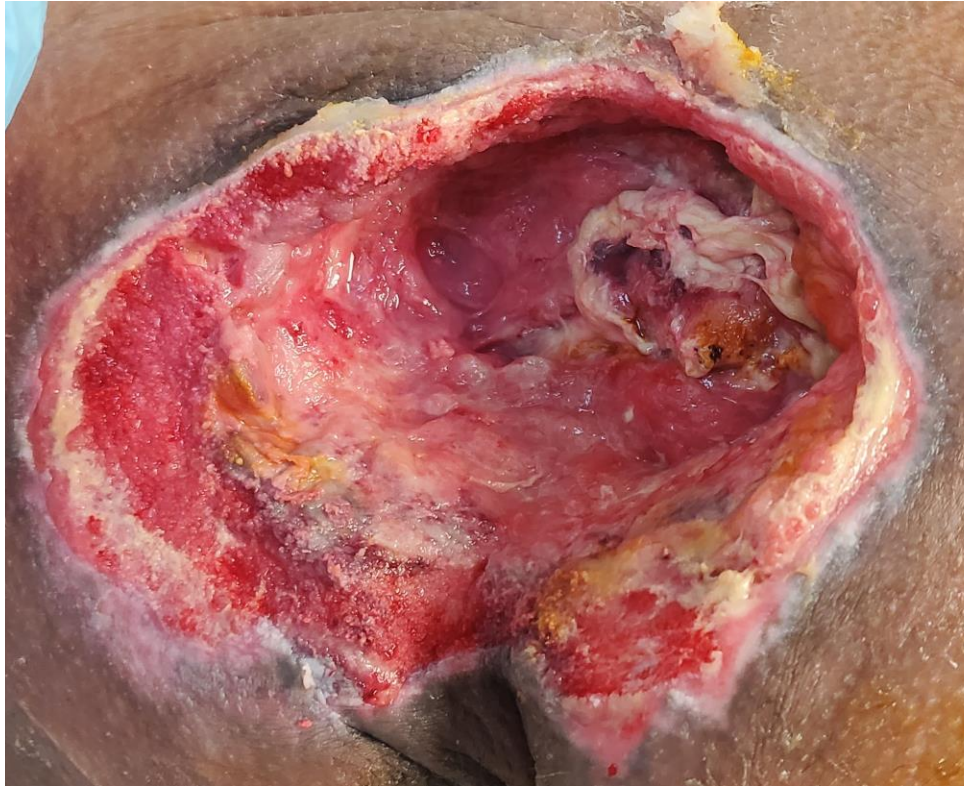


Patient in 40s admitted during COVID 2nd to COVID-related complications resulting in stroke, lung damage, and pressure injury



Wound originally seen and treated conservatively

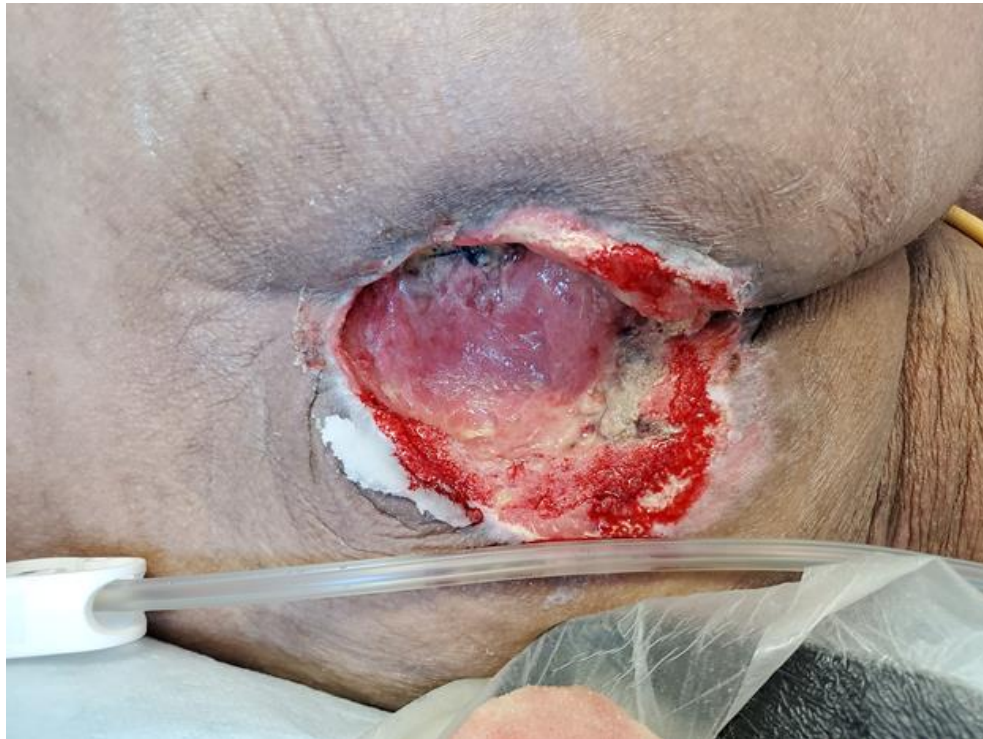Stage 4 Pressure Injury



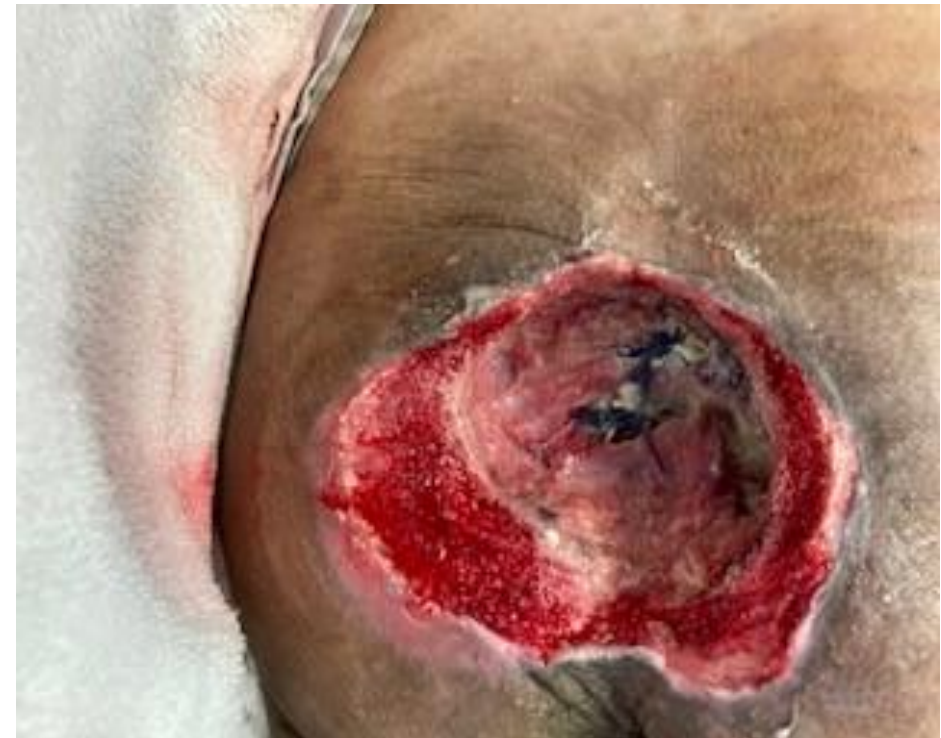- **Day 1 (182 days in ICU)**
- Serial debridements had been completed on the patient along with antibiotics
- There was still fragmented bone and purulence coming from the wound
- Traditional negative pressure was initiated at -125 mm Hg, low continuous

Stage 4 Pressure Injury

Day 8

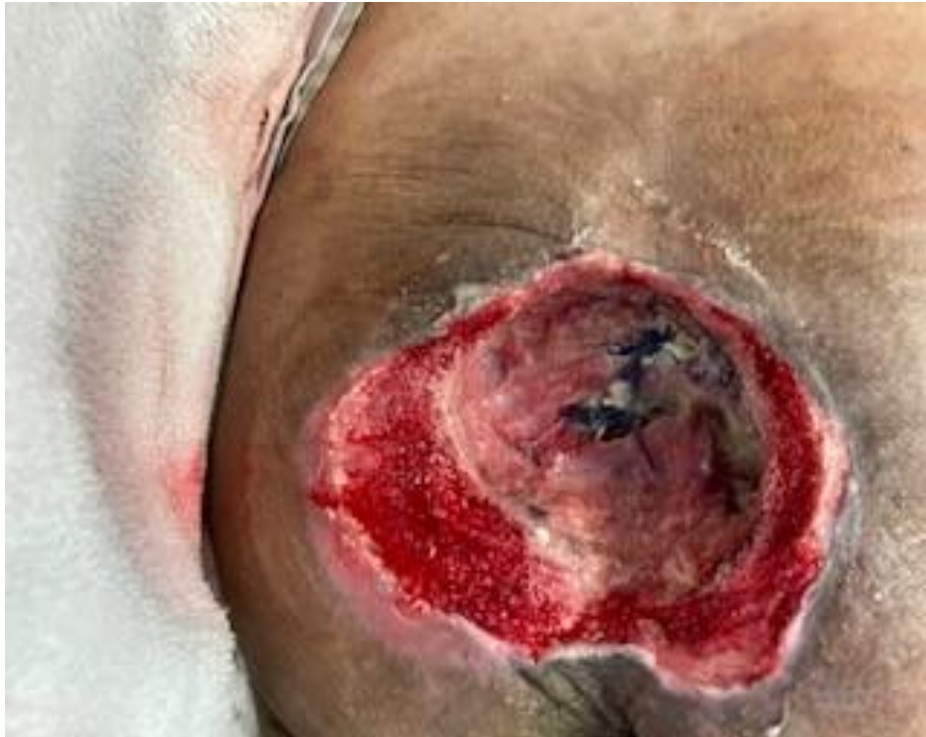

Day 15



Despite several interventions, the patient's wound still showed minimal proliferative changes.

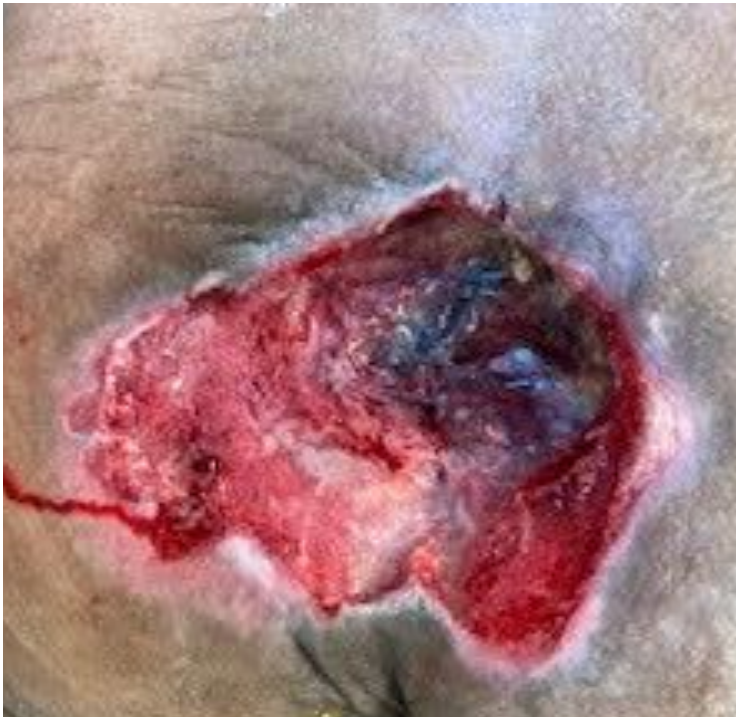Stage 4 Pressure Injury



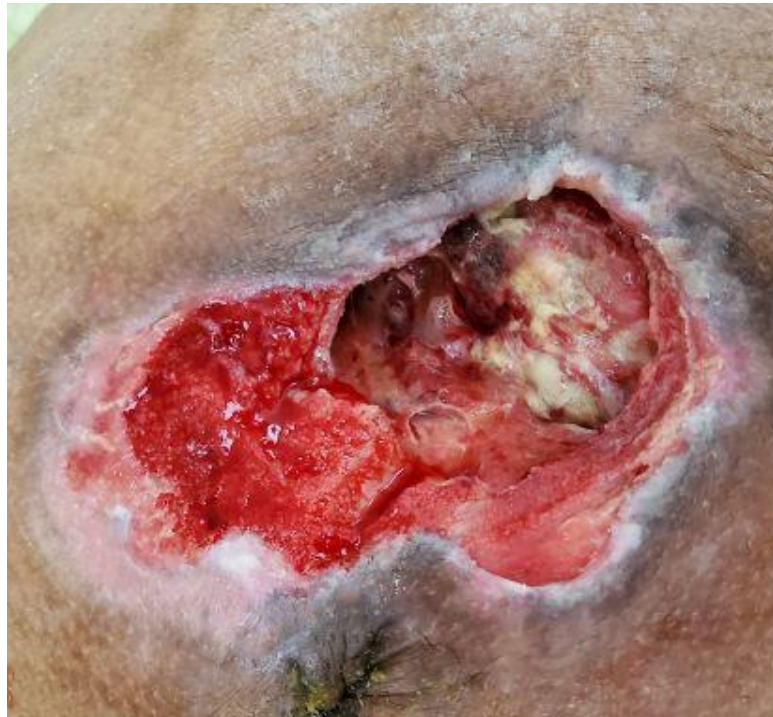- **Day 15**
- Initiated instillation negative pressure
Settings: -125 mm Hg medium continuous |
10min dwell time with 2hr interval
- Instillation solution: PHMB

Stage 4 Pressure Injury

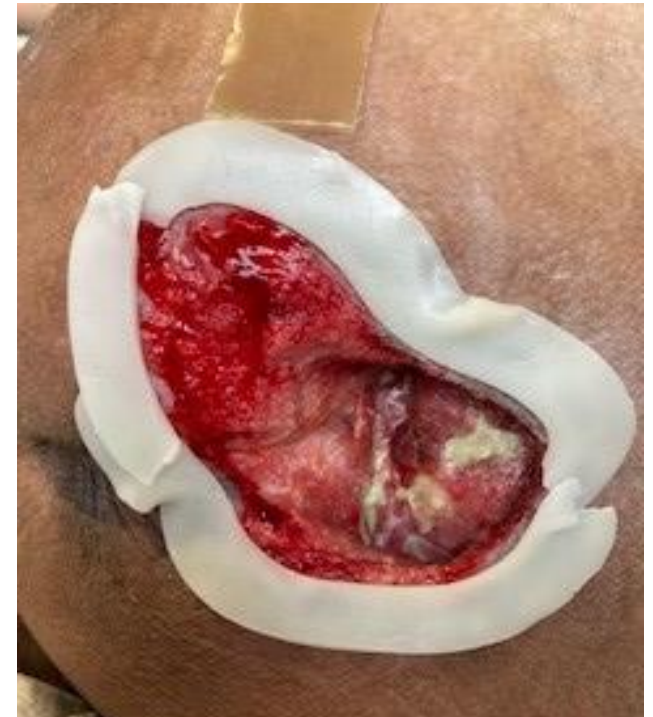Day 18



Day 28

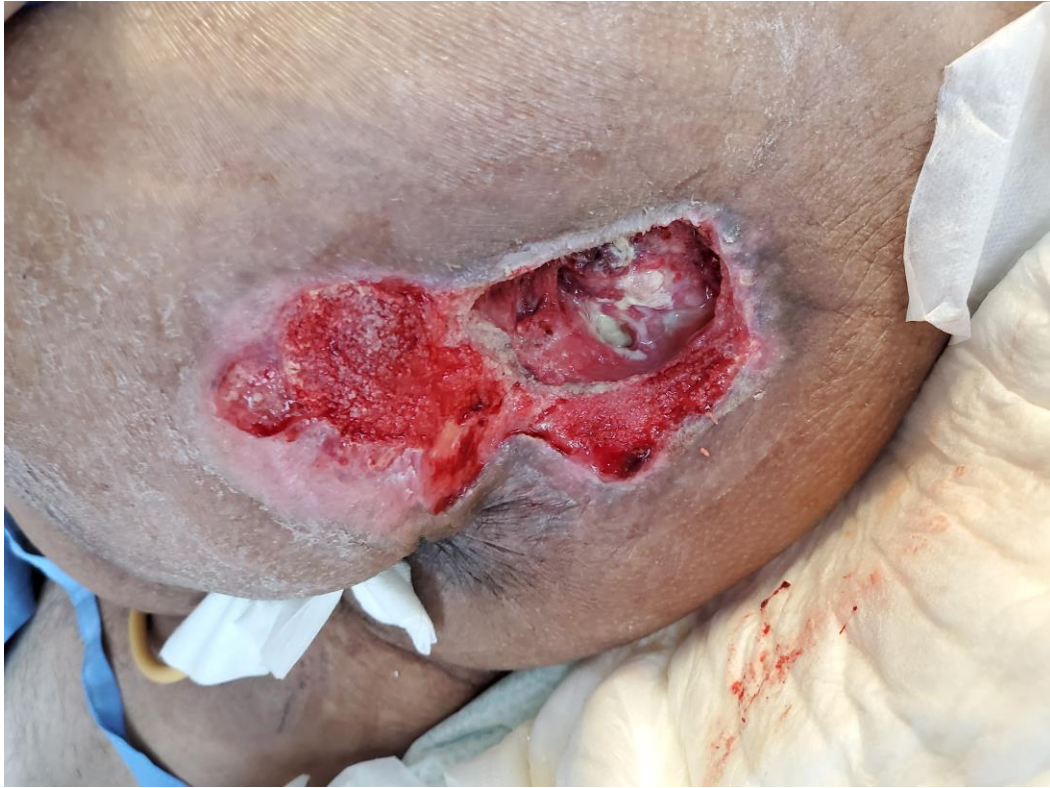

Day 31



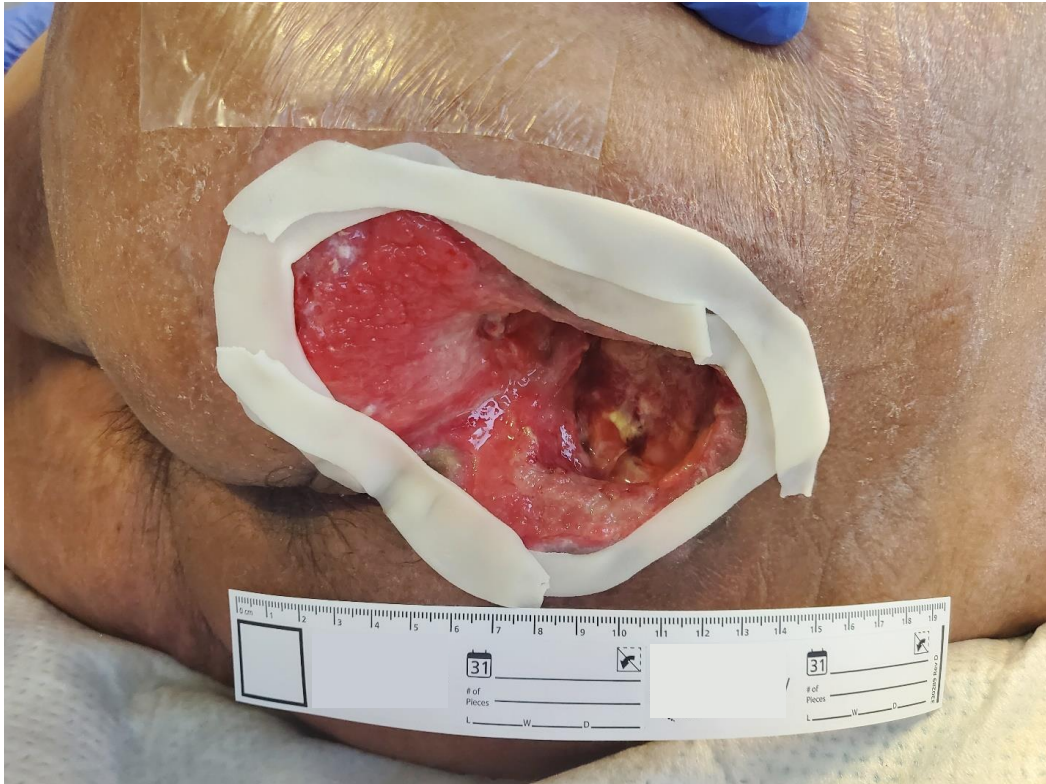Continued instillation negative pressure

Stage 4 Pressure Injury



- **Day 34**
- Wound improving, no signs of infection
- Instillation negative pressure was discontinued
- Traditional negative pressure was initiated at -125 mm Hg, low continuous

Stage 4 Pressure Injury



- **Day 44**
- Wound deteriorating, increasing hyper granular tissue, odor, and purulence
- Traditional negative pressure was discontinued
- Instillation negative pressure was reinstated
- Settings: -125 mm Hg medium continuous | 10min dwell time with a 2hr interval
Installation solution: PHMB



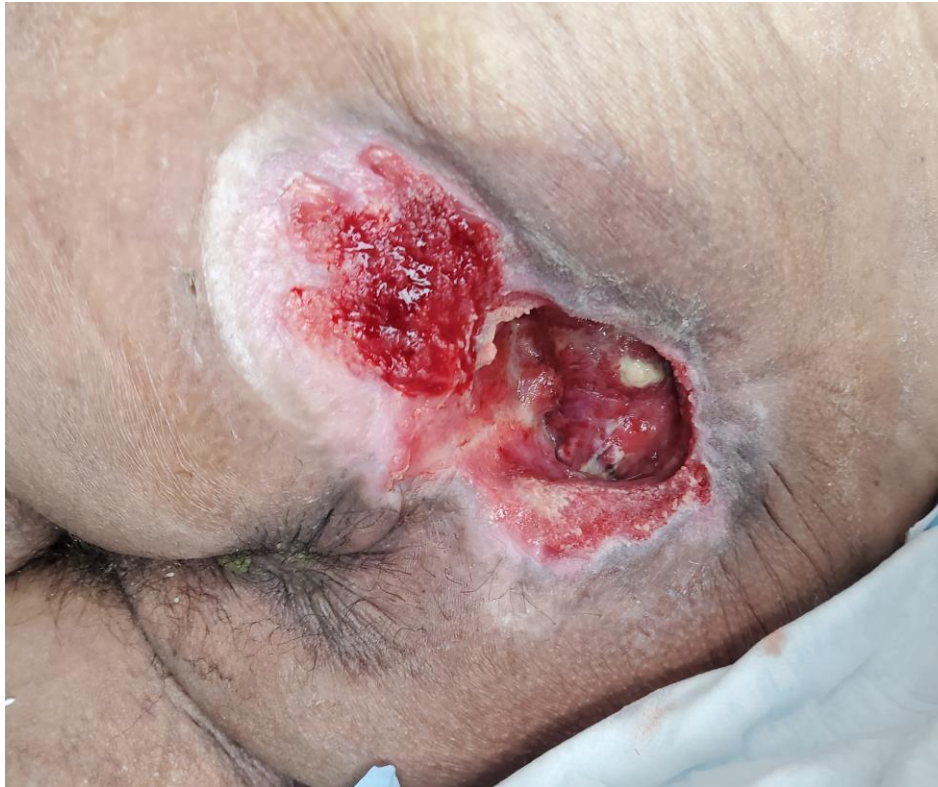Polling Question

How would you treat this wound after seeing this deterioration?

- A. Continue with traditional NPWT
- B. Switch back to instillation NPWT
- C. Remove negative pressure altogether and use conventional dressing

***Polling was pre-recorded.**

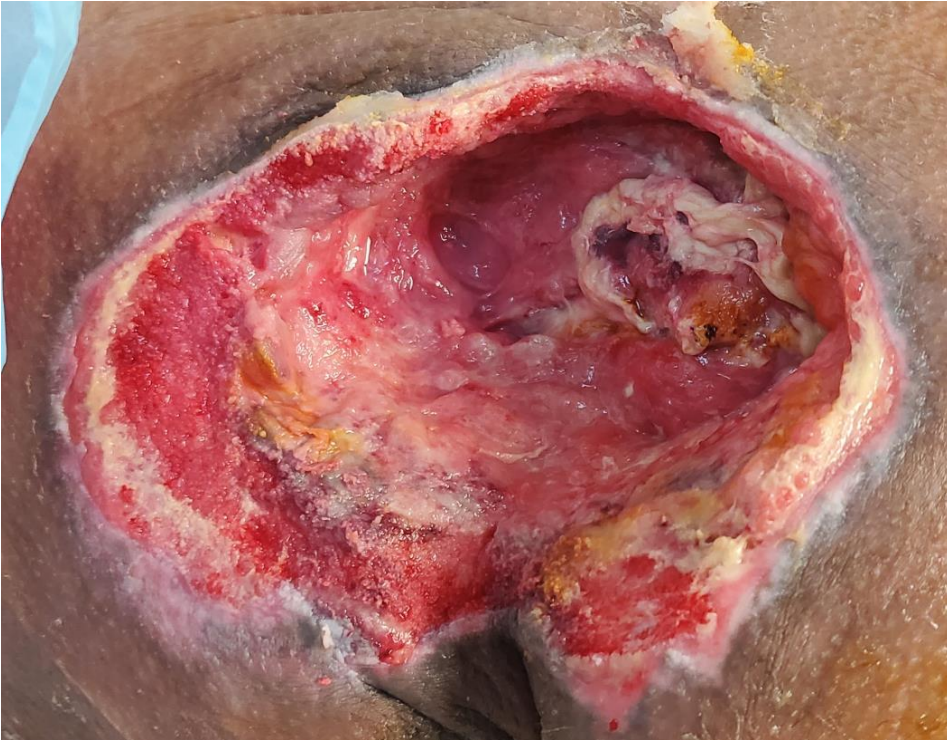Stage 4 Pressure Injury



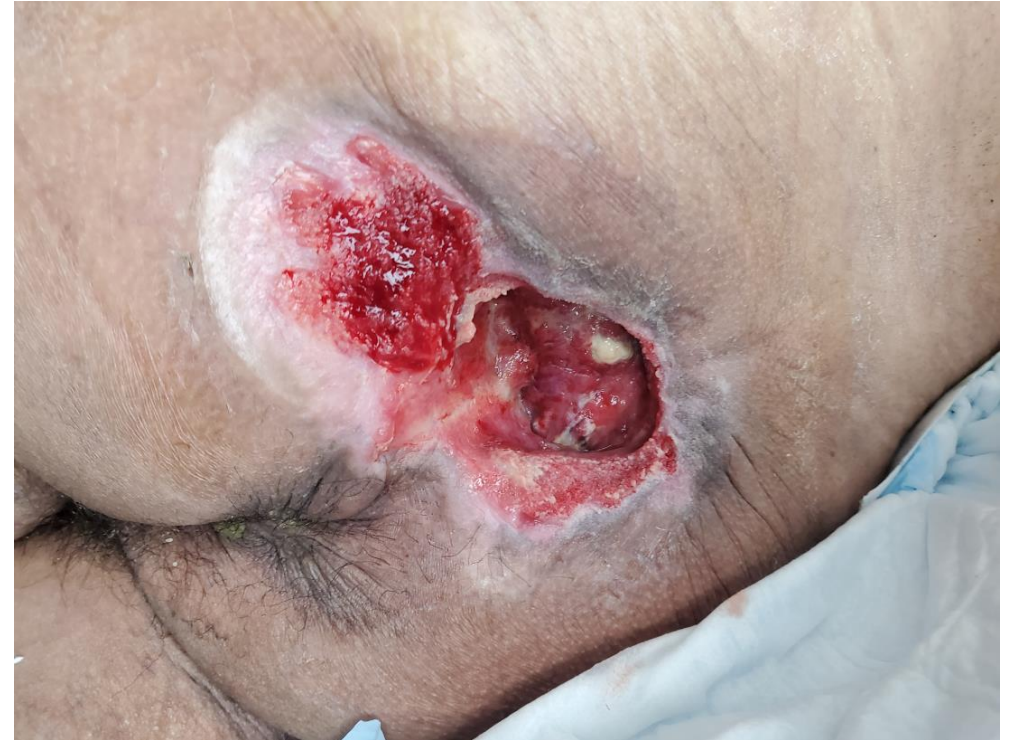- **Day 52**
- Instillation negative pressure continued until **Day 62**, then switched to a traditional dressing for discharge to LTC
- Wound at discharge showed no signs of infection and had granular tissue base

Stage 4 Pressure Injury

Day 1



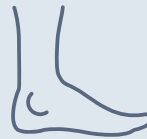Day 52



Surgical Flap Failure



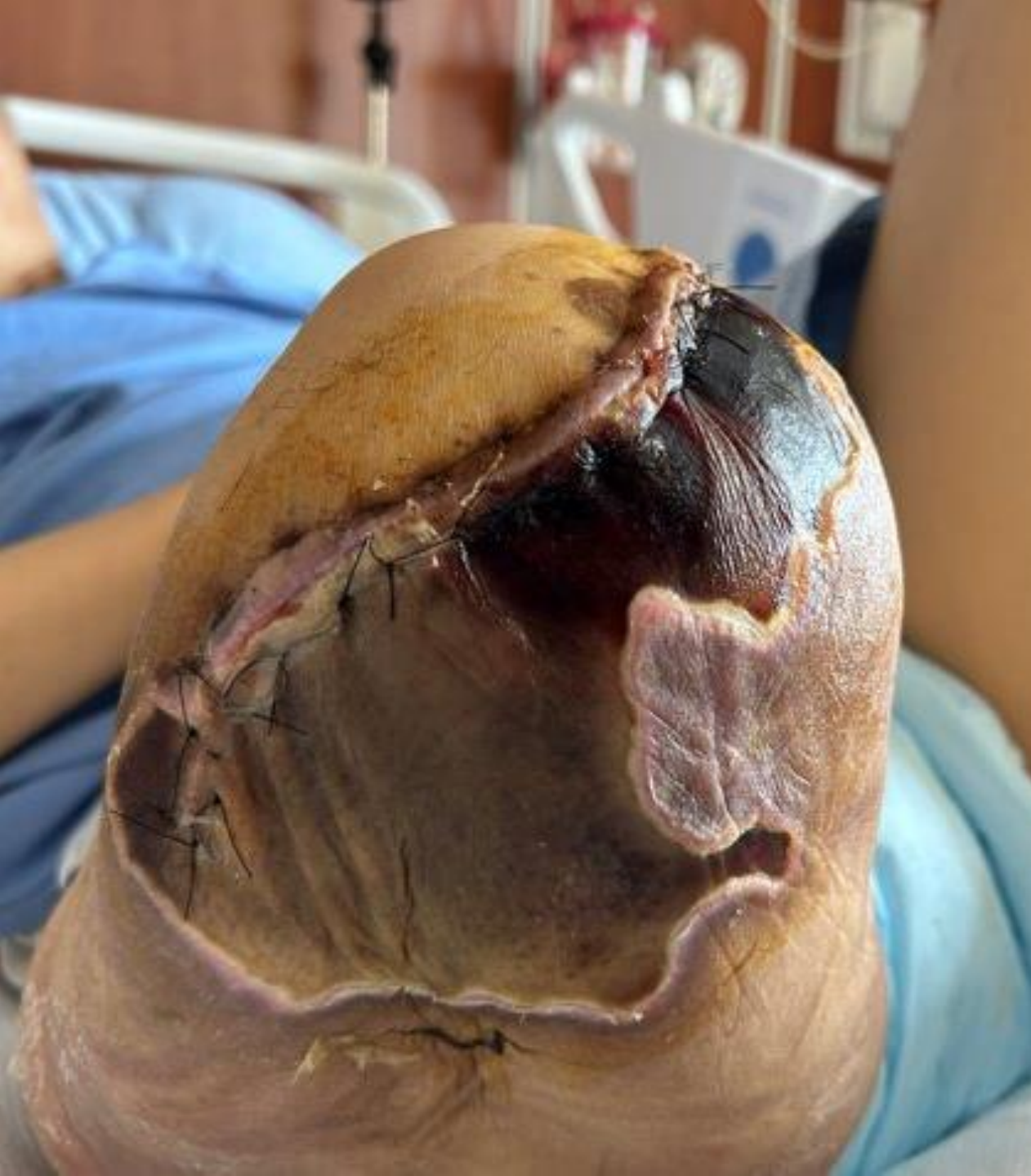PMX: Type 2 diabetes mellitus



Post-op day 24 after above-knee amputation for necrotizing fasciitis/diabetic foot infection performed by another organization



Patient was sent to rehab, then to our organization less than 24hrs later

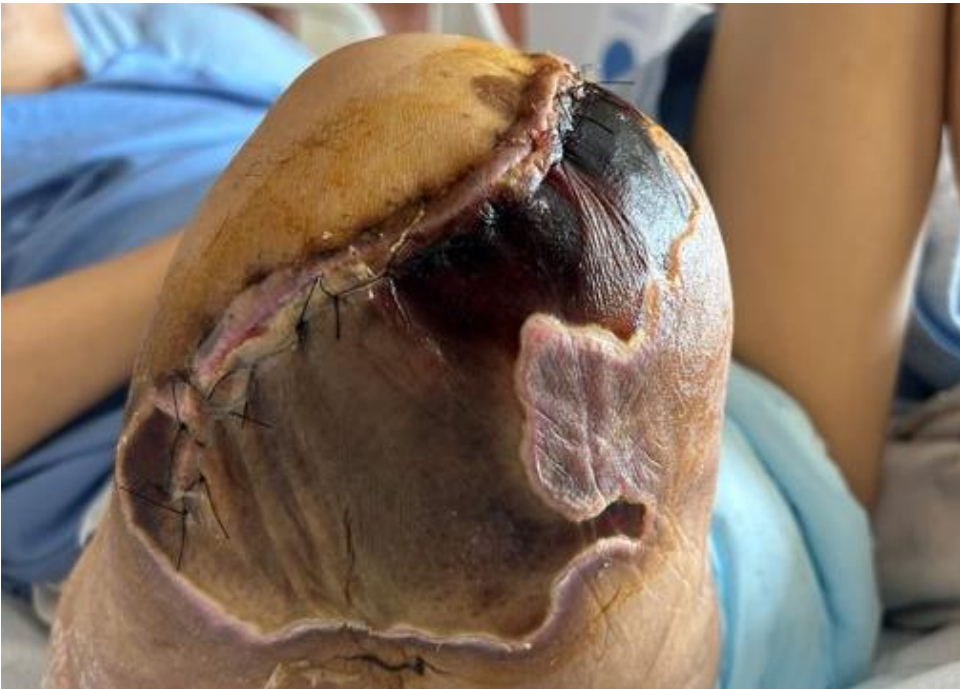

Surgical Flap Failure

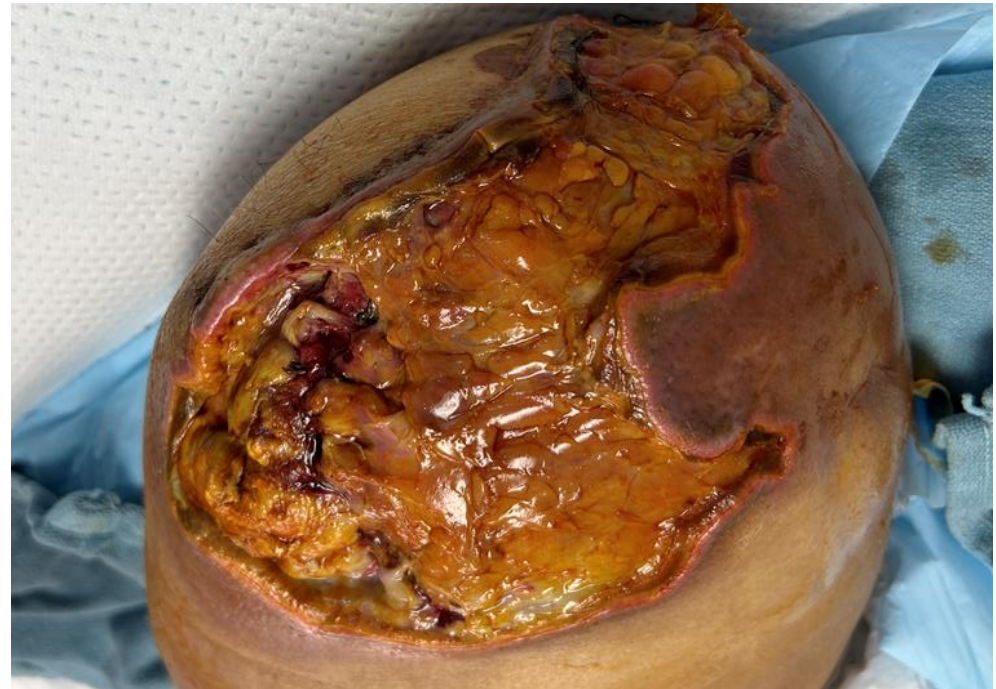- **Day 1**
- Extensive unstable necrosis of the surgical site and flap
- Wound presented with warmth, odour, and patient reported pain
- Patient declined further amputation, opting instead for conservative therapy

Surgical Flap Failure

Pre Wound Debridement



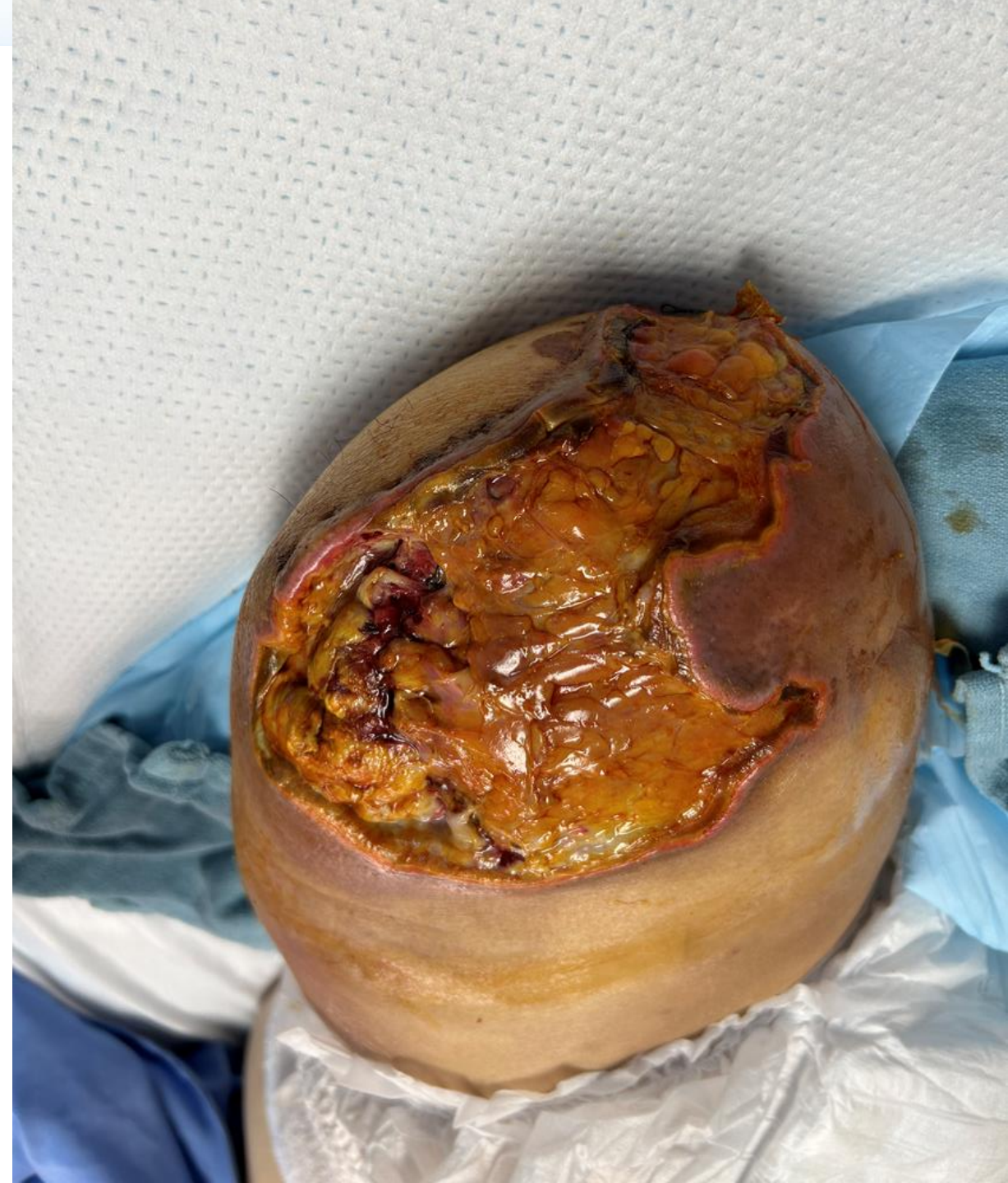Post Wound Debridement



Conservative sharp wound debridement

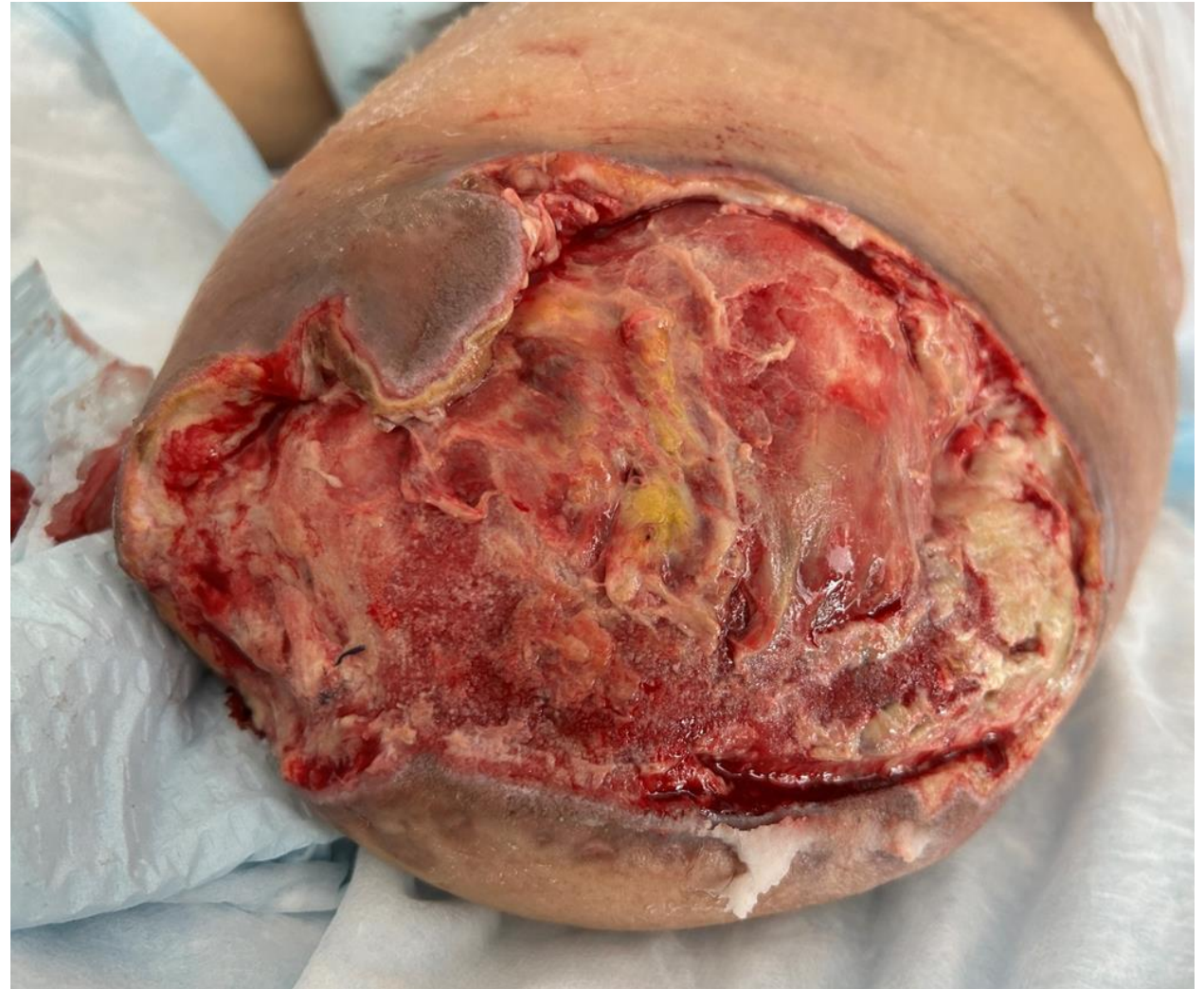Surgical Flap Failure

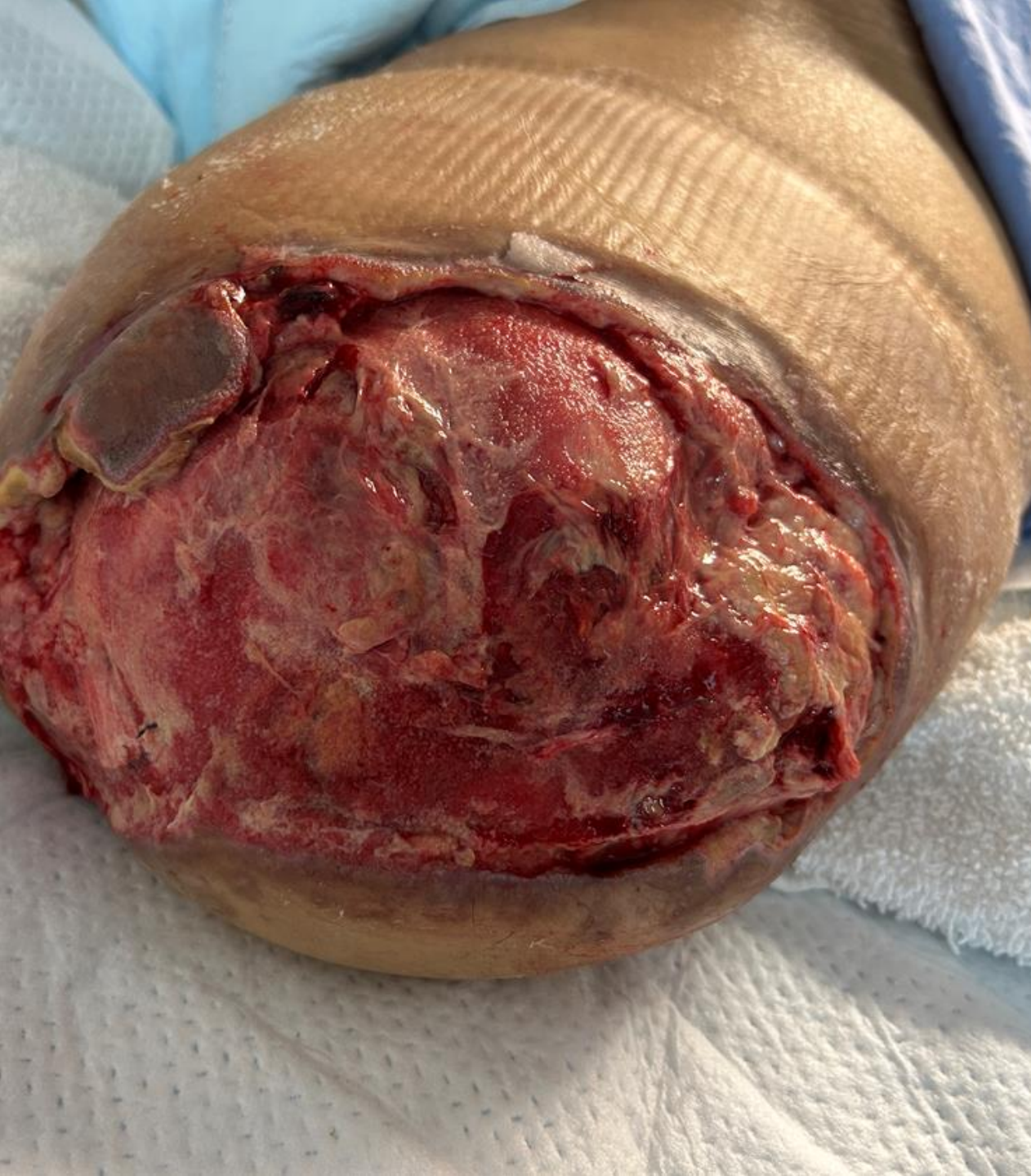
- Extensive undermining throughout leg with tunnel to 1 o'clock = 8cm
- Copious purulent drainage
- Extensive ischemic adipose tissue
- Instillation negative pressure was initiated
- Settings: -125 mm Hg medium continuous | 10min dwell time with 2hr interval
- Installation solution: Hypochlorous acid



Surgical Flap Failure

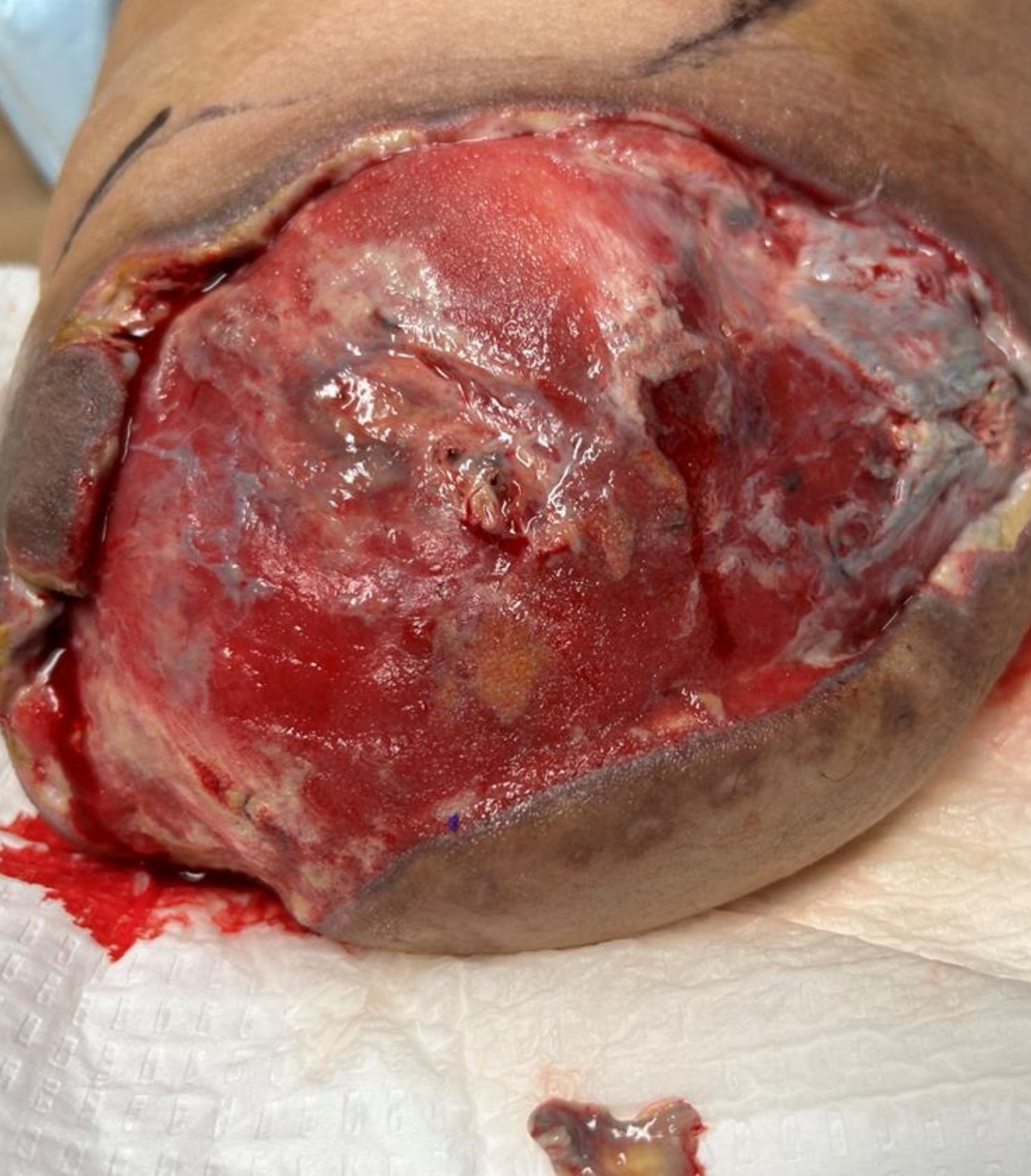
- **Day 4**
- Decreased purulent drainage
- No odour or induration
- Increased tissue perfusion and granular tissue growth
- Instillation negative pressure continued





Surgical Flap Failure

- **Day 7**
- Serosanguineous drainage
- Increased granular tissue growth
- Reduction in peripheral edema (used in combination with compression therapy)
- Instillation negative pressure continued



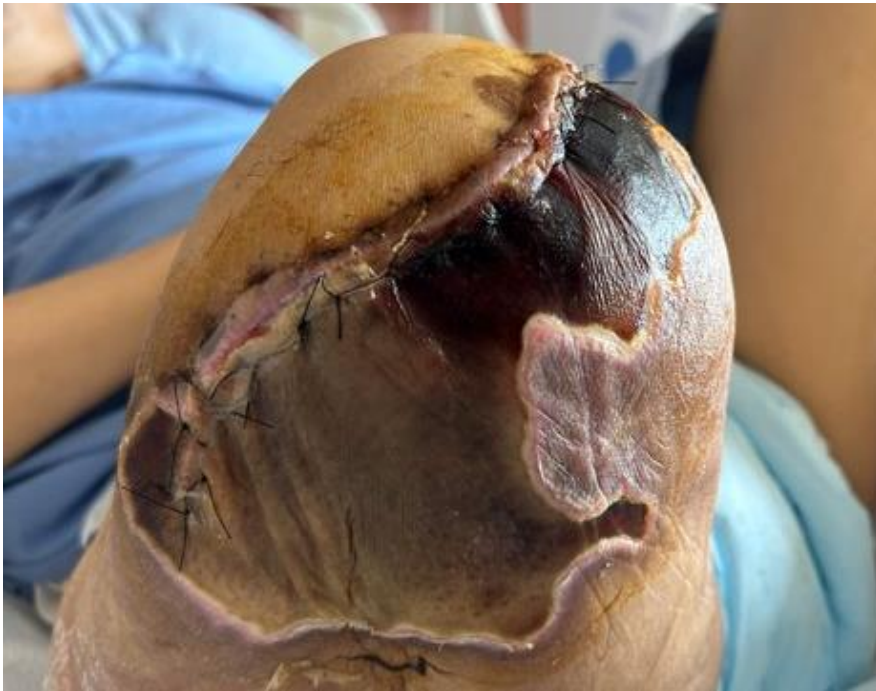Surgical Flap Failure

- **Day 10**
- Removal of large amount of thin, adherent necrosis
- Continued granular tissue growth and wound contraction
- Transferred to rehab to await grafting

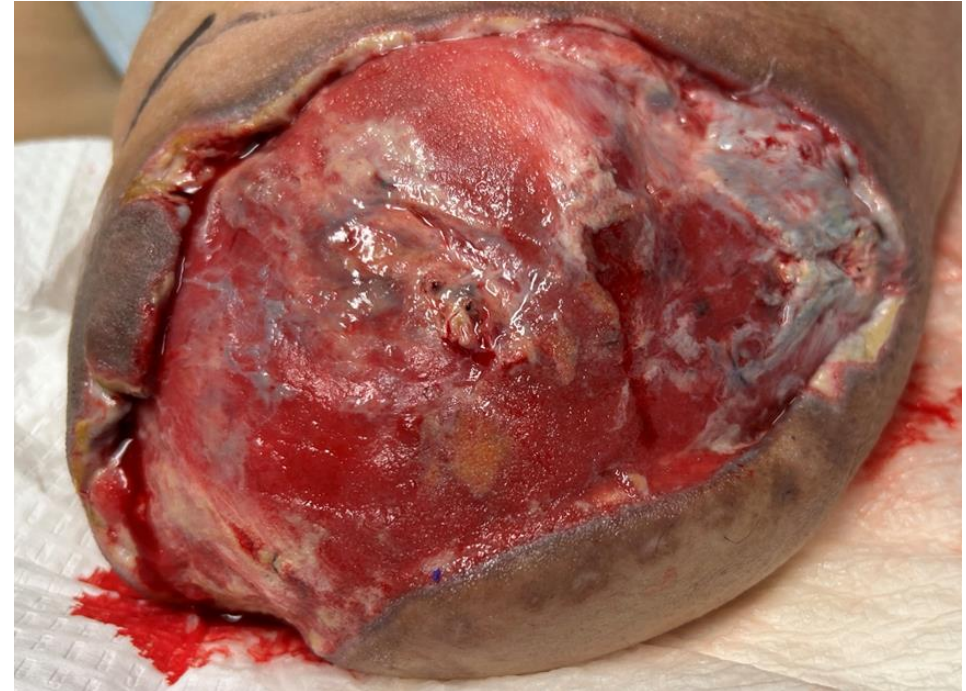
- Instillation negative pressure **discontinued**
- Initiated traditional negative pressure

Surgical Flap Failure

Day 1

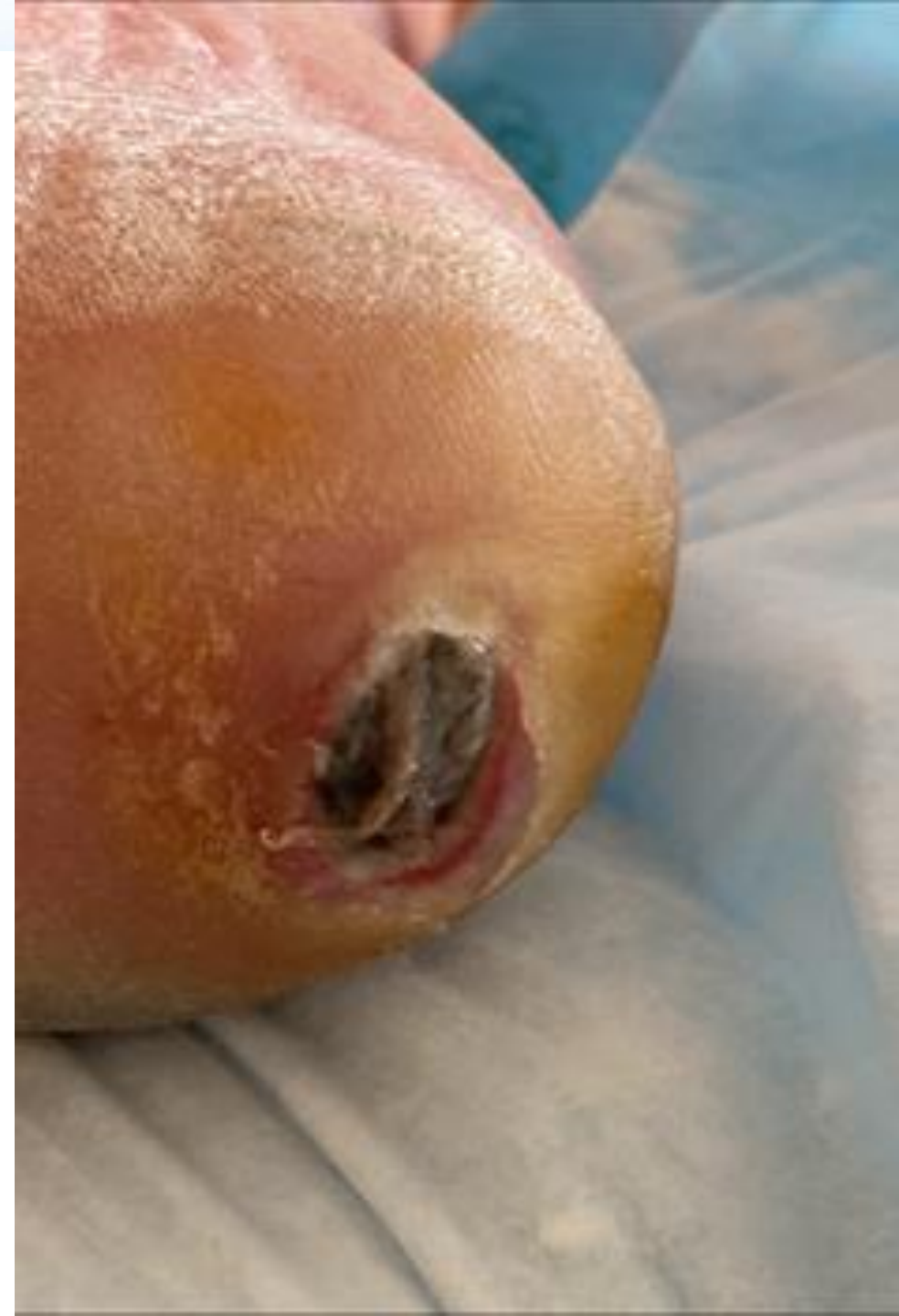

Day 10

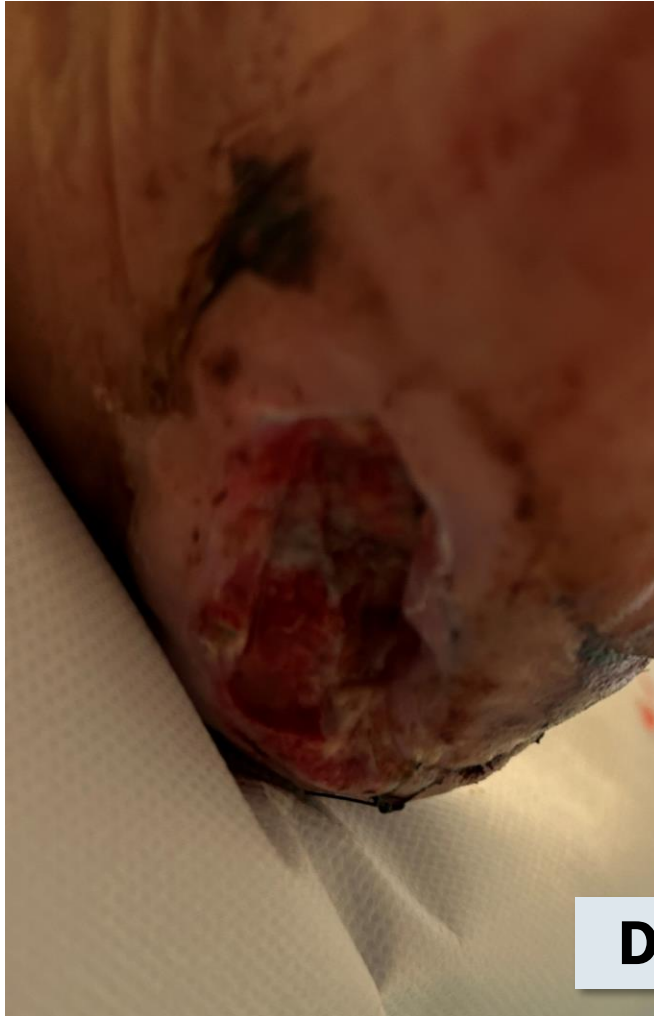

Diabetic Foot Infection

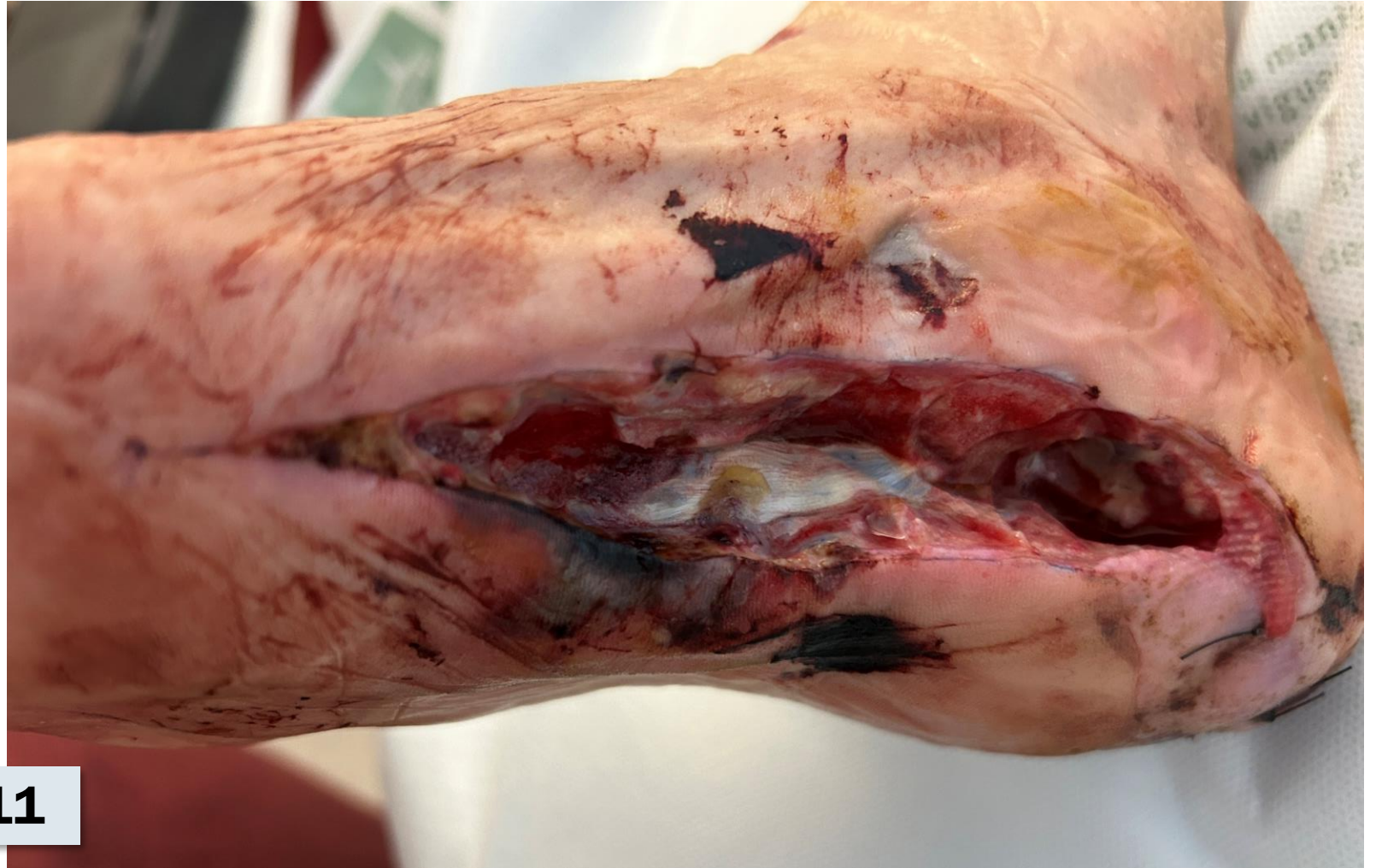- 65y Female admitted for diabetic foot infection. She has several comorbid conditions, including
 - Obstructive sleep apnea, iron deficiency, hypothyroidism, Type 2 diabetes mellitus, hypertension, dyslipidemia, osteoporosis, former smoker (quit 5-6yrs ago), venous insufficiency
- Taken to OR for repeat debridement by orthopedics and was assessed and treated by acute pain services over an 11-day timeframe
- Debridements included necrotic muscle and tendon tissue and evacuation of a deep midfoot abscess



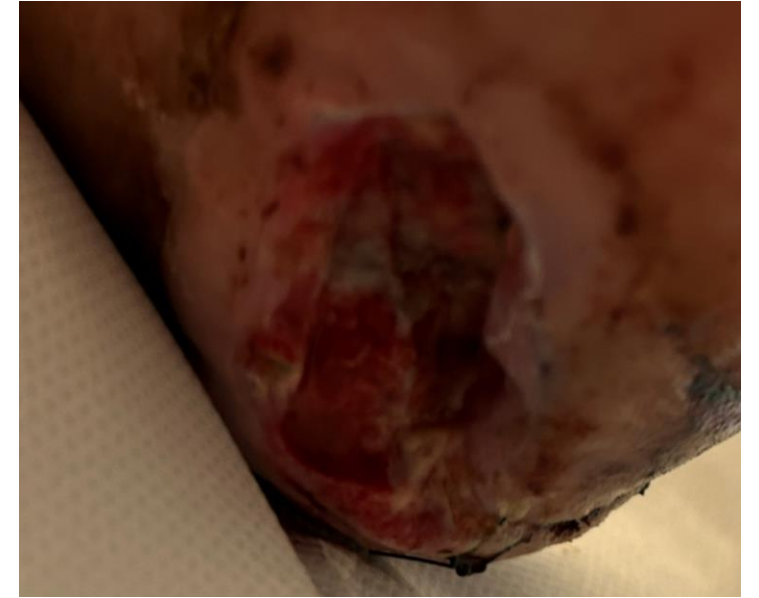
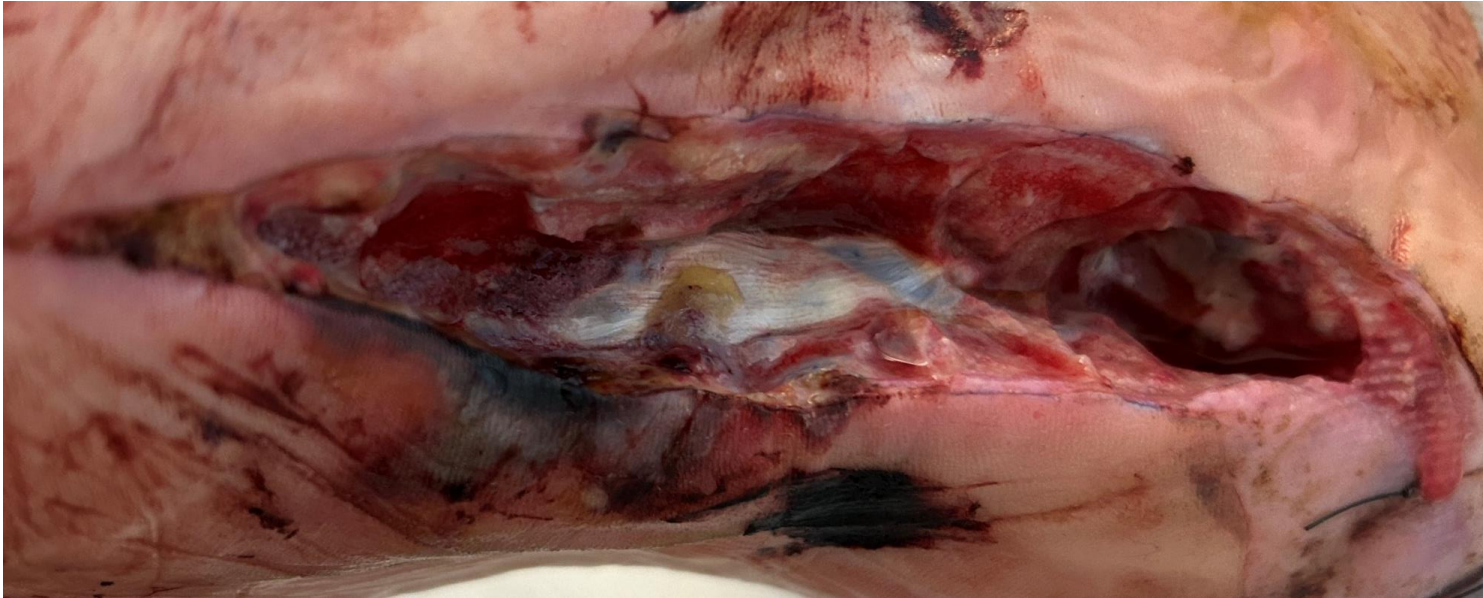Diabetic Foot Infection



Day 11



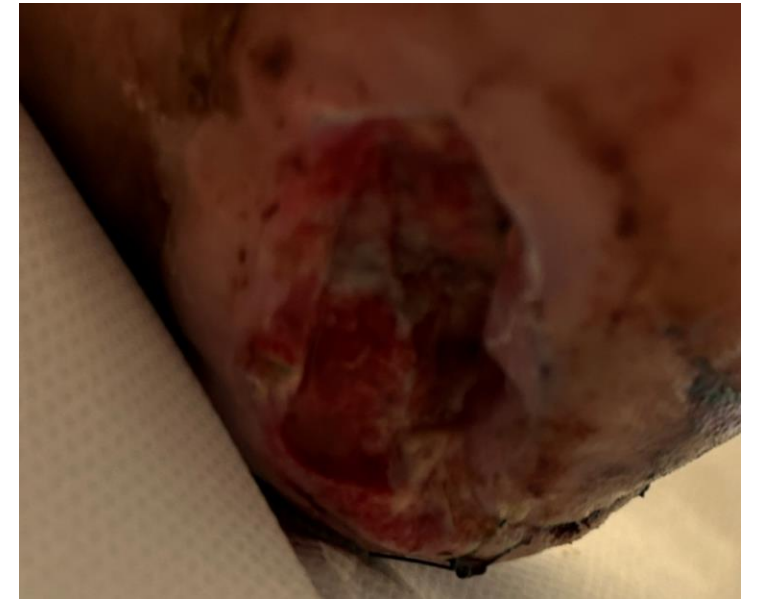
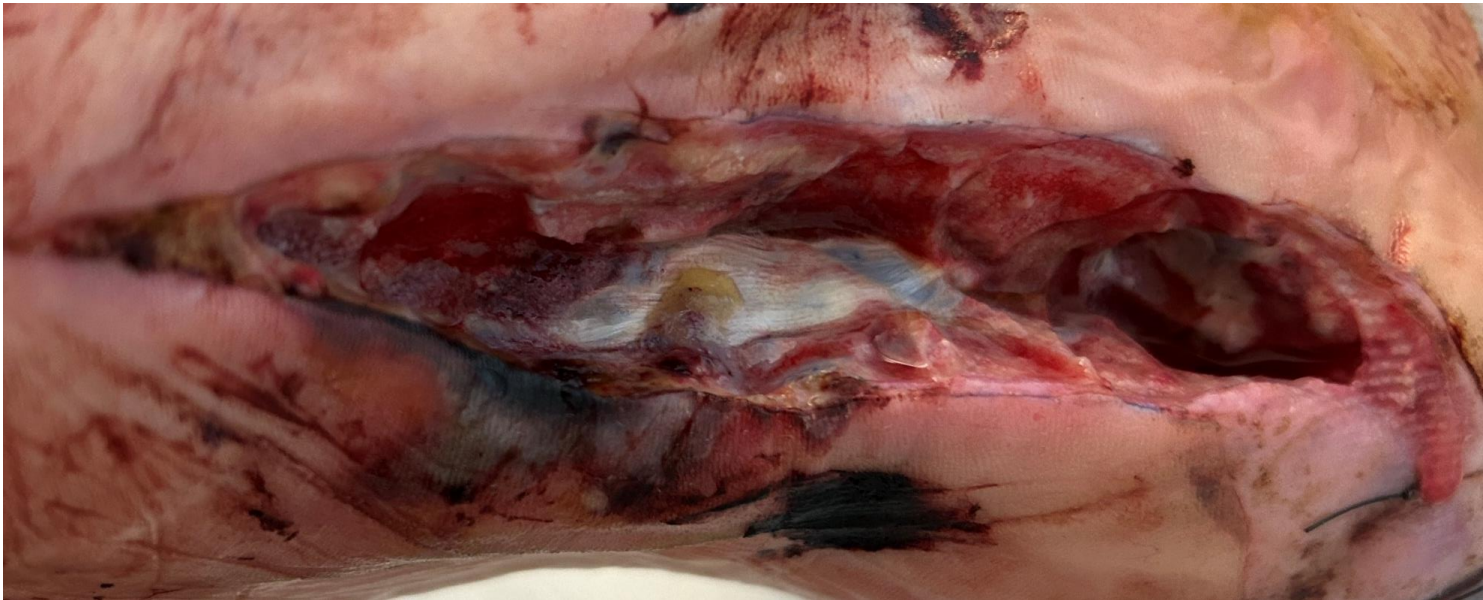Diabetic Foot Infection



- Medial wound has decreased in drainage
- No odour, induration, or erythema
- However, there is an increase in LKC

Day 11: LKC: 20.2 | Day 13: LKC: 12.7

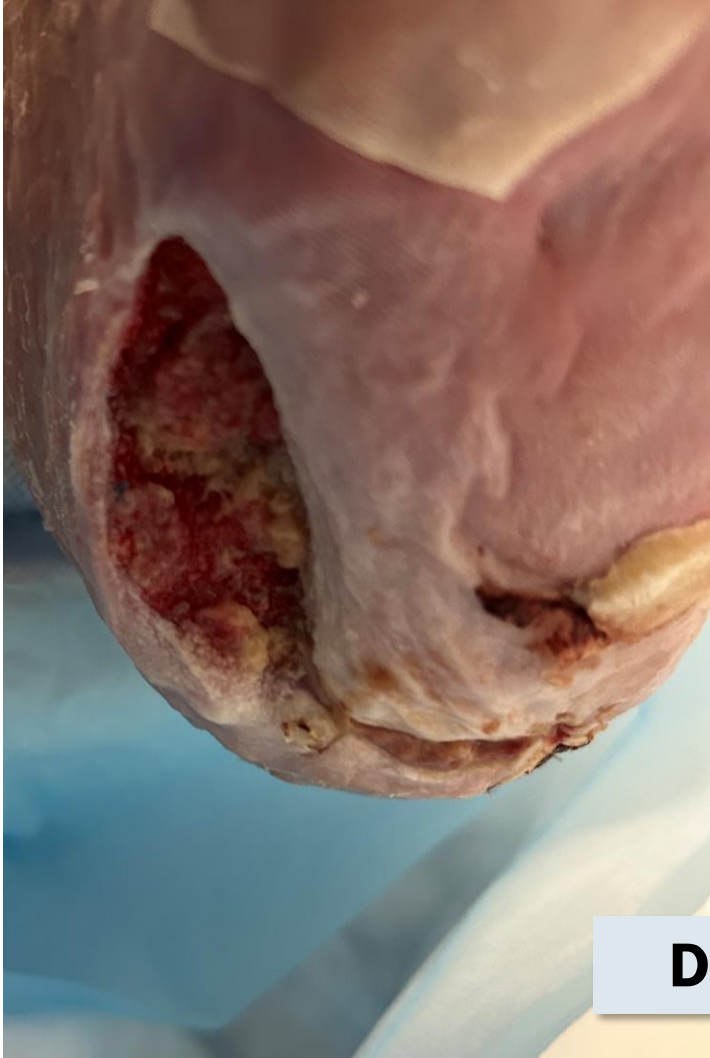Diabetic Foot Infection



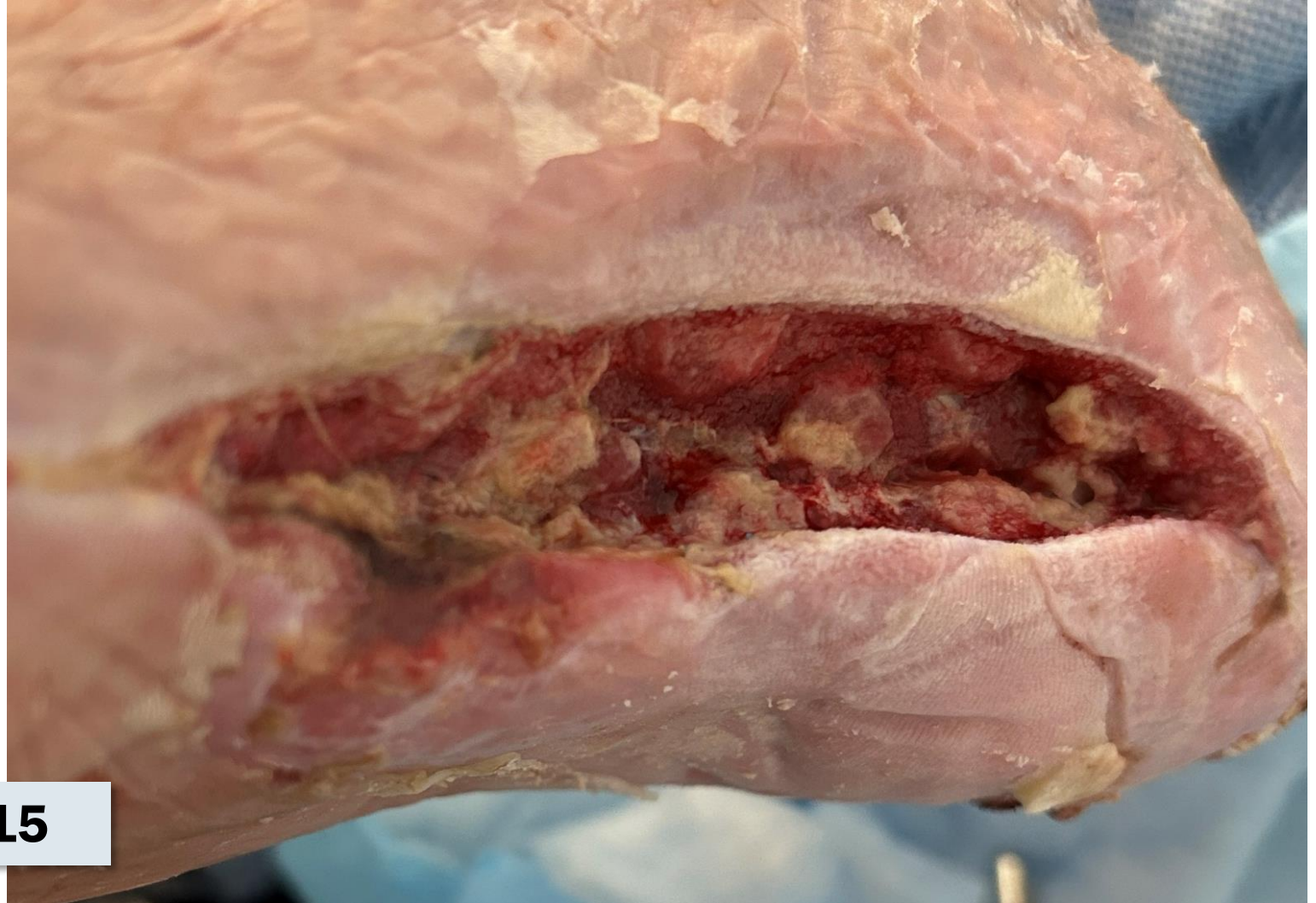- Fluid instillation
- Pressure: -125 mm Hg | Intensity: Low | Interval: Intermittent | Change Frequency: QMWF
- Fluid instillation amount: 25mL | Fluid instillation type: HOCl
- Instillation duration: 10min | Instillation interval time: 3hrs

Day 11: LKC: 20.2 | Day 13: LKC: 12.7

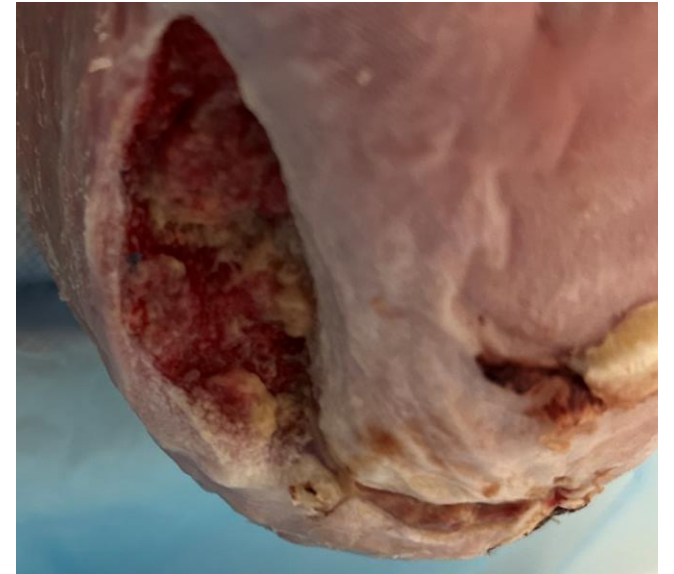
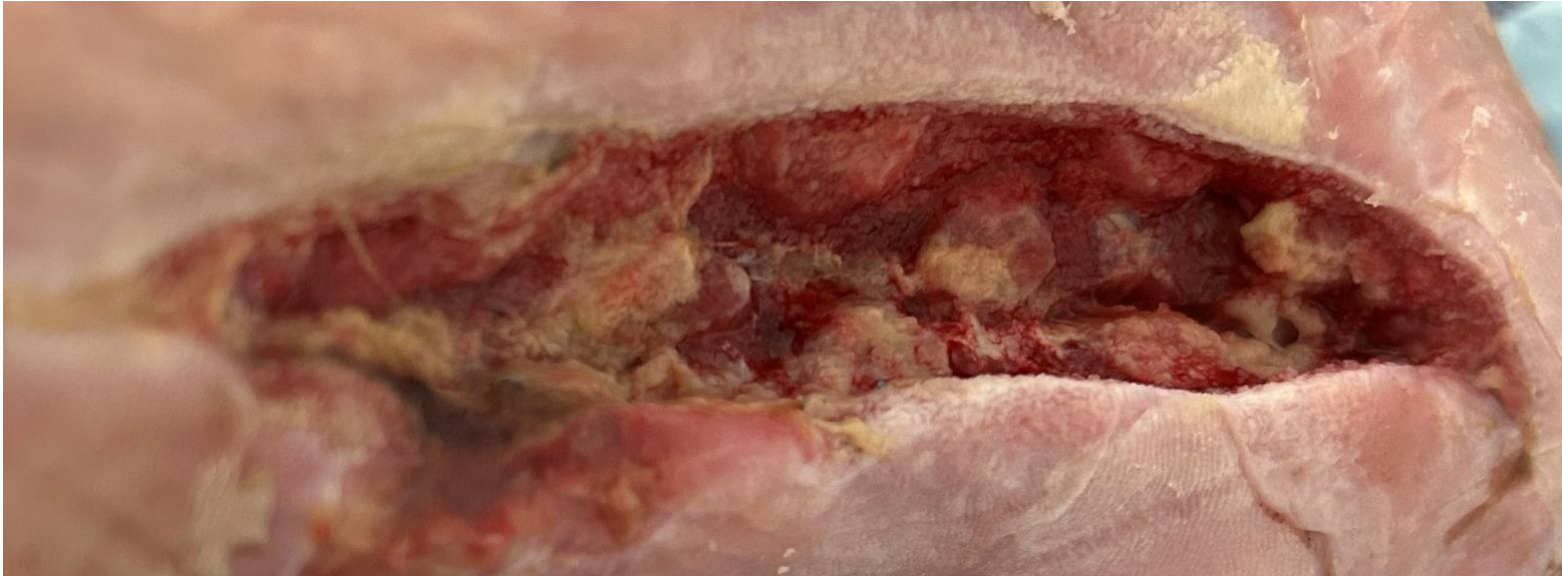
Diabetic Foot Infection



Day 15



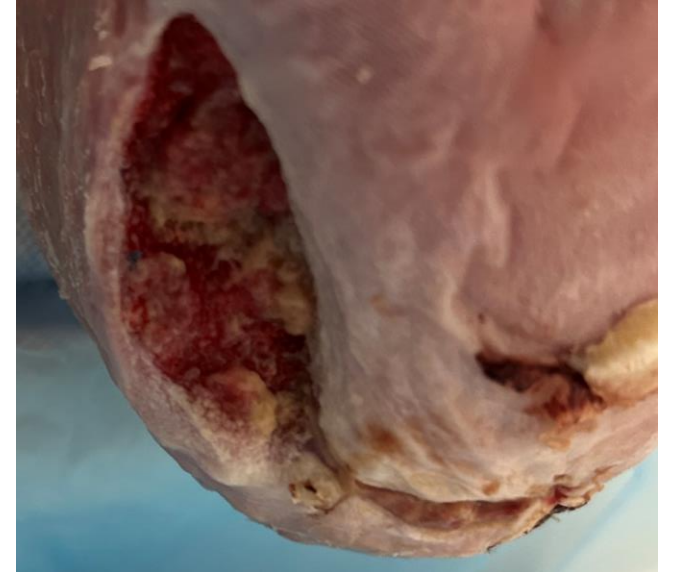
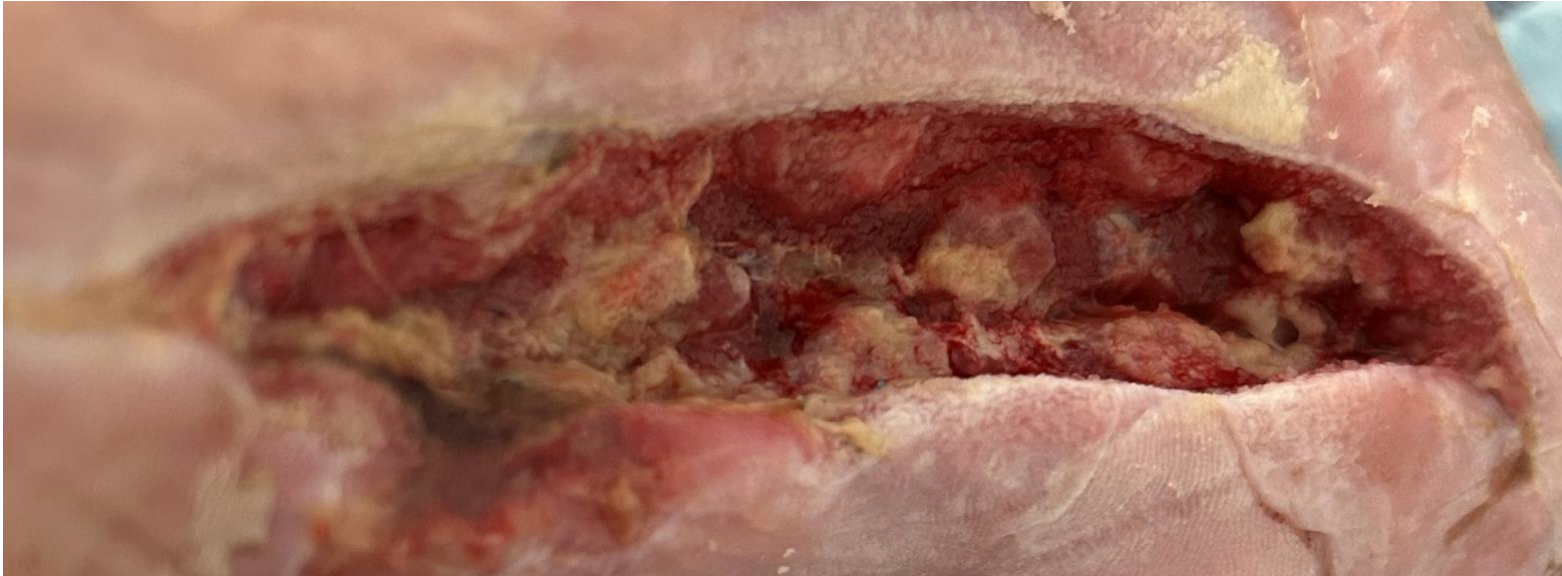
Diabetic Foot Infection



- Mostly beefy granular tissue with small amount of thin, fibrinous tissue
- No signs of infection, odor, induration, or erythema; peri skin intact
- Despite full efforts to provide pain control, the patient was experiencing lasting pain with negative pressure changes

Day 15: LKC: 9.5

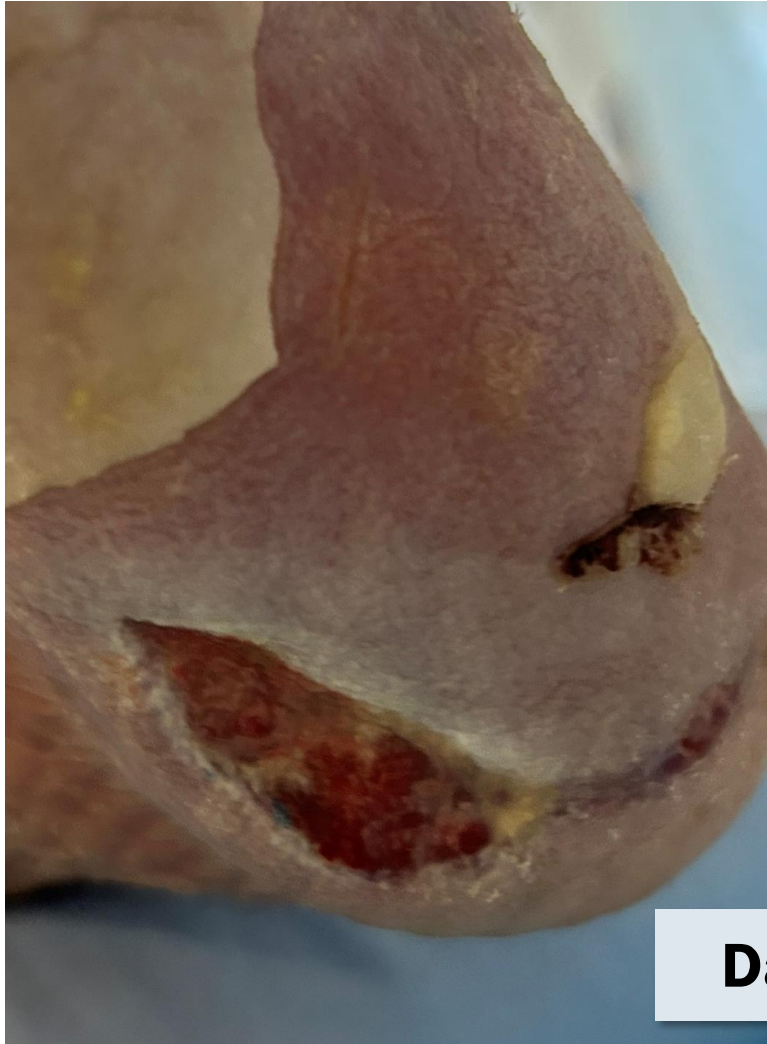
Diabetic Foot Infection



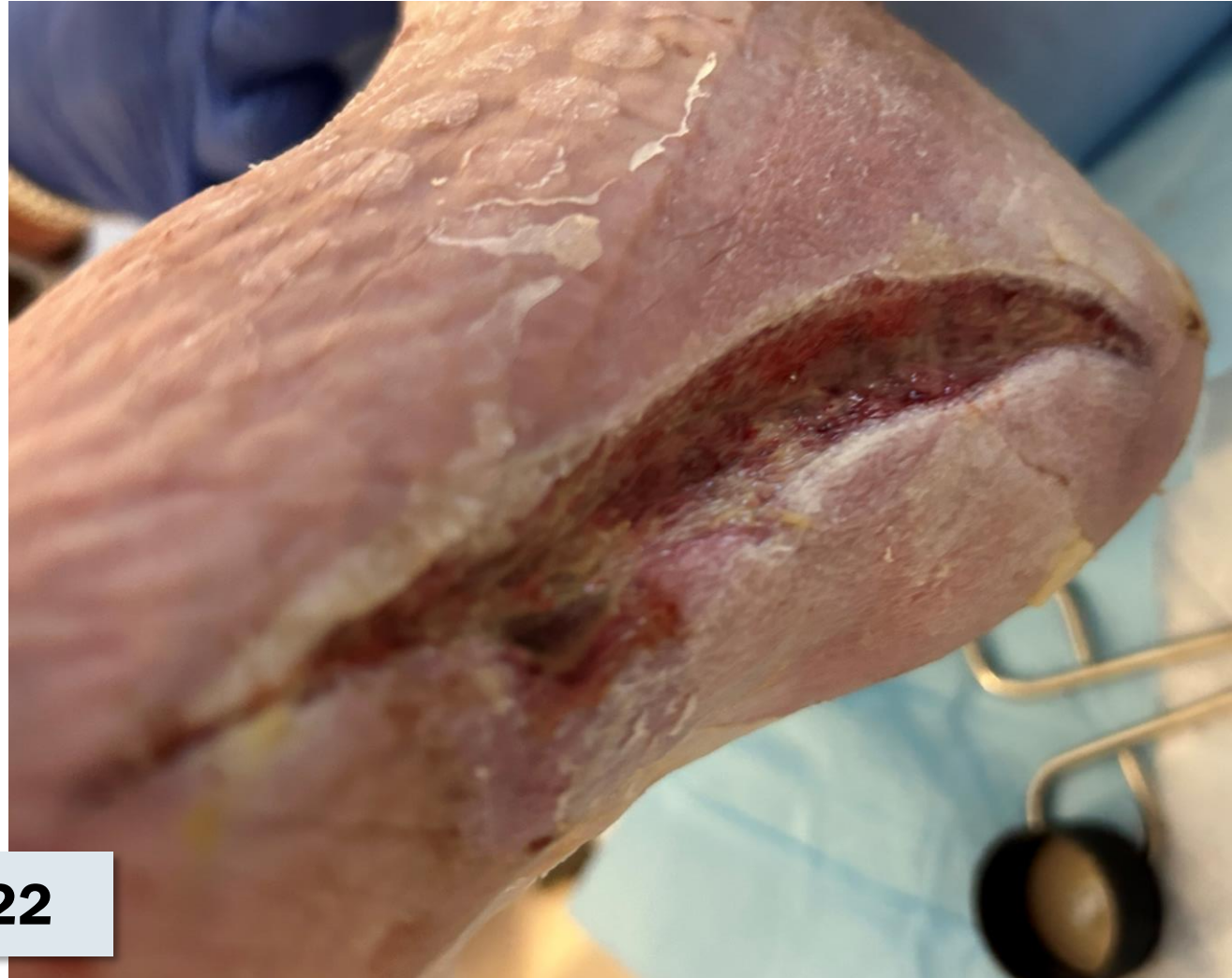- Peel and place dressing application
- Pressure: -125 mm Hg | Intensity: Small | Interval: Continuous

Day 15: LKC: 9.5

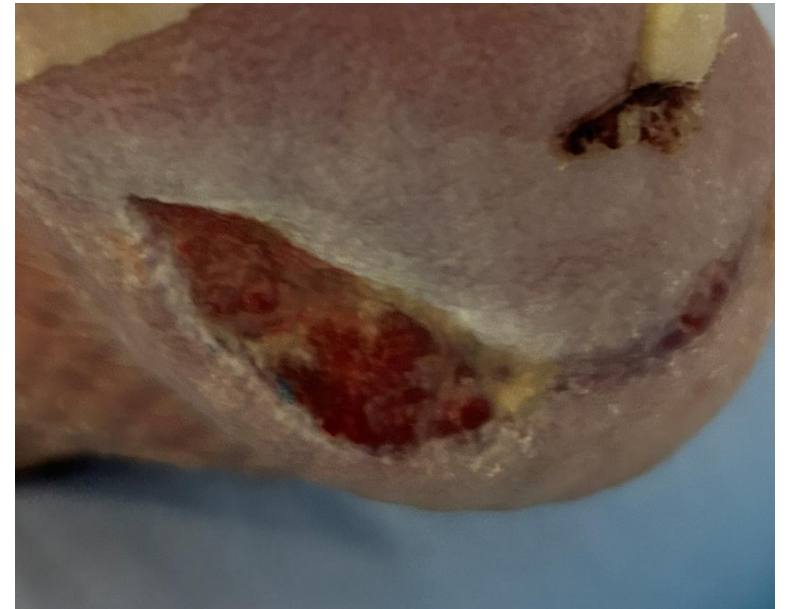
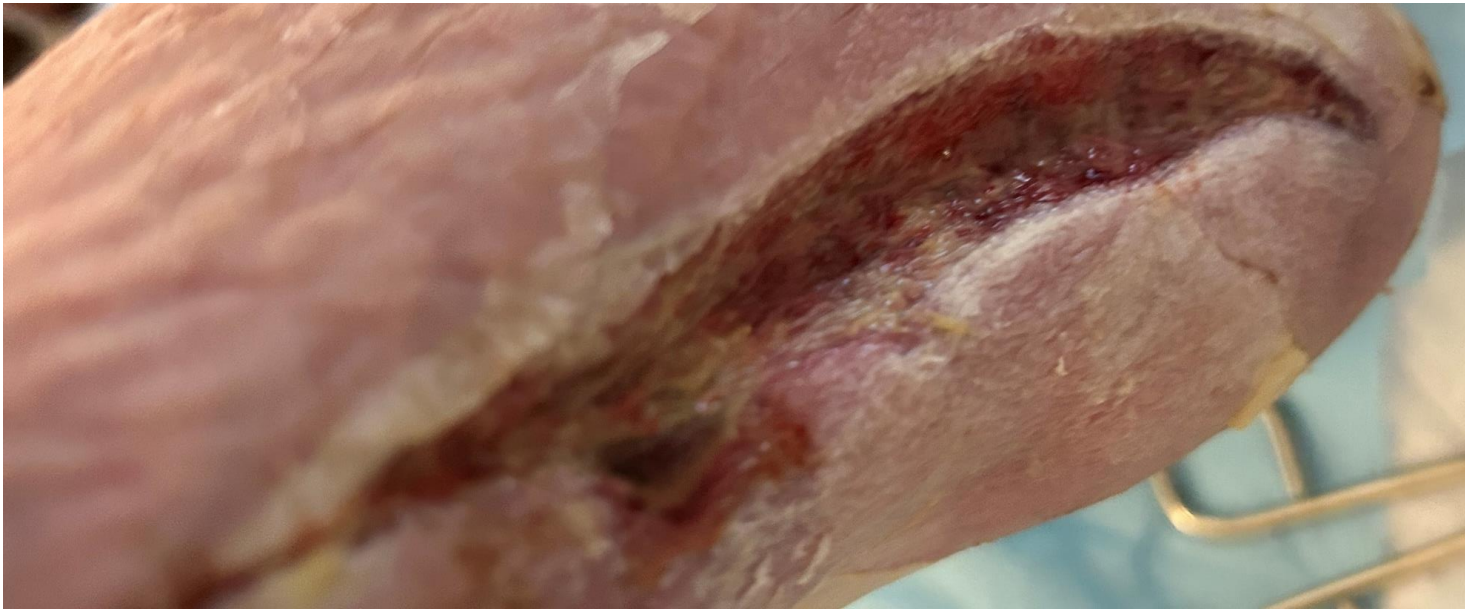Diabetic Foot Wound



Day 22



Diabetic Foot Wound



- Wound healing well, epithelial tissue migrating inward. No pain with dressing changes with peel and place negative pressure kit. LKC remained low, no signs of infection.
- Patient ready for discharge. Dressing changed to conventional dressing

Day 22, LKC: 8.3

Clinical Pearls

- **Develop or Adopt Structured Guidance:** Consider the creation or implementation of an NPWT algorithm or clinical guideline to support staff in making appropriate and consistent treatment decisions
- **Embrace Therapeutic Diversity:** Incorporate a broad range of treatment modalities into your wound care practice to address the complex and dynamic needs of patients
- **Recognize the Need for Multimodal Strategies:** Understand that most complex wounds require the use of multiple treatment modalities over time to achieve full re-epithelialization
- **Remain Adaptable:** Do not hesitate to adjust treatment strategies if the patient's condition fails to improve or shows signs of deterioration; flexibility is essential for optimal outcomes

NPWT Technologies and an Algorithmic Approach to Selection

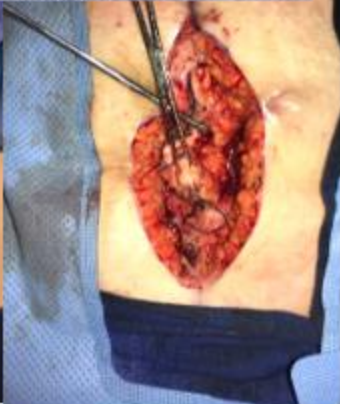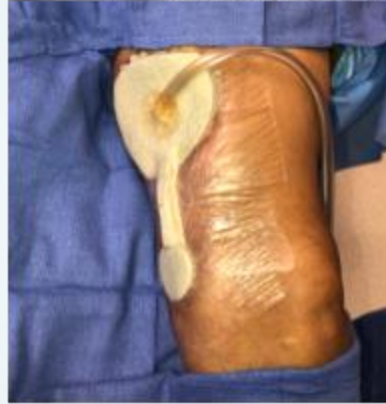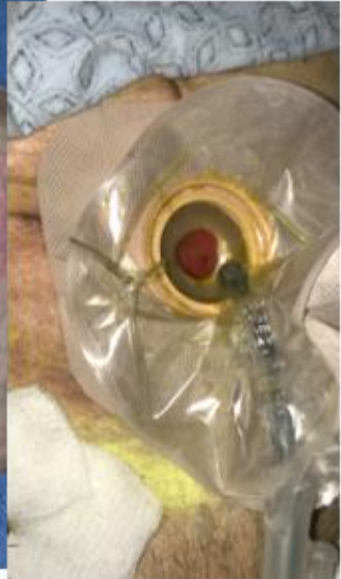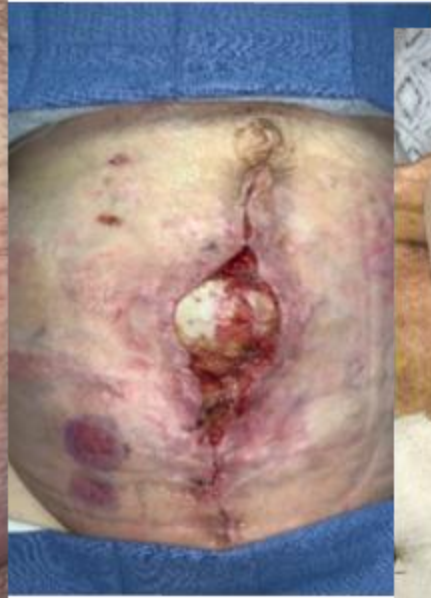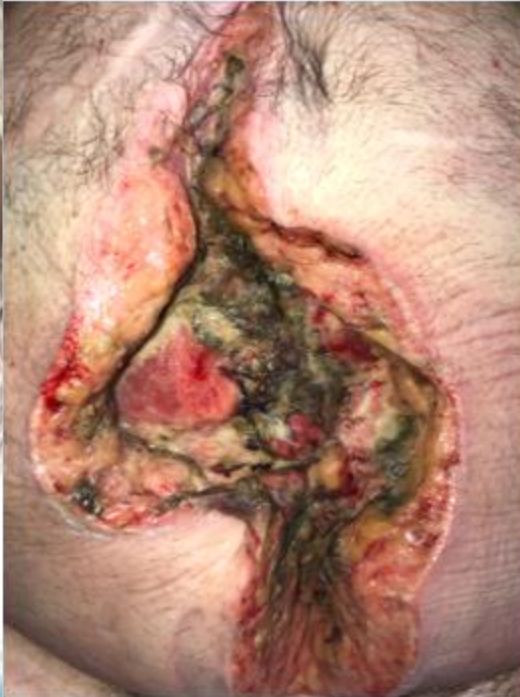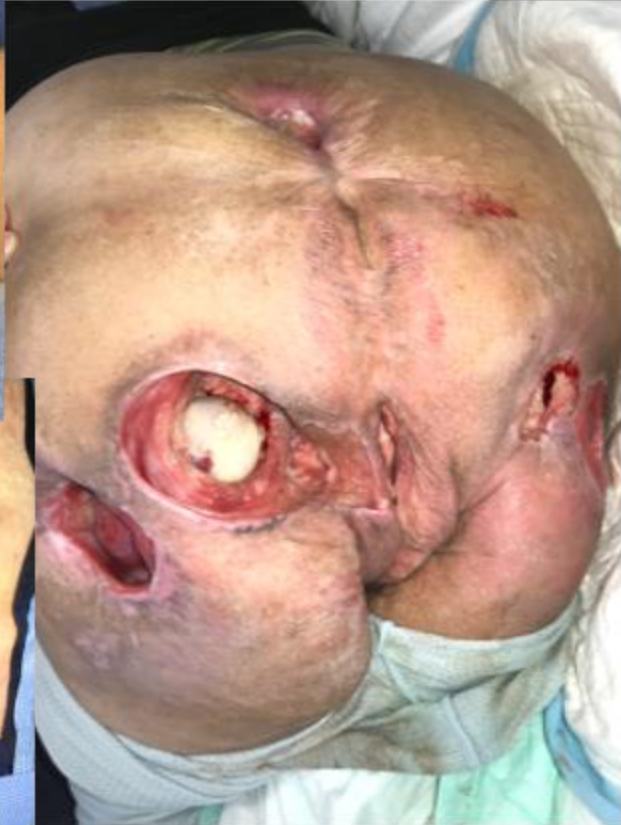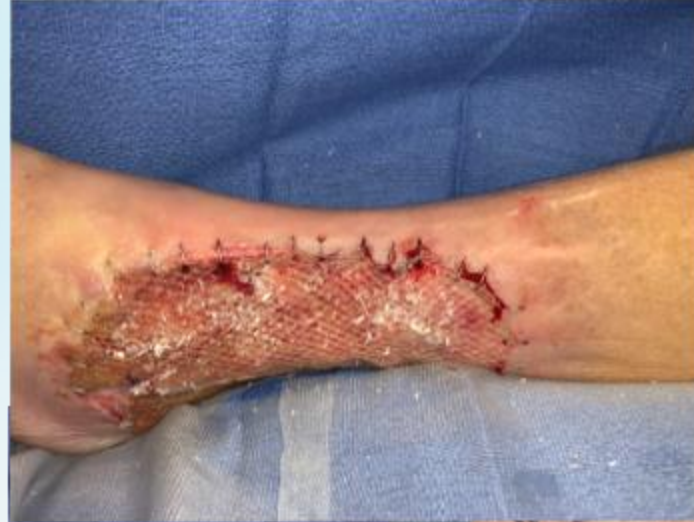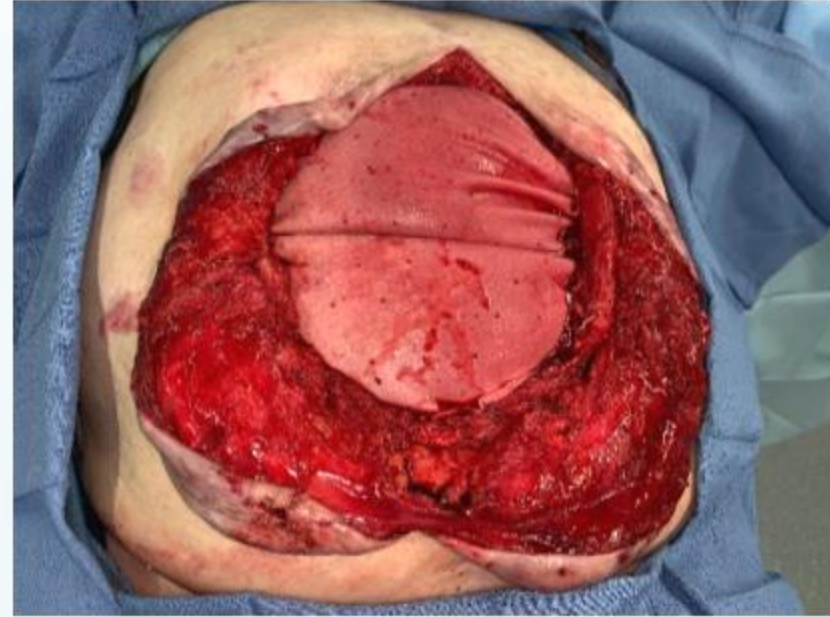
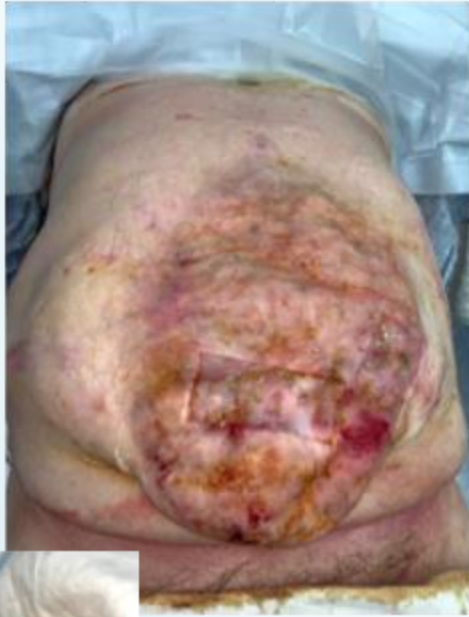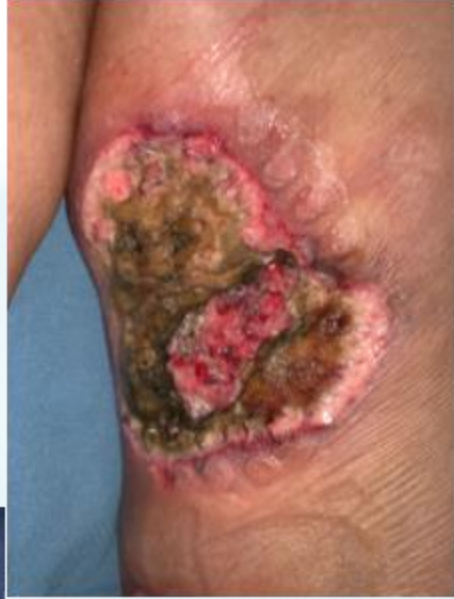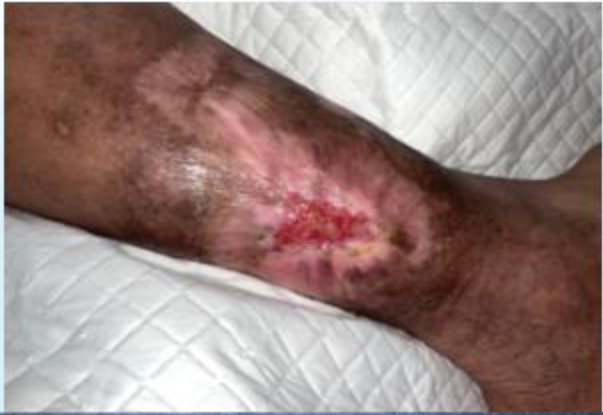Michael N. Desvigne, MD, FACS, CWS, FACCSWS, MAPWCS

Plastic & Reconstructive Surgery

Wound Care & Hyperbaric Medicine

Abrazo Arrowhead Hospital & Wound Clinic

Glendale, AZ





Polling Question

Negative pressure wound therapy (NPWT) refers to all negative pressure delivery systems placed on a patient?

- A. True
- B. False

***Polling was pre-recorded.**

Clarification of Terminology

- Negative pressure **wound** therapy (NPWT)
- NPWT with **instillation and dwell** (NPWTi-d)
- NPWT with irrigation (NPWT-I)
- Incisional NPWT (iNPWT) vs **closed incisional NPWT** (ciNPWT)
- Traditional NPWT (tNPWT) or single use NPWT (sNPWT)

Care Setting Considerations

- Acute Care Setting
 - “Sick” patients
 - Comorbidities
 - Wound may or may not be primary problem
 - The clock is ticking
 - Discharge planning and transition of care
- Post-Acute Care Setting
 - Complexity of dressing changes
 - Teaching (WOCN vs RN vs Caregiver)

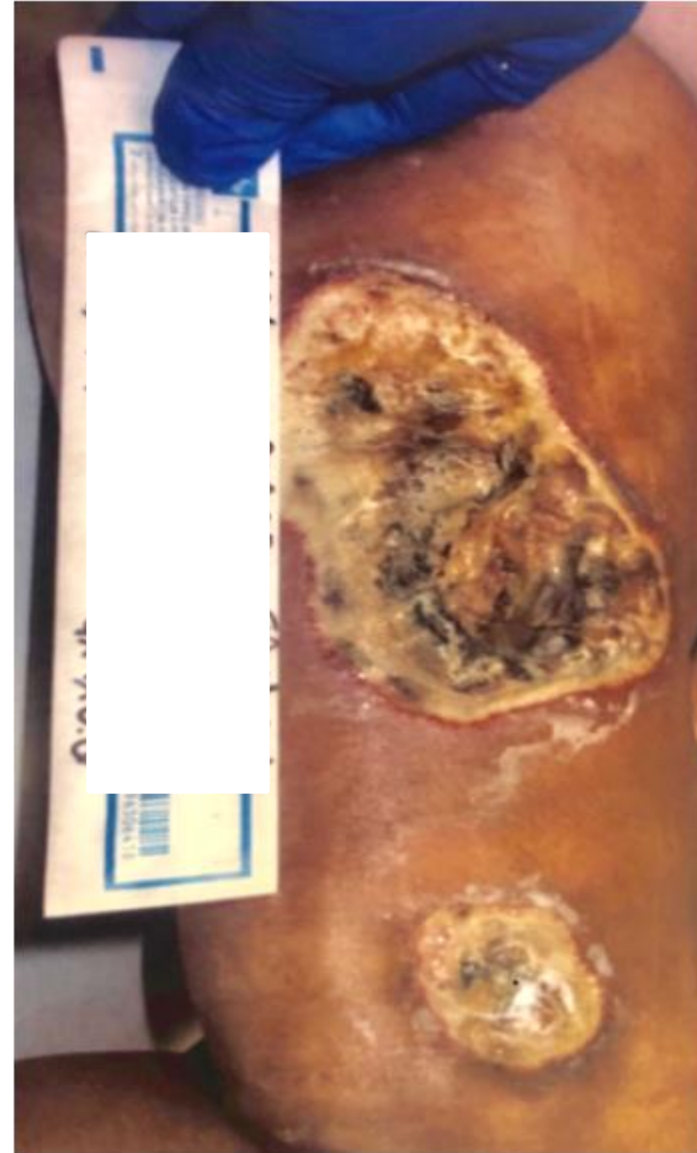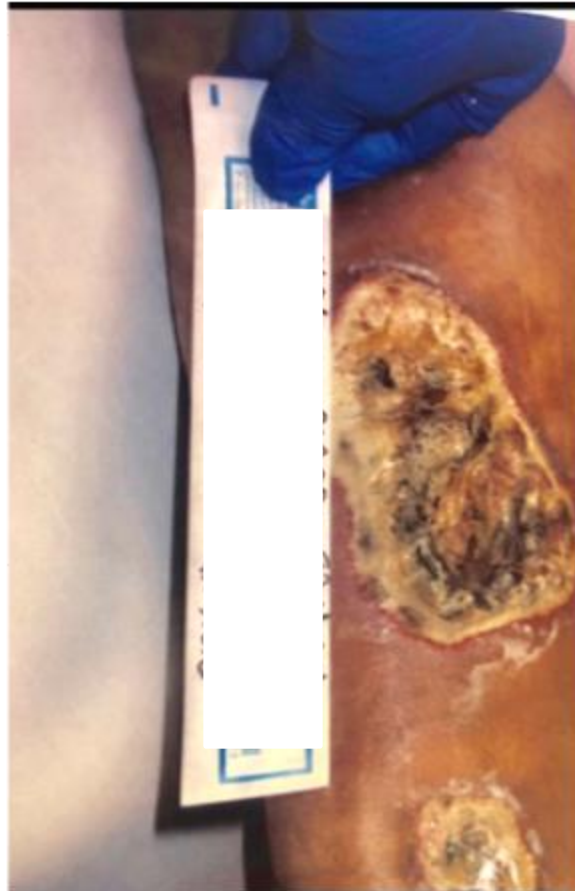Algorithmic Approach

- NPWT for wound management
 - Acute setting
 - NPWT
 - NPWTi-d
 - Goal of therapy? (wound bed preparation vs re-epithelialization)
 - Post-Acute setting (NPWT disposable vs non-disposable)
 - Skilled nursing
 - Home
 - Goal of therapy? (wound bed preparation vs re-epithelialization)
- ciNPT for incisional management
- Acute ----- Post Acute setting

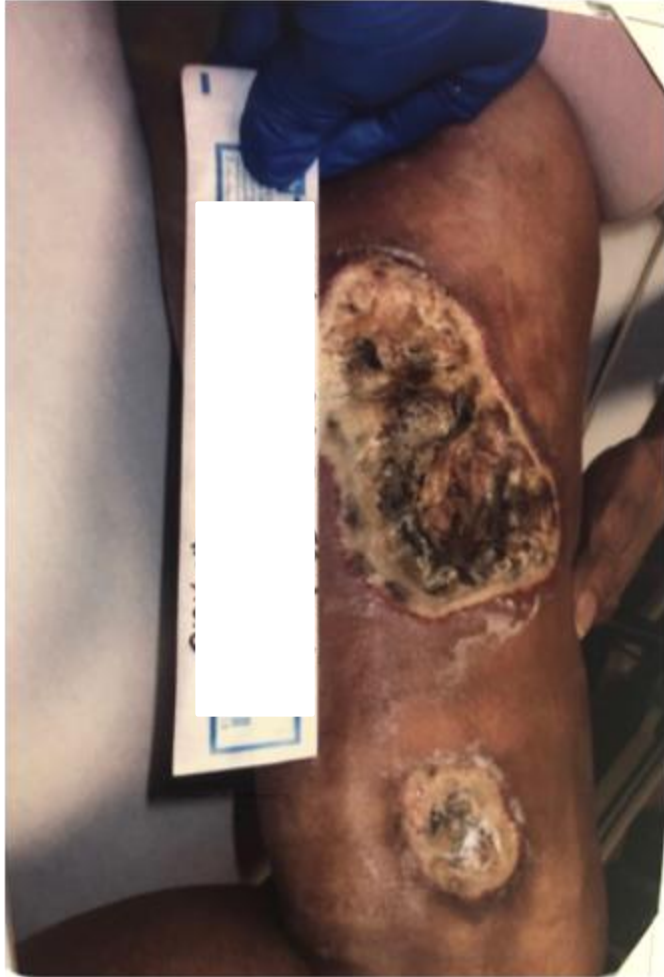Case Summary: Complex Wound, Left Thigh

- 62y Female presents with complex wound, left thigh. Previous right femoral stent placement for severe peripheral vascular disease (PVD). Developed full thickness necrosis, left thigh. Presents for surgical management.
- Medical history: PVD, HTN, previous smoker
- Treatment:
 - NPWTi-d initiated at bedside while awaiting surgical debridement
 - Taken to OR for excision of nonviable tissue

Complex Wound, Left Thigh (Day 0)



Complex Wound, Left Thigh (Day 0)

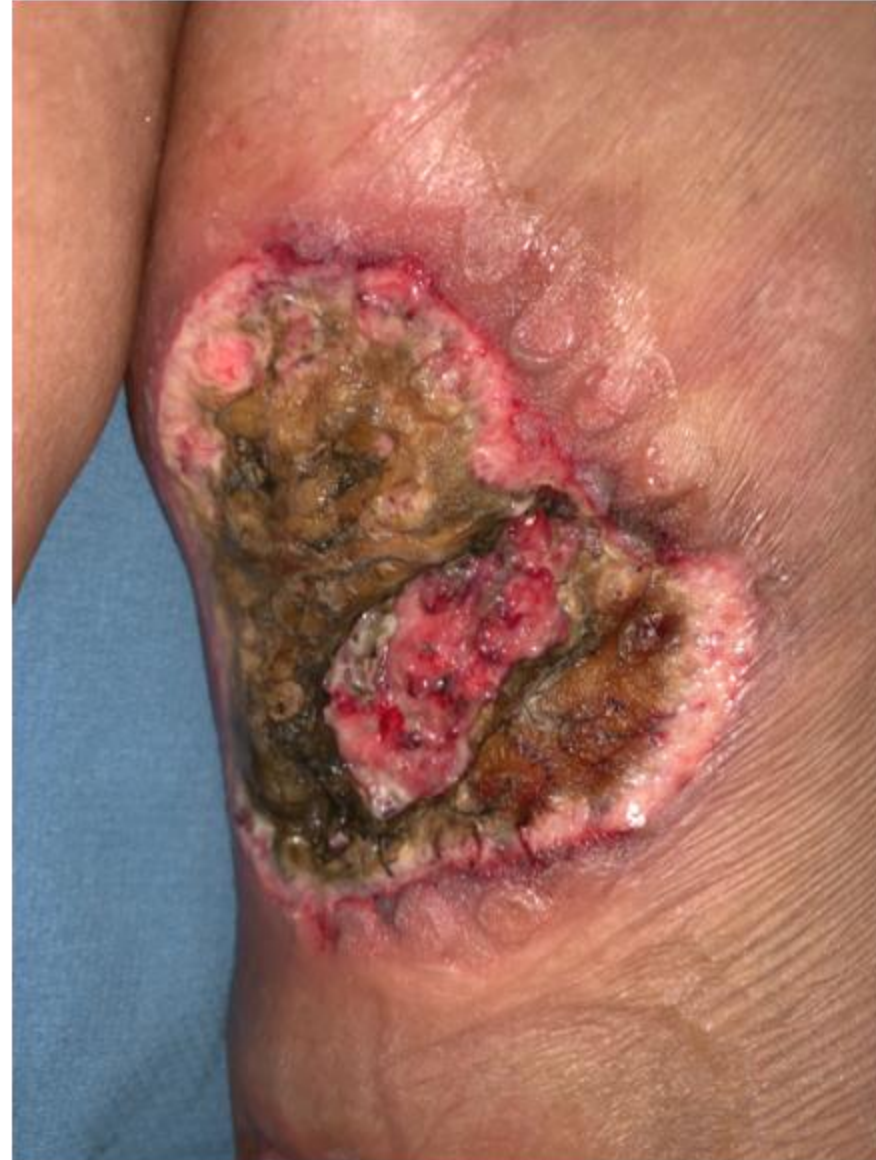
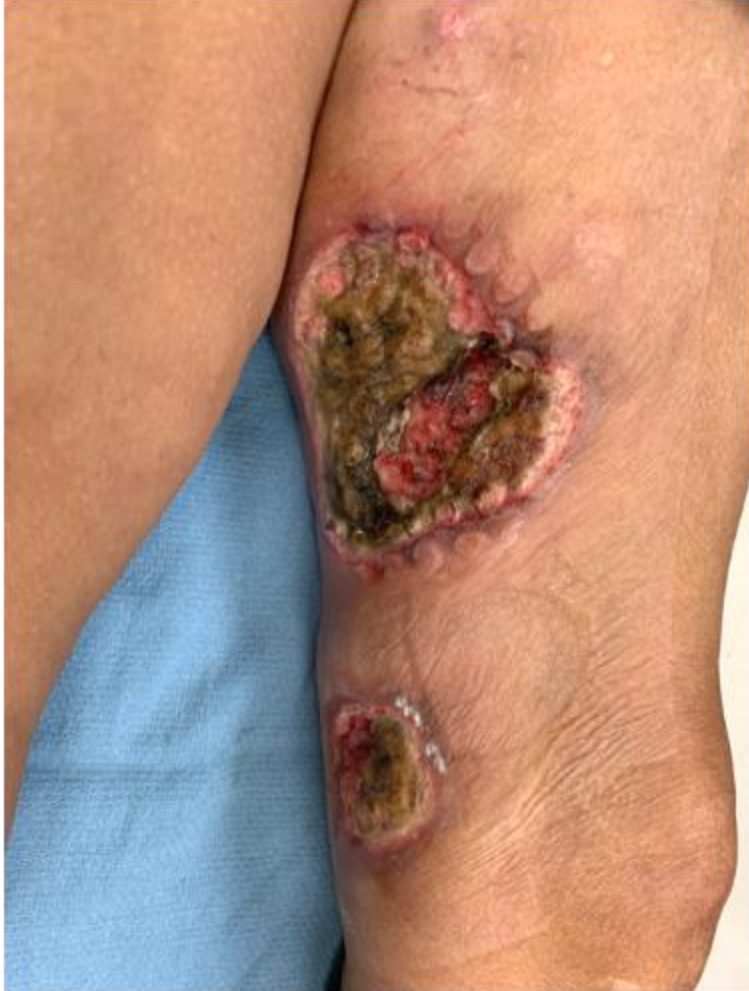
She is on Heparin

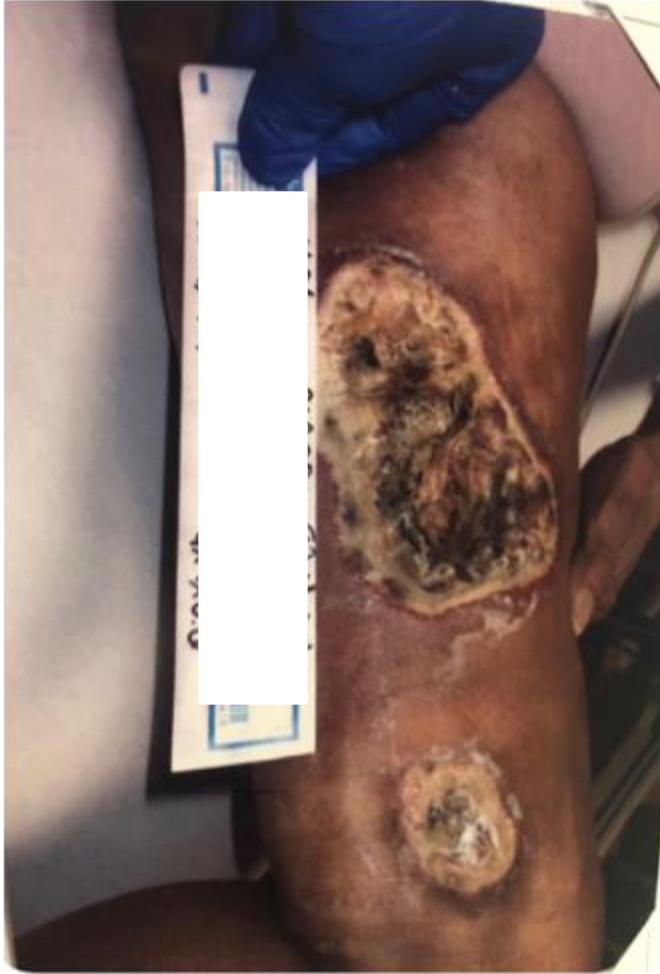Friday 8:05 AM

She is on Heparin

Complex Wound, Left Thigh (Day 1)

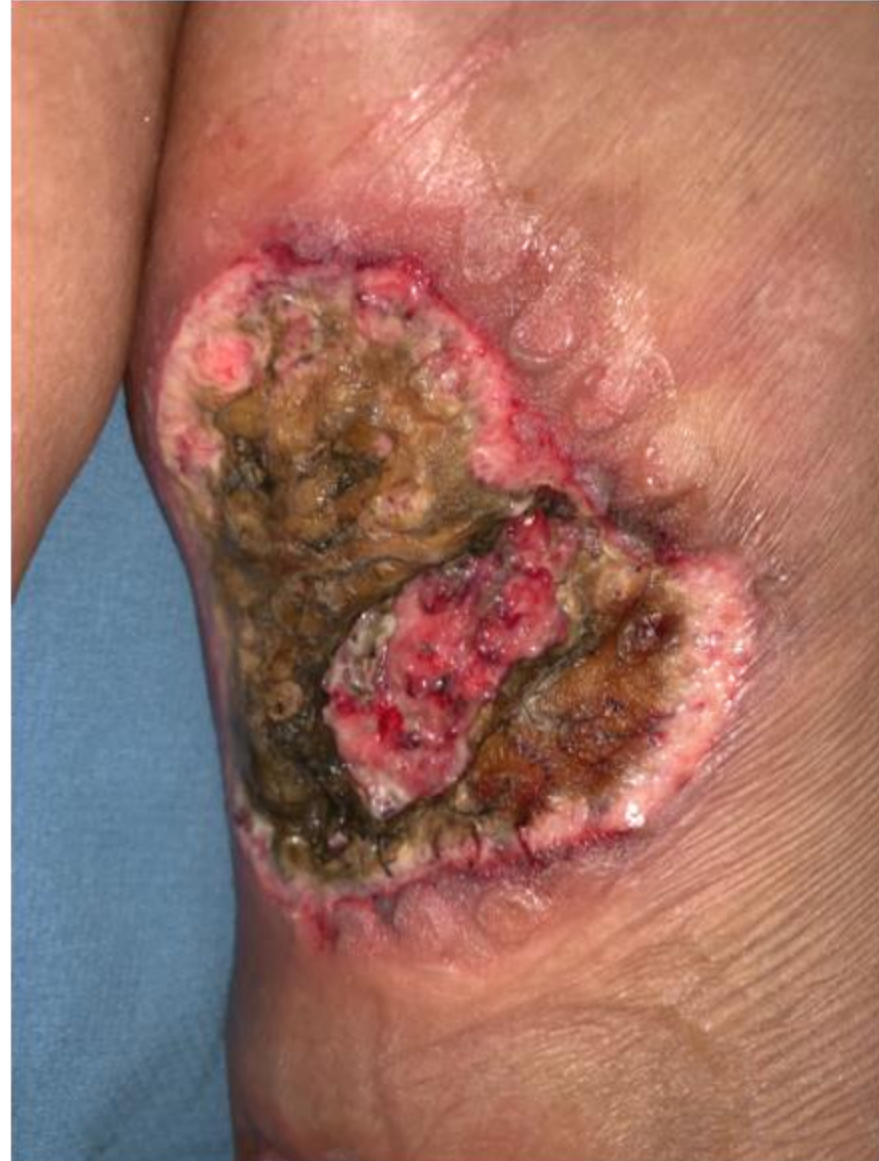

Complex Wound, Left Thigh (Day 1)



She is on Heparin

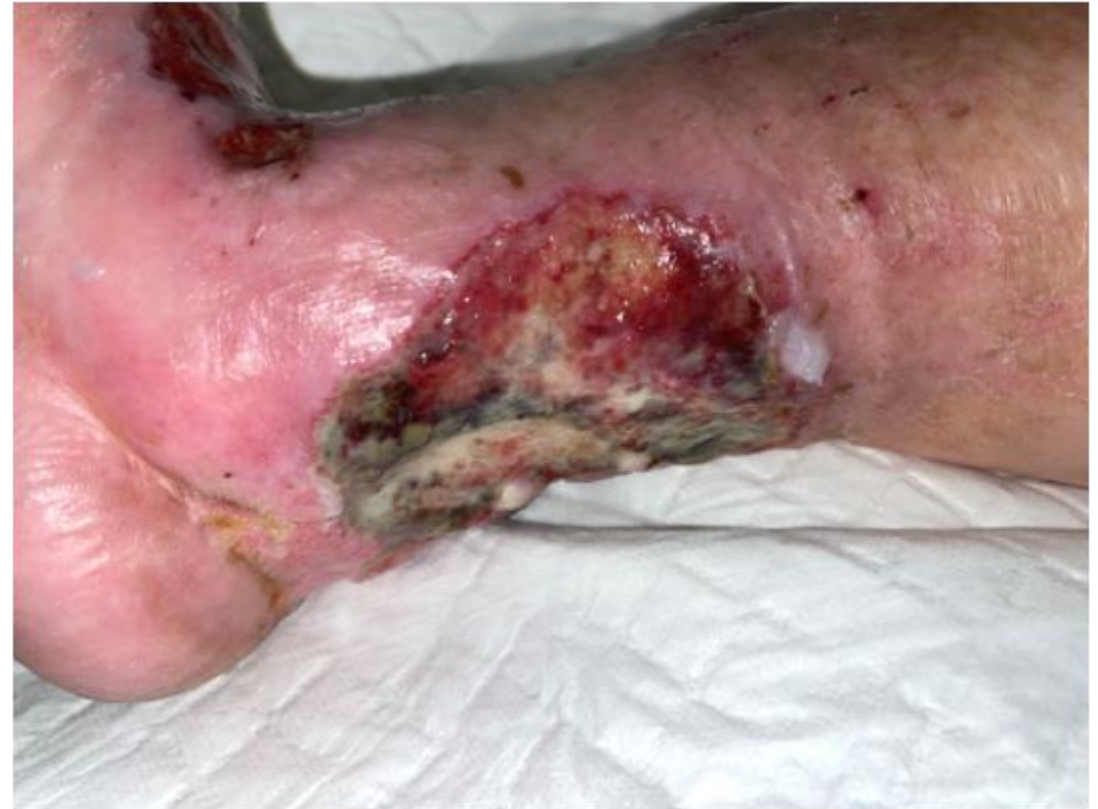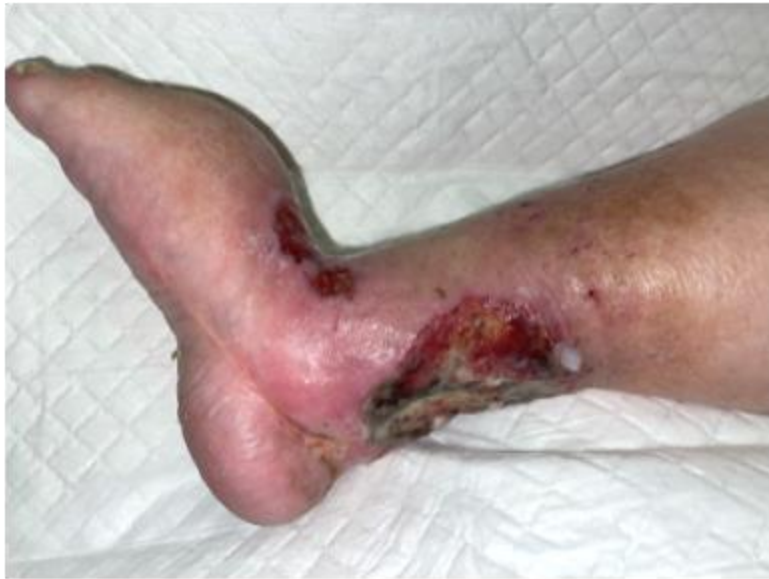Friday 8:05 AM



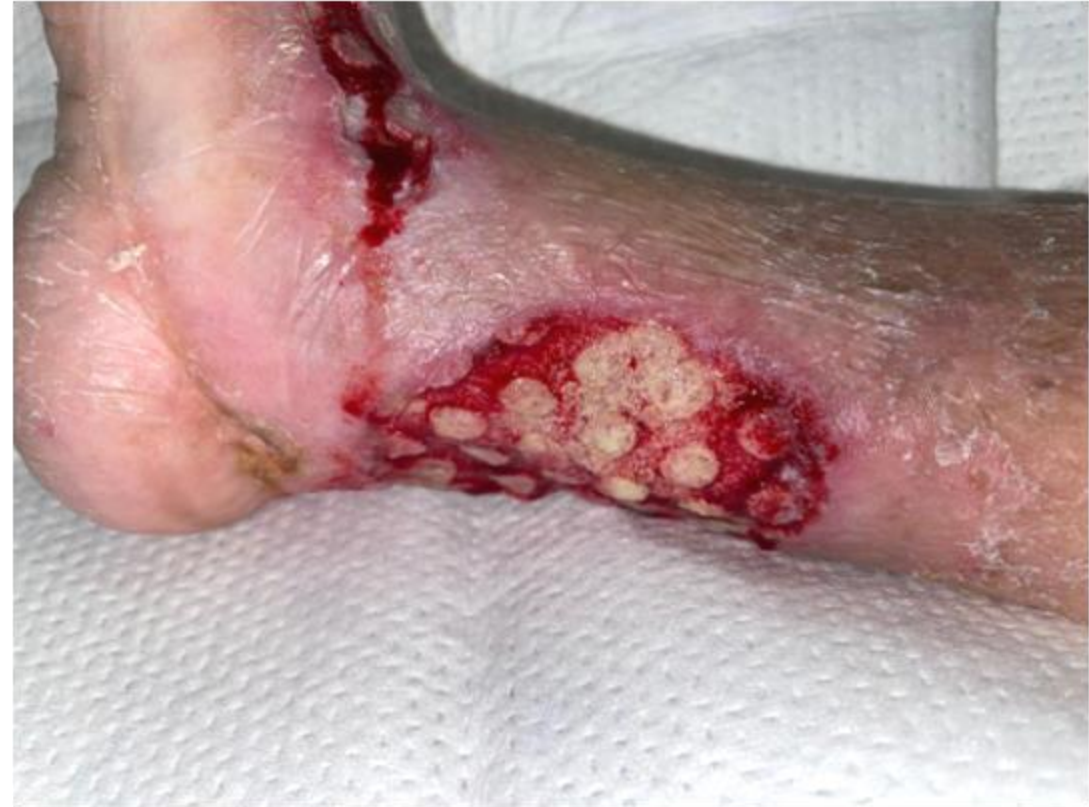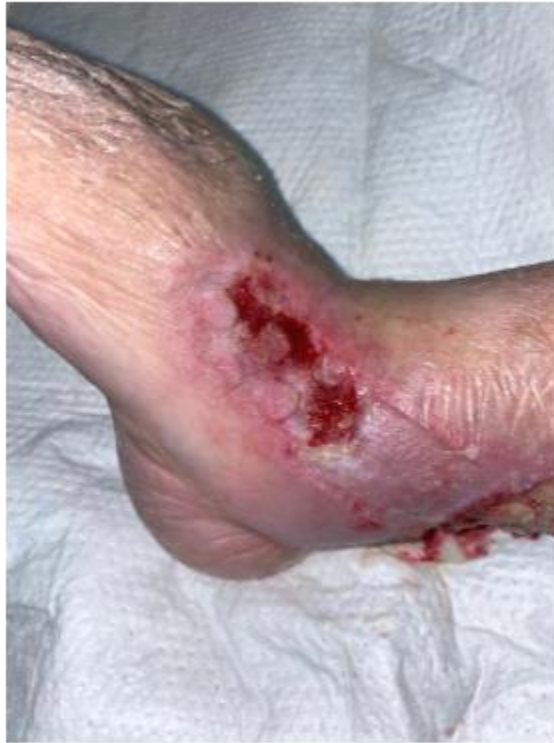Case Summary: Non-Healing Wound, Charcot Deformity

- 69y Female presents with non-healing wound BLE
- Medical history: Arthrogryposis, obesity, asthma, venous insufficiency
- Multiple surgeries RLE for Charcot deformity
- Treatment
 - Admitted to hospital for acute infection RLE wound
 - NPWTi-d initiated for wound bed preparation RLE
 - 3M™ Promogran Prisma™ Matrix (ORC, silver, and silver-ORC dressing) initiated LLE
 - Taken to OR for split-thickness skin graft (STSG) RLE
 - NPWT continued as bolster dressing for STSG for 7 days

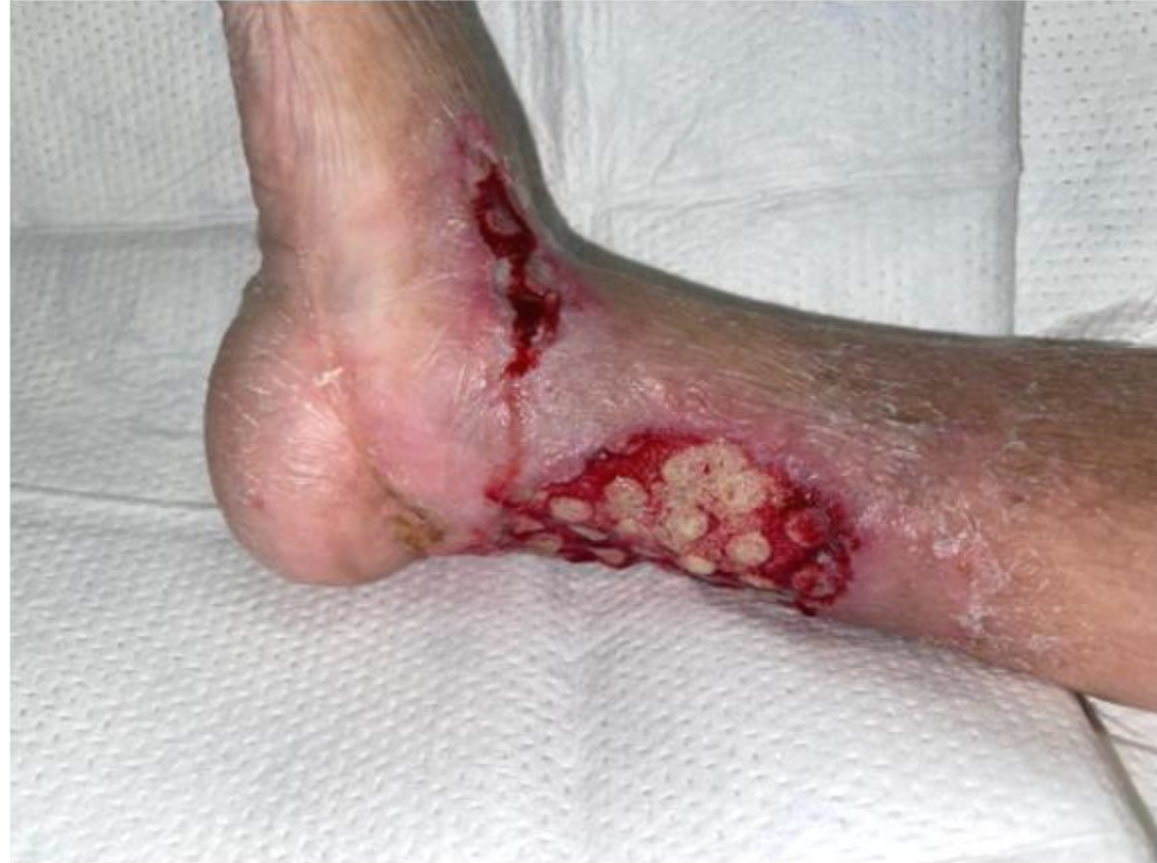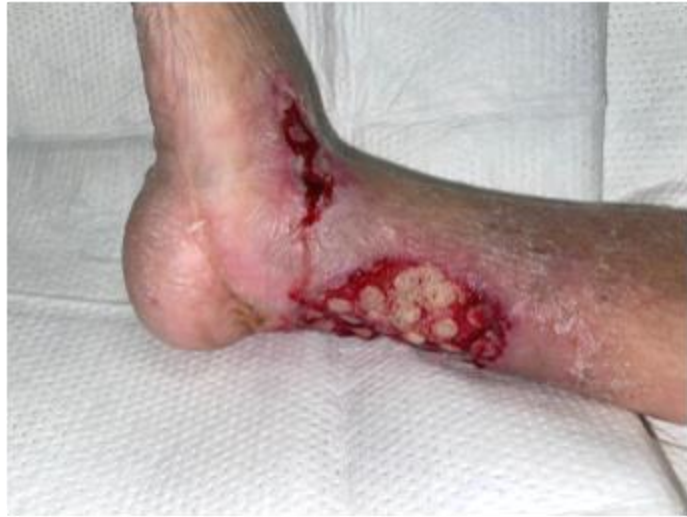Non-Healing Surgical Wound, Charcot Deformity (Day 0)



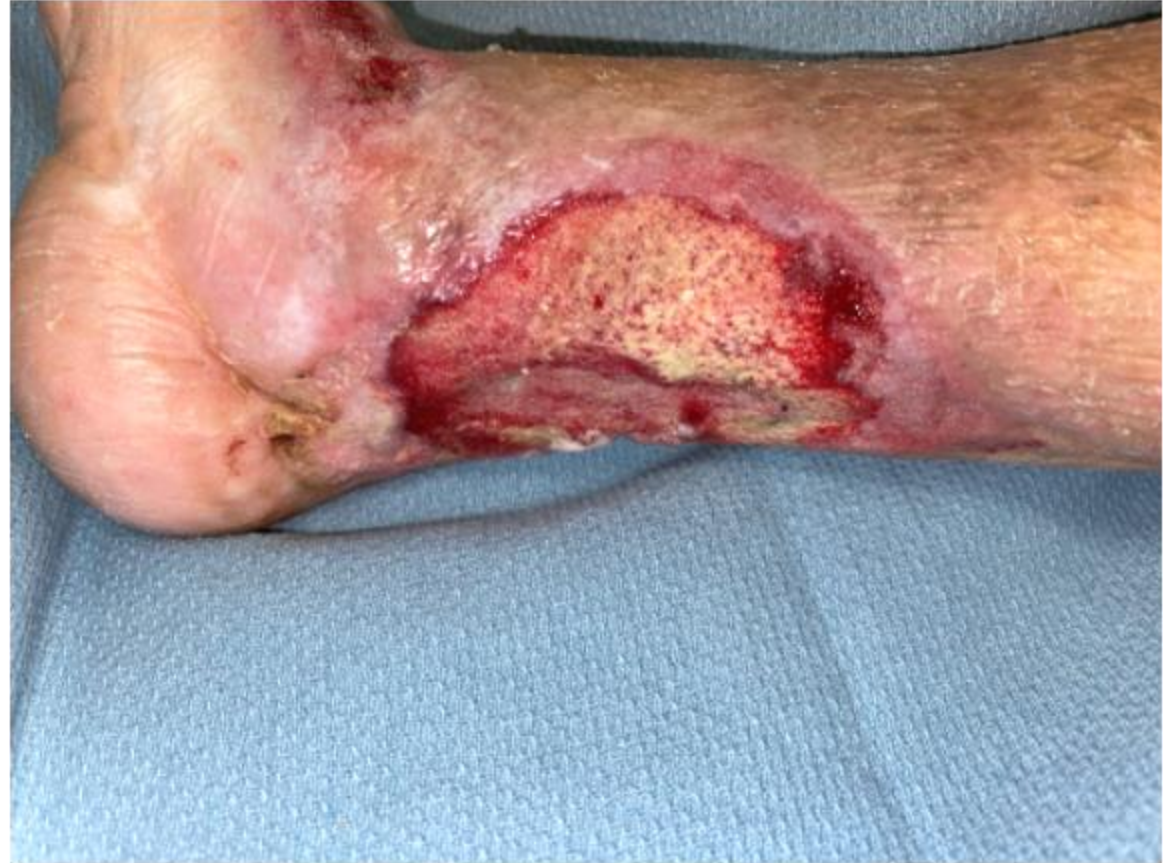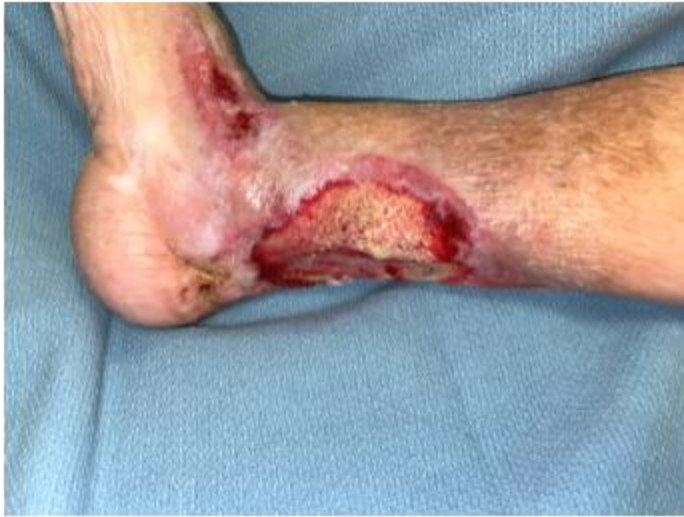Non-Healing Surgical Wound, Charcot Deformity (Day 3)



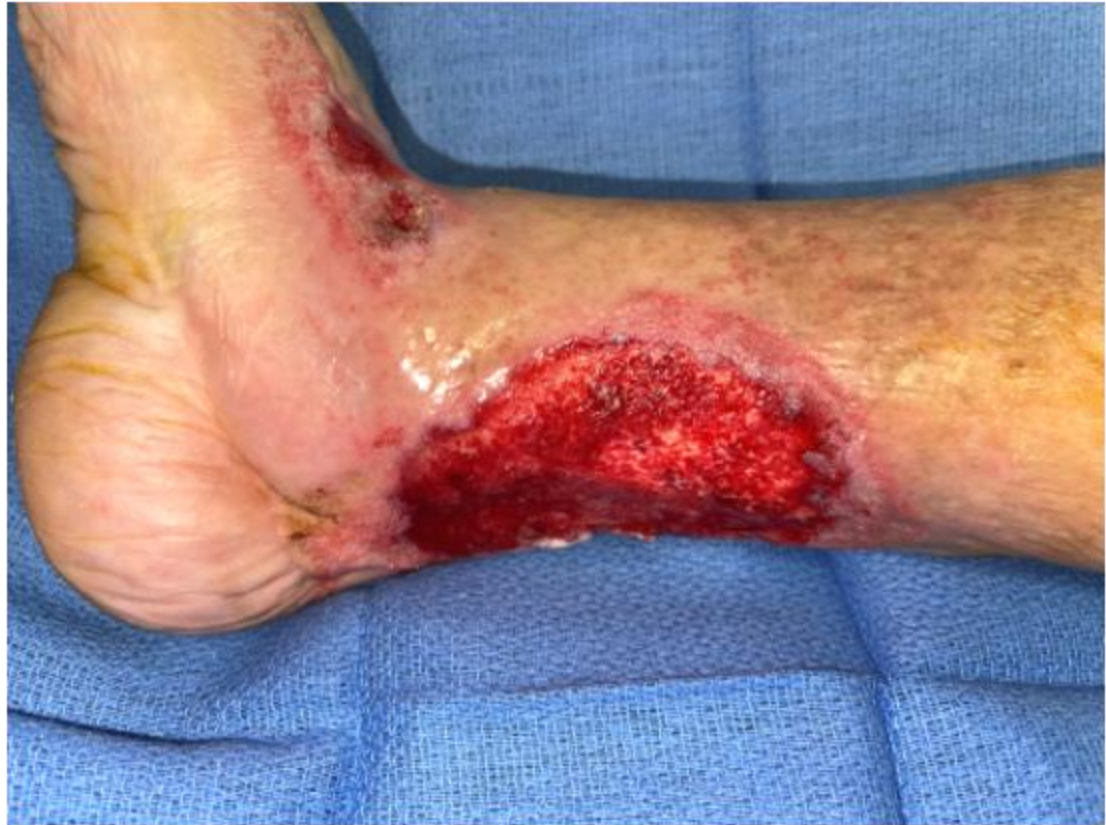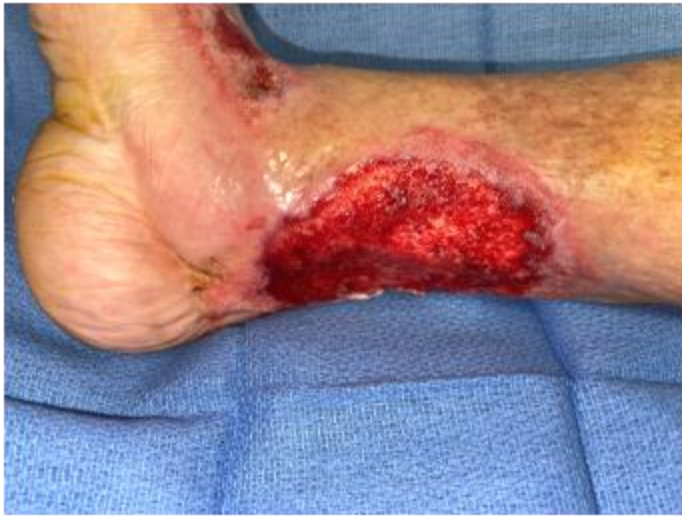Non-Healing Surgical Wound, Charcot Deformity (Day 7)



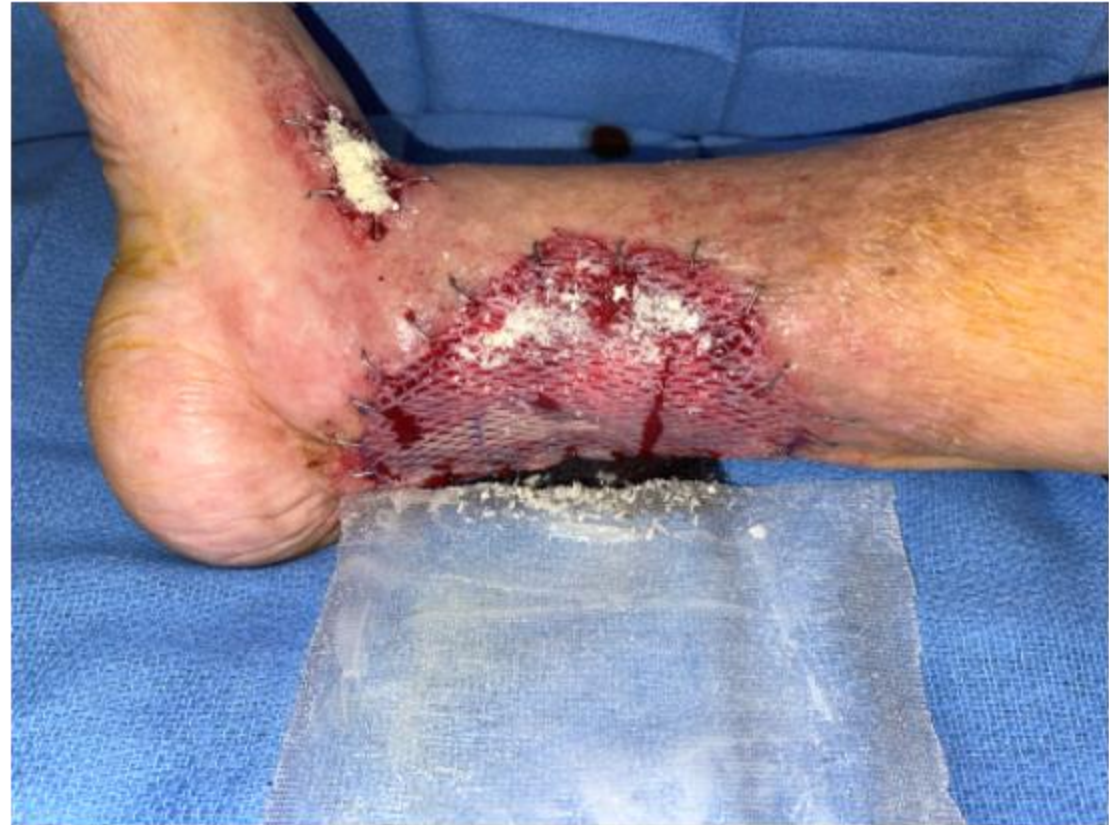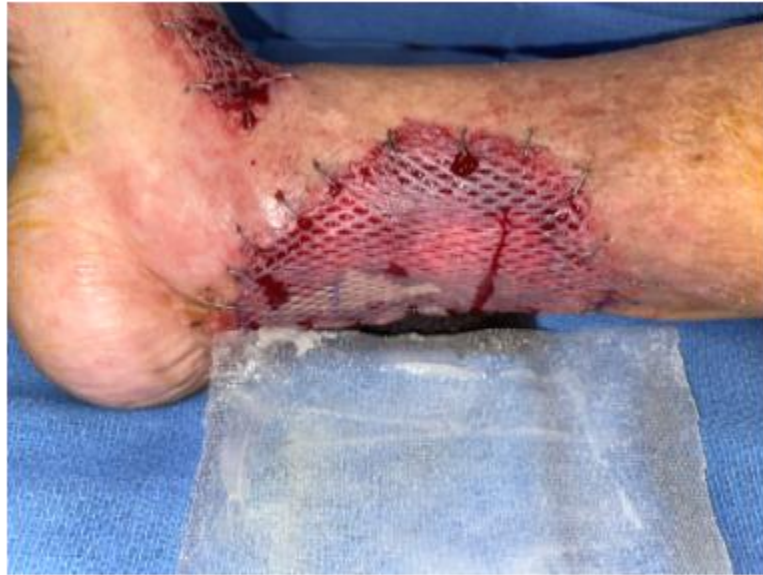Non-Healing Surgical Wound, Charcot Deformity (Day 10)



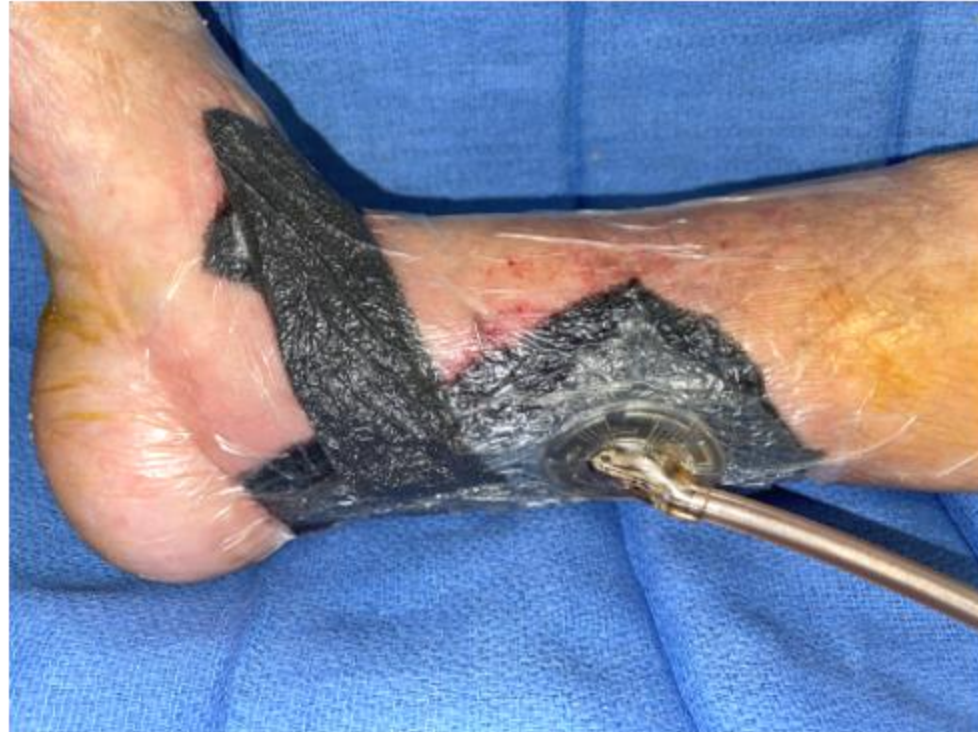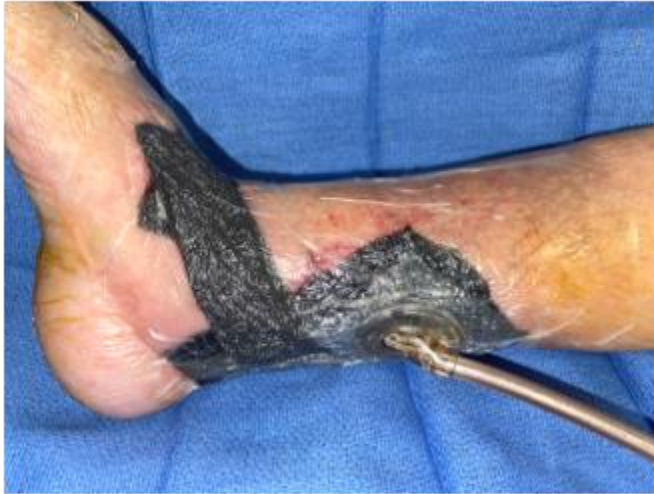Non-Healing Surgical Wound, Charcot Deformity (Day 10)



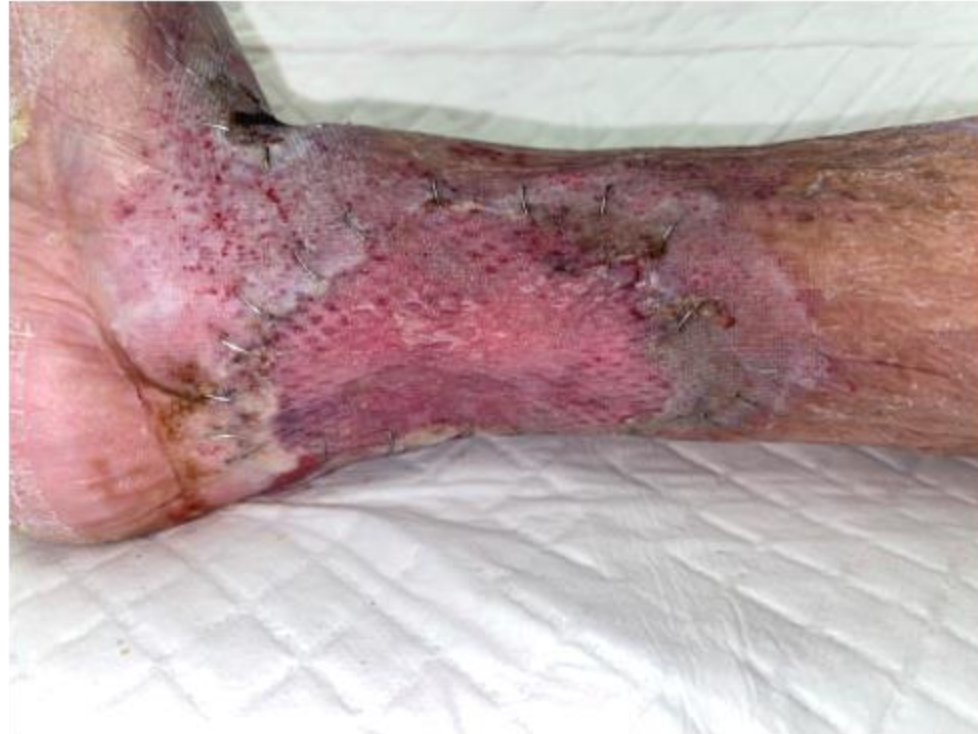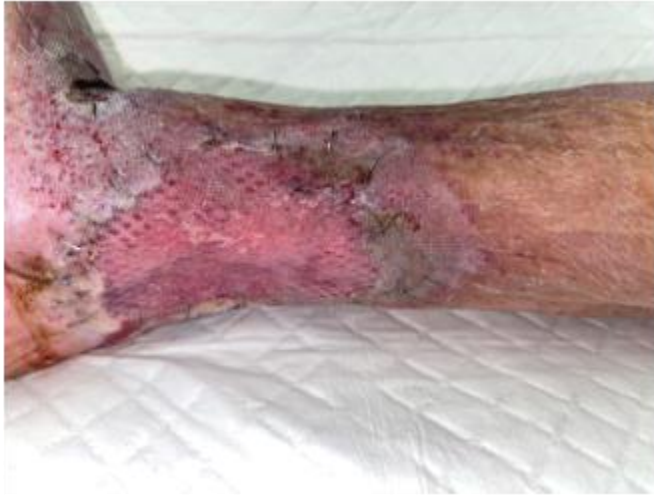Non-Healing Surgical Wound, Charcot Deformity (Day 10)



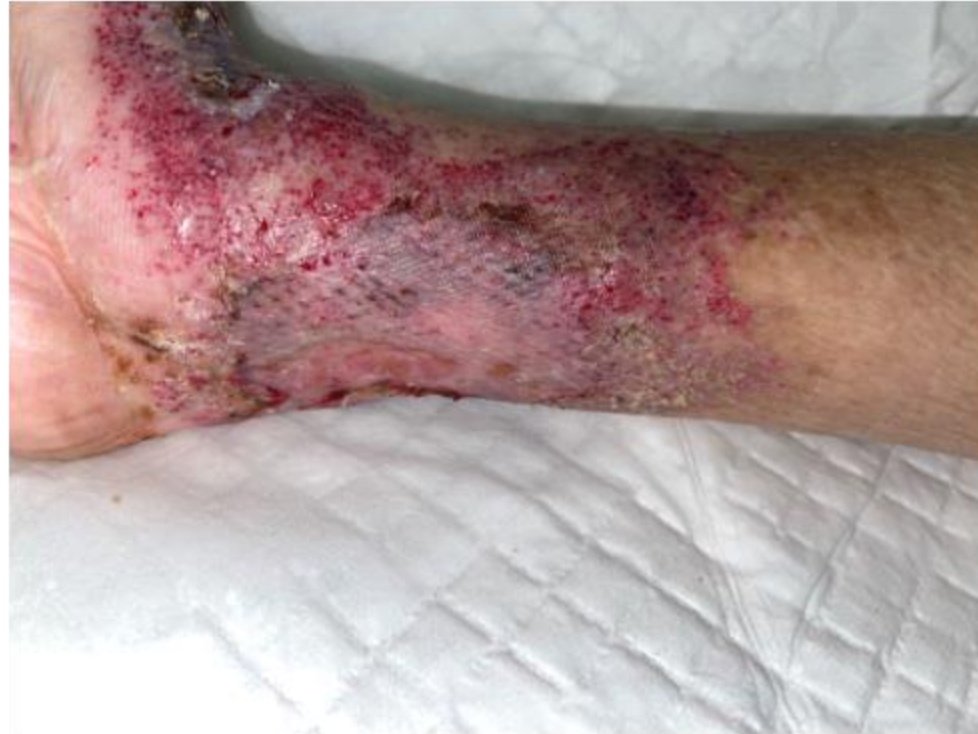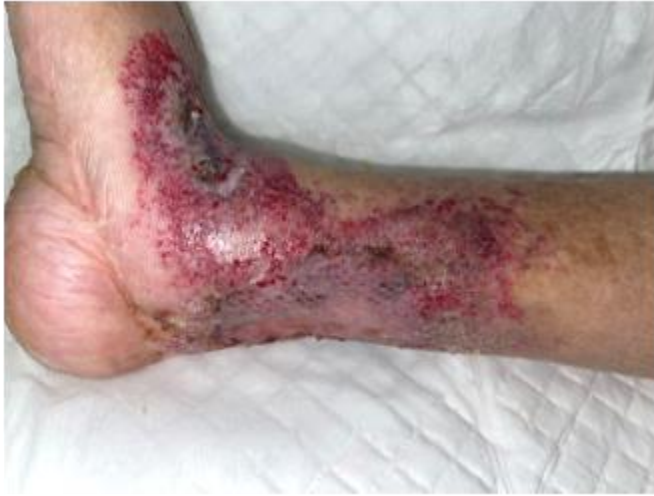Non-Healing Surgical Wound, Charcot Deformity (Day 10)



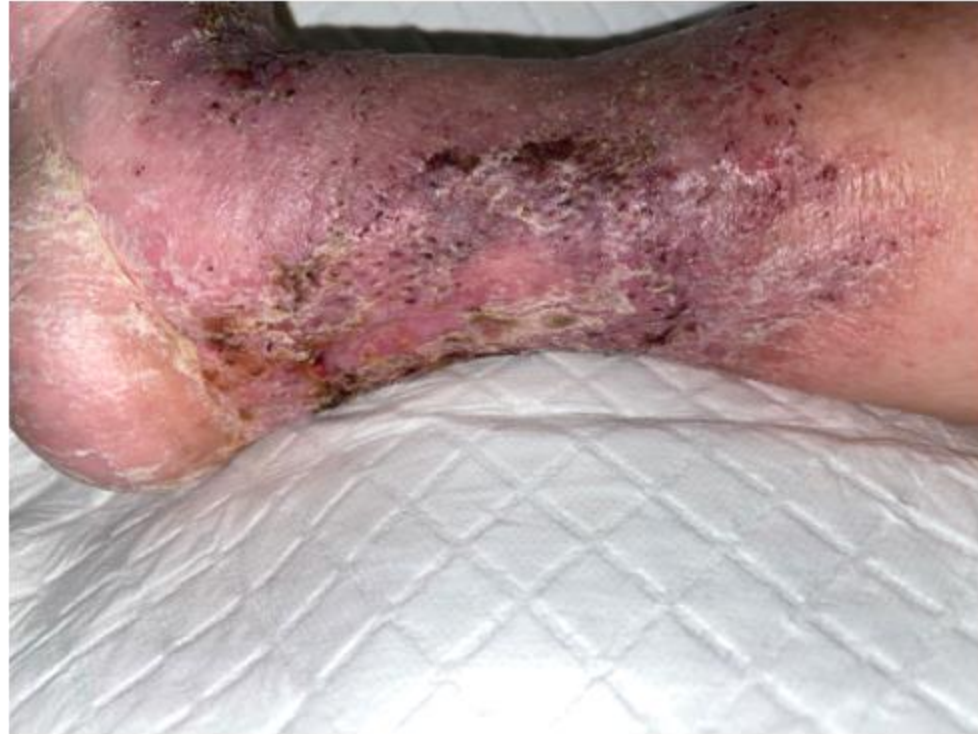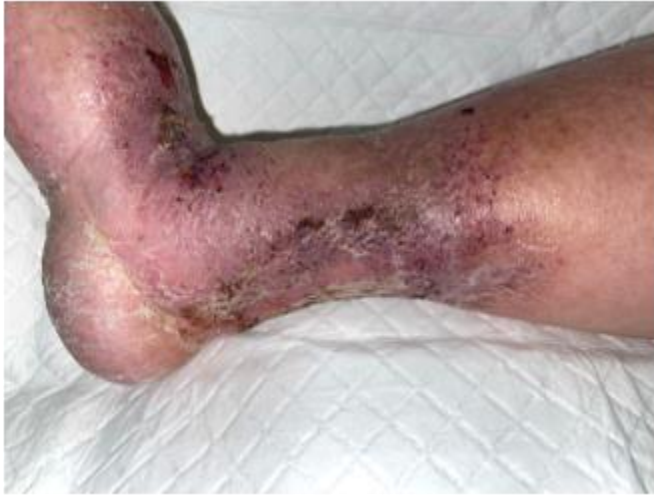Non-Healing Surgical Wound, Charcot Deformity (Day 17)



Non-Healing Surgical Wound, Charcot Deformity (Day 24)



Non-Healing Surgical Wound, Charcot Deformity (4 Wks)





Polling Question

Negative pressure wound therapy with instillation and dwell (NPWTi-d) should NOT be used in a wound with significant necrotic debris?

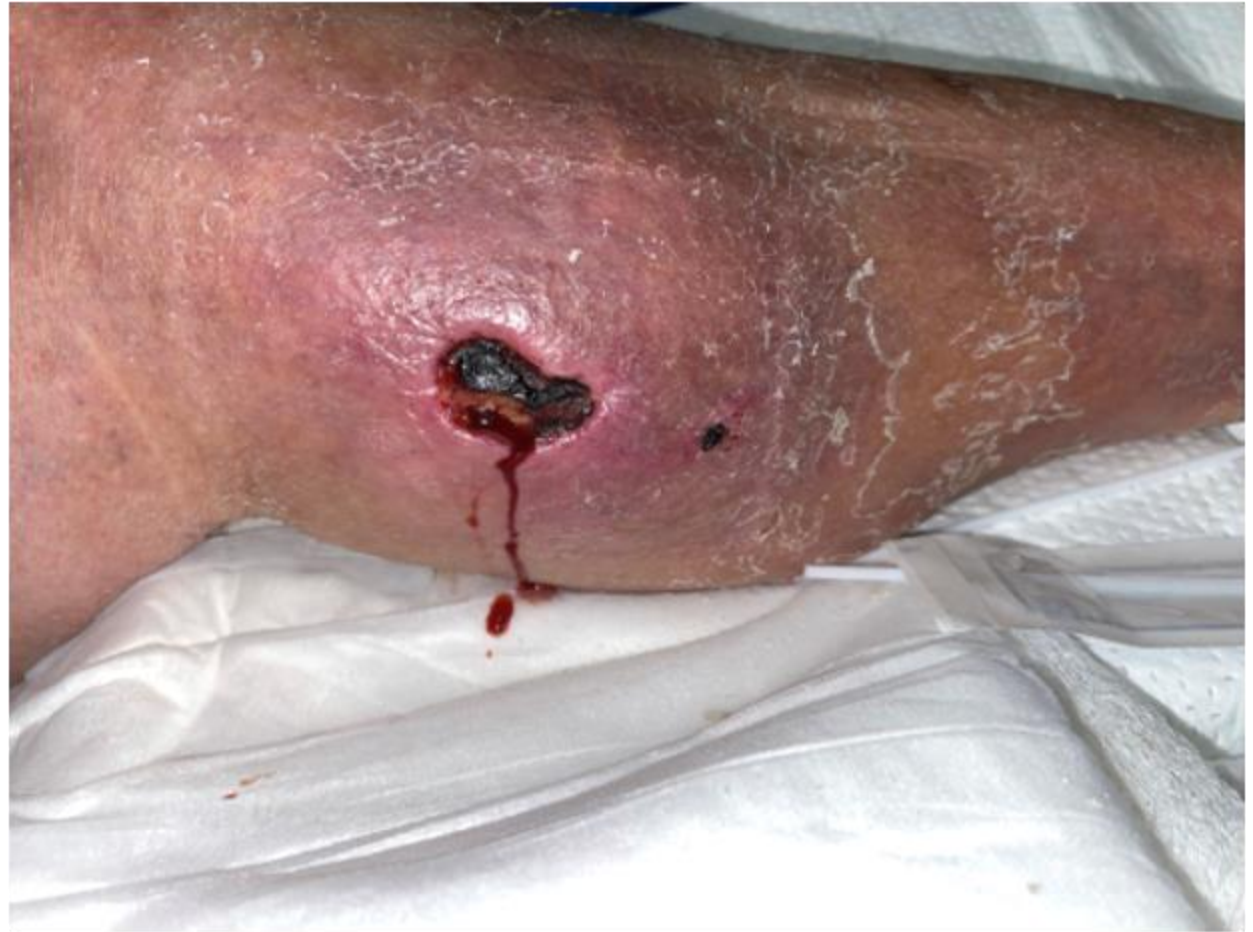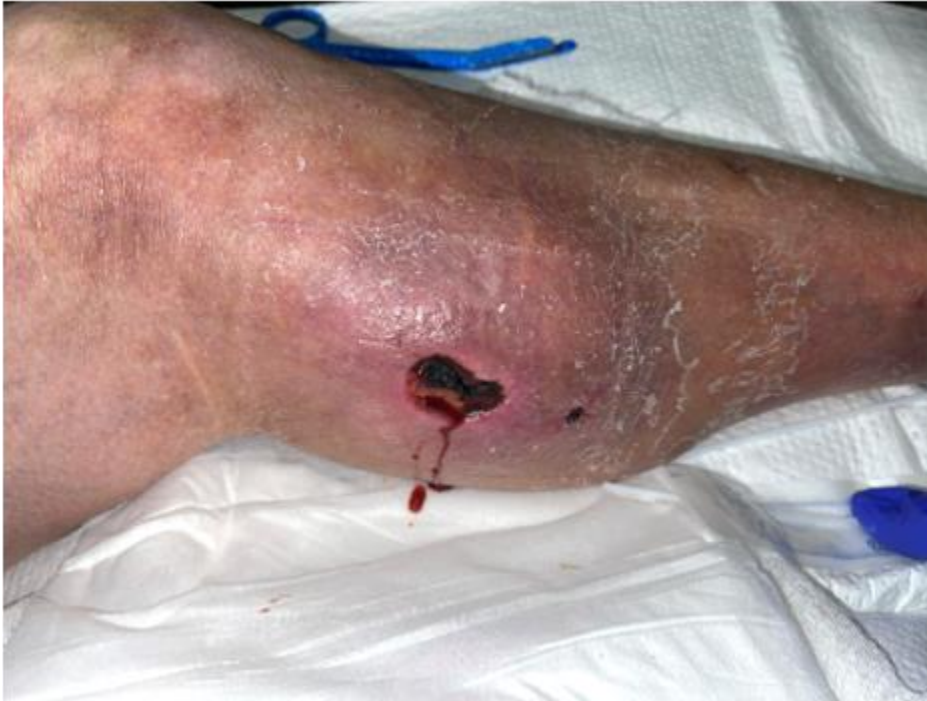- A. True
- B. False

***Polling was pre-recorded.**

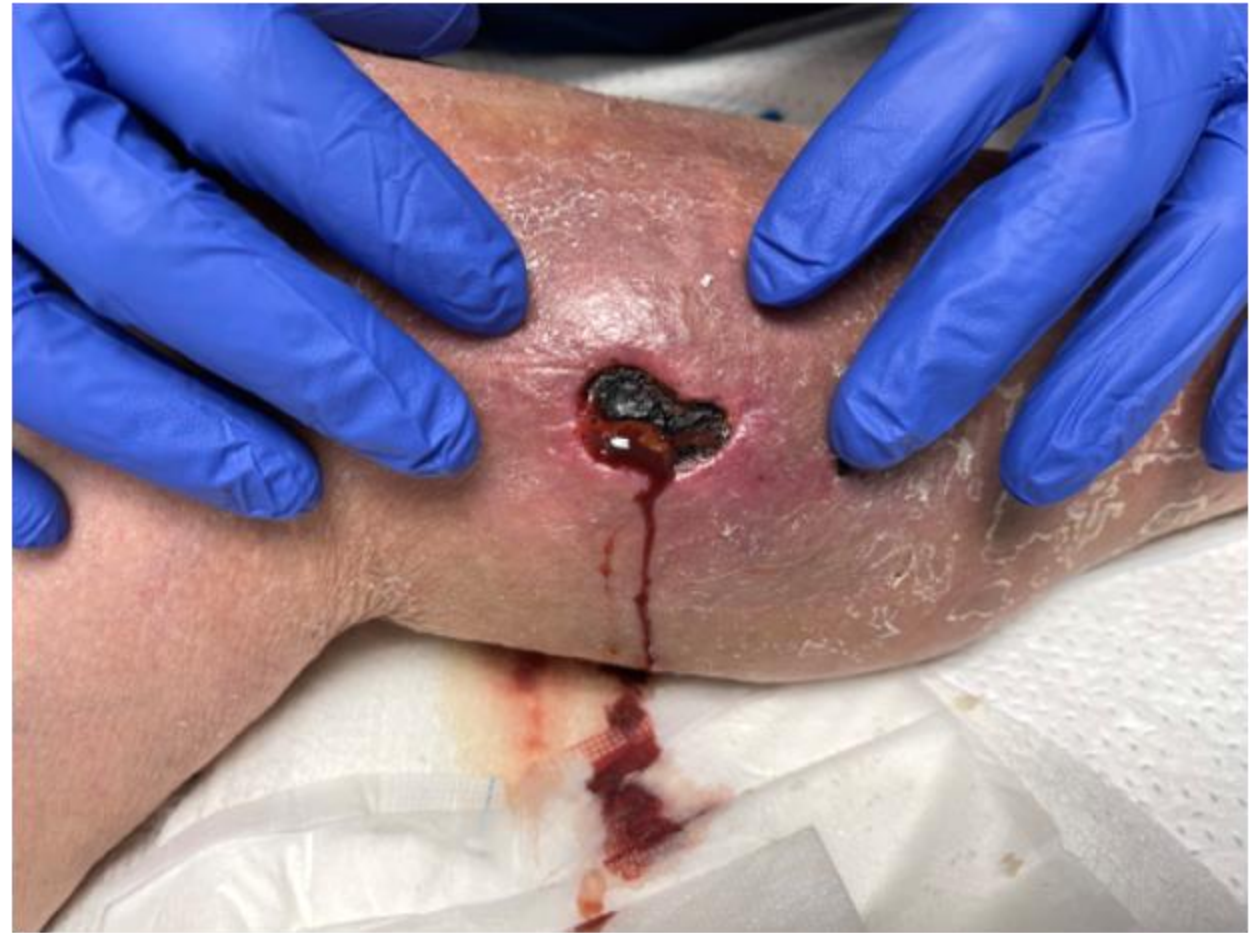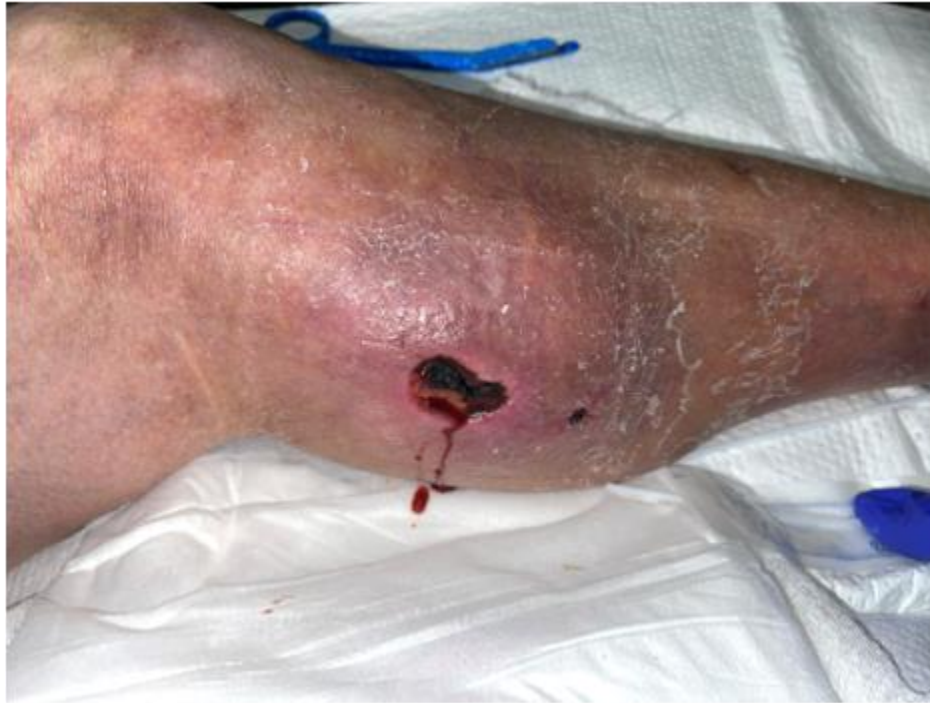Case Summary: Hematoma, LLE

- 78y Female with h/o trauma resulting in LLE hematoma. Pt is anticoagulated secondary to congenital clotting disorder. While awaiting surgery, she was admitted to hospital with worsening pain and erythema consistent with infection.
- Medical history: Clotting disorder
- Treatment:
 - Admitted to hospital for IV antibiotic therapy
 - Underwent bedside evacuation of hematoma
 - NPWTi-d initiated with at bedside
 - No operative intervention required
 - NPWT continued as outpatient

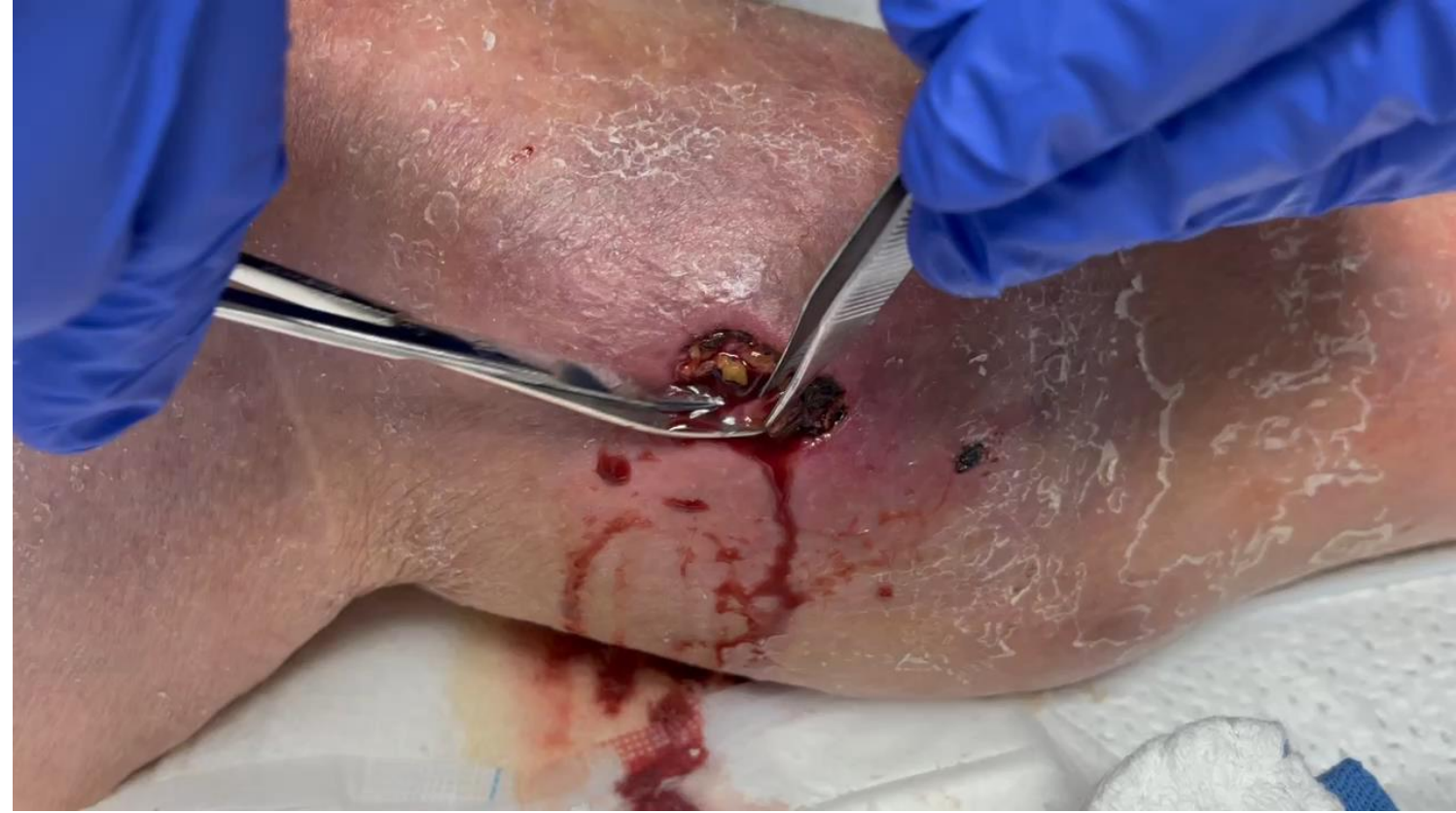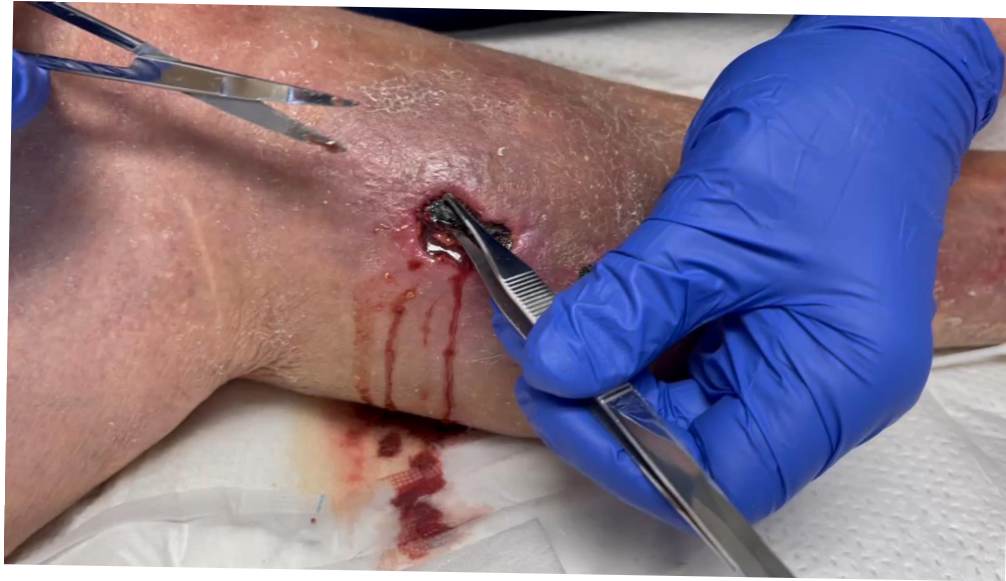Hematoma (Day 1)



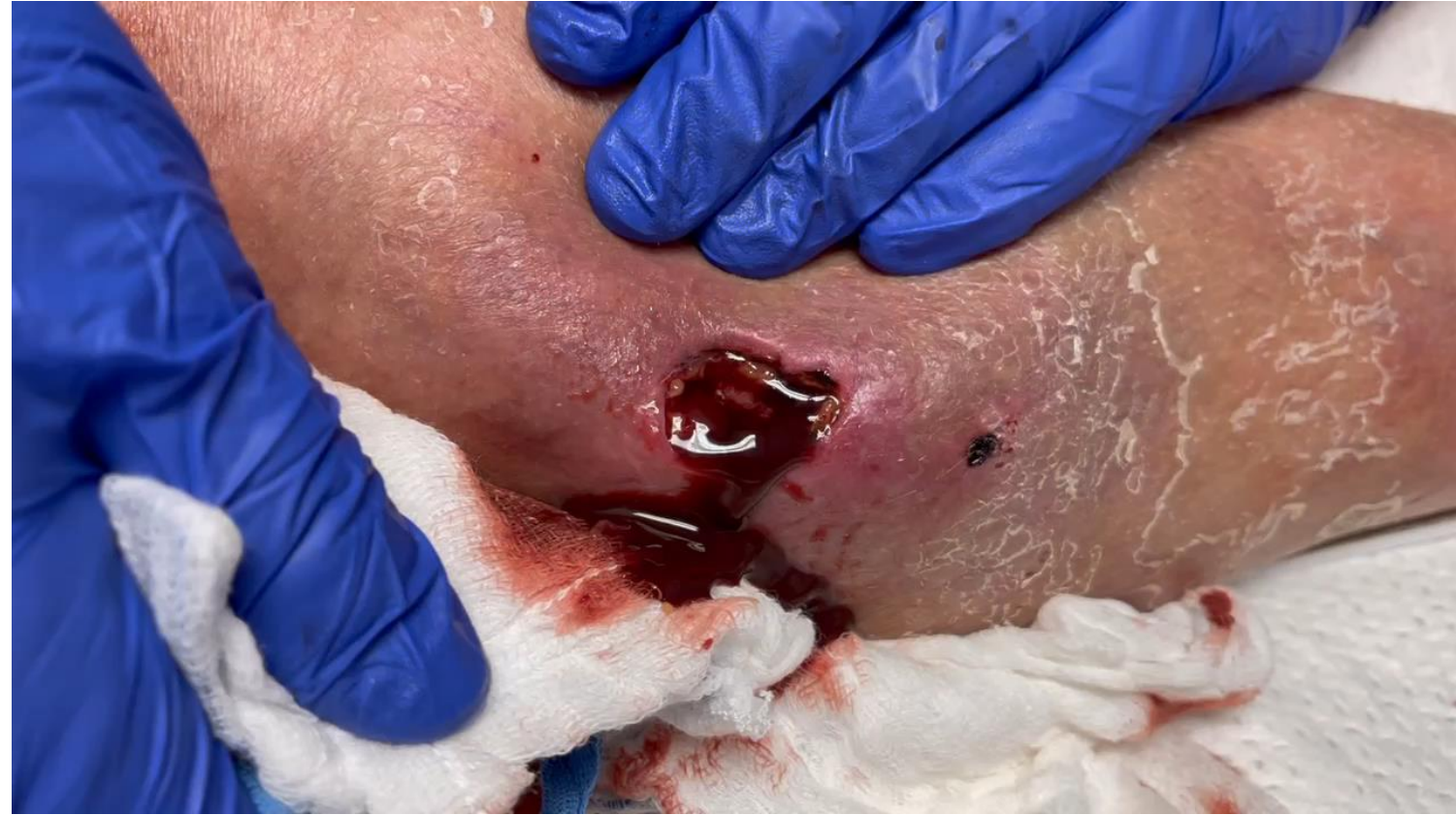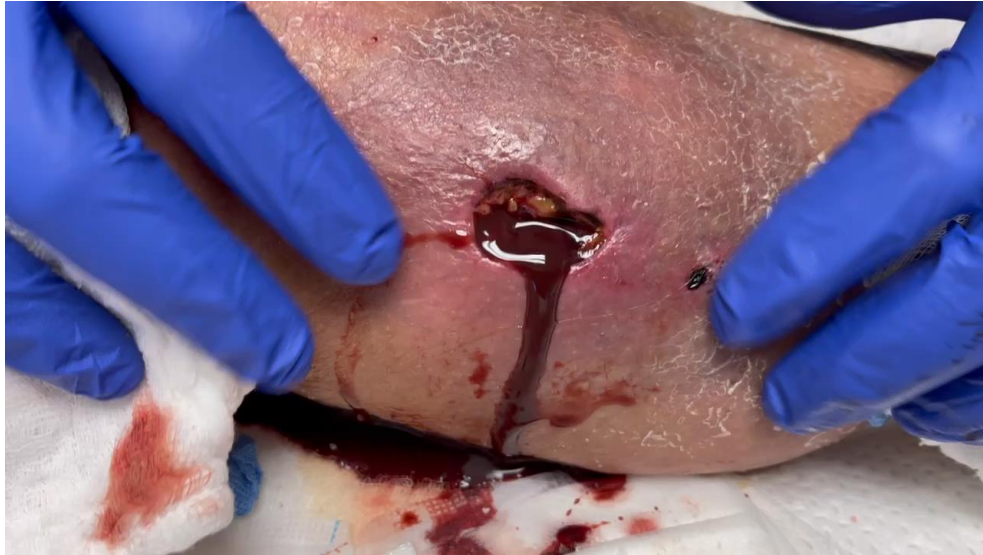Hematoma (Day 1)



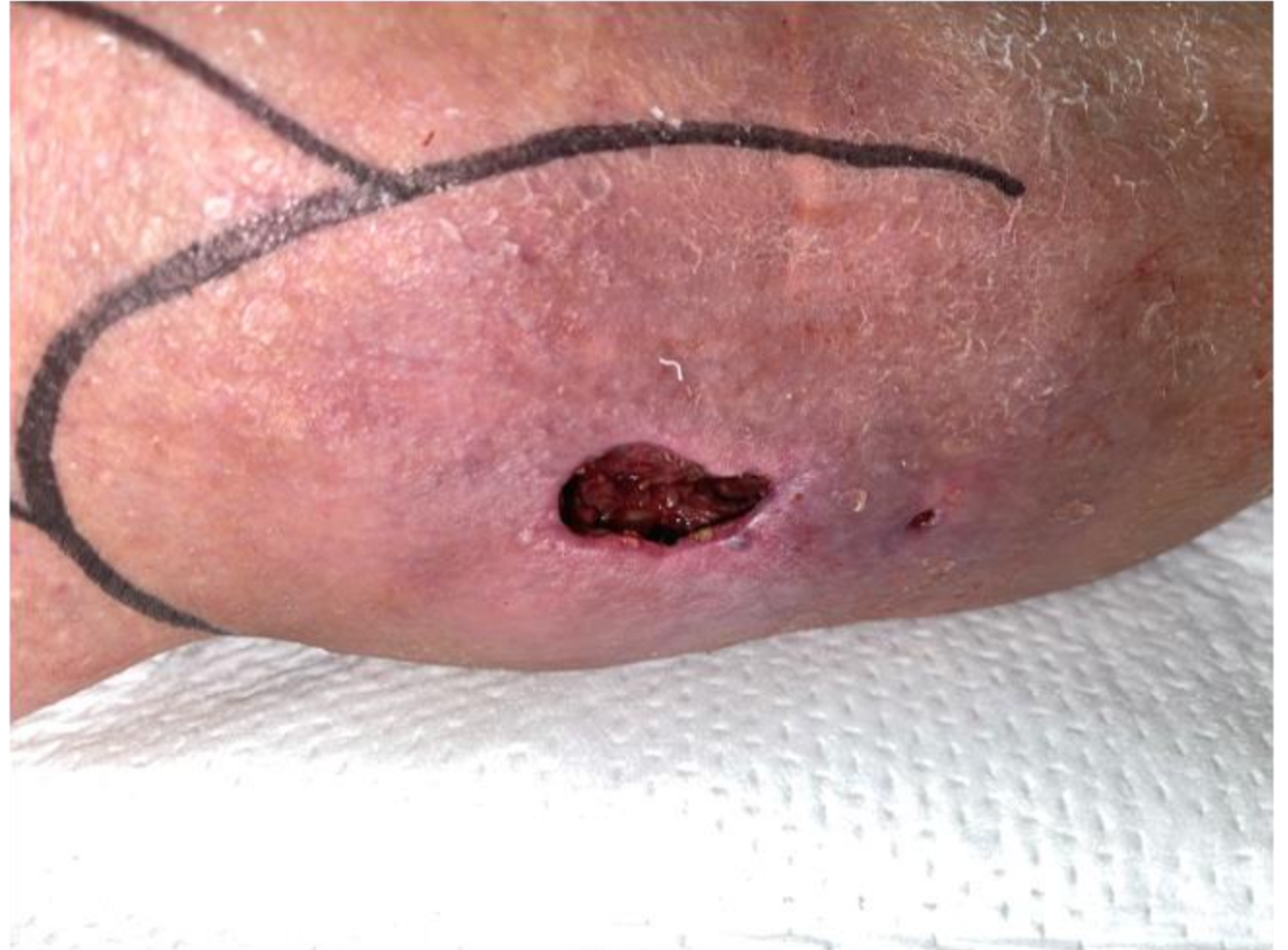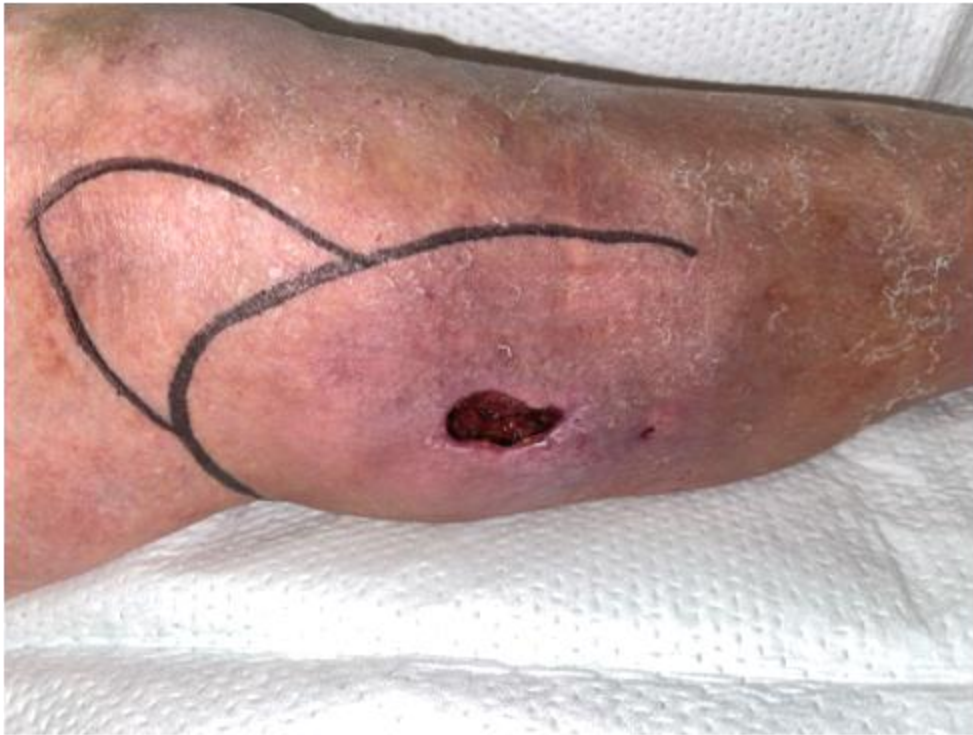Hematoma (Day 1)



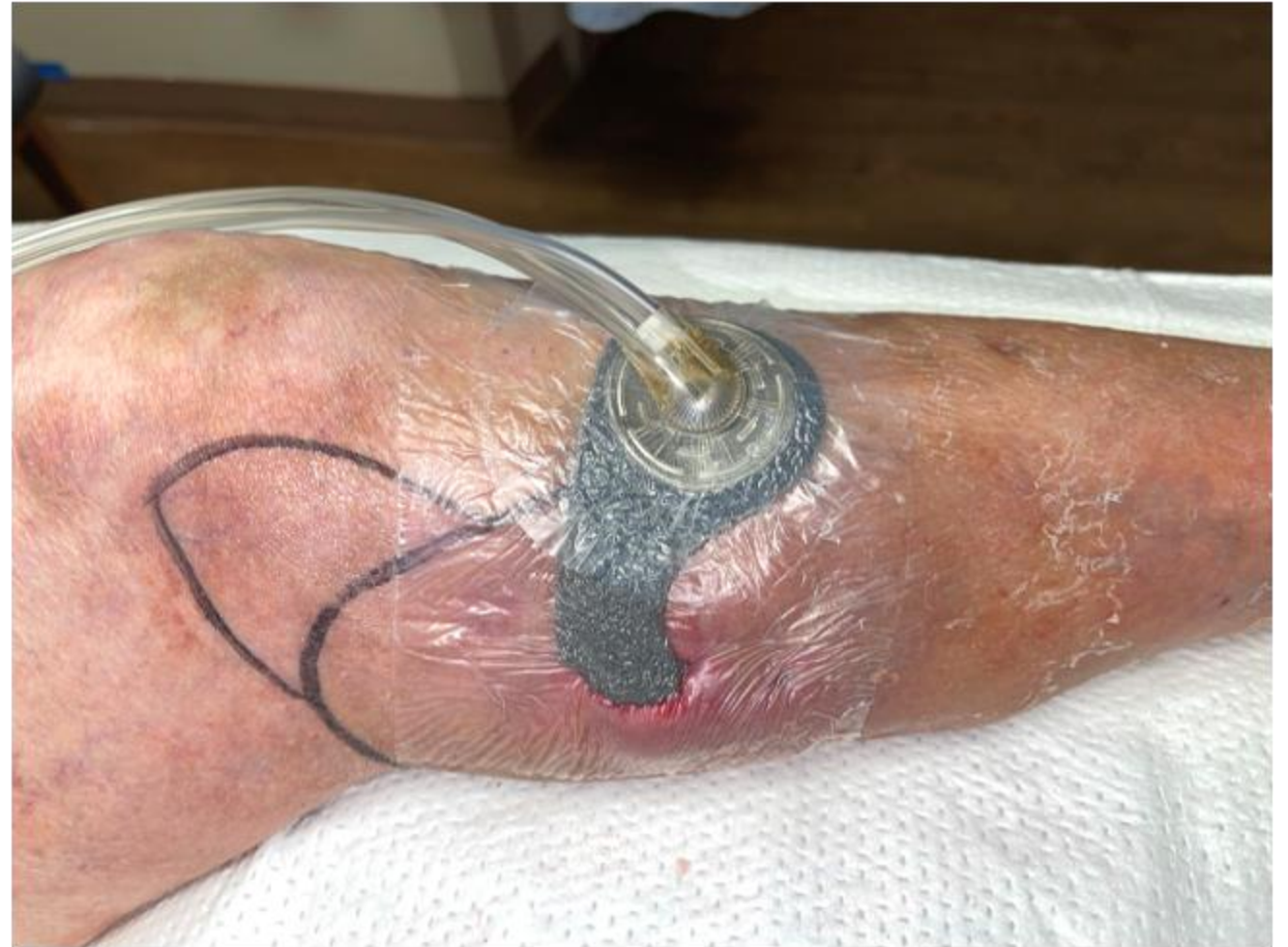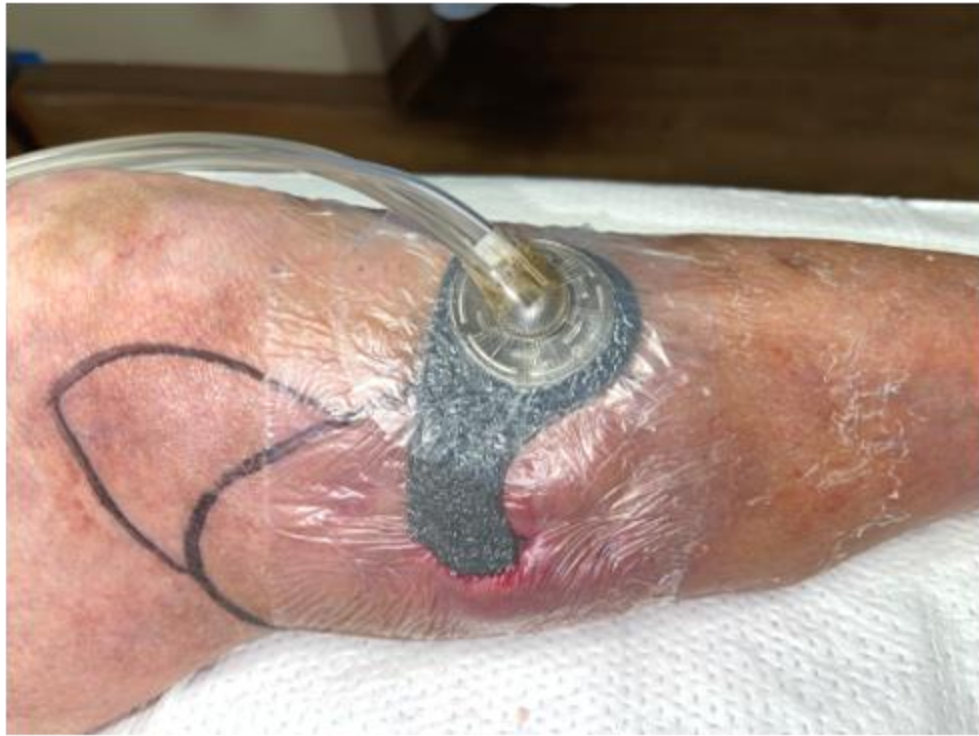Hematoma (Day 1)



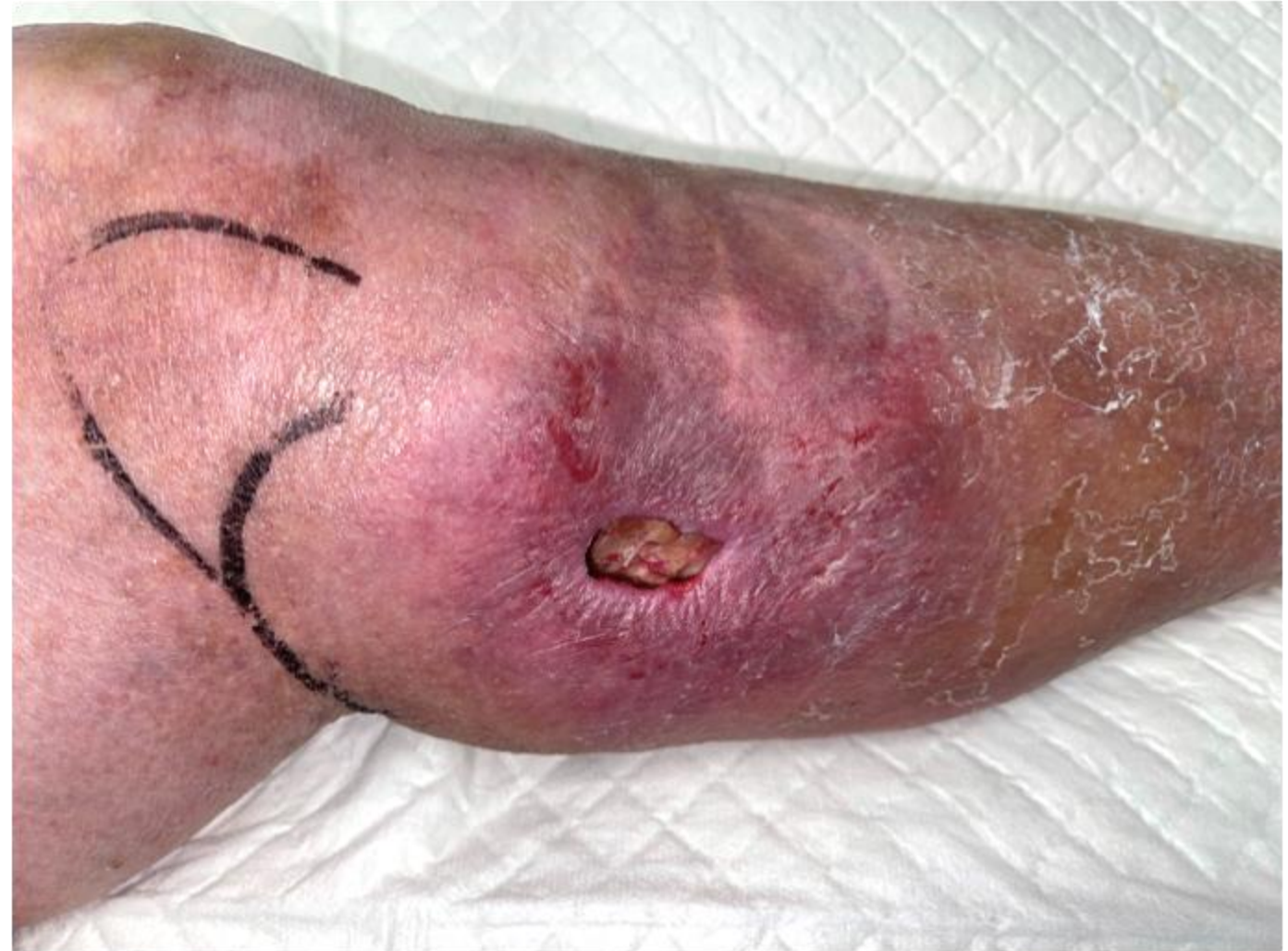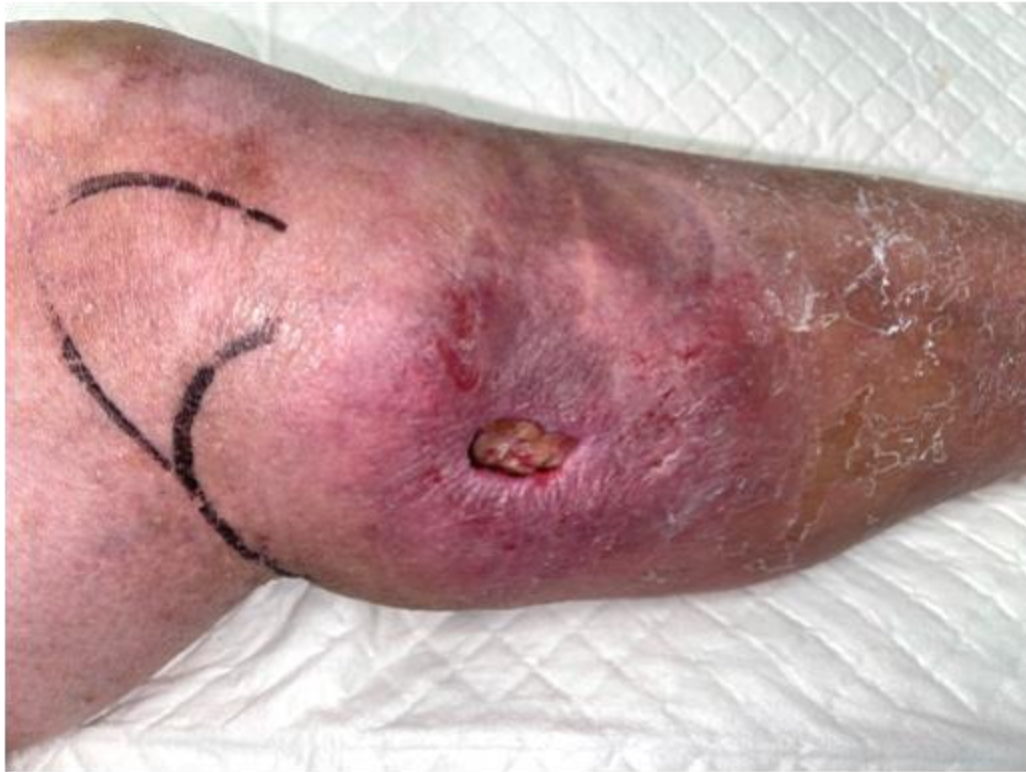Hematoma (Day 1)



Hematoma (Day 1)



Hematoma (Day 3)



PREVENA Therapy Has Been Granted A New Indication Statement by the FDA (U.S.)

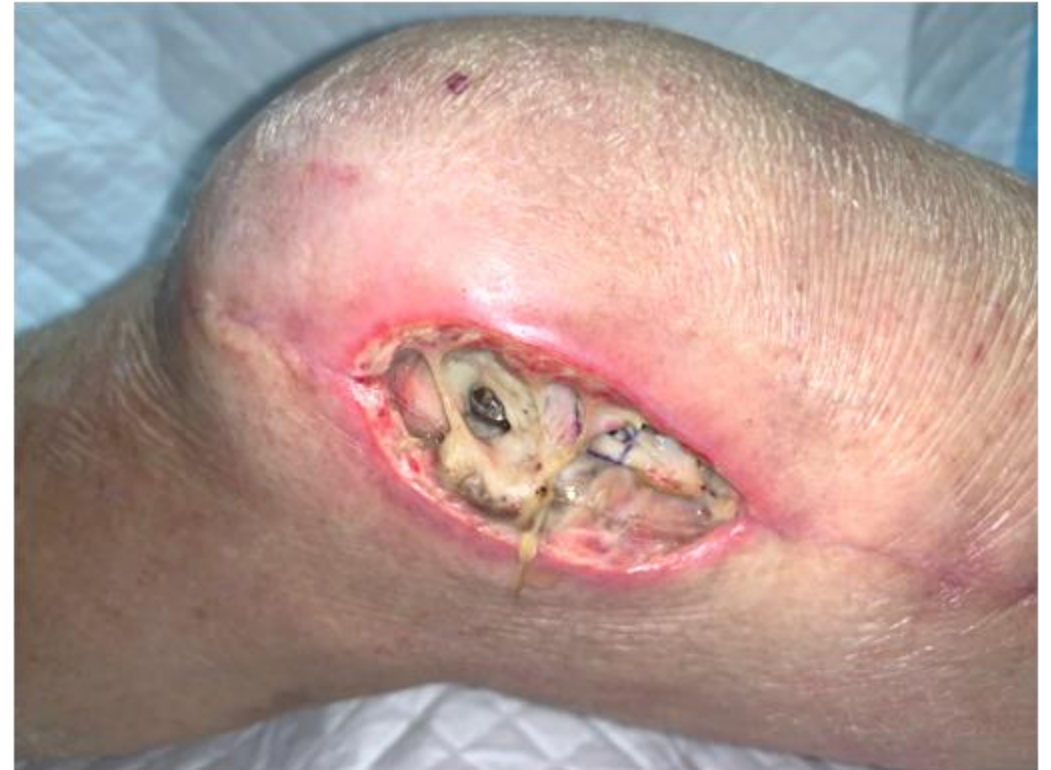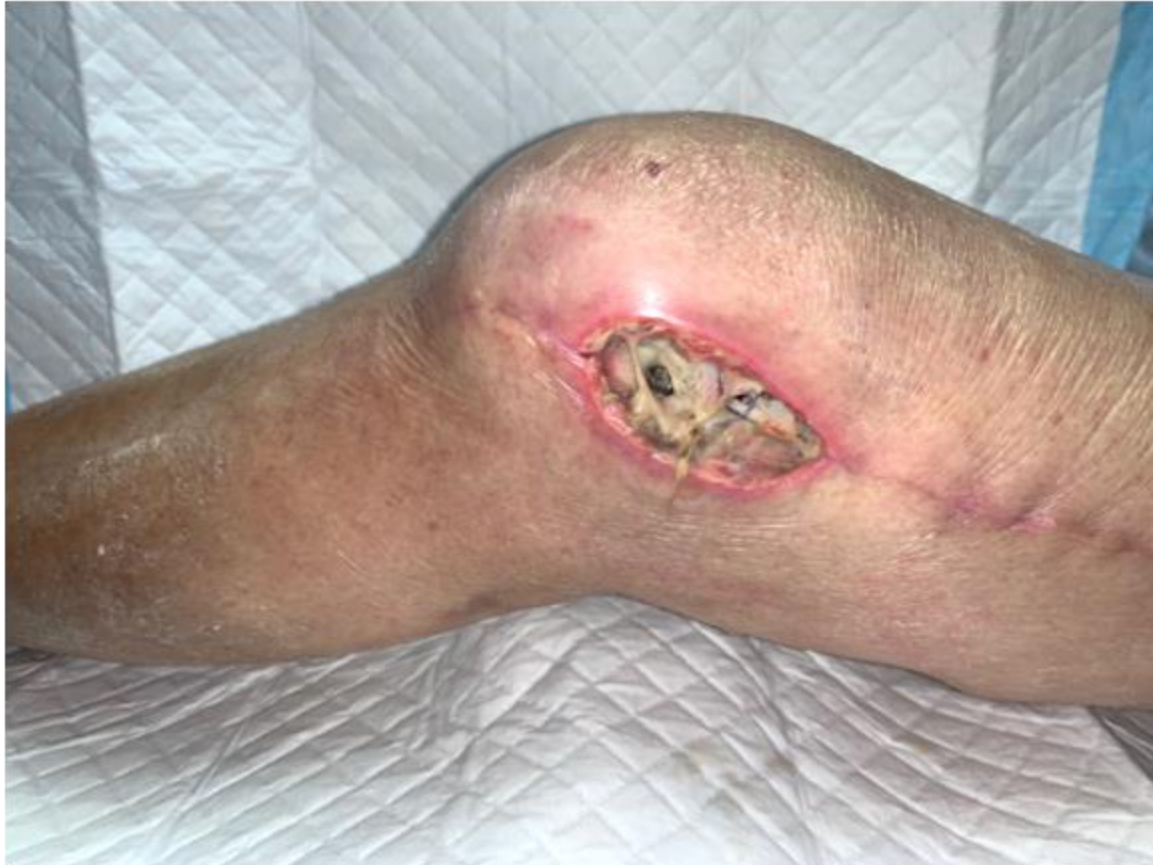PREVENA 125 and PREVENA PLUS 125 Therapy Units manage the environment of closed surgical incisions and remove fluid away from the surgical incision via the application of **-125mmHg continuous negative pressure**. When used with legally marketed compatible dressings, PREVENA 125 and PREVENA PLUS 125 Therapy Units are intended to **aid in reducing the incidence of seroma**; and, **in patients at high risk for post-operative infections, aid in reducing the incidence of superficial surgical site infection** in Class I and Class II wounds.

- *The effectiveness of PREVENA™ Therapy in reducing the incidence of SSIs and seromas in all surgical procedures and populations has not been demonstrated. See full indications for use and limitations at myKCI.com*
 - Limitations (Clinician Guide)
 - The device is not intended to treat surgical site infection or seroma
 - Safety and effectiveness in pediatric population (<22 years old) have not been evaluated
 - Safety and effectiveness in Class III (Contaminated) and Class IV (Dirty/Infected) wounds have not been demonstrated. Furthermore, Class IV surgical wounds are not expected to be closed primarily, and the subject device should only be used on closed surgical incisions.
 - The device has not been demonstrated to reduce deep incisional and organ space surgical site infections

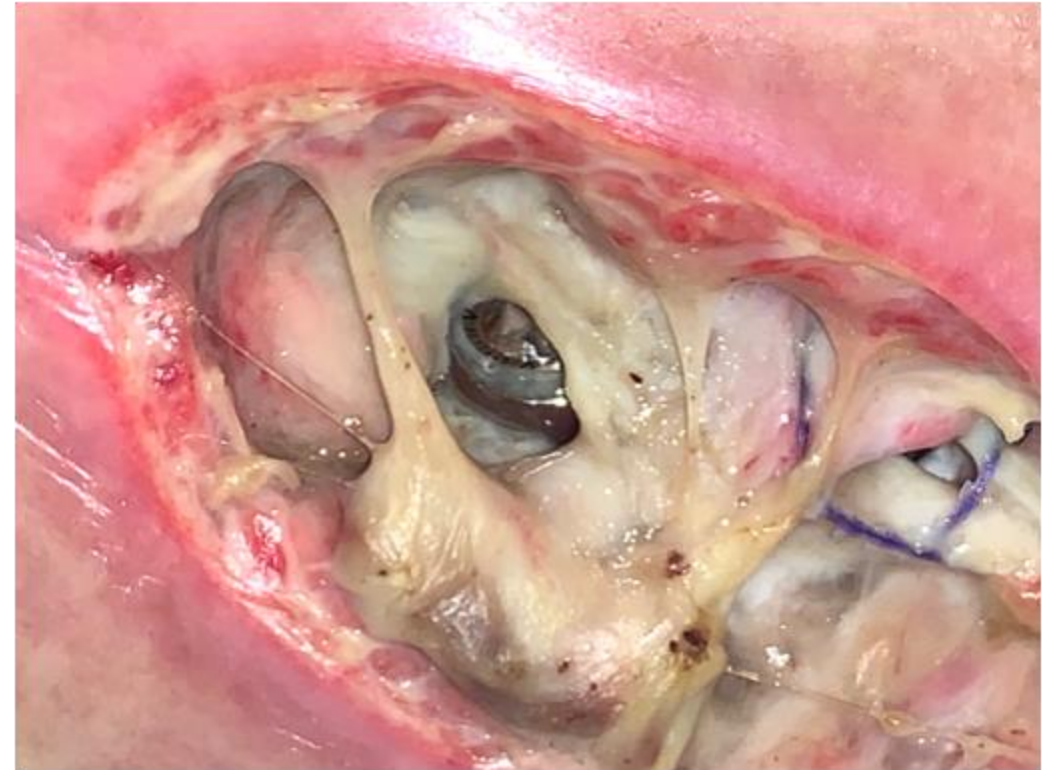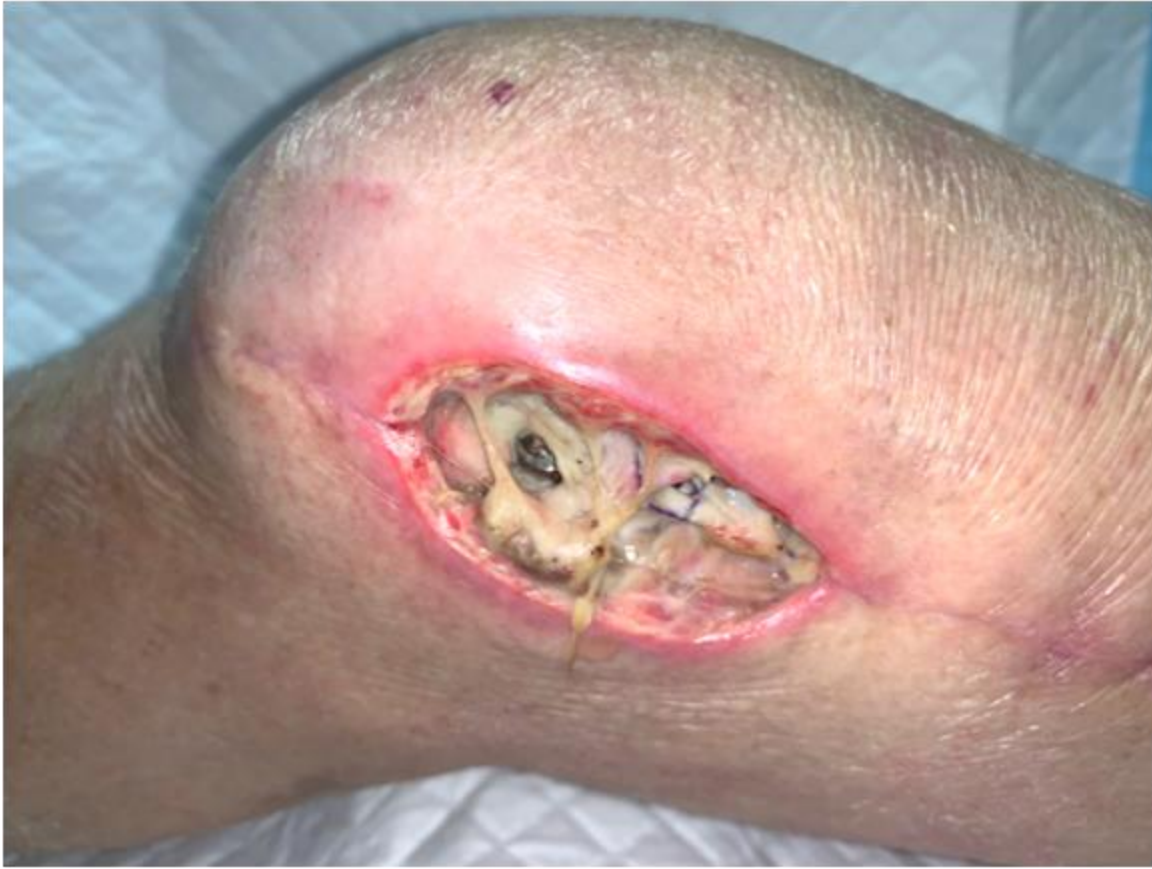Case Summary: Non-Healing Surgical Wound, Knee

- 69y Female presents with non-healing surgical wound 4 wks s/p ORIF distal femur fracture
- Medical history: Multiple surgeries R hip and previous L femur fracture DM, HTN, Chronic opioid use
- Treatment:
 - Taken to OR for excision non-viable tissue
 - NPWTi-d initiated for wound bed preparation
 - Returned to OR for definitive closure
 - Placental allograft placed to optimize healing
 - ciNPT initiated immediately following closure

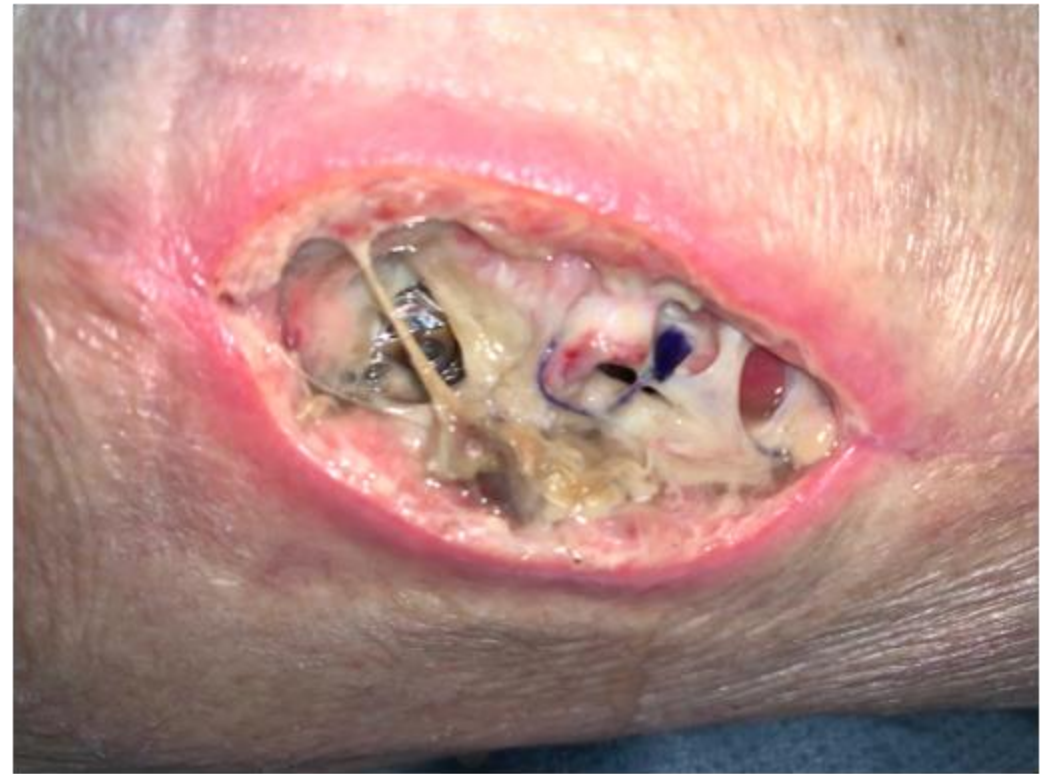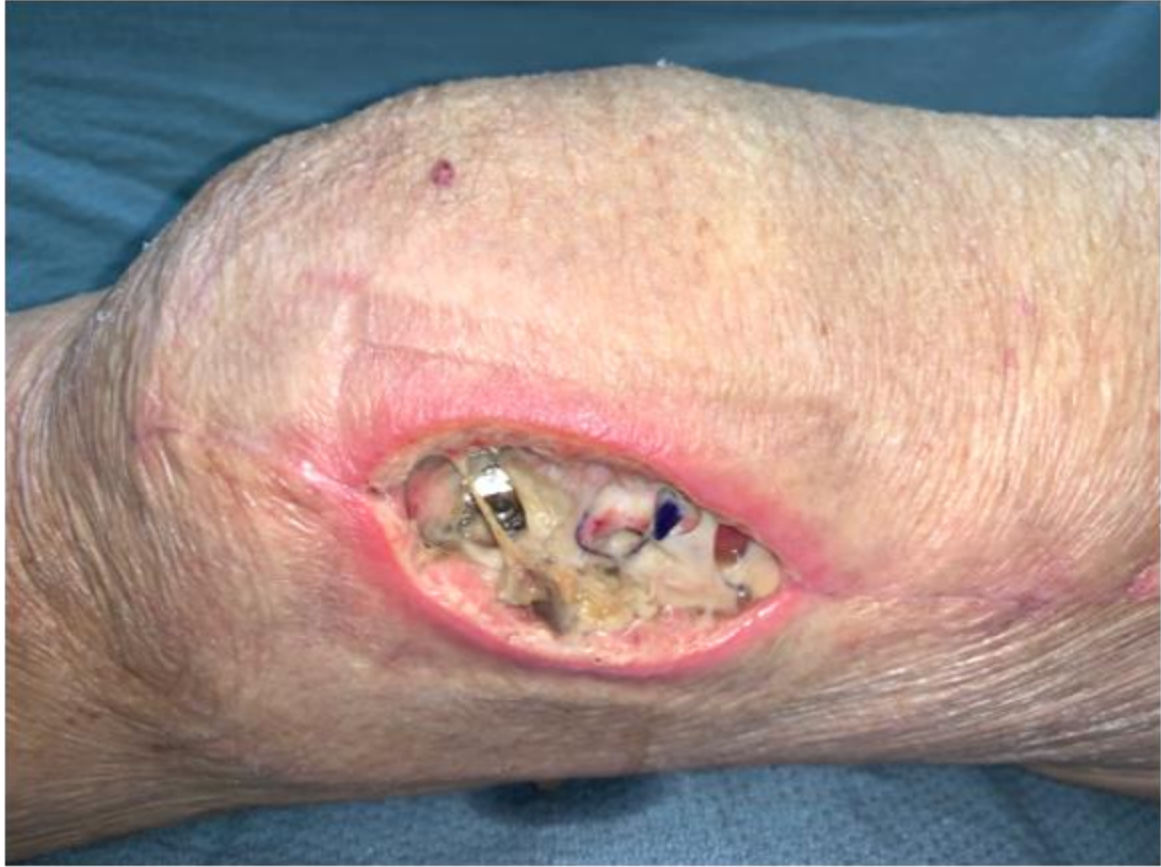Non-Healing Surgical Wound, Knee (Day 0)



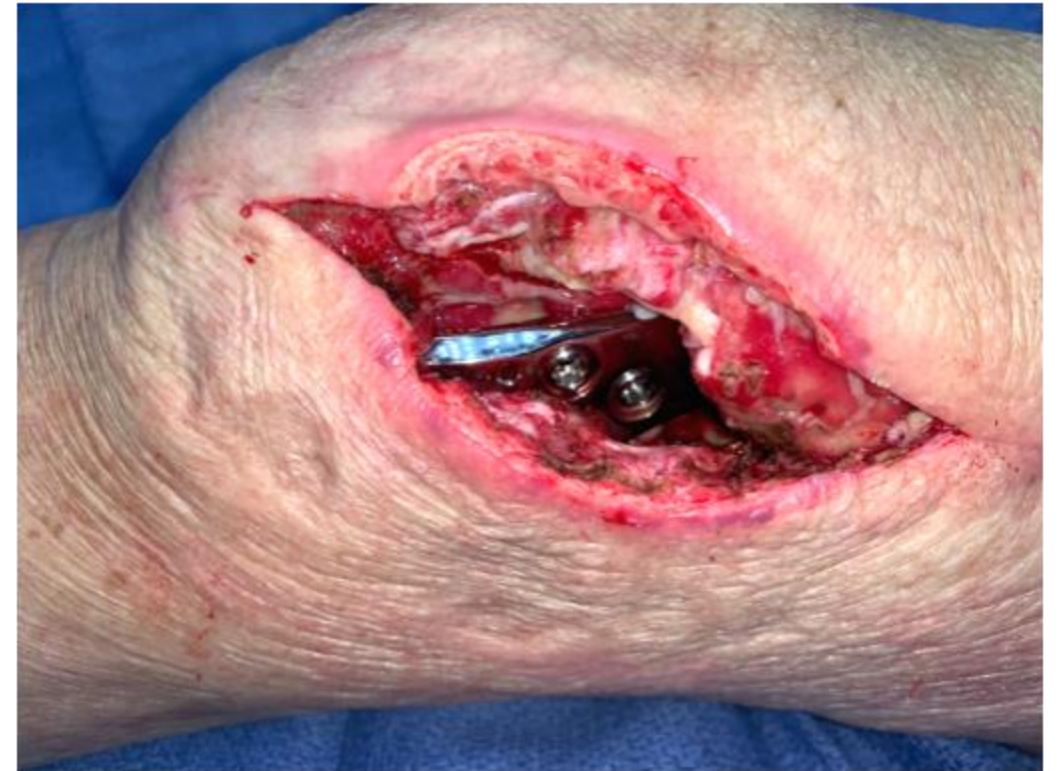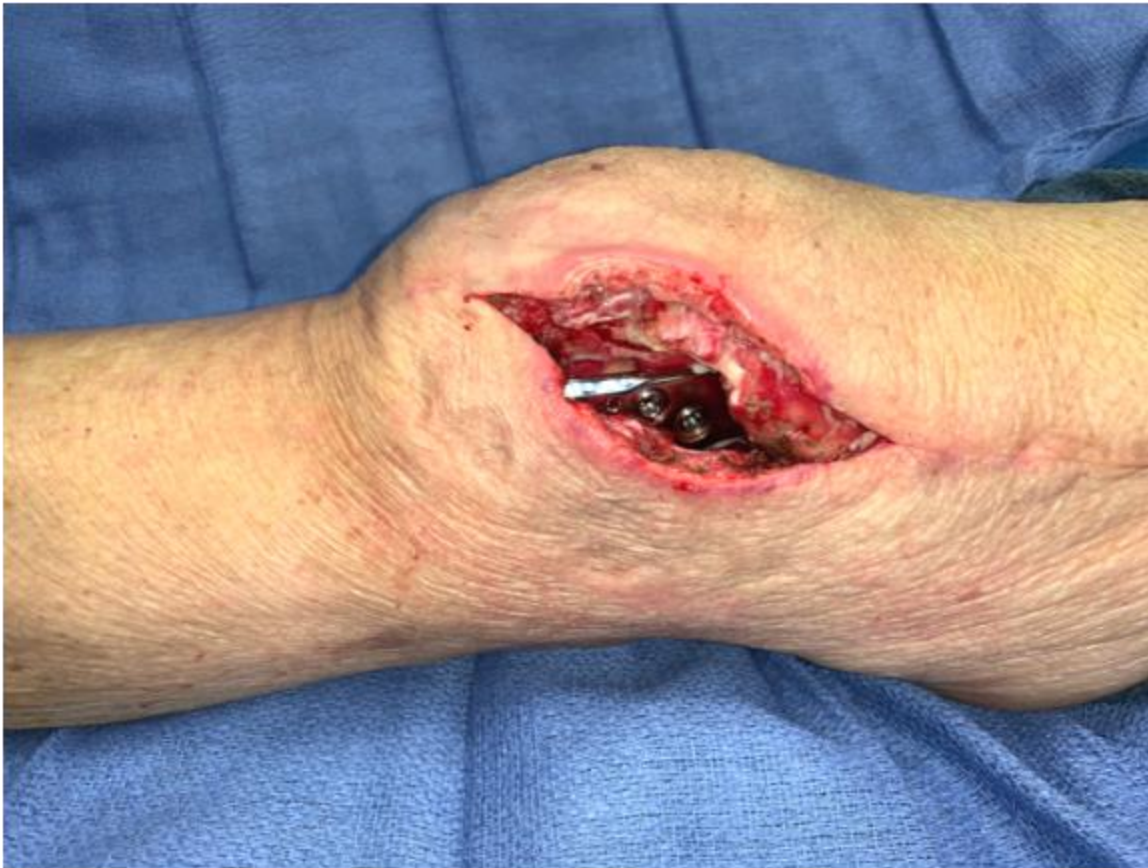Non-Healing Surgical Wound, Knee (Day 0)



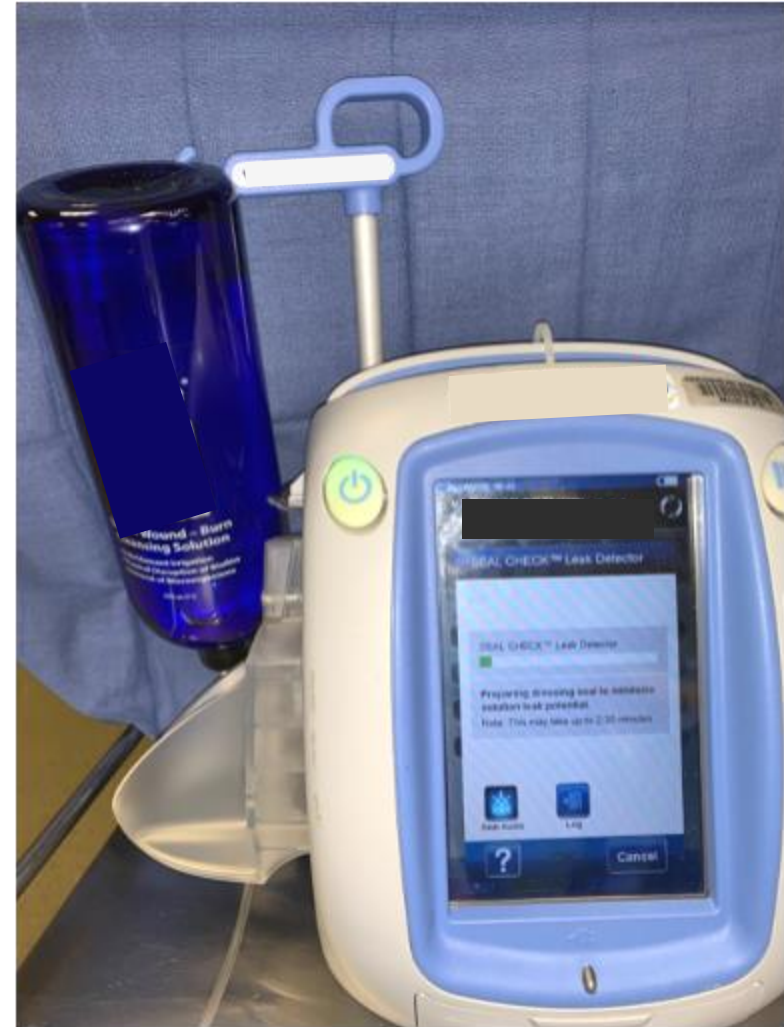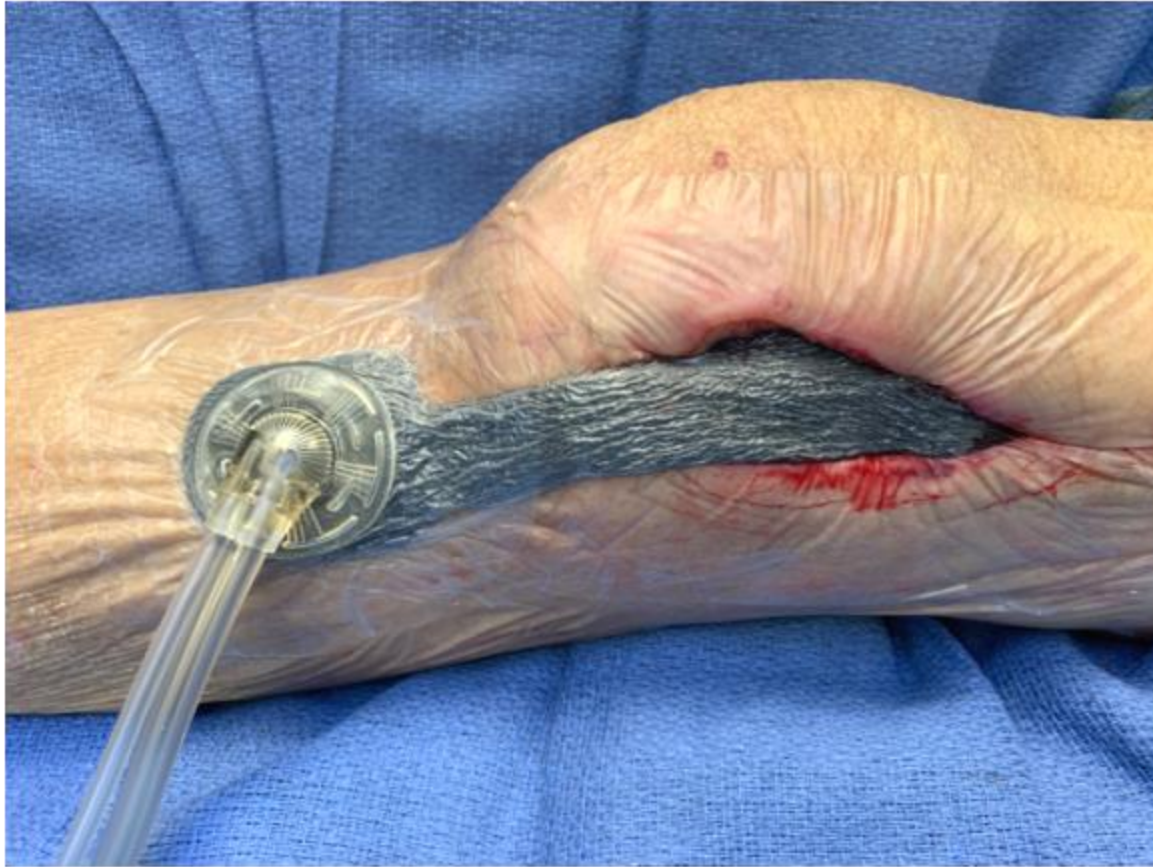
Non-Healing Surgical Wound, Knee (Day 1)



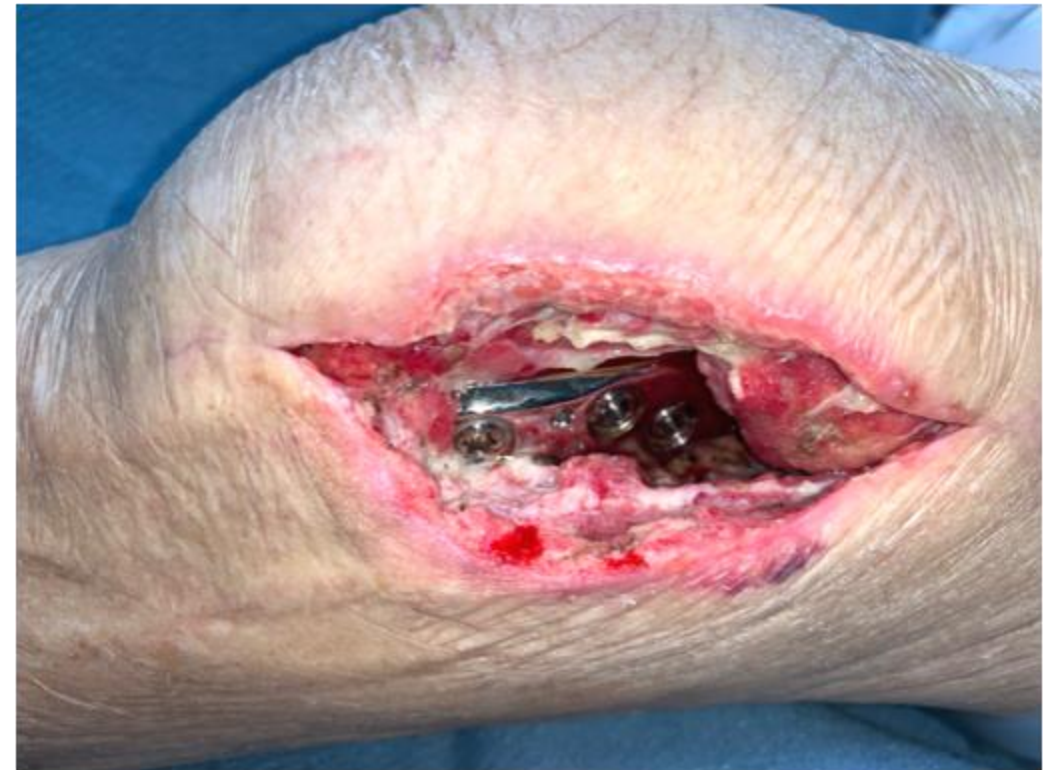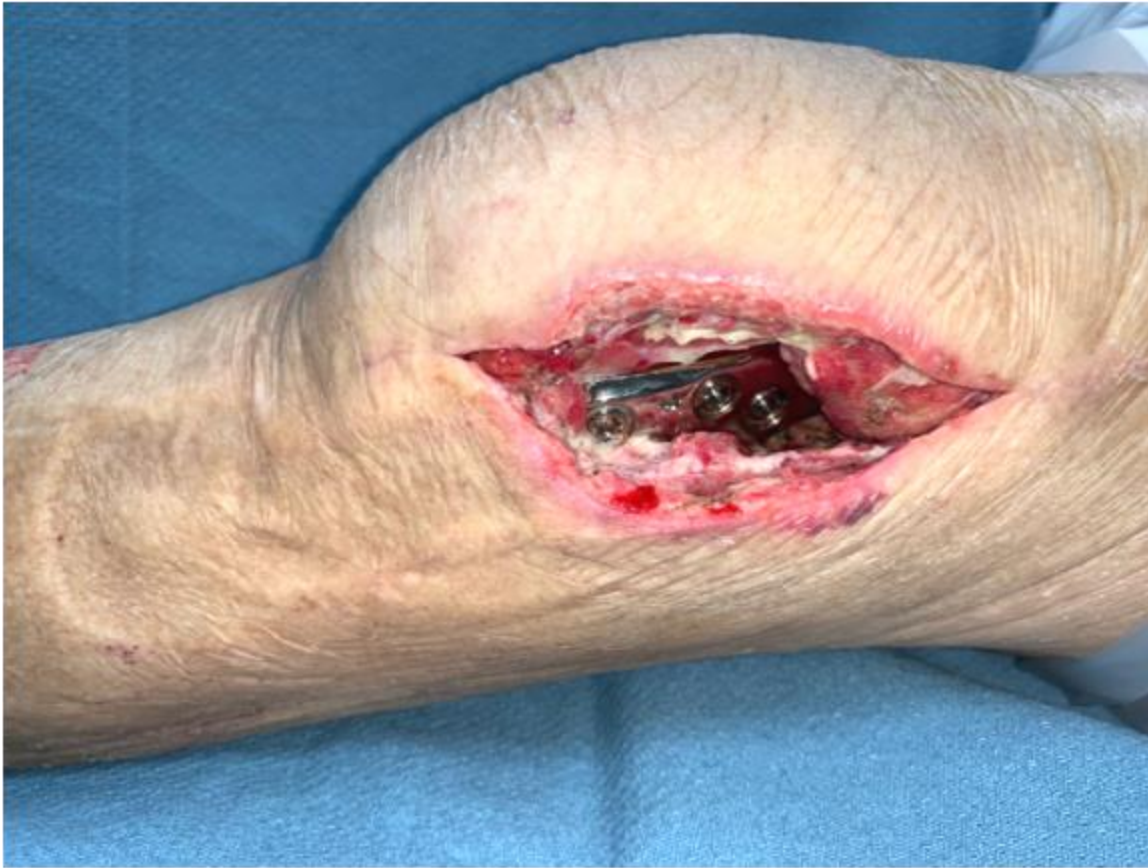Non-Healing Surgical Wound, Knee (Day 1)



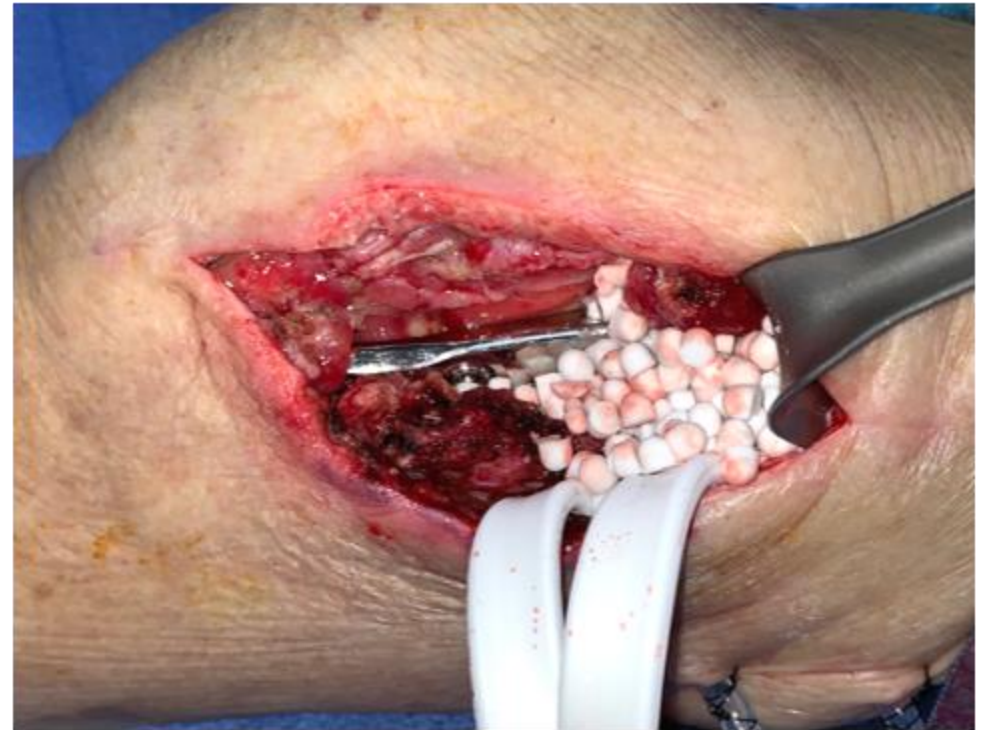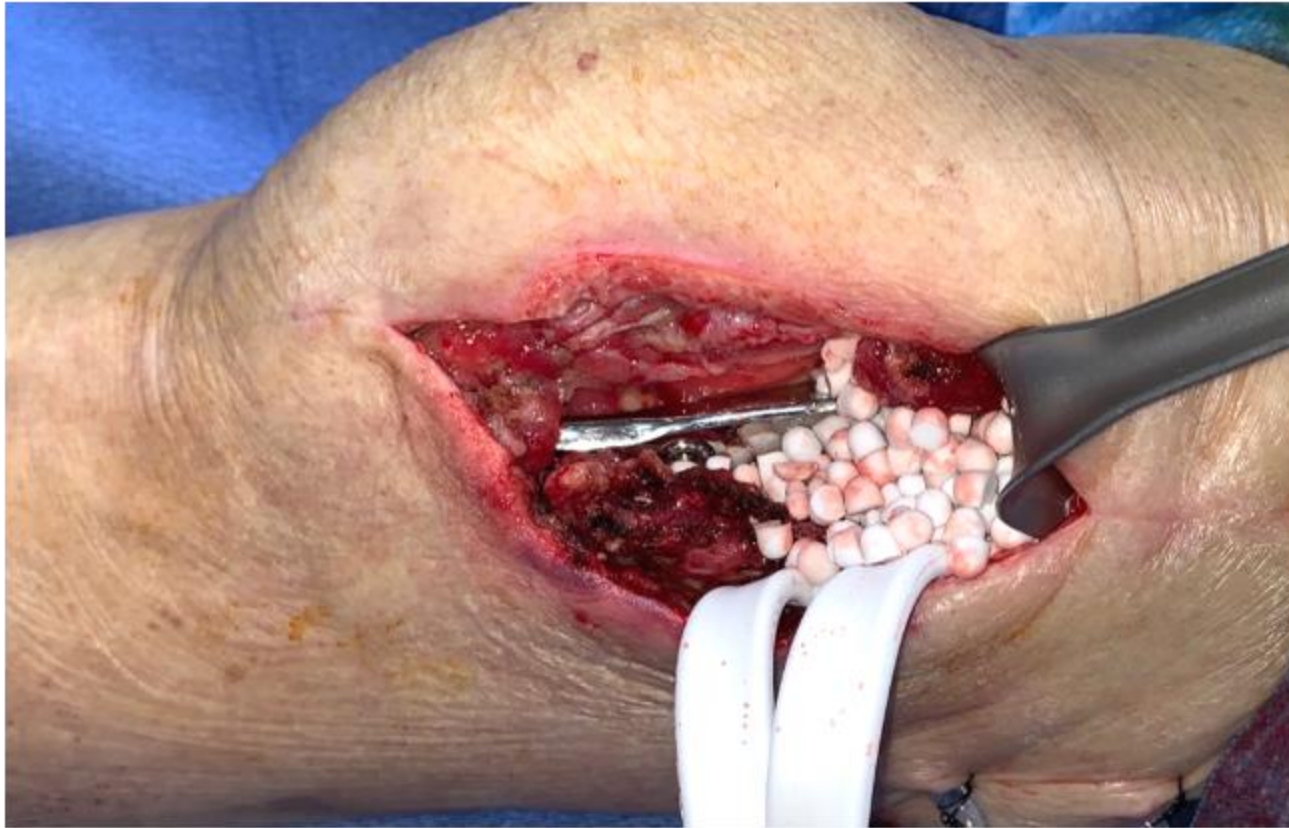Non-Healing Surgical Wound, Knee (Day 1)



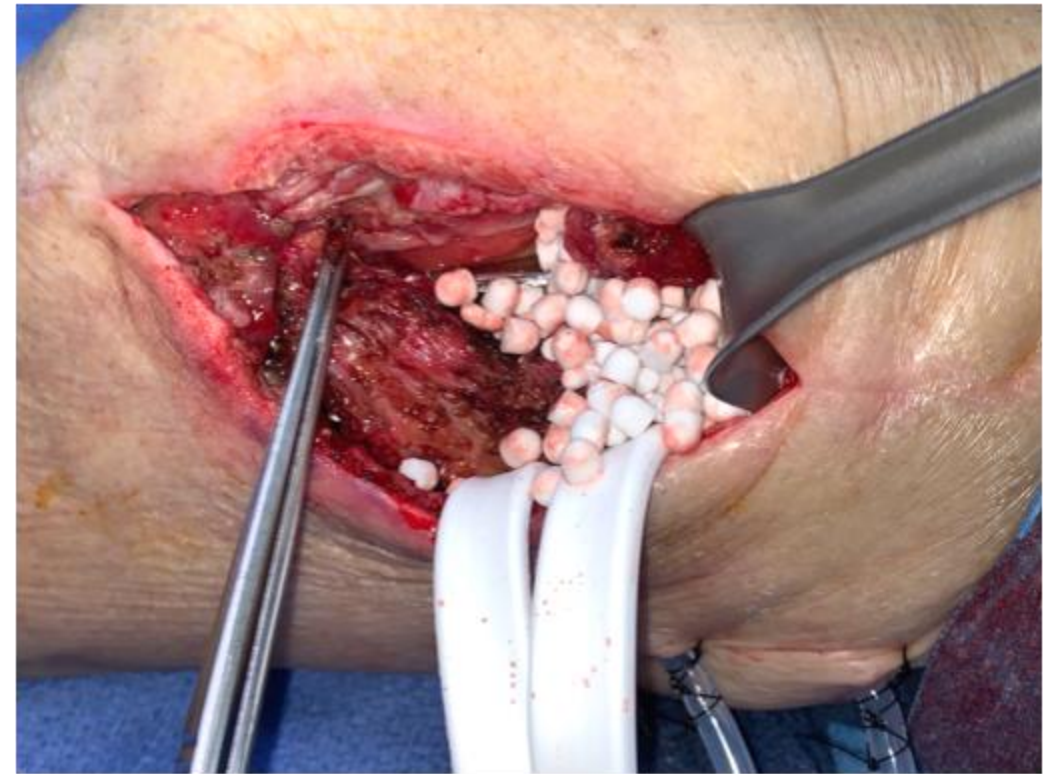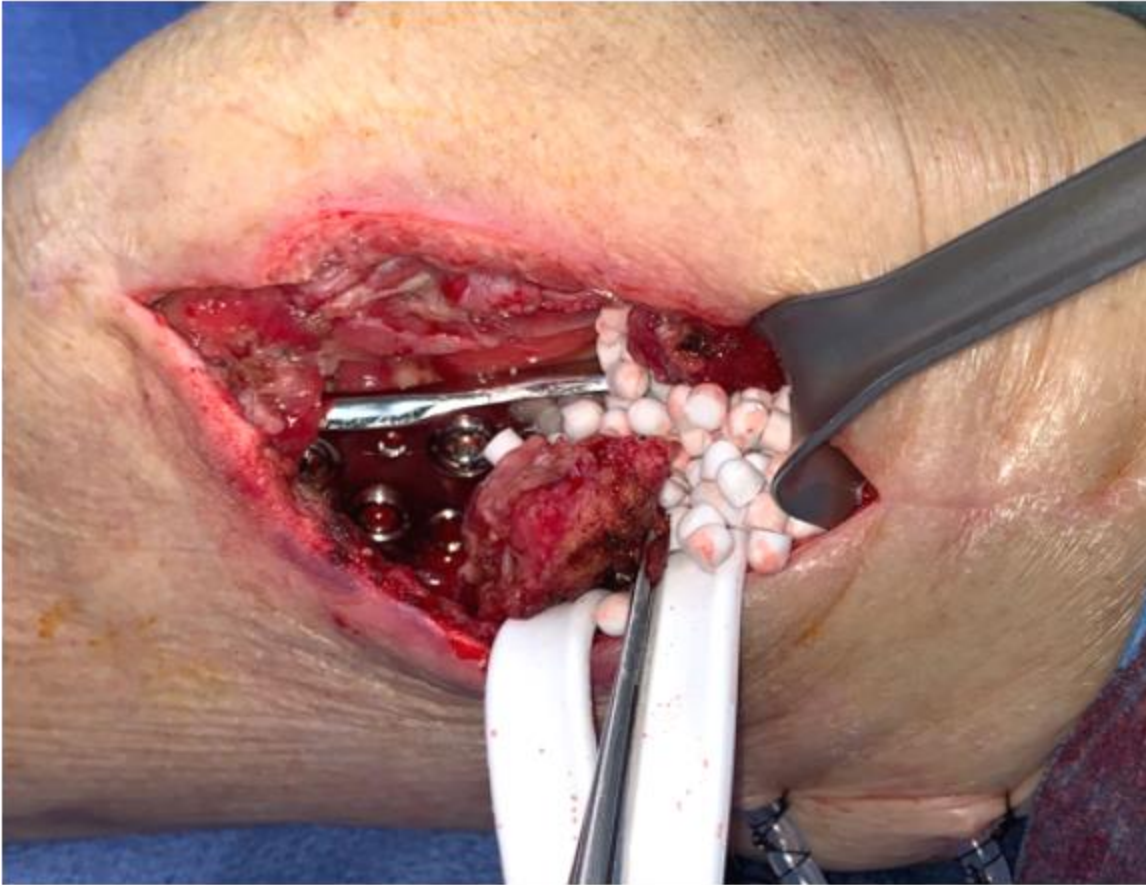Non-Healing Surgical Wound, Knee (Day 4)



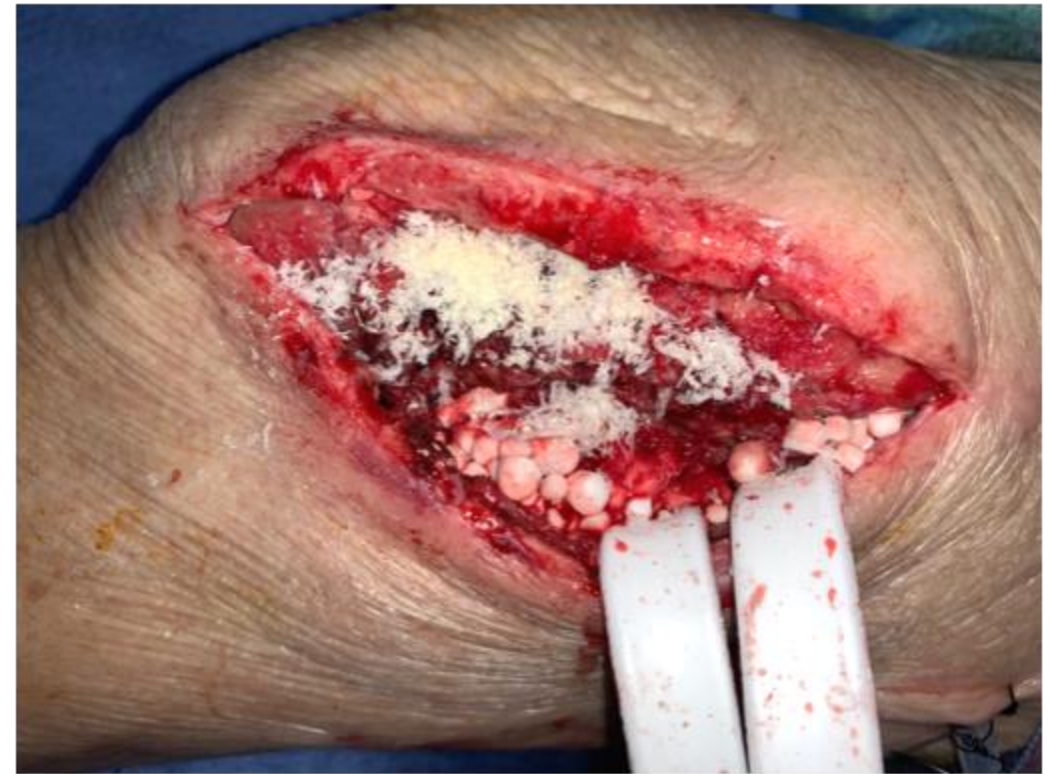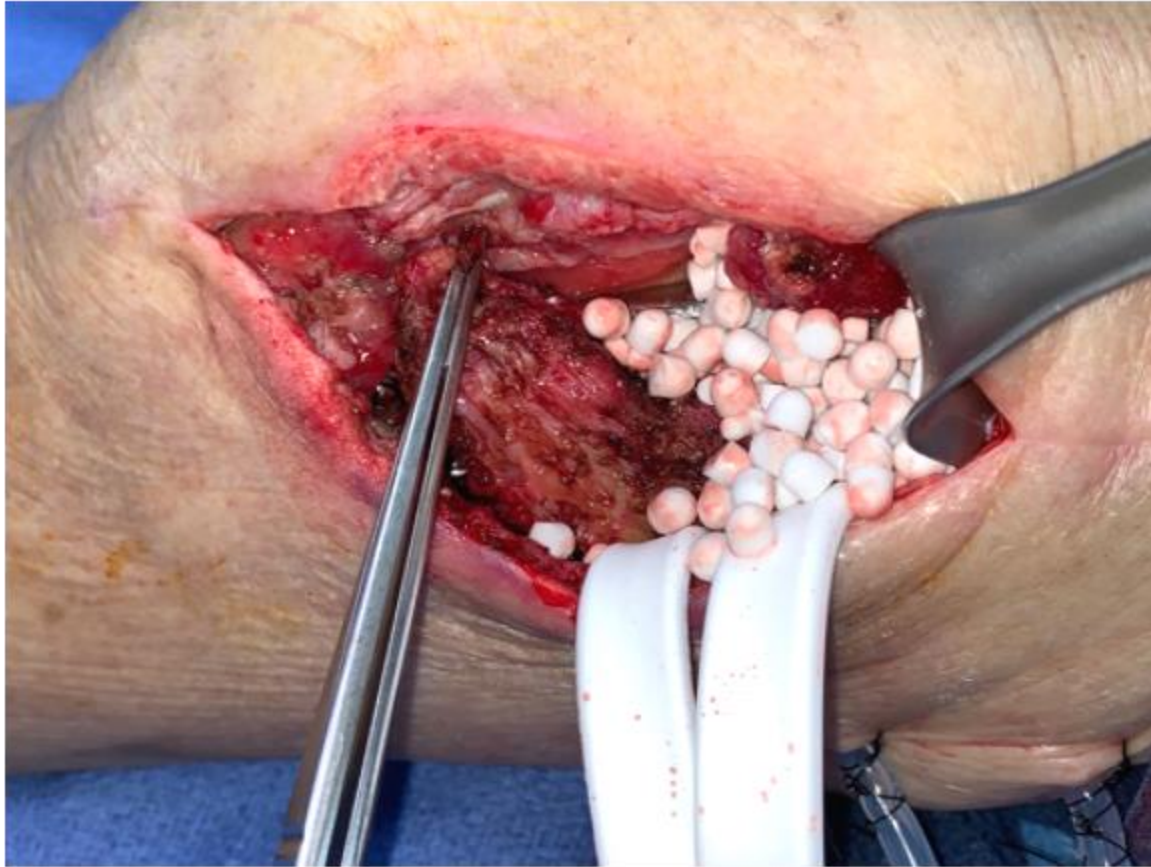Non-Healing Surgical Wound, Knee (Day 4)



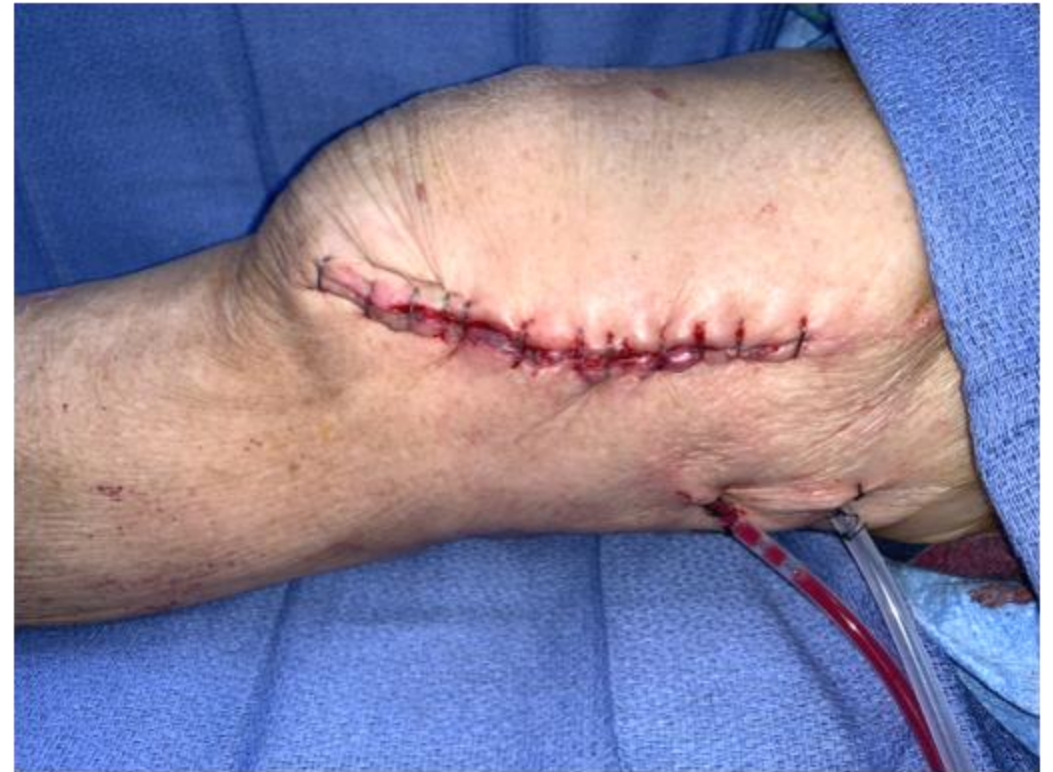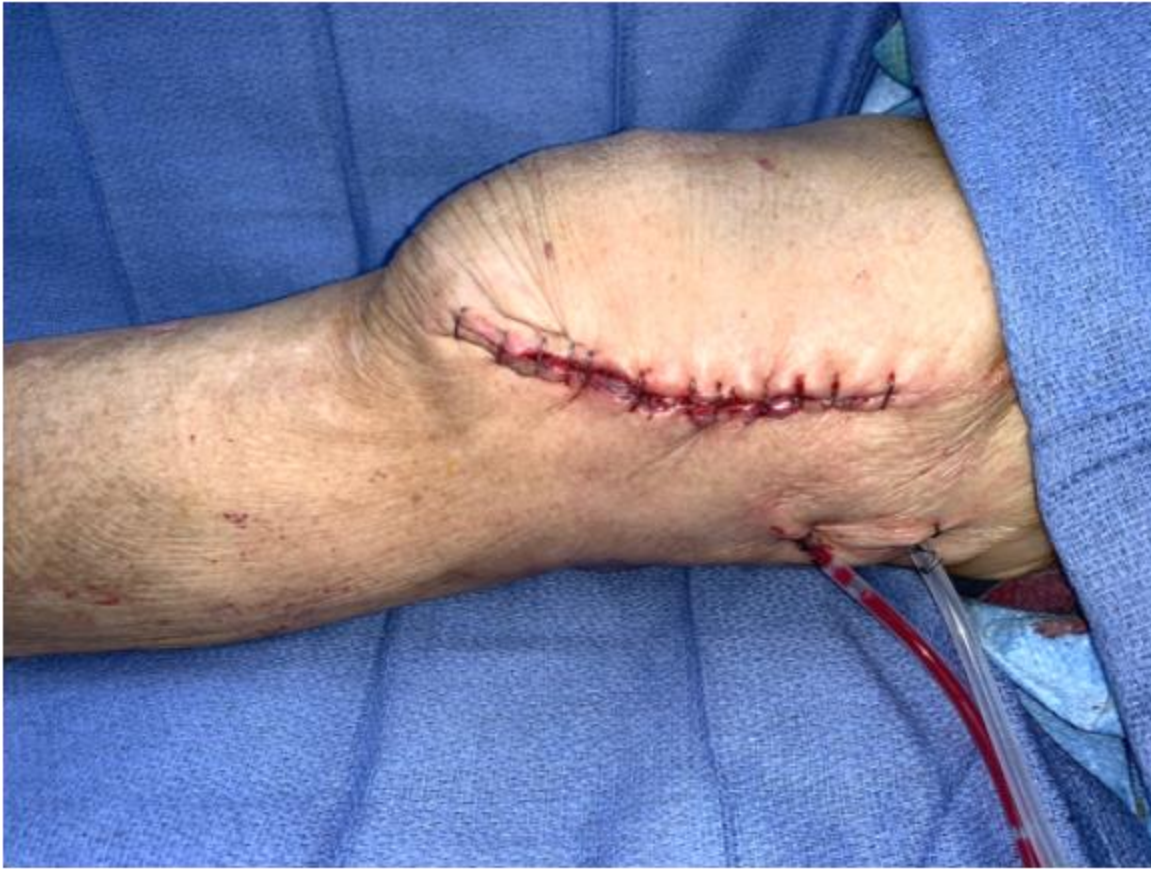Non-Healing Surgical Wound, Knee (Day 4)



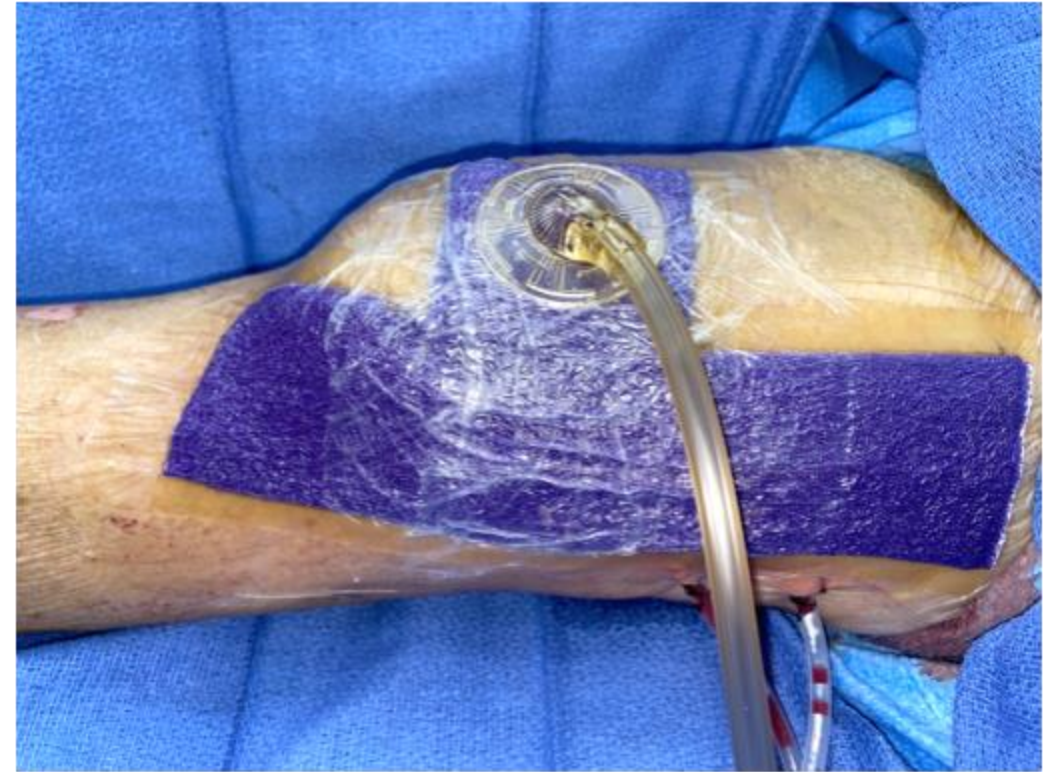
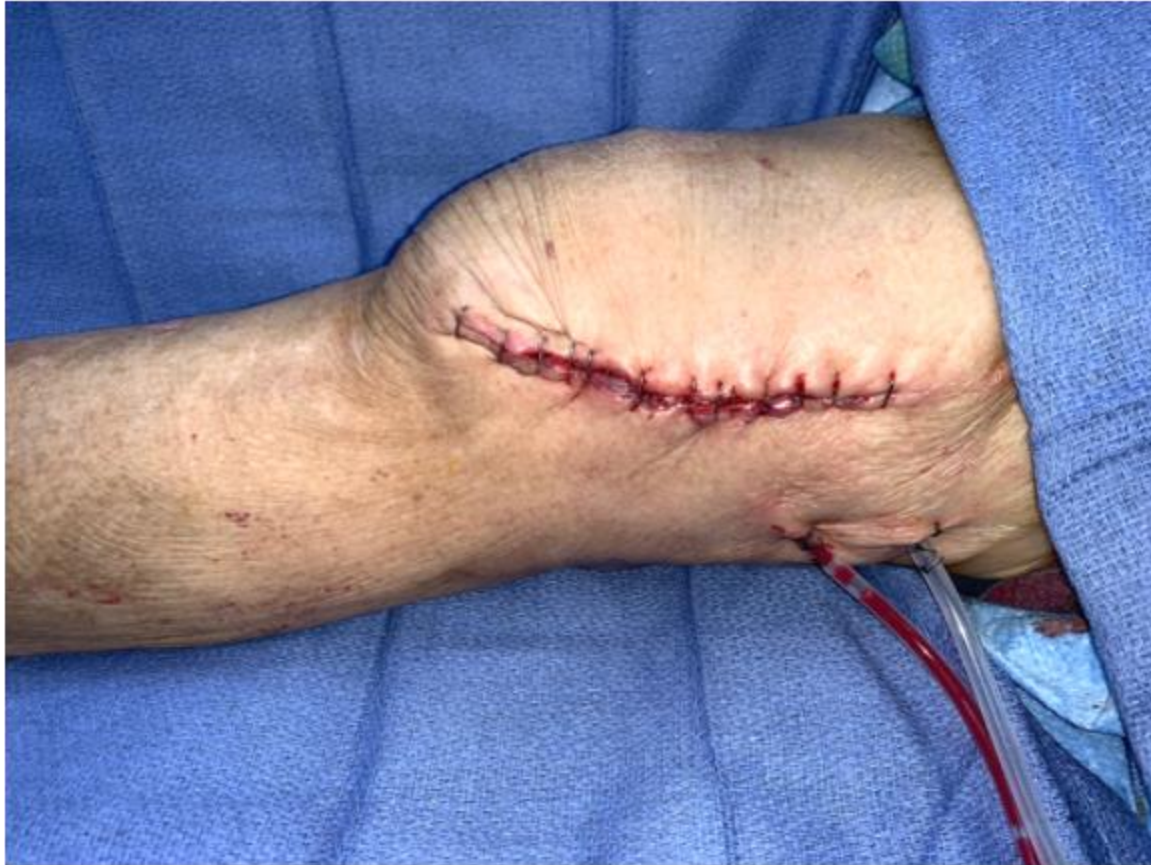Non-Healing Surgical Wound, Knee (Day 4)



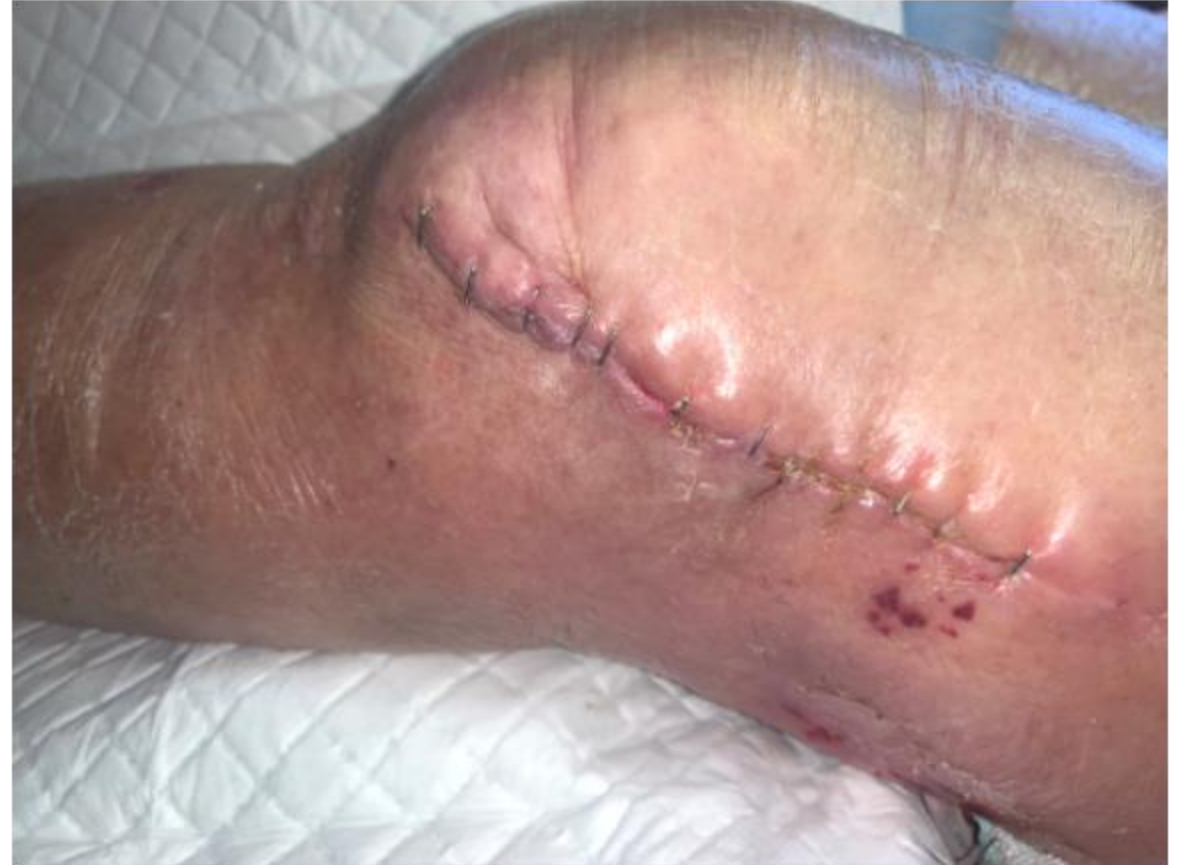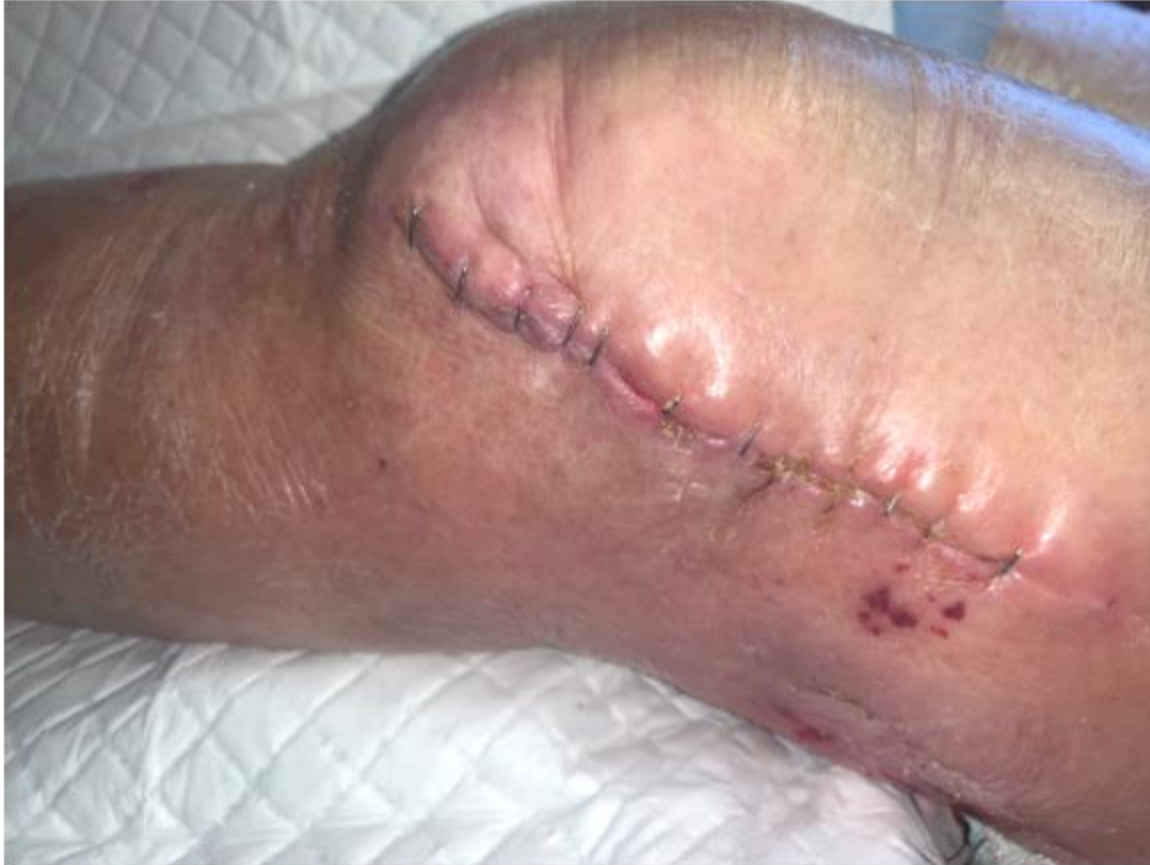Non-Healing Surgical Wound, Knee (Day 4)



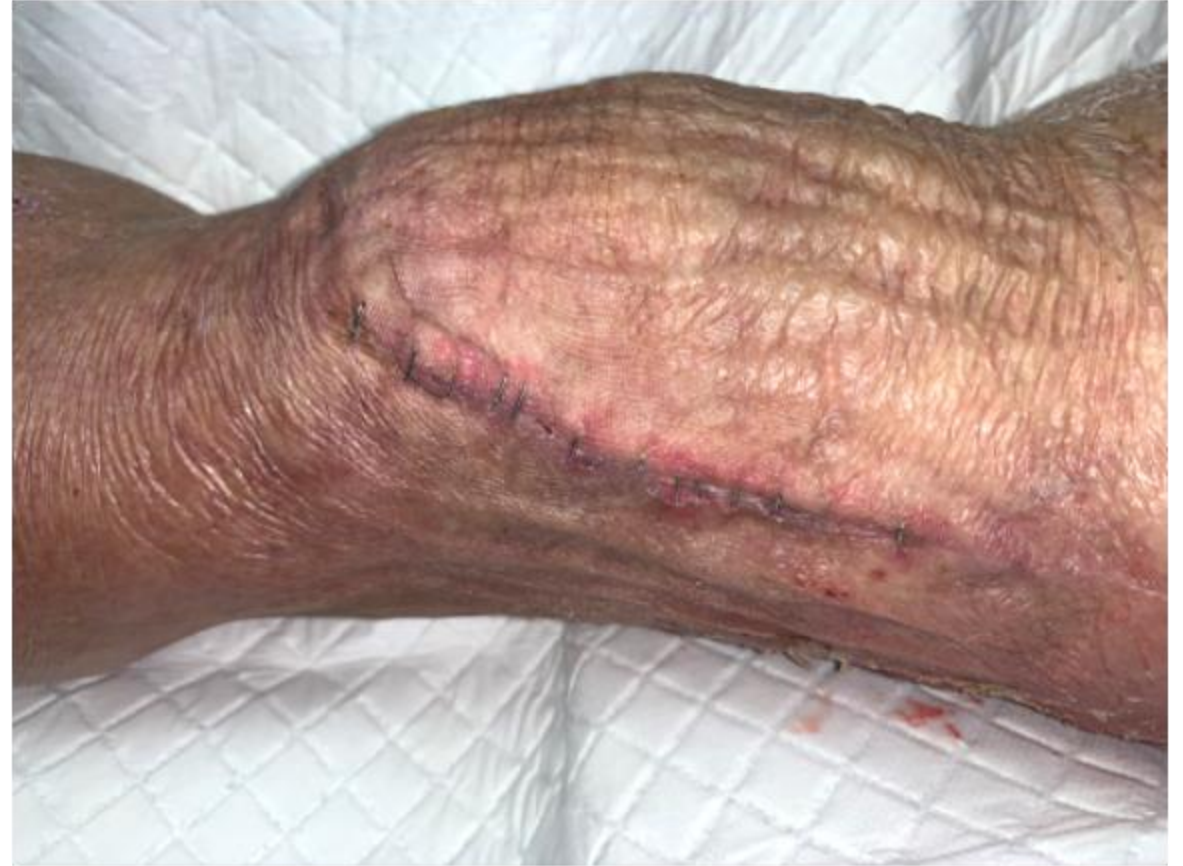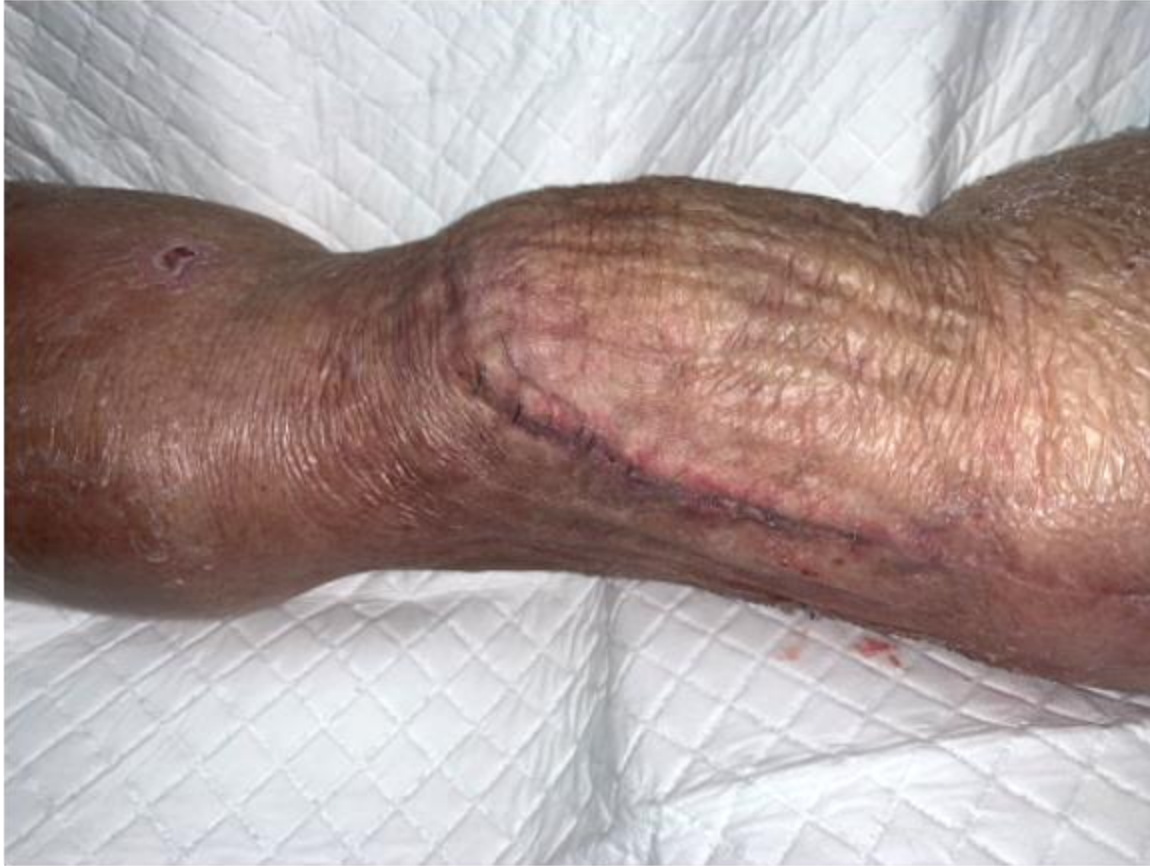Non-Healing Surgical Wound, Knee (Day 4)



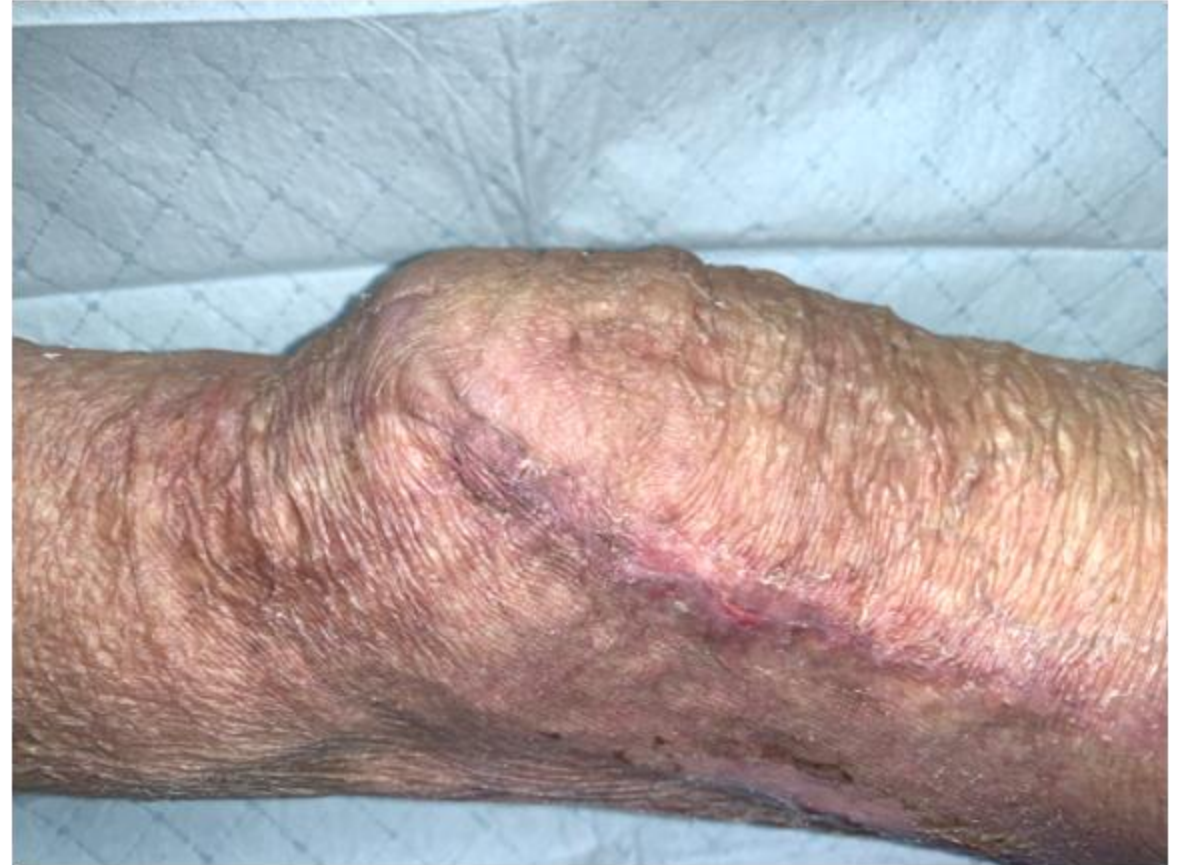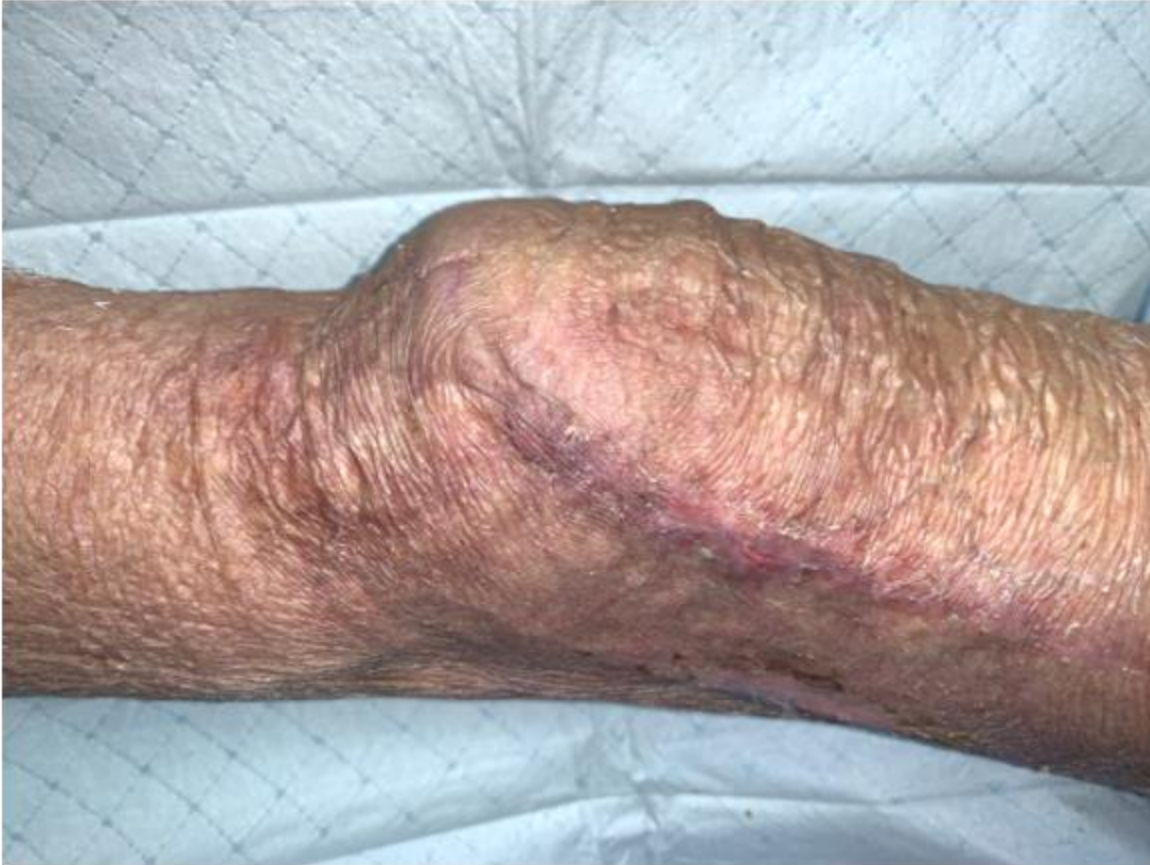Non-Healing Surgical Wound, Knee (Day 14)



Non-Healing Surgical Wound, Knee (Day 21)



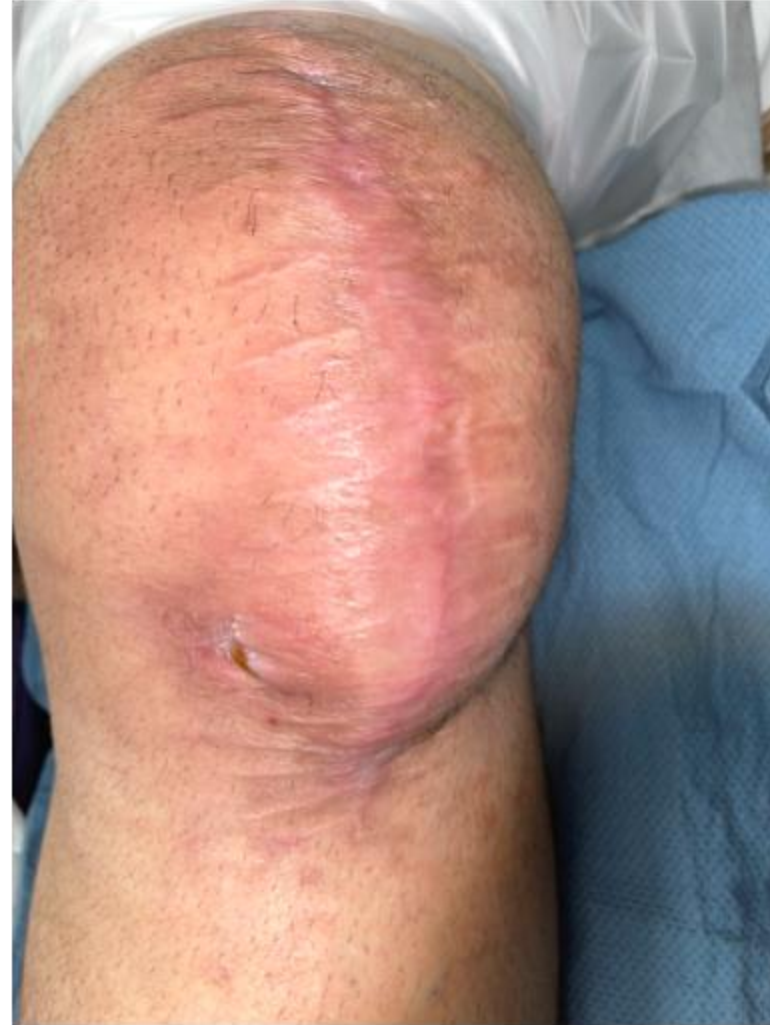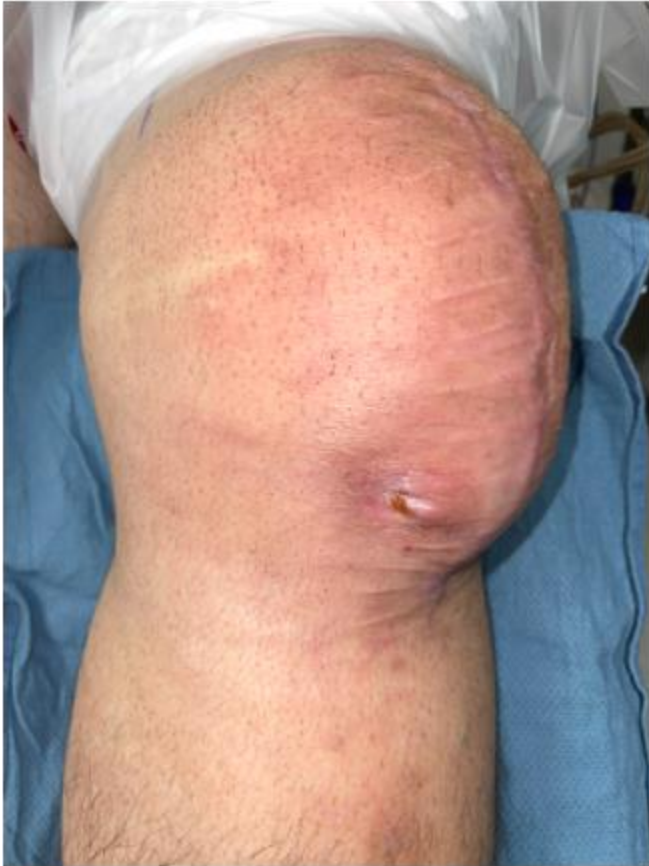Non-Healing Surgical Wound, Knee (Day 28)



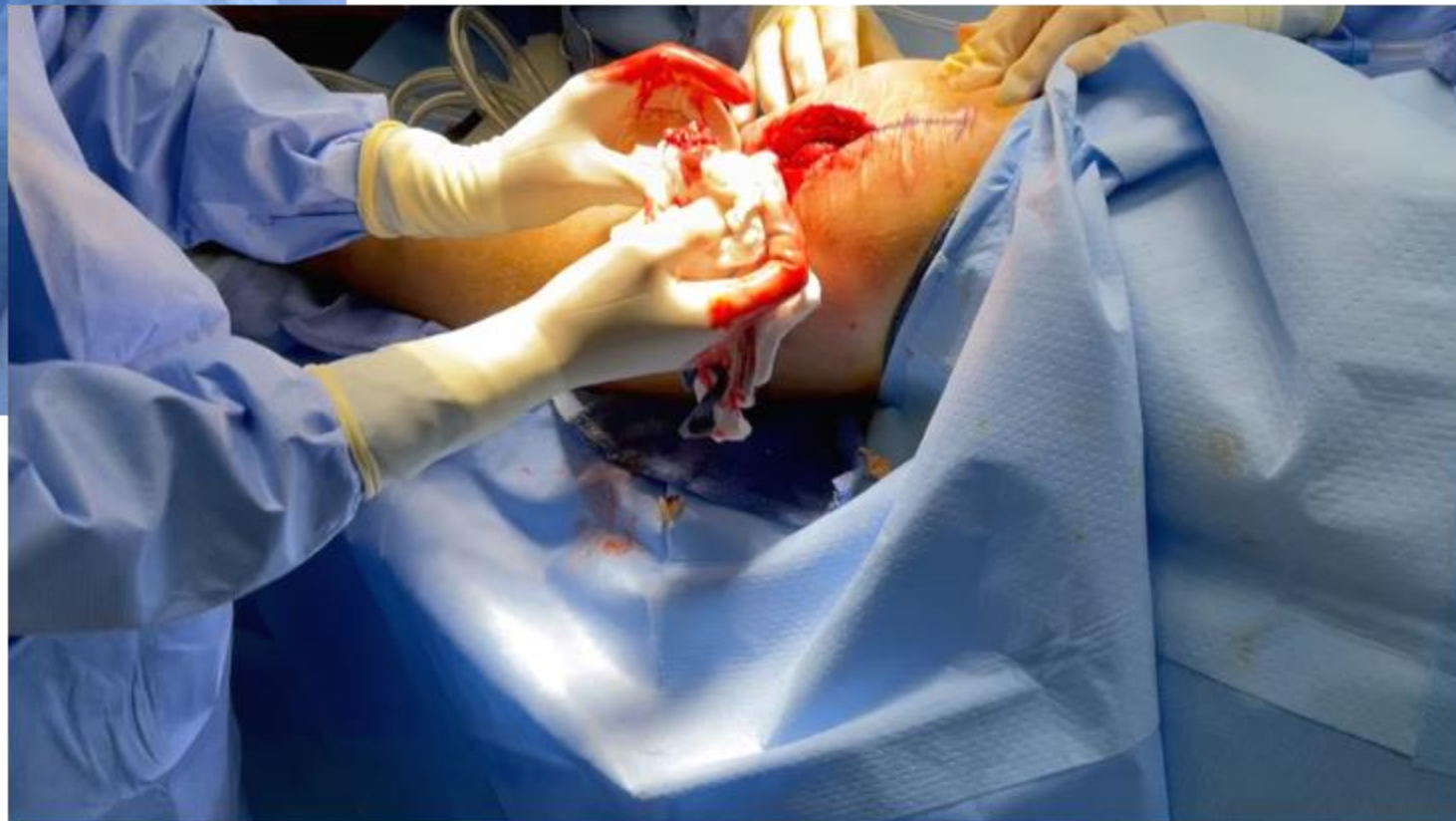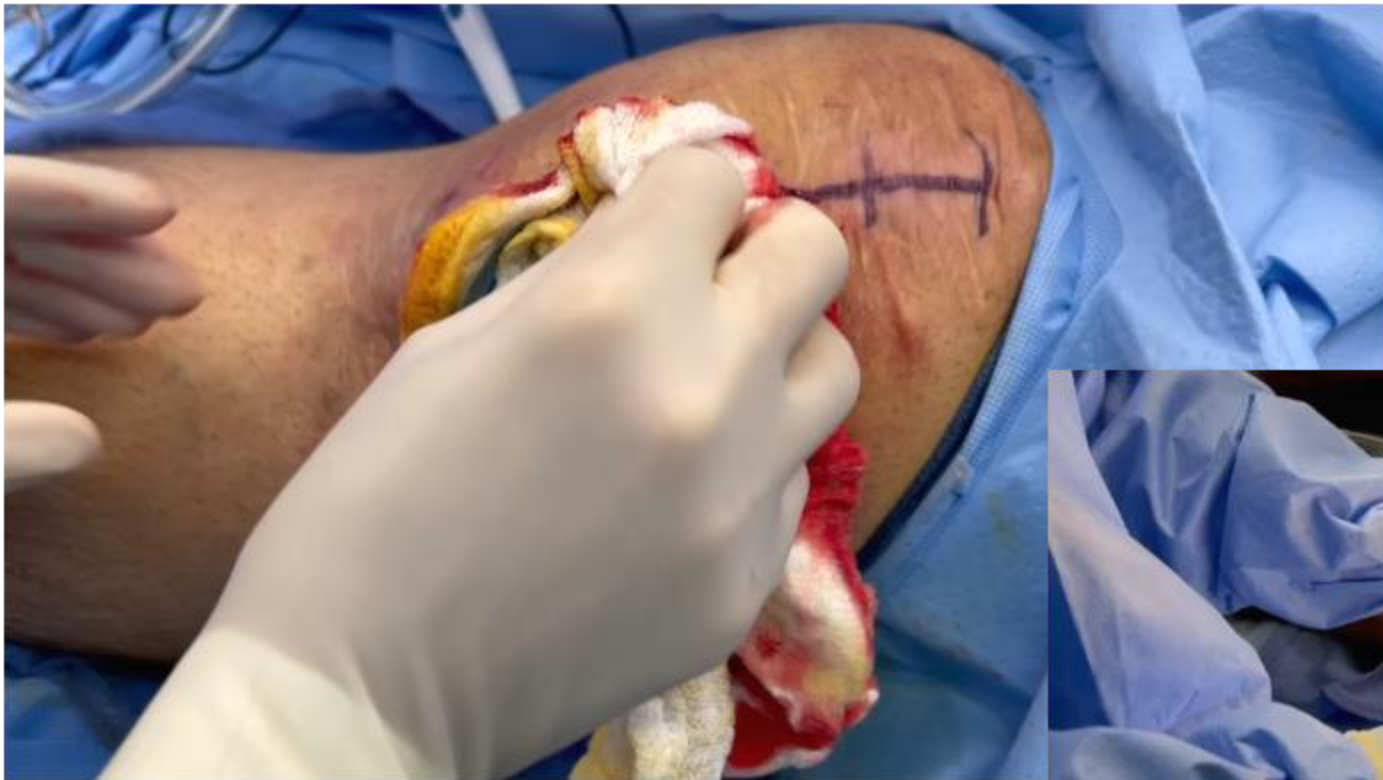Case Summary: Chronic Infection, Knee

- 47y Male presents with chronic infection, left knee s/p TKA 1 yr ago with washout and hardware removal 1 month later. 6 months later suffered patellar dislocation requiring surgical repositioning. Since then, he has had chronic drainage and pain.
- Medical history: HTN
- Treatment:
 - Taken to OR for excision non-viable tissue and phlegmon
 - Placental allograft placed to optimize healing
 - ciNPT initiated immediately following closure
 - sNPWT (single use, disposable) placed for additional NPT support

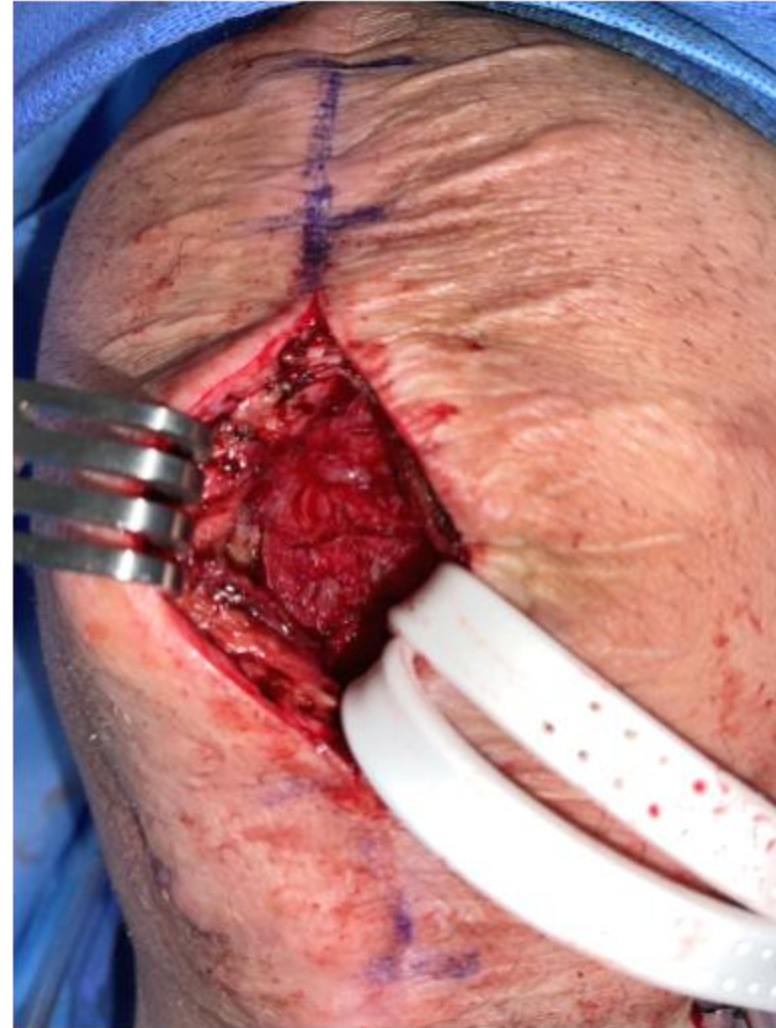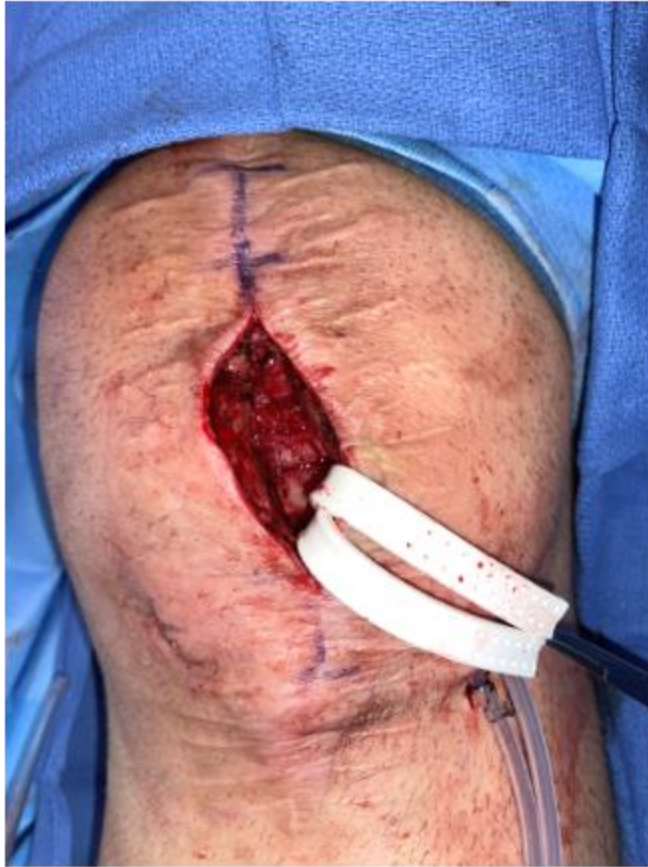Chronic Infection, Knee (Day 0)



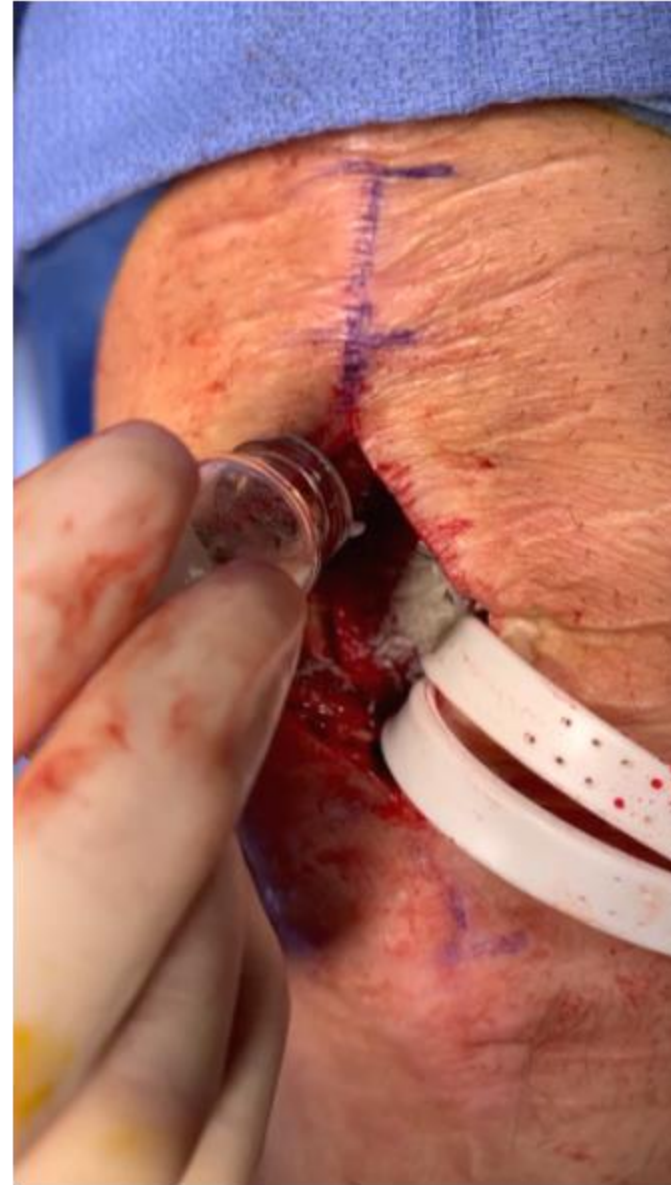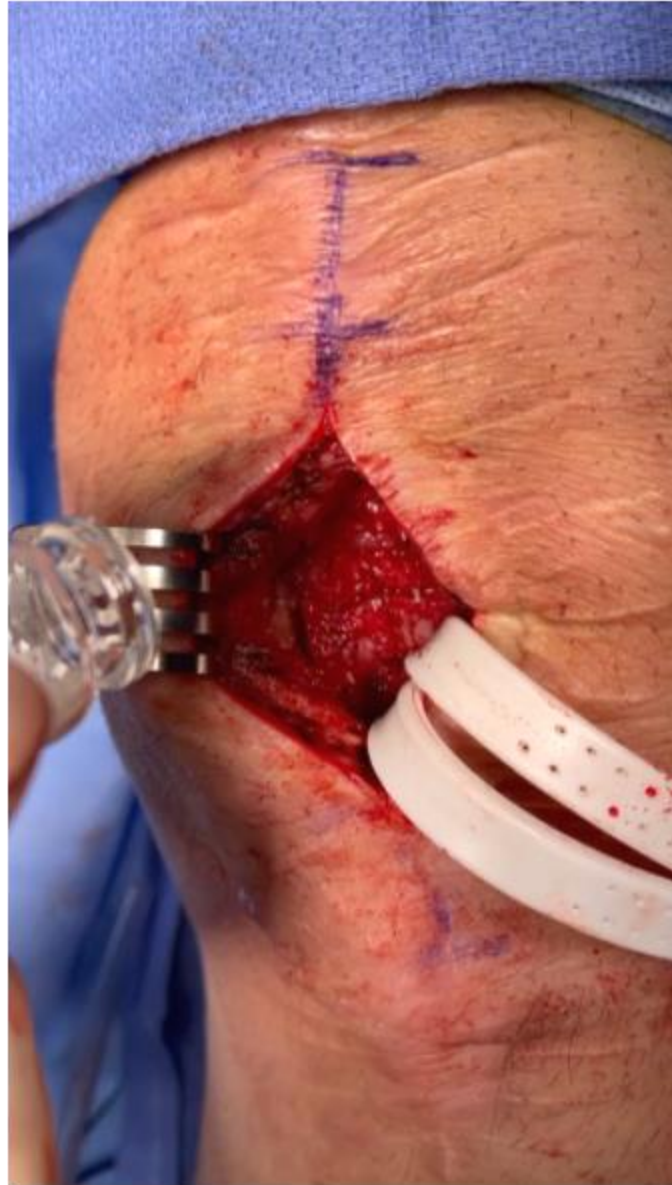Chronic Infection, Knee (Day 0)



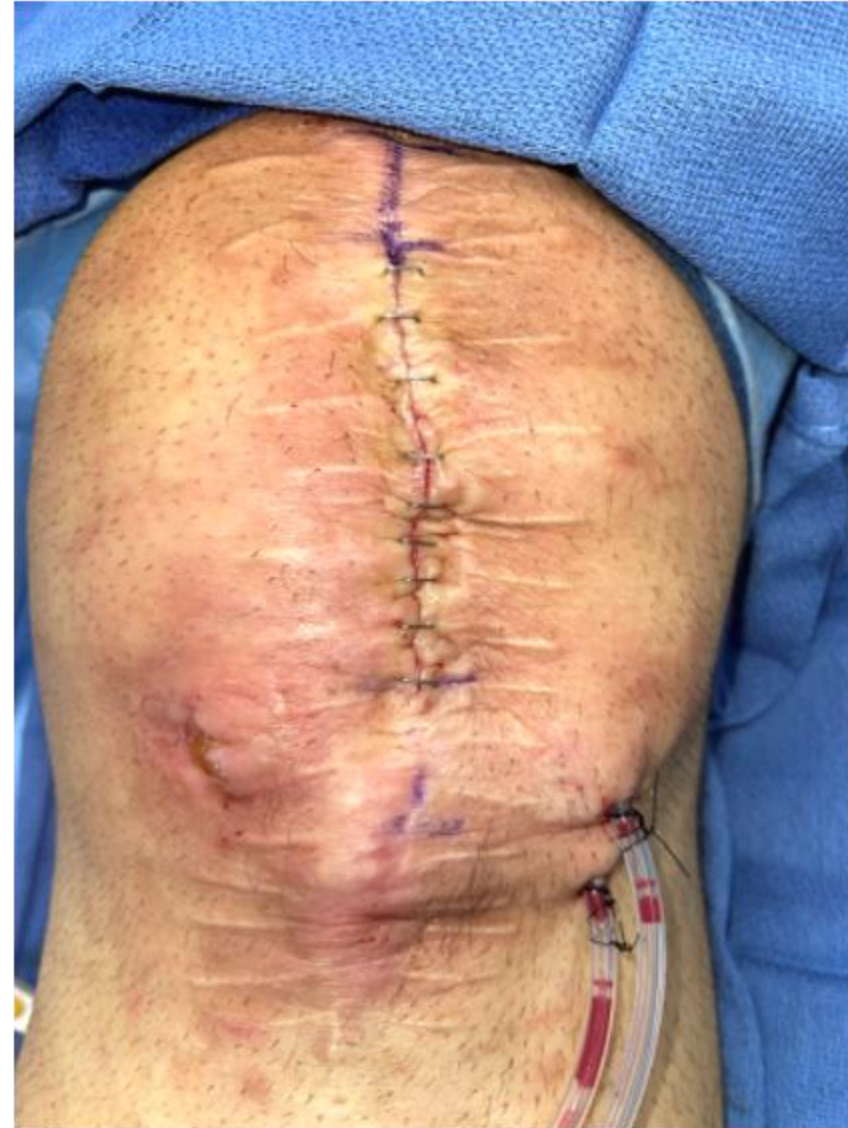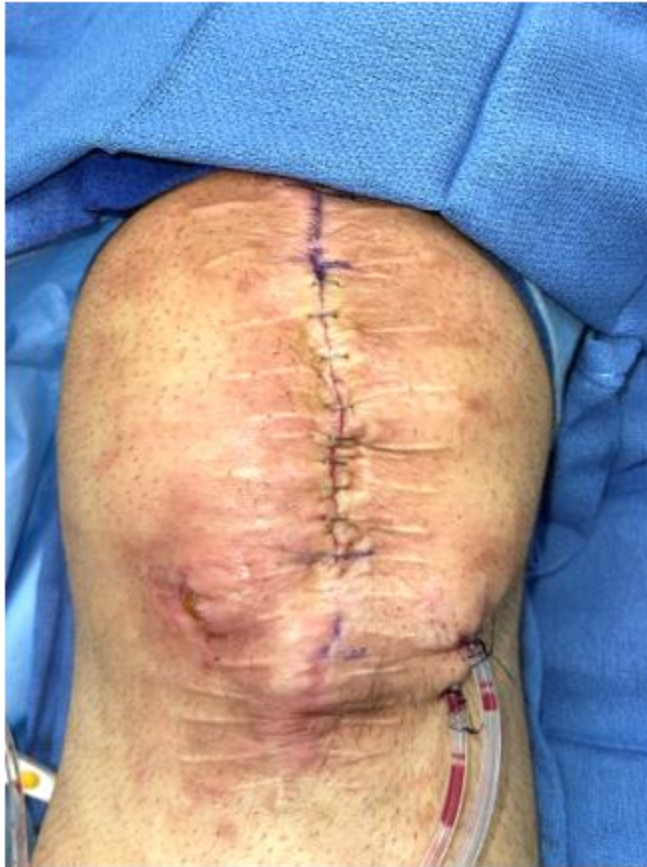Chronic Infection, Knee (Day 0)



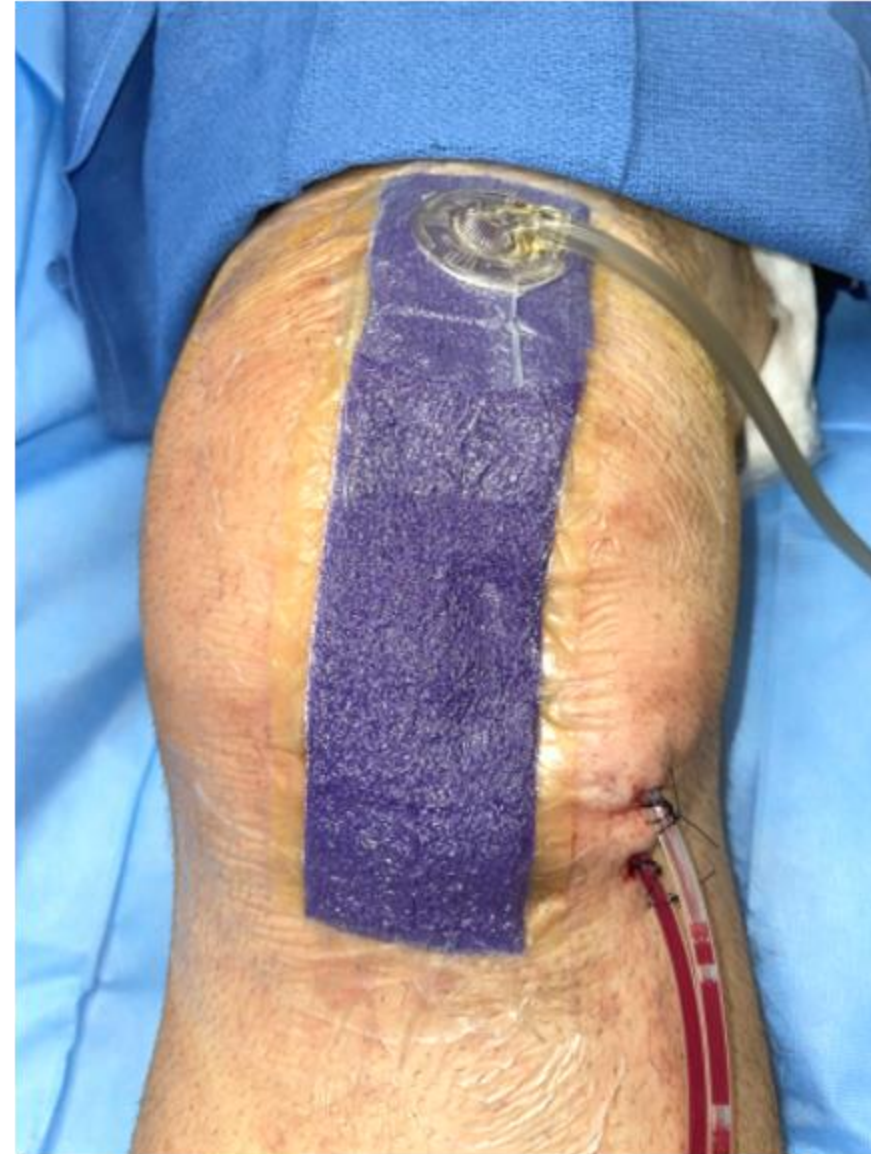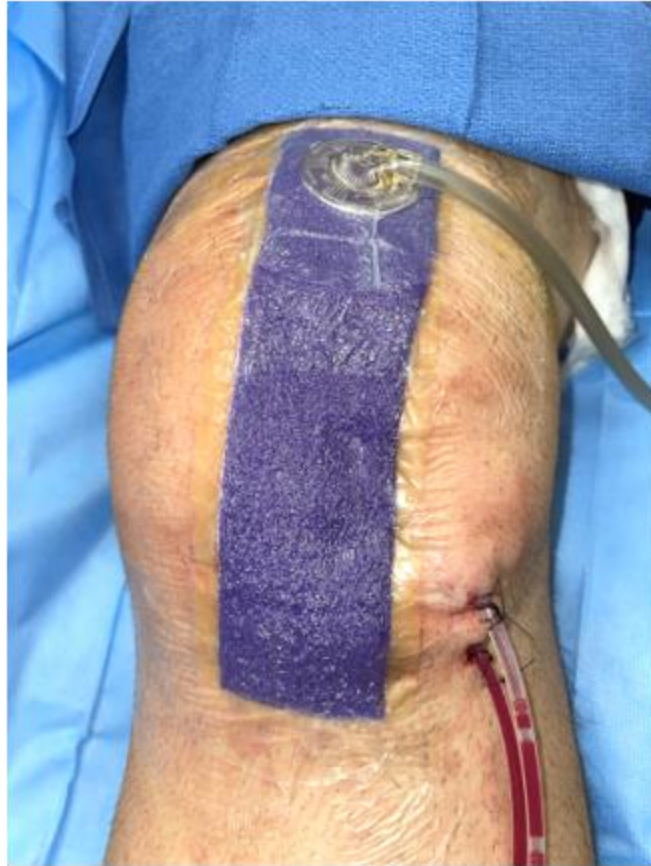Chronic Infection, Knee (Day 0)



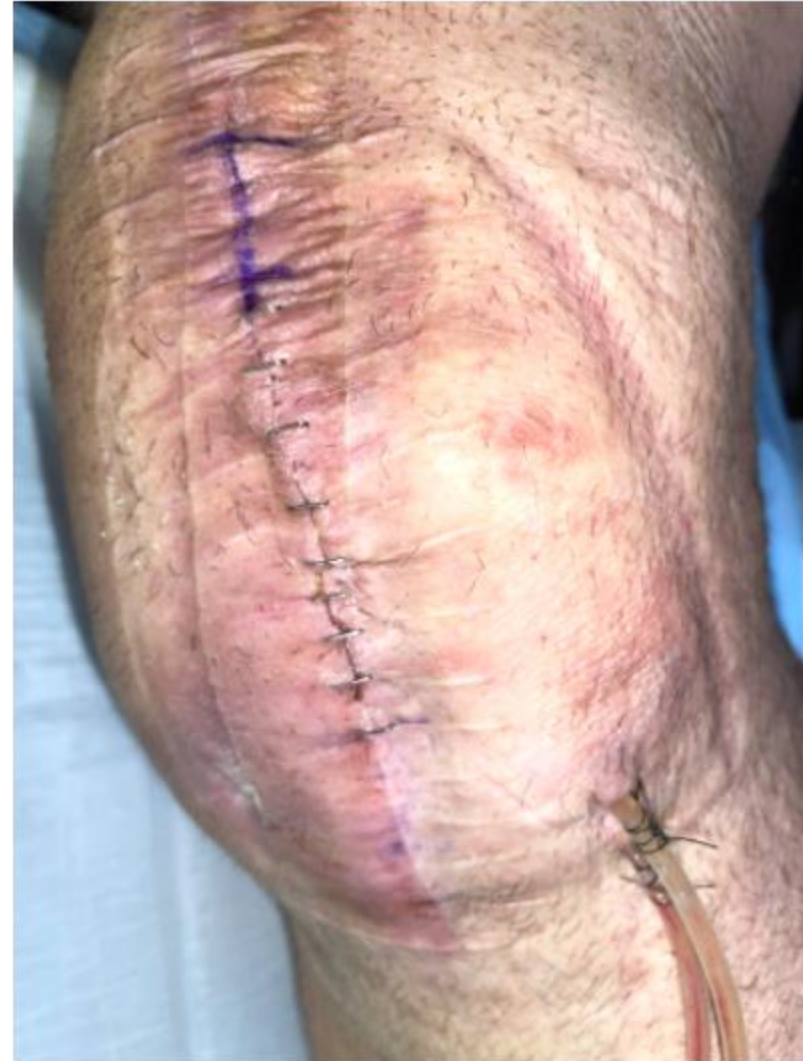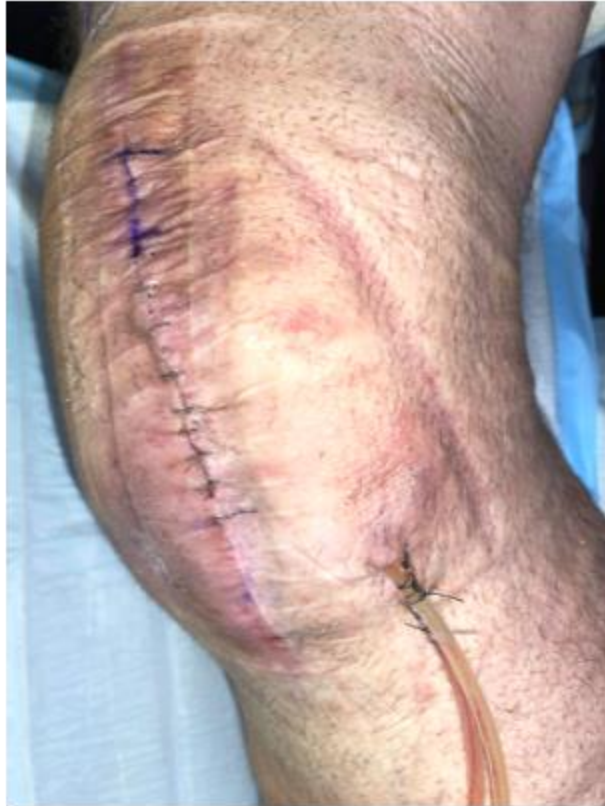Chronic Infection, Knee (Day 0)



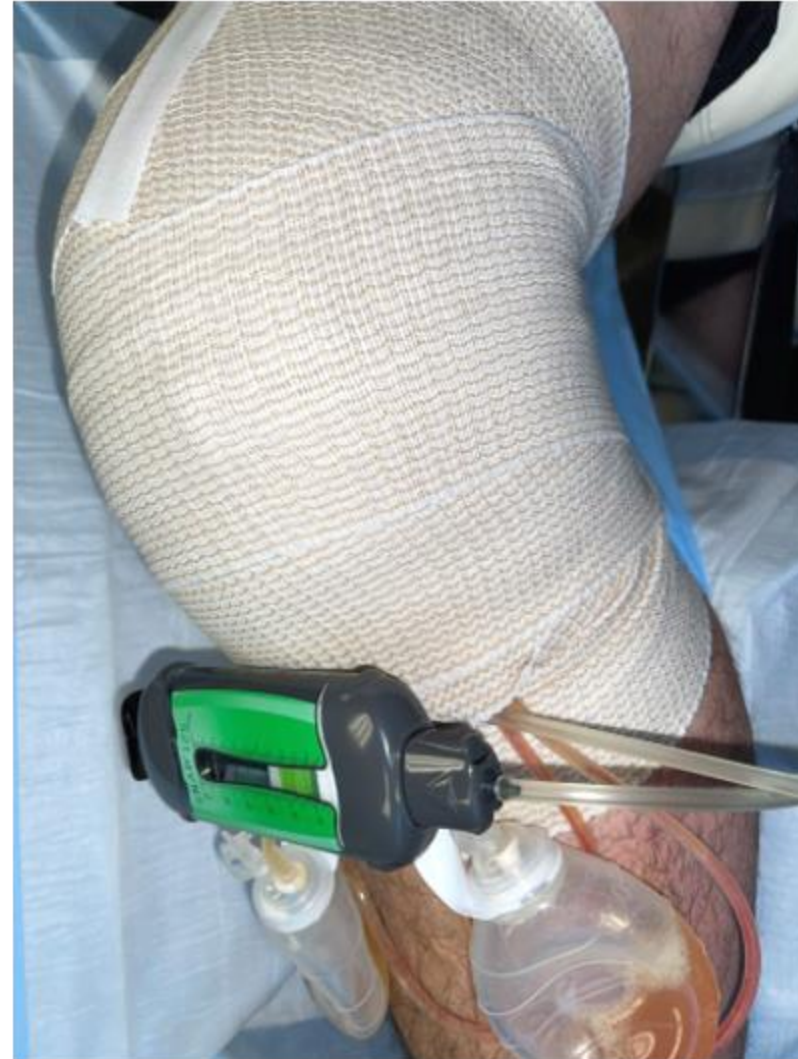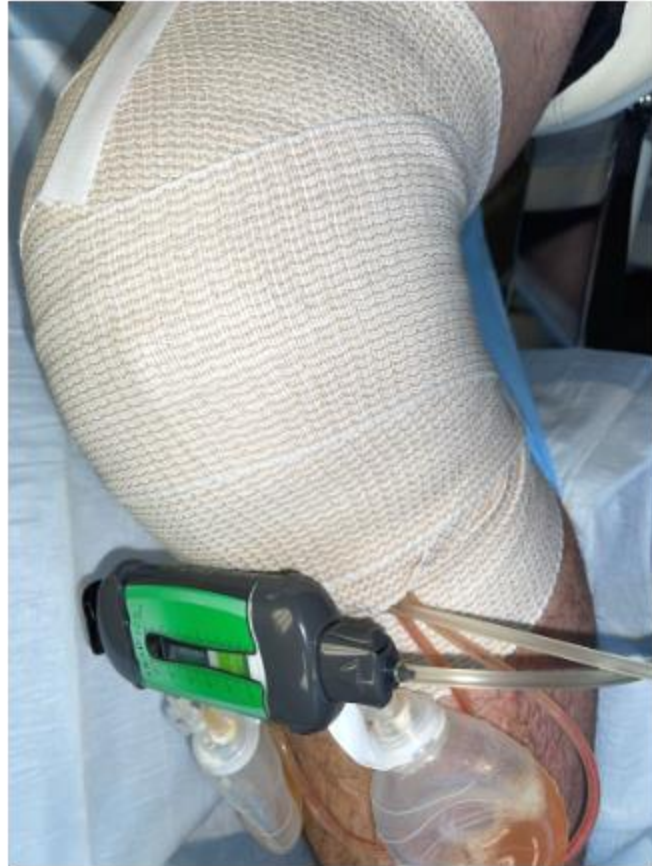Chronic Infection, Knee (Day 0)



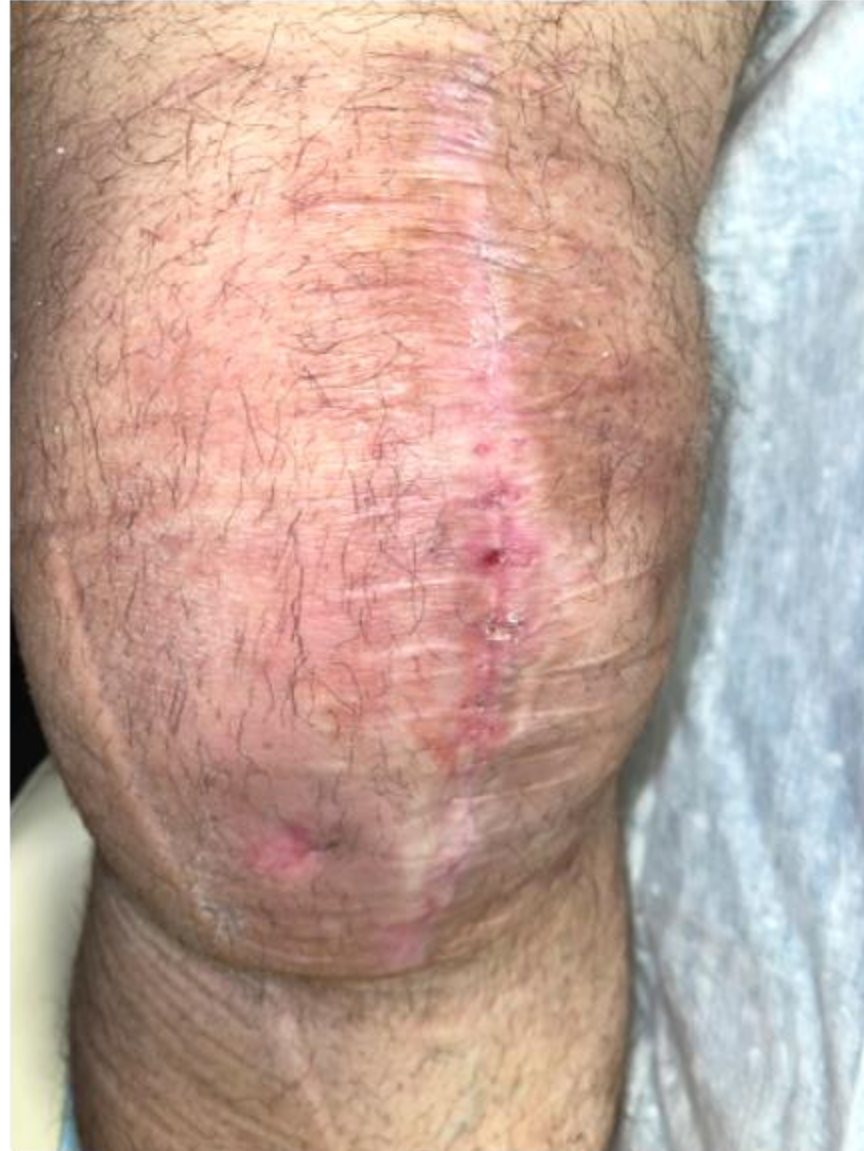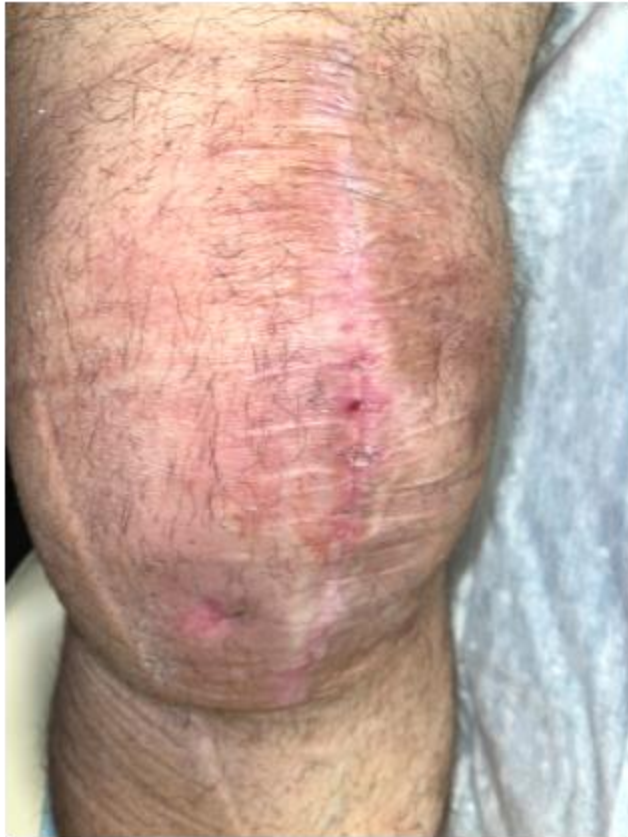Chronic Infection, Knee (Day 7)



Chronic Infection, Knee (Day 7)



Chronic Infection, Knee (6 Wks)





Polling Question

The negative pressure wound therapy (NPWT) technology chosen initially may include:

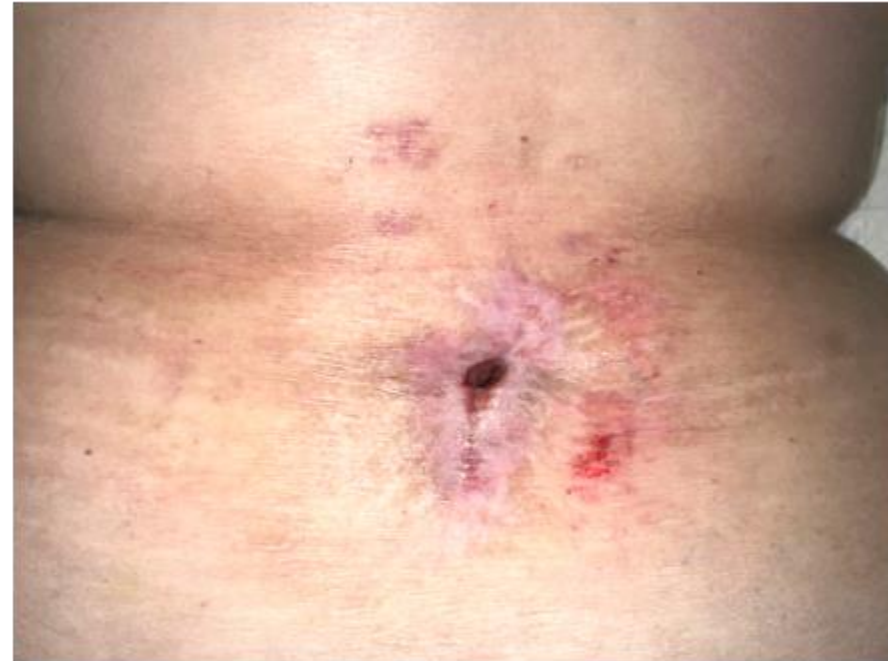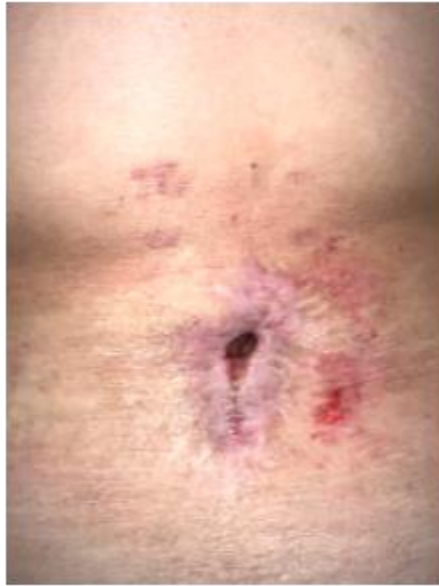1. tNPWT (traditional)
2. NPWTi-d (instillation and dwell)
3. ciNPT (closed incision)
4. sNPT (single use, disposable)
5. ALL OF THE ABOVE

***Polling was pre-recorded.**

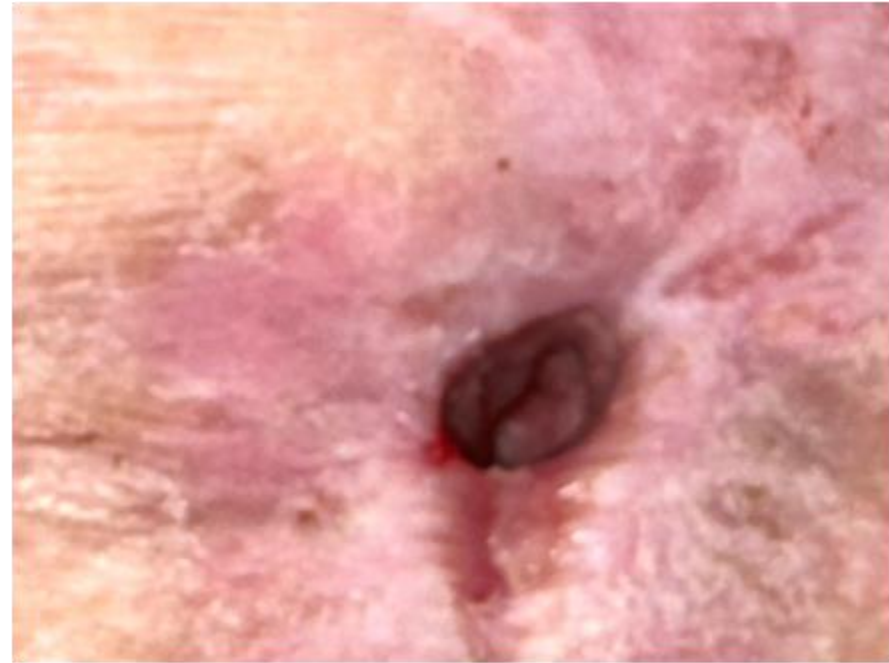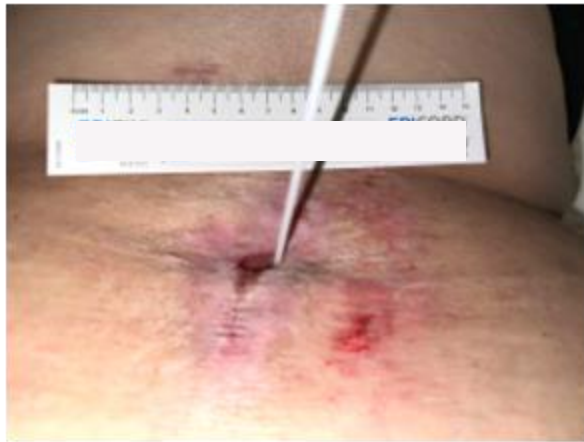Case Summary: Non-Healing Surgical Wound

- 54y Female s/p laminectomy with post-operative abscess requiring operative debridement and hardware placement. Had recurring infection requiring operative drainage with wound left to heal secondarily.
- Medical history: HTN, rheumatoid arthritis
- Treatment
 - Receiving NPWT for wound bed preparation
 - NPWT continued with all-in-one 7-day dressing to assist with healing
 - Surgical closure planned, but wound healed without need for surgical intervention

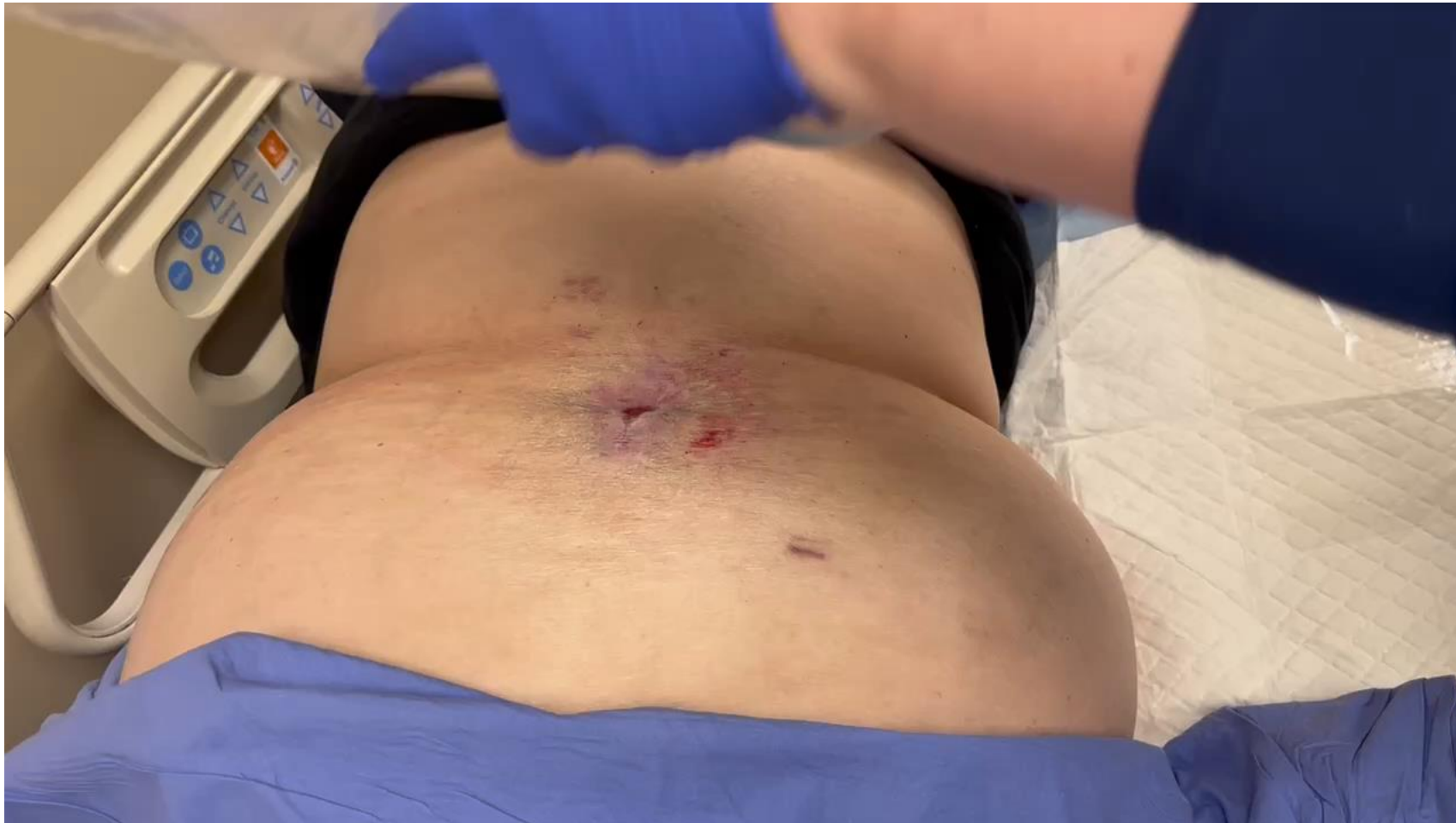Non-Healing Surgical Wound (Day 1)



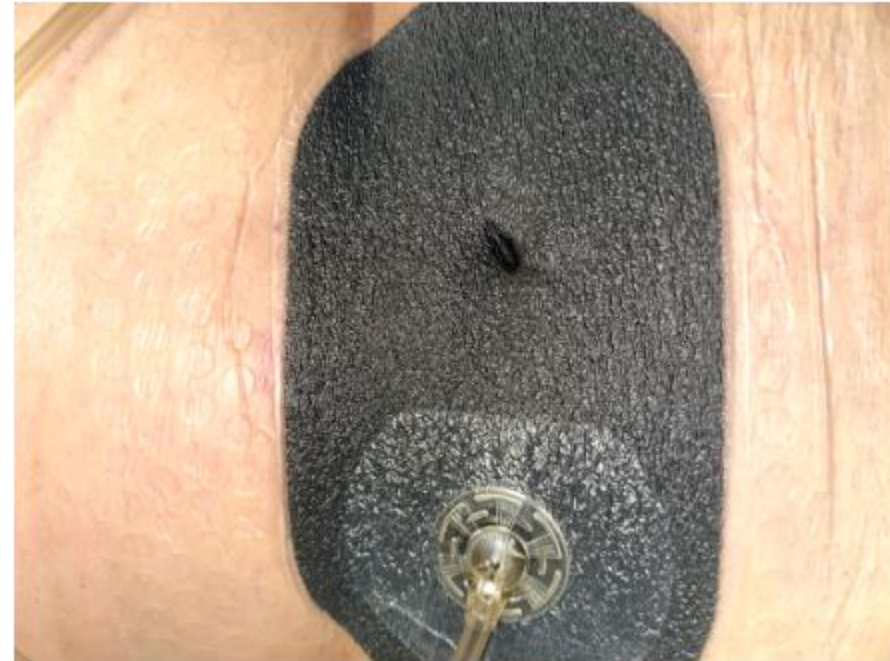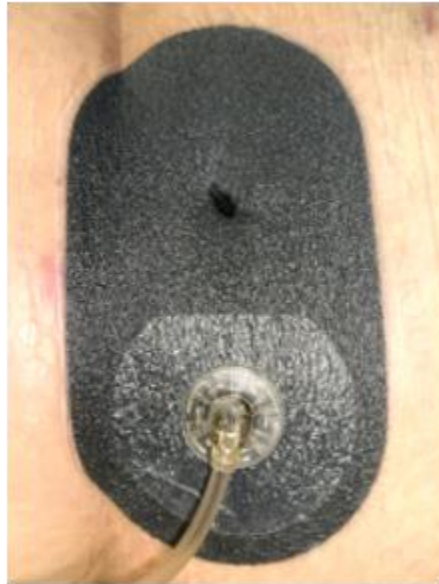Non-Healing Surgical Wound (Day 1)



Non-Healing Surgical Wound (Day 1)



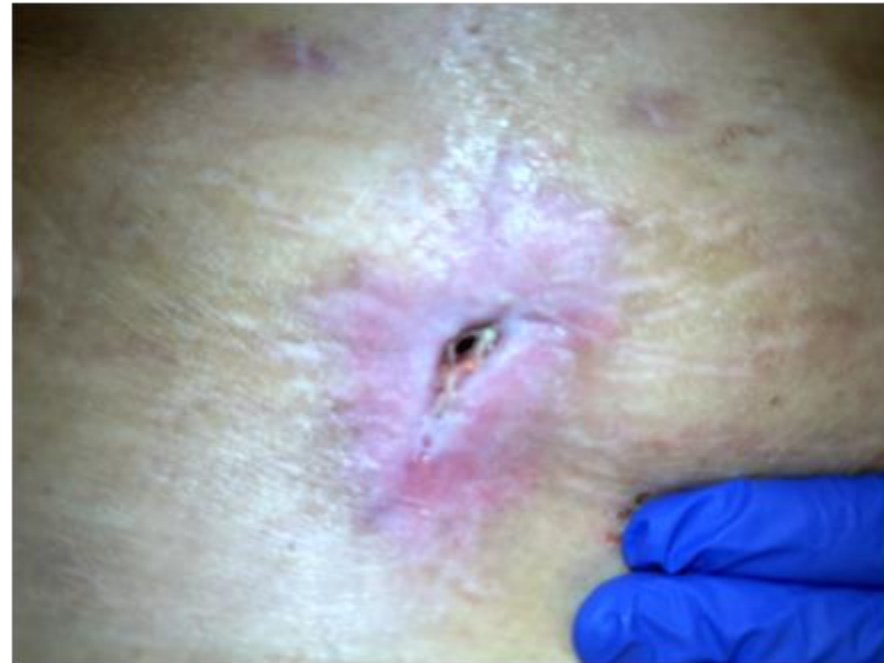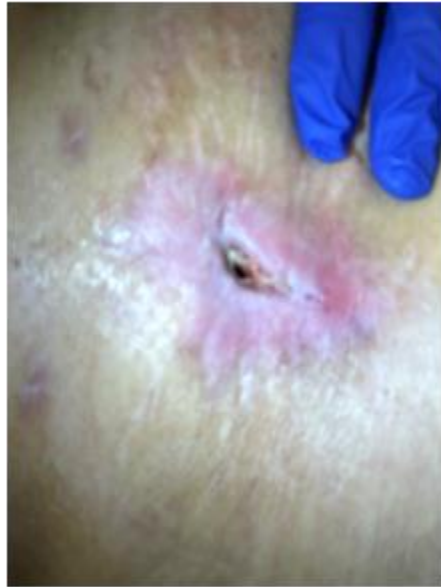Non-Healing Surgical Wound (Day 1)



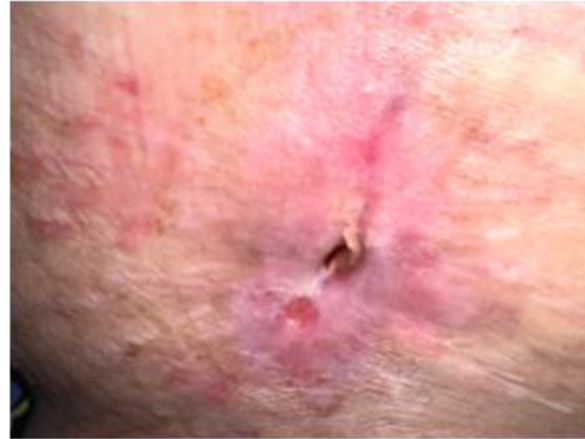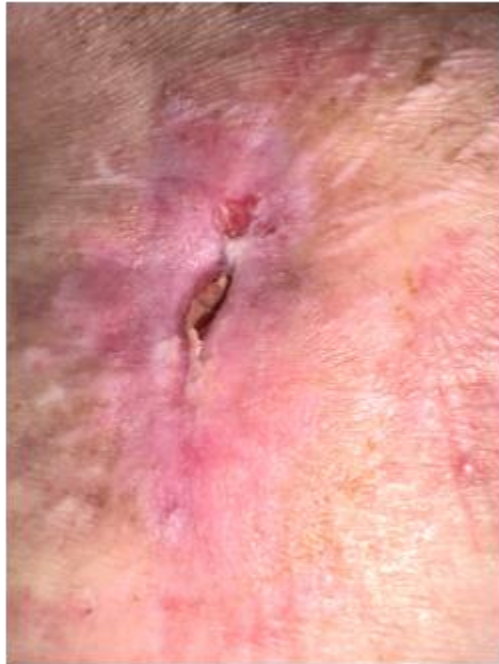Non-Healing Surgical Wound (Day 1)



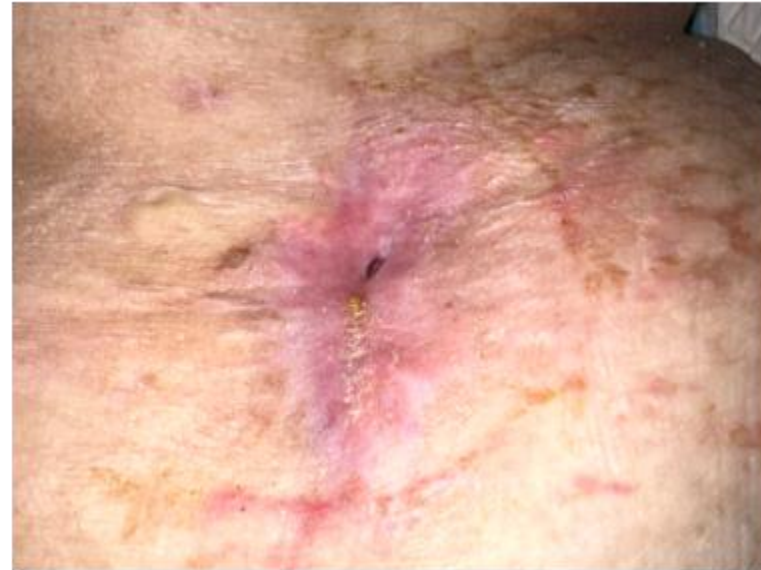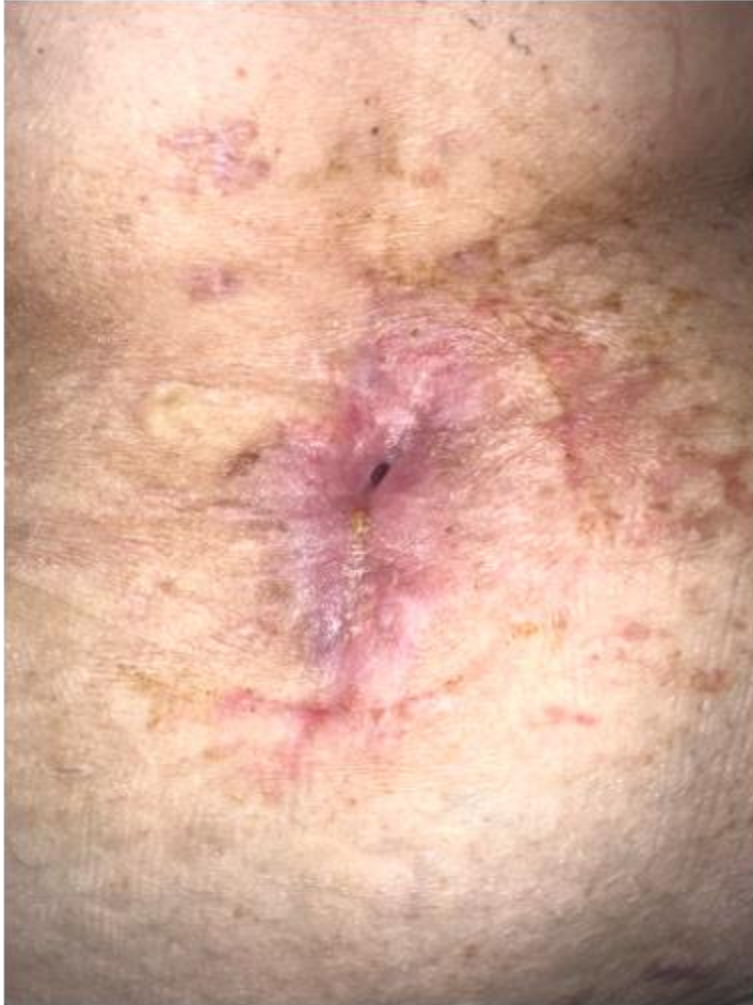Non-Healing Surgical Wound (Day 7)



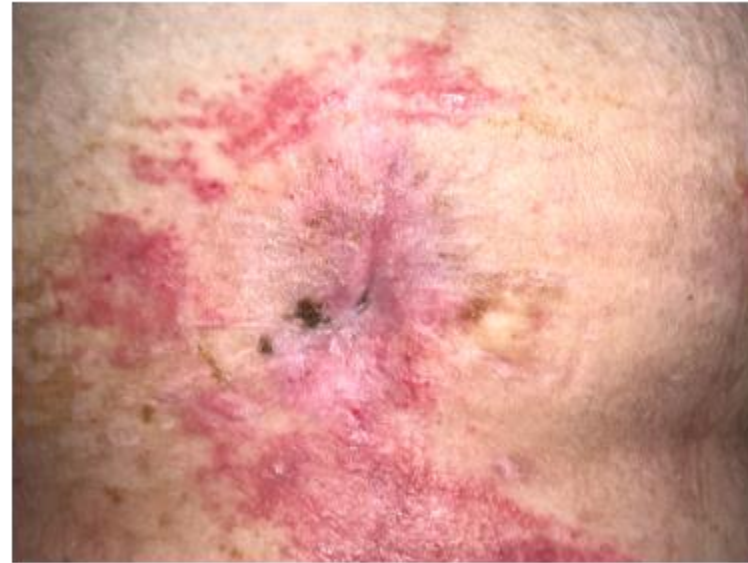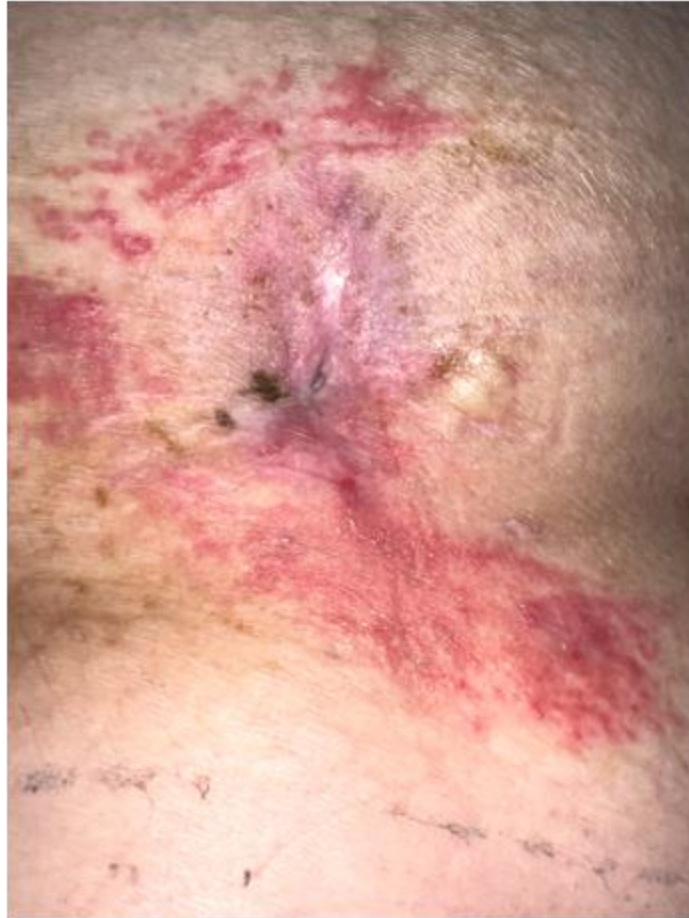Non-Healing Surgical Wound (Day 14)



Non-Healing Surgical Wound (4 Wks)



Non-Healing Surgical Wound (5 Wks)





Polling Question

Negative pressure wound therapy (NPWT) may only be used for wound bed preparation and should NEVER be used for complete re-epithelialization.

1. True
2. False

***Polling was pre-recorded.**



Polling Question

Which of the following differentiates “peel and place” dressing technology from other NPWTi-d dressings?

- A. Can be worn up to 7 days before dressing change
- B. Dressing change can be completed in ≈ 2 minutes
- C. Ease of use reduces need for staff training
- D. All of the above

***Polling was pre-recorded.**

“The price of greatness is responsibility.”

—Winston Churchill

Thank You!

Questions?