

IVUS Insights: Translating Evidence into Practice for Arterial and Venous Disease

Sponsored by an educational grant from Philips

Faculty

- **Stephen Black, MD, FEBVS, FRCS Ed, MbBCH**
Chief of Surgery, Guy's and St. Thomas' Hospital; Professor of Venous Surgery, Kings College London; London, UK
- **Elizabeth Genovese, MD, MS, FACS**
Assistant Professor of Surgery; Penn Advanced Limb Preservation Program, Director at HUP Division of Vascular Surgery and Endovascular Therapy, University of Pennsylvania
- **Kumar Madassery, MD, FSIR**
Director, Peripheral Vascular Interventions & CLTI Limb Salvage Program; Director, Advanced VIR Fellowship; Rush University Medical Center, Chicago; Rush Oak Park Hospital, Oak Park, IL
- **Gloria Salazar, MD, FSIR FCIRSE**
Clinical Associate Professor of Radiology, University of North Carolina at Chapel Hill

Faculty Disclosures

- **Stephen Black, MD, FEBVS, FRCS Ed, MbBCH**
Advisory Board: Gore; Philips; Consultant, Speakers Bureau: BD; BSCI; Cook; Gore; Medtronic; Optimed; Philips; Veryan; Vesper
- **Elizabeth Genovese, MD, MS, FACS**
Advisory Board: Boston Scientific; Cook; Philips; R3; Consultant and Educator: Abbott; Boston Scientific; Cook; Gore; Inari; Penumbra; Reflow; Shockwave; Philips; Research Support: Boston Scientific
- **Kumar Madassery, MD, FSIR**
Advisory Board: Boston Scientific; Cordis X; Consultant: Abbott; Asahi; Cook; Penumbra; Philips; Shockwave
- **Gloria Salazar, MD, FSIR FCIRSE**
Advisory Board: Medtronic; Consultant: Boston Scientific; BD; Medtronic; Mentice; Optimed; Philips; TriSalus; Speakers Bureau: Boston Scientific; Cook; Medtronic; Optimed; Penumbra; Philips

Disclosures

- The faculty have been informed of their responsibility to disclose to the audience if they will be discussing off-label or investigational use(s) of drugs, products, and/or devices (any use not approved by the US Food and Drug Administration)
 - Applicable CME staff have no relationships to disclose relating to the subject matter of this activity
 - This activity has been independently reviewed for balance
- This CME activity includes brand names for participant clarity purposes only. No product promotion or recommendation should be inferred.

Learning Objectives

- Understand the applications for intravascular imaging in both arteries and veins
- Apply intravascular ultrasound (IVUS) imaging techniques to practice
- Comprehend and apply global guidelines for venous and arterial diseases

Global Data Update on Arterial IVUS


Kumar Madassery, MD, FSIR

Director, Peripheral Vascular Interventions and CLTI Limb Salvage Program

Director, Advanced VIR Fellowship

Rush University Medical Center, Chicago, IL

Rush Oak Park Hospital, Oak Park, IL



Why IVUS in PAD?

Atherectomy is a controversial topic

- Nice to have a reason why you choose something

Why IVUS in PAD?

Atherectomy is a controversial topic

- Nice to have a reason why you choose something

Can find significant dissections

Why IVUS in PAD?

Atherectomy is a controversial topic

- Nice to have a reason why you choose something

Can find significant dissections

Can properly size balloons and stents

Why IVUS in PAD?

Atherectomy is a controversial topic

- Nice to have a reason why you choose something

Can find significant dissections

Can properly size balloons and stents

Can catch under-expanded stents

Biggest Complaint

“No Data”

WITHOUT DATA

**YOU'RE JUST ANOTHER PERSON WITH
AN OPINION**

memegenerator.net

1998

Clinical Trial > [Cardiovasc Intervent Radiol.](#) 1998 Sep-Oct;21(5):367-74.

doi: [10.1007/s002709900282](#).

Comparison of angiography and intravascular ultrasound before and after balloon angioplasty of the femoropopliteal artery

[W van Lankeren](#) ¹, [E J Gussenhoven](#), [H Pieterman](#), [M R van Sambeek](#), [A van der Lugt](#)

- Looked at angiographic and IVUS data before and after balloon angioplasty of the femoropopliteal artery
- 135 patients evaluated
- IVUS detected
 - More lesions
 - Calcified lesions
 - More vascular damage than angiography

2014

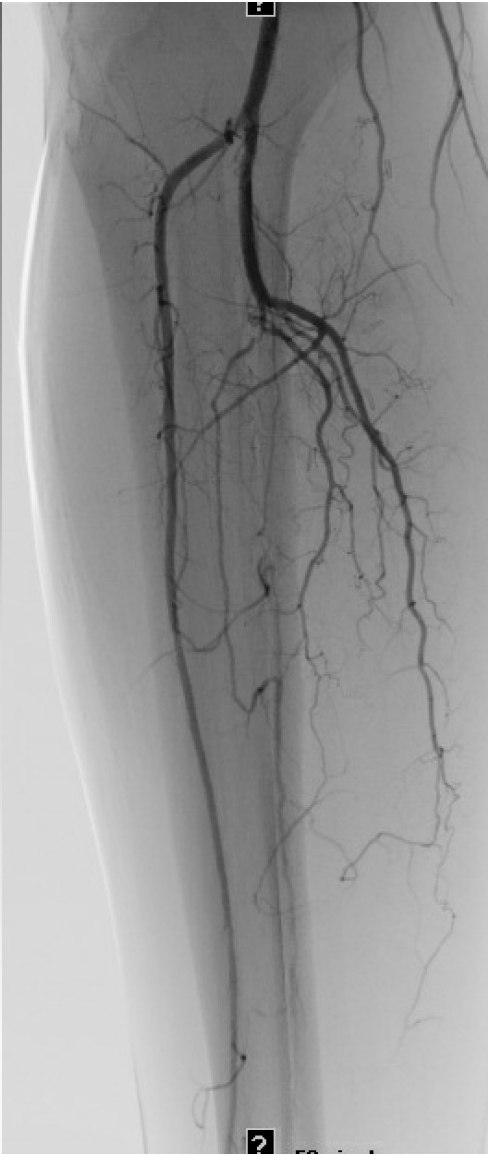
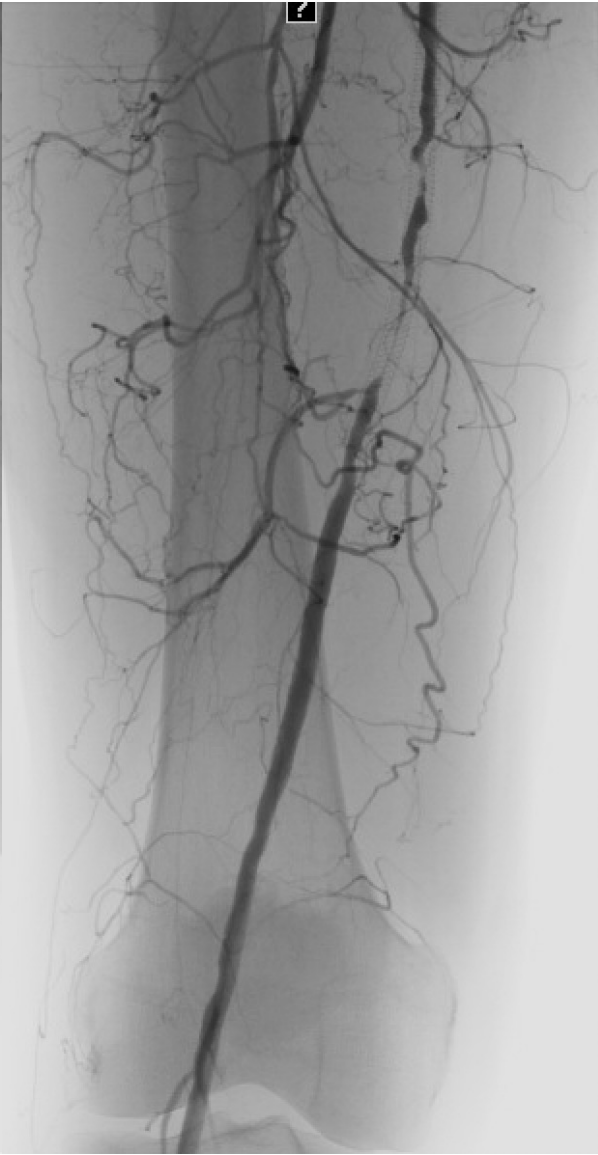
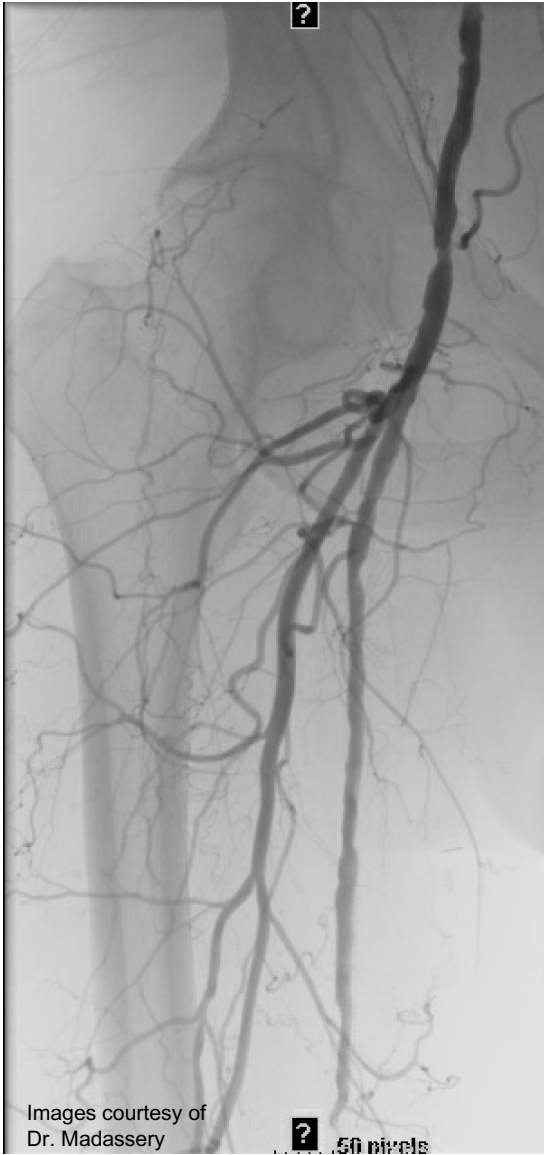Multicenter Study

> J Endovasc Ther. 2014 Aug;21(4):485-92. doi: 10.1583/14-4721R.1.

Efficacy of intravascular ultrasound in femoropopliteal stenting for peripheral artery disease with TASC II class A to C lesions

Osamu Iida ¹, Mitsuyoshi Takahara, Yoshimitsu Soga, Kenji Suzuki, Keisuke Hirano, Daizo Kawasaki, Yoshiaki Shintani, Nobuhiro Suematsu, Terutoshi Yamaoka, Shinsuke Nanto, Masaaki Uematsu

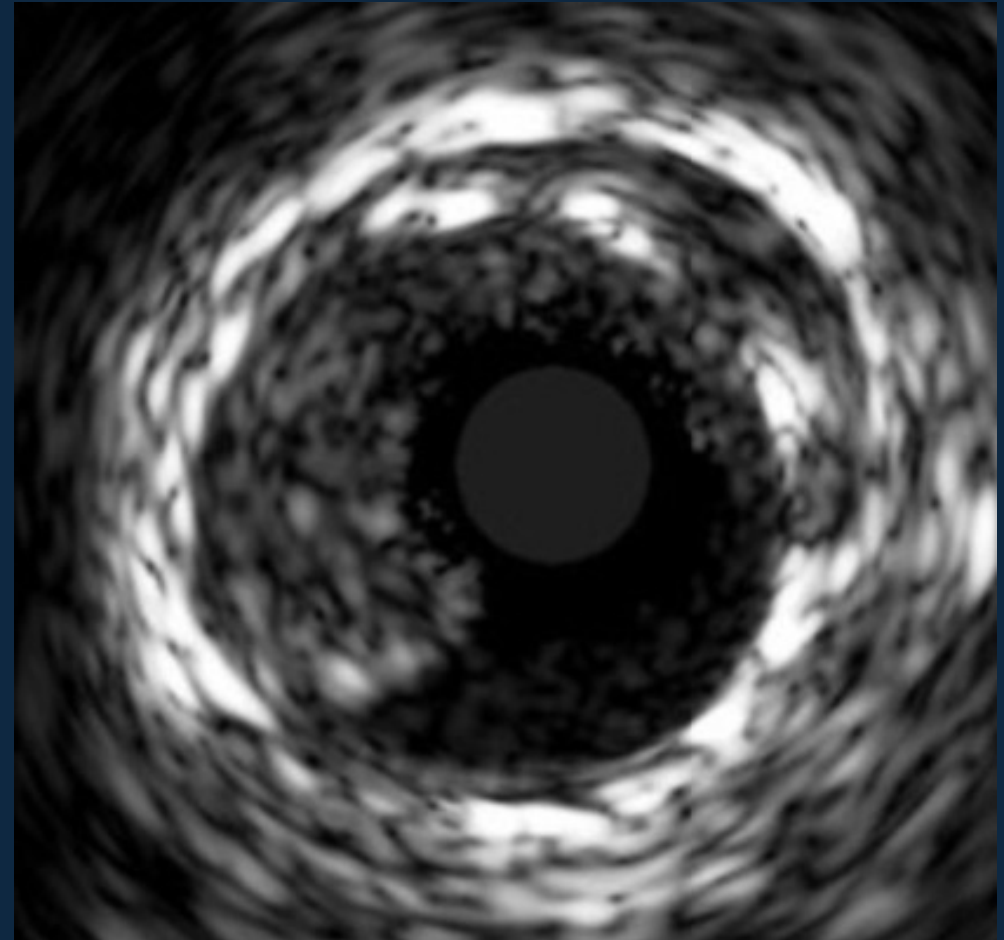
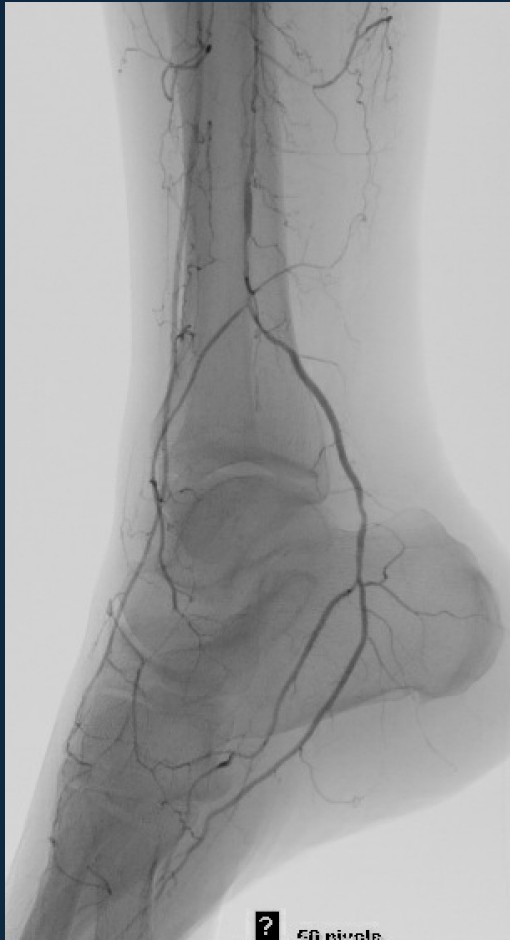
- IVUS in nitinol stenting in the fempop
- Retrospective review of ~1200 patients
- Evaluating **primary patency rate** between 234 propensity score-matched pairs with vs without IVUS use
- Higher **5-yr** primary patency with, than without, IVUS use
- IVUS with significantly better
 - Assisted primary and secondary patency
 - Freedom from any reintervention and adverse limb events



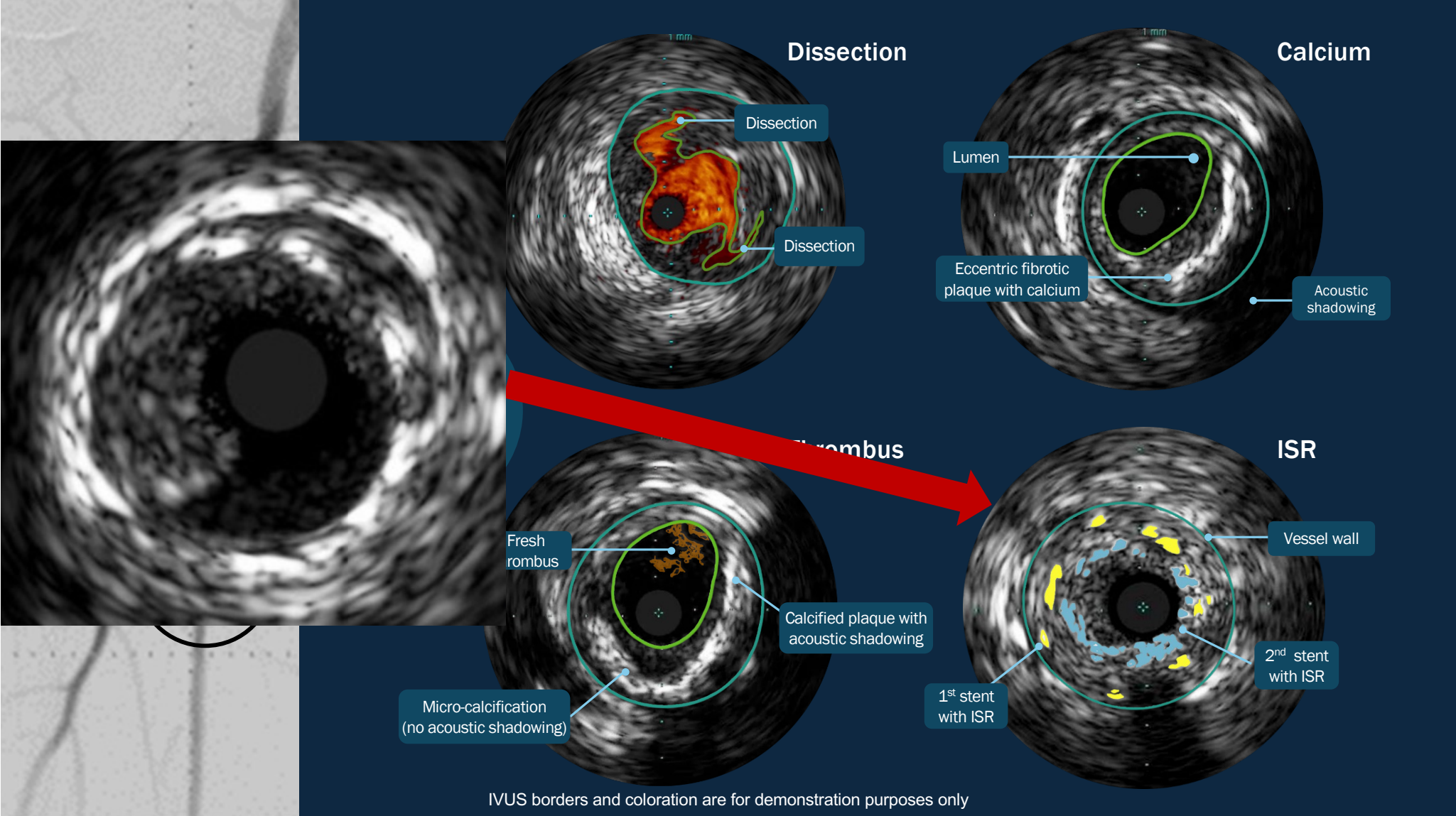
Images courtesy of
Dr. Madassery

How We Used to Tell Vessel Size and What Type of Plaque

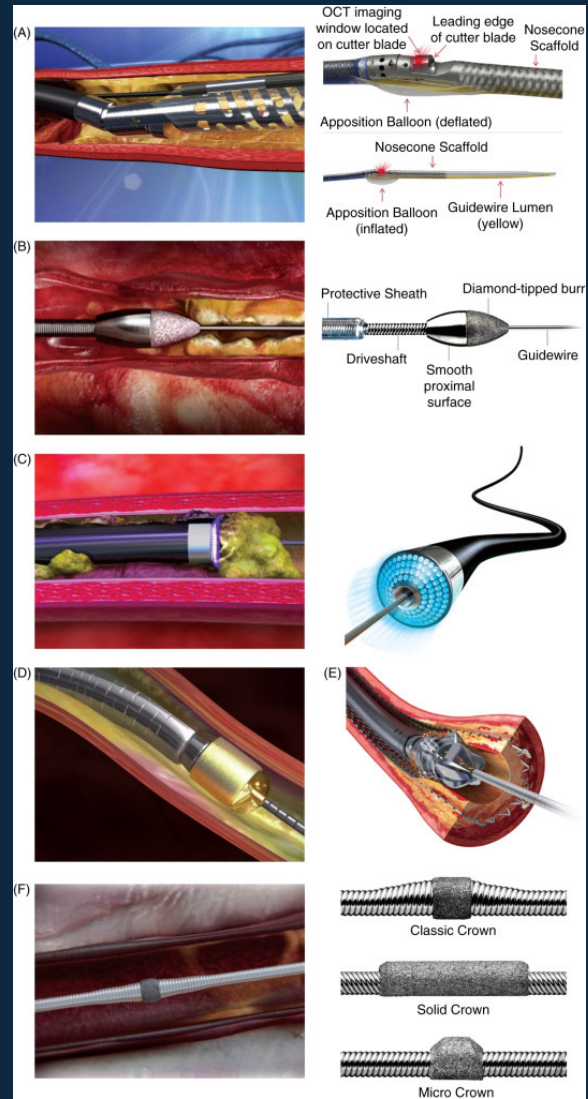





Images courtesy of Dr. Madassery



Choosing a Tool



Global Evidence

Australian Data, 2022

Randomized Controlled Trial > JACC Cardiovasc Interv. 2022 Mar 14;15(5):536-546.

doi: 10.1016/j.jcin.2022.01.001.

The Impact of Intravascular Ultrasound on Femoropopliteal Artery Endovascular Interventions: A Randomized Controlled Trial

Richard B Allan ¹, Phillip J Puckridge ², J Ian Spark ³, Christopher L Delaney ²

Affiliations + expand

PMID: 35272779 DOI: 10.1016/j.jcin.2022.01.001

Free article



1-yr Data

Study Design

Detailed description of design previously reported

150 patients

Undergoing femoro-popliteal interventions

Parallel-group design with balanced randomization

Control group (angiography information only available)

3-Year Follow-Up Outcomes

Primary Outcome

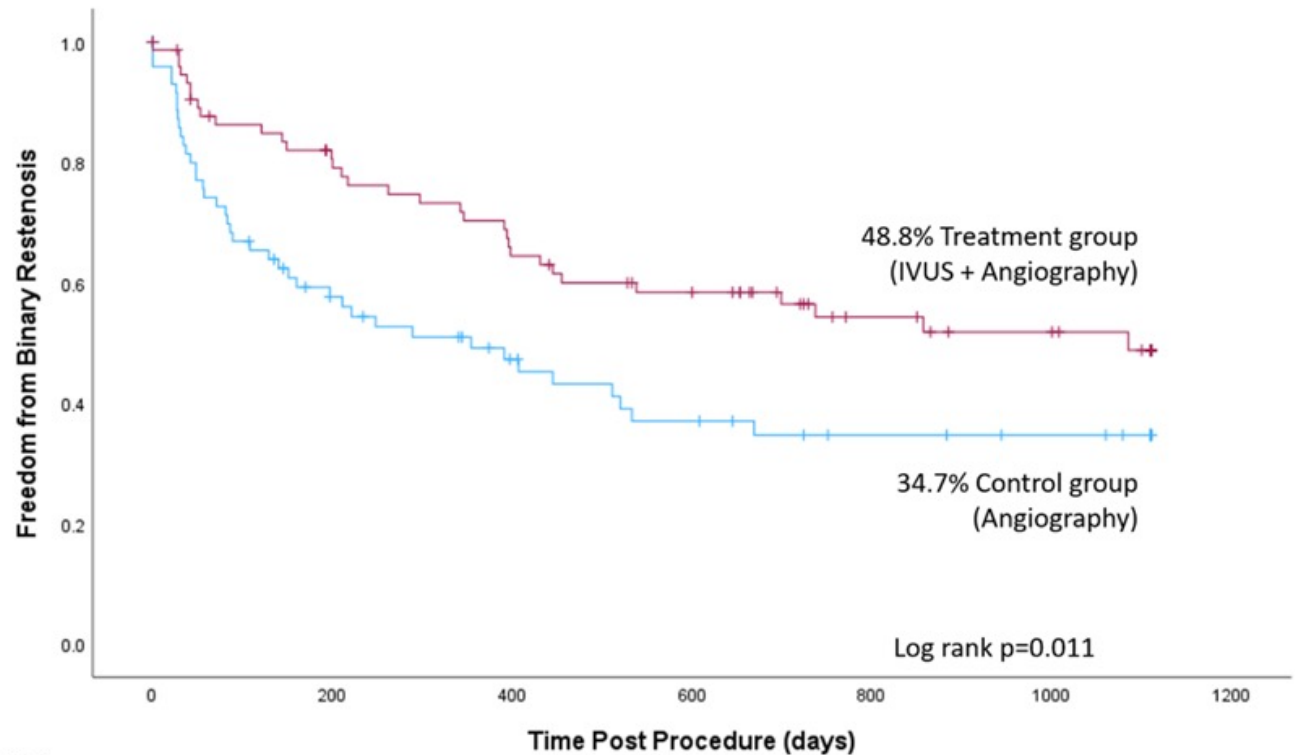
- Binary restenosis within 36 months of the index procedure
 - >50% stenosis on duplex ultrasound
 - PSV \geq 2.4

Secondary Outcomes

- Clinically driven Target Lesion Revascularization (TLR)
- Major Adverse Events (MAE)

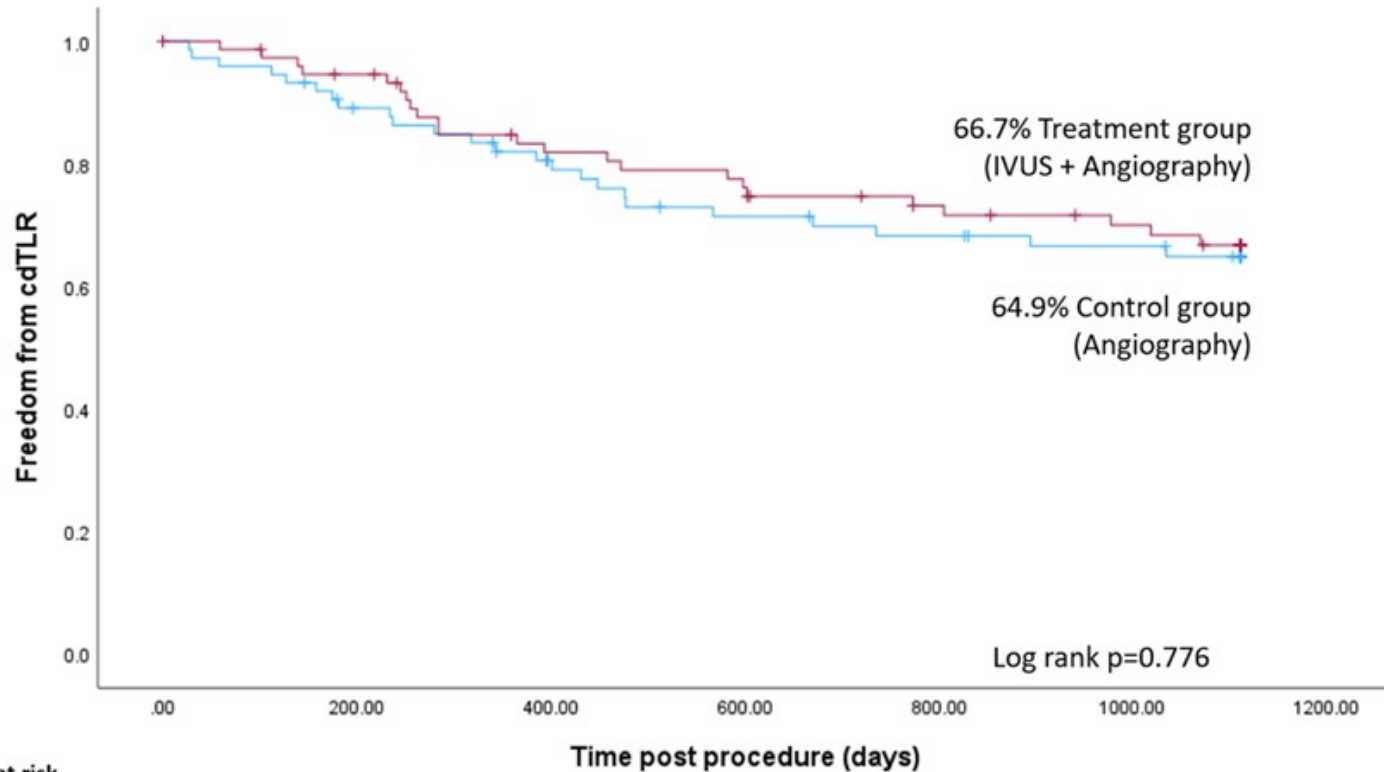
Primary Outcome 36 Months

- Significant benefit at **12** months
- Persistent **reduction in binary re-stenosis at 36 months**
- Freedom from binary restenosis **48.8%** with IVUS vs **34.7%** using angiography alone ($P=0.011$)



Patients at risk		0	200	400	600	800	1000	1200
Control group		74	26	14	9			
Treatment group		76	45	25	16			

Secondary Outcomes 36 Months



Patients at risk
Control group
Treatment group

74
76

59
63

43
49

37
40

- No difference in cdTLR rates at **12** or **36** months

Use of IVUS Was Safe

- **No significant difference in MAE** within 36 months between treatment and control groups
 - (32.9% vs 40.5%, $p=0.397$)

	Control group (angiography) (n=74)	Treatment Group (IVUS and angiography) (n=76)	p value
Death	18 (24.3%)	10 (13.2%)	0.077*
Myocardial infarction	21 (28.4%)	17 (22.4%)	0.405†
Stroke/TIA	4 (5.4%)	1 (1.3%)	0.206†
Major amputation	2 (2.7%)	3 (5.3%)	1.000†
Acute kidney failure	0 (0.0%)	1 (3.9%)	1.000†
Thrombolysis	0 (0.0%)	1 (1.3%)	1.000†
Re-admission	2 (2.7%)	1 (1.3%)	0.617†
Individuals with at least one MAE	30 (40.5%)	25 (32.9%)	0.397†

Subgroup Analysis Benefit in DCB Use

- Original publication IVUS availability significantly increased the mean DCB size chosen
- At **36 months higher freedom from Binary Restenosis in treatment group vs control group**
 - Treated with DCB
 - 68.2% in IVUS treatment vs 31.8% without IVUS
 - $P=0.005$
- No differences seen in POBA or stents
- No difference observed in cdTLR between different treatment types

Conclusions: 36 Month Outcomes

IVUS with Angio → significantly increased freedom from binary restenosis



IVUS provides greater understanding of the target vessel in femoro-popliteal segment



Primary benefit seen with use of DCB technology

Korean Data

3 studies that have elucidated benefits of IVUS use in fem-pop revascularization outcomes



1

Intravascular ultrasound-guided drug-coated balloon angioplasty for femoropopliteal artery disease: a clinical trial

Young-Guk Ko ^{1*}†, Seung-Jun Lee^{1†}, Chul-Min Ahn¹, Sang-Hyup Lee ¹, Yong-Joon Lee ¹, Byeong-Keuk Kim¹, Myeong-Ki Hong ¹, Yangsoo Jang¹, Tae-Hoon Kim^{2,3}, Ha-Wook Park³, Ji Yong Jang⁴, Jae-Hwan Lee^{5,6}, Jae-Hyeong Park⁶, Su Hong Kim⁷, Eui Im⁸, Sang-ho Park⁹, and Donghoon Choi^{1*}; on behalf of the IVUS-DCB investigators

¹Severance Cardiovascular Hospital, Yonsei University College of Medicine, Seodaemun-gu, Seoul 03722, Korea; ²Division of Cardiology, Hanil General Hospital, Seoul, Korea; ³Division of Cardiology Cardiovascular Center, Bucheon Sejong Hospital, Bucheon, Korea; ⁴Division of Cardiology, National Health Insurance Service Ilsan Hospital, Goyang, Korea; ⁵Division of Cardiology, Chungnam National University Sejong Hospital, Sejong, Korea; ⁶Division of Cardiology, Chungnam National University Hospital, Daejeon, Korea; ⁷Division of Cardiology, Busan Veterans Hospital, Busan, Korea; ⁸Division of Cardiology, Yongin Severance Hospital, Seoul, Korea; and ⁹Cardiology Department, Soonchunhyang University Cheonan Hospital, Cheonan, Korea

Received 14 March 2024; revised 14 April 2024; accepted 28 May 2024


- Does IVUS improve **PP** and clinical outcomes for fem-pop interventions with DCB compared to angio alone?

Design

- Multicenter
- Randomized **SINGLE-Blinded** Superiority Trial
- Independent Clinical Event Adjudication Committee
- Funded by Medtronic and Korea United Pharm (No Involvement in design, data collection, analysis, etc)
- Rutherford 2-5
- Lesion length <150mm
- POBA 1mm less than planned DCB size
- Atherectomy for calcium was allowed

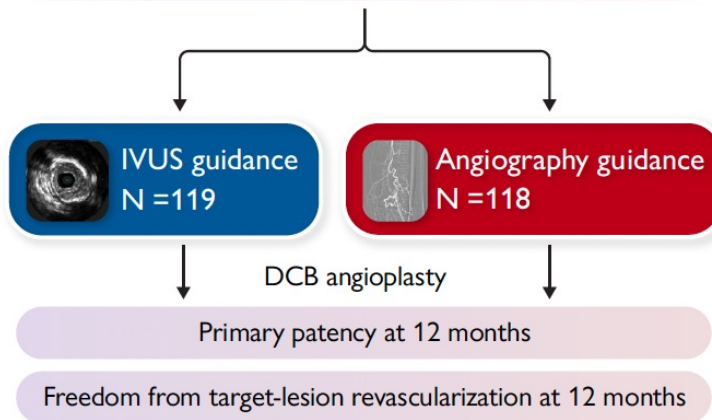
Results

Intravascular ultrasound-guided drug-coated balloon angioplasty for femoropopliteal artery disease



Patients with symptomatic femoropopliteal artery disease

- Rutherford categories 2 to 5
- Total: N =237
- 7 centres in South Korea



Post-procedure minimal lumen diameter

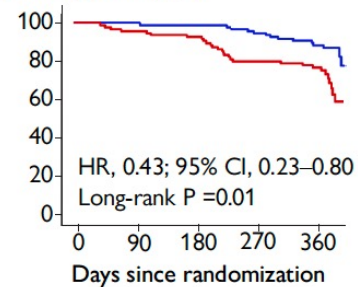
IVUS guidance
 3.90 ± 0.59 mm

Angiography guidance
 3.71 ± 0.73 mm

IVUS guidance led to a larger post-procedure MLD
(+ 0.19 mm, P =0.03)

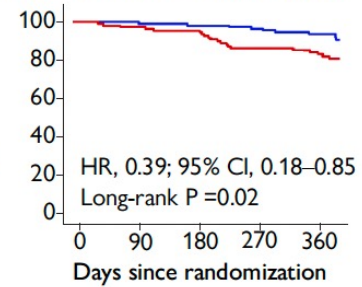
Primary patency

Proportion of patients with primary patency (%)



Target lesion revascularization

Proportion of patients free from target lesion revascularization (%)



— IVUS guidance — Angiography guidance

**IVUS
DCB
Trial**

Randomized Controlled Trial > [JACC Cardiovasc Interv.](#) 2025 Mar 10;18(5):558-569.

doi: 10.1016/j.jcin.2024.10.052. Epub 2025 Jan 22.

Intravascular Ultrasound-Guided vs Angiography-Guided Drug-Coated Balloon Angioplasty in Patients With Complex Femoropopliteal Artery Disease

Seung-Jun Lee¹, Tae-Hoon Kim², Jae-Hwan Lee³, Chul-Min Ahn¹, Sang-Hyup Lee¹,
Yong-Joon Lee¹, Byeong-Keuk Kim¹, Myeong-Ki Hong¹, Yangsoo Jang¹, Ha-Wook Park⁴,
Ji Yong Jang⁵, Jae-Hyeong Park⁶, Su Hong Kim⁷, Eui Im⁸, Sang-Ho Park⁹, Donghoon Choi¹,
Young-Guk Ko¹⁰; IVUS-DCB Investigators

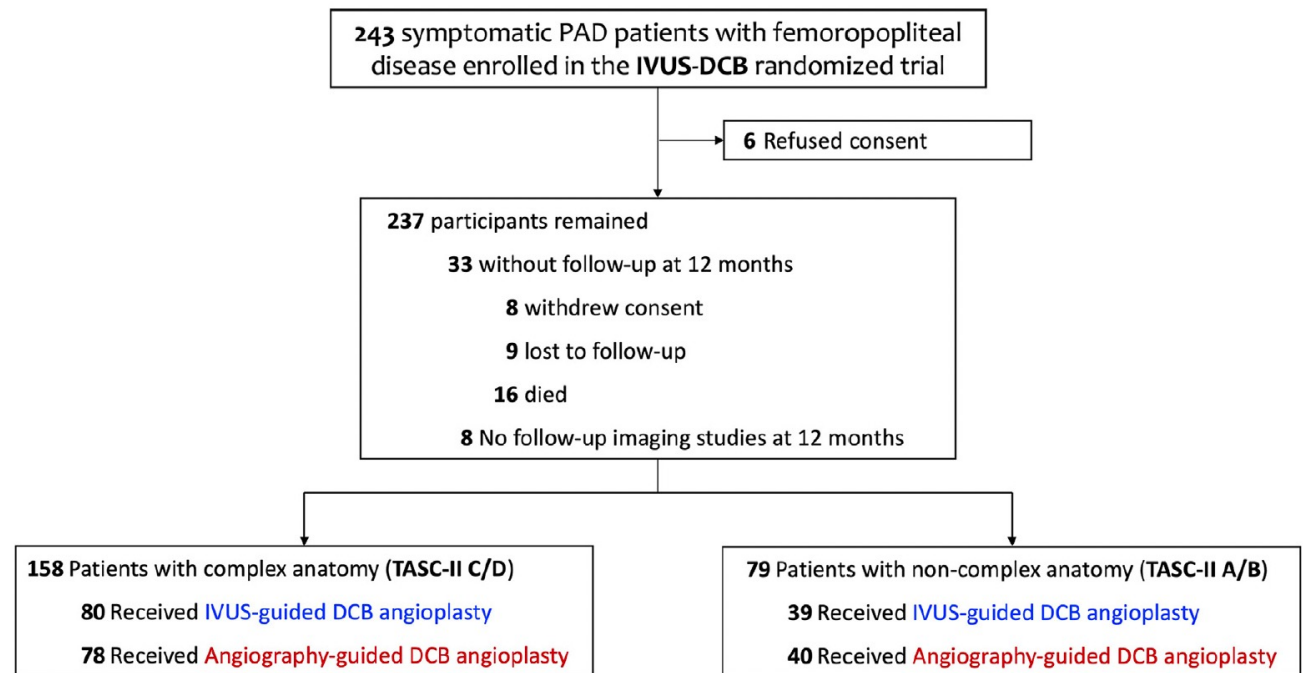
Affiliations + expand

PMID: 39846915 DOI: [10.1016/j.jcin.2024.10.052](#)

Design

1. “Non-Complex” FPA
 - a. Tasc II A or B
2. “Complex FPA”
 - a. Tasc II C or D
3. Calcium
 - a. PACSS

FIGURE 1 Flow Chart Schematic Illustrating the Design of the Current Study



DCB = drug-coated balloon; IVUS = intravascular ultrasound; PAD = peripheral artery disease; TASC = Trans-Atlantic Inter-Society Consensus.

Lesion and Crossing/ Treatment Characteristics

TABLE 2 Angiographic and Procedural Characteristics for Target Lesions

	TASC II C/D			TASC II A/B		
	IVUS Guidance (n = 80)	Angiography Guidance (n = 78)	P Value	IVUS Guidance (n = 39)	Angiography Guidance (n = 40)	P Value
Angiographic characteristics						
Lesion length, mm	241.0 ± 85.8	257.8 ± 89.7	0.24	132.8 ± 97.6	131.2 ± 70.8	0.93
Reference vessel diameter, mm	5.0 ± 0.7	5.0 ± 0.7	0.66	5.0 ± 0.8	5.0 ± 0.7	0.88
Minimal lumen diameter, mm	0.13 ± 0.36	0.29 ± 0.61	0.05	0.84 ± 0.82	0.84 ± 0.68	0.99
Total occlusion	65 (83.3)	59 (76.6)	0.40	13 (33.3)	9 (22.5)	0.41
PACSS calcification score						
0 to 2	38 (47.5)	43 (55.1)	0.42	27 (69.2)	29 (72.5)	0.94
3 to 4	42 (52.5)	35 (44.9)		12 (30.8)	11 (27.5)	
Popliteal involvement	5 (6.2)	5 (6.5)	>0.99	6 (15.4)	5 (12.5)	0.96
Poor distal runoff vessels ^a	21 (26.2)	25 (32.1)	0.53	9 (23.1)	11 (27.5)	0.85
Procedural characteristics						
Subintimal recanalization	29 (37.2)	29 (37.7)	>0.99	2 (5.1)	2 (5.0)	>0.99
Use of atherectomy device	34 (43.6)	28 (36.4)	0.45	7 (17.9)	10 (25.0)	0.63
Pre-balloon diameter, mm	5.1 ± 0.8	4.2 ± 1.1	<0.001	5.2 ± 0.8	4.8 ± 0.8	0.08
Pre-balloon length, mm	130.2 ± 58.2	126.9 ± 65.0	0.74	107.7 ± 53.5	103.2 ± 56.3	0.72
Pre-balloon maximal pressure, mm Hg	11.9 ± 4.2	8.9 ± 2.7	<0.001	11.4 ± 2.1	8.8 ± 2.6	<0.001
Total DCB length, treated lesion length, mm	299.2 ± 98.8	311.4 ± 100.6	0.45	161.3 ± 97.1	166.8 ± 86.5	0.79
Number of DCBs, total						
Maximal DCB diameter, mm	2.2 ± 0.8	2.3 ± 0.7	0.48	1.4 ± 0.6	1.4 ± 0.5	0.79
Mean DCB diameter, mm	6.0 ± 0.7	5.9 ± 0.9	0.41	5.5 ± 0.7	5.7 ± 0.6	0.26
Adjuvant postdilatation	5.4 ± 0.6	5.4 ± 0.7	0.69	5.4 ± 0.7	5.5 ± 0.6	0.52
Maximal post-balloon pressure, mm Hg	27 (33.8)	12 (15.4)	0.01	4 (10.3)	4 (10.0)	>0.99
Bailout stent implantation	13.5 ± 3.0	9.6 ± 3.4	0.001	14.8 ± 3.0	9.5 ± 6.4	0.14
Postprocedural minimal lumen diameter, mm	20 (25.6)	13 (16.9)	0.26	4 (10.3)	4 (10.0)	0.97
Postprocedural diameter stenosis, %	3.9 ± 0.6	3.6 ± 0.8	0.005	3.9 ± 0.6	3.9 ± 0.6	0.80
Postprocedural diameter stenosis, %	21.5 ± 12.5	28.0 ± 13.5	0.002	21.6 ± 11.0	20.5 ± 11.7	0.68
Immediate procedural outcomes						
Technical success	59 (73.8)	44 (56.4)	0.03	32 (82.1)	28 (70.0)	0.32
Procedural success	56 (70.0)	43 (55.1)	0.08	32 (82.1)	28 (70.0)	0.32
Dissection ^b						
A	46 (57.5)	52 (66.7)	0.31	24 (61.5)	16 (40.0)	0.09
B	4 (8.2)	10 (18.9)		4 (15.4)	5 (23.8)	
C	19 (38.8)	22 (41.5)		16 (61.5)	7 (33.3)	
D	16 (32.7)	14 (26.4)		4 (15.4)	4 (19.0)	
E	5 (10.2)	5 (9.4)		0	0	
E	2 (4.1)	1 (1.9)		0	0	
Distal embolization	0	0	–	0	0	–
Vessel perforation	1 (1.2)	1 (1.3)	>0.99	0	0	–
Access site complications	2 (2.5)	2 (2.6)	>0.99	0	0	–
Postprocedure ABF ^c	0.97 ± 0.13	0.90 ± 0.17	0.002	1.02 ± 0.12	0.99 ± 0.10	0.19

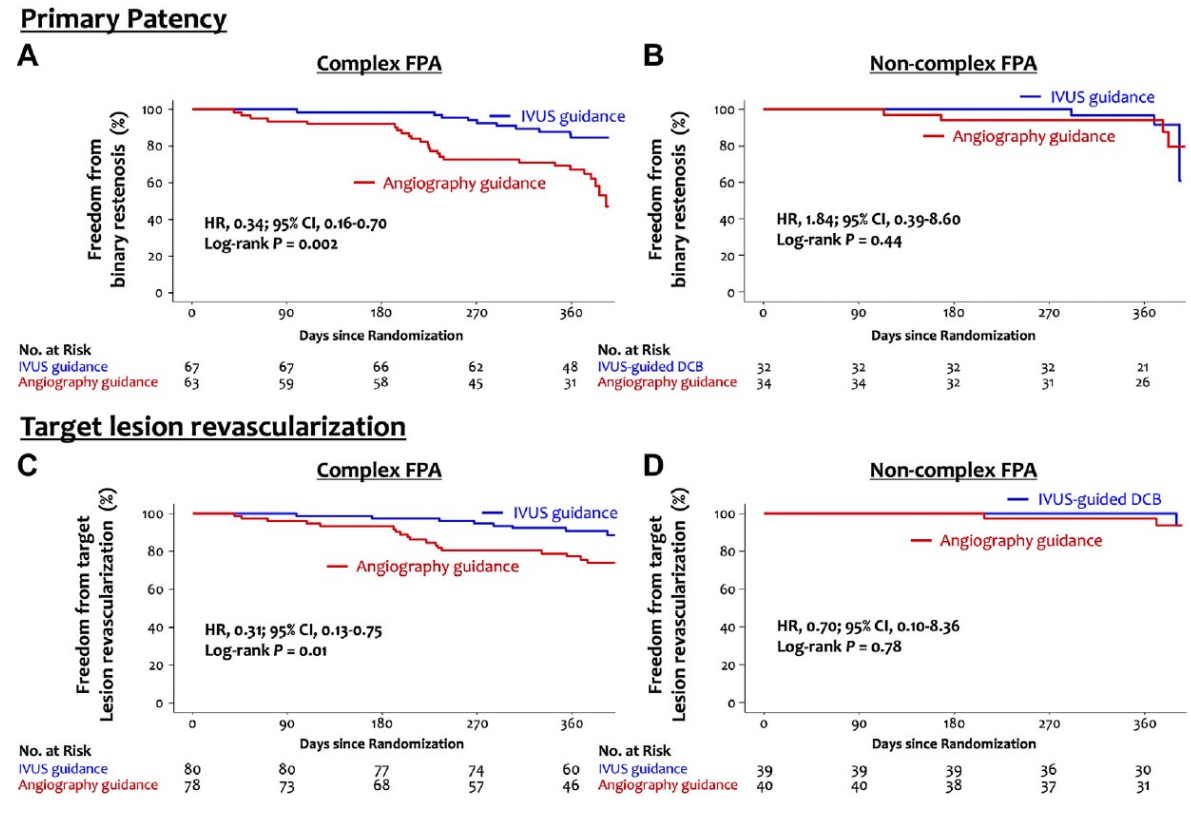
Values are mean ± SD or n (%). ^aIndicates that the number of patent runoff vessels is either 0 or 1. ^bType A: dissection involves minor radiolucent areas; Type B: dissection is linear, usually on both sides of the vessel; Type C: dissection includes contrast outside the flow lumen; Type D: spiral-pattern dissection; Type E: dissection with persistent filling defects. ^cMeasured within 48 hours after the index procedure.

DCB = drug-coated balloon; PACSS = Peripheral Arterial Calcium Scoring System; other abbreviations as in Table 1.

In **complex FPA**, IVUS guidance was associated with:

1. Significantly higher rates of primary patency
2. Higher freedom from CD-TLR
3. Sustained clinical and hemodynamic improvement relative to angiography guidance

FIGURE 2 Kaplan-Meier Curves for Clinical Endpoints According to Lesion Complexity

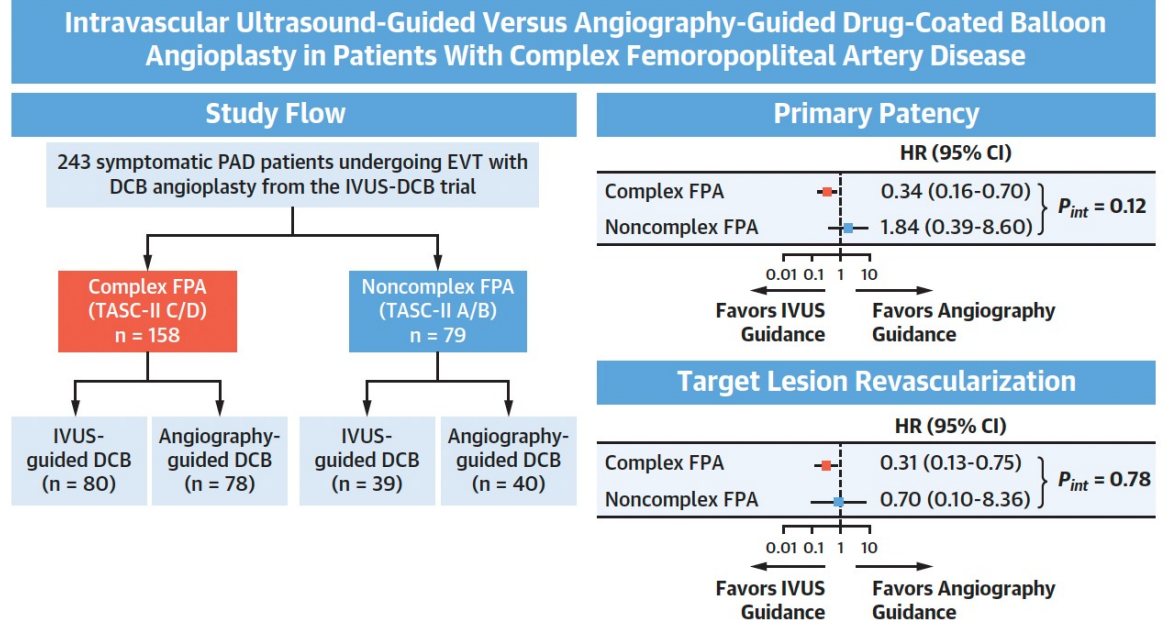


Kaplan-Meier curves for primary patency (A and B) and clinically driven target lesion revascularization (C and D) 12 months after IVUS-guided or angiography-guided DCB angioplasty in patients with complex (A and C) or noncomplex (B and D) femoropopliteal artery (FPA) lesions. Patients who underwent predefined imaging evaluations for the target lesion within 395 days following the index procedure were eligible for the primary patency analysis. HRs are for IVUS-guided DCB angioplasty vs angiography-guided DCB angioplasty, calculated using the Cox proportional hazards model adjusted for age, body mass index, and chronic kidney disease. Abbreviations as in [Figure 1](#).

Limits

1. Follow-up binary re-stenosis eval was with CTA, mostly
2. Not powered for many parameters

CENTRAL ILLUSTRATION Intravascular Imaging and Lesion Complexity During Drug-Coated Balloon Angioplasty for Femoropopliteal Disease



- Among patients enrolled and followed for 12 months, two-thirds had complex (TASC-II C/D) anatomy
- IVUS guidance for DCB angioplasty of complex anatomy was associated with higher rates of primary patency and clinical improvement versus angiography guidance
- Outcomes were similar irrespective of guidance modality for noncomplex (TASC-II A/B) lesions

Lee S-J, et al. JACC Cardiovasc Interv. 2025;18(5):558-569.

Intravascular imaging and lesion complexity during drug-coated balloon (DCB) for femoropopliteal disease. EVT = endovascular treatment; FPA = femoropopliteal artery; IVUS = intravascular ultrasound; IVUS-DCB = Intravascular Ultrasound-Guided Drug-Coated Balloon Angioplasty for Femoropopliteal Artery Disease trial; PAD = peripheral artery disease; TASC = Trans-Atlantic Inter-Society Consensus.

IVUS DCB Trial Sub-Analysis

> [Am J Cardiol.](#) 2025 Jul 1;246:58-64. doi: 10.1016/j.amjcard.2025.03.018. Epub 2025 Mar 26.

Intravascular Ultrasound Predictors of 12-Month Patency Loss Following Drug-Coated Balloon Angioplasty for the Femoropopliteal Artery

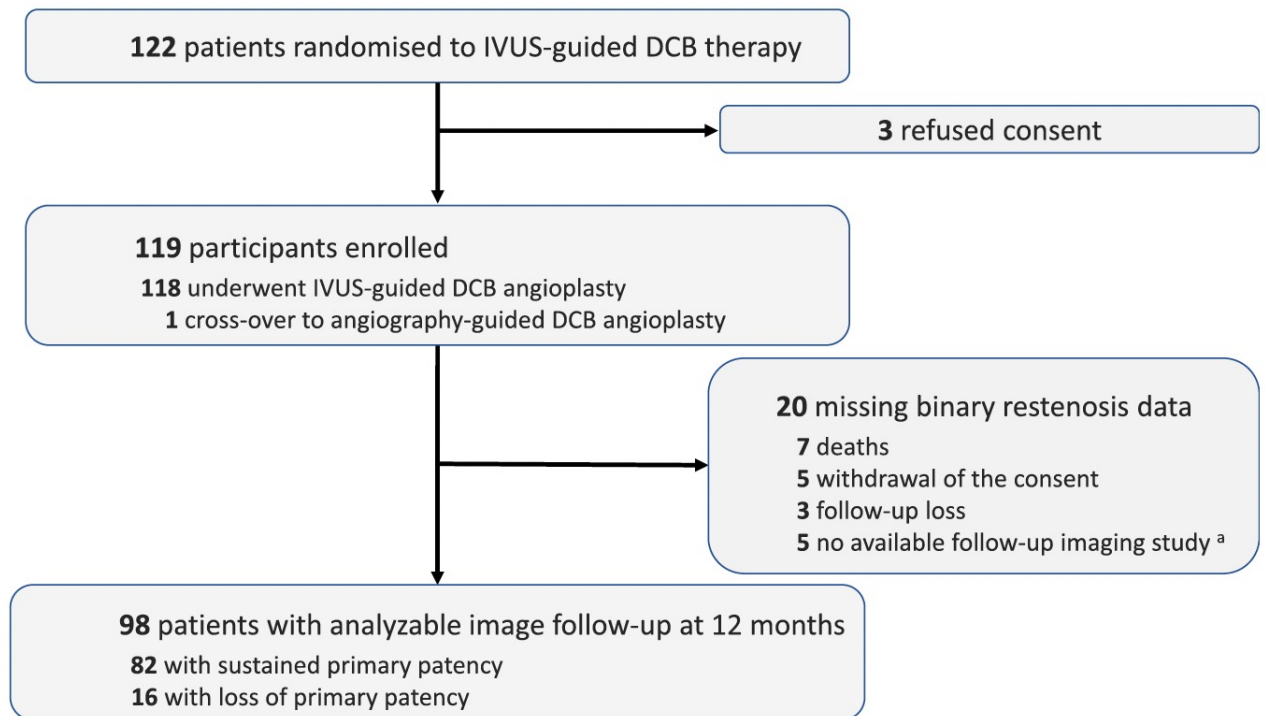
Jaeoh Lee ¹, Ji Yong Jang ², Chul-Min Ahn ¹, Seung-Jun Lee ¹, Sang-Hyup Lee ¹, Yong-Joon Lee ¹, Sung-Jin Hong ¹, Jung-Sun Kim ¹, Byeong-Keuk Kim ¹, Myeong-Ki Hong ¹, Yangsoo Jang ¹, Tae-Hoon Kim ³, Ha-Wook Park ⁴, Jae-Hwan Lee ⁵, Jae-Hyeong Park ⁶, Su Hong Kim ⁷, Eui Im ⁸, Sang-Ho Park ⁹, Donghoon Choi ¹, Young-Guk Ko ¹⁰;
IVUS-DCB Investigators

Affiliations + expand

PMID: 40154590 DOI: [10.1016/j.amjcard.2025.03.018](#)

Looking for Re-Stenosis Subset

- Took the 243 from the IVUS DCB trial
- Total of 98 had follow-up 12-month patency data



Procedural Events

- IVUS done twice per patient
- They used Philips > Boston IVUS
- Admiral DCB
- Luminal and subintimal CTO
- Atherectomy for calcium
- Bail-out nitinol stents

Table 2
Lesion and procedural characteristics

Characteristics	Patency-maintained (n = 82)	Patency-loss (n = 16)	p-value
TASC-II type C/D	55 (67.1)	12 (75.0)	0.742
Lesion length, mm	220.2 ± 118.3	226.6 ± 152.0	0.852
Total occlusion	53 (65.4)	11 (73.3)	0.766
Severe calcification*	41 (50.0)	6 (37.5)	0.521
Popliteal artery involvement	7 (8.5)	3 (18.8)	0.434
Poor BTK run-off†	21 (25.6)	5 (31.2)	0.875
Intraluminal wiring	61 (74.4)	7 (43.8)	0.033
Atherectomy	28 (34.1)	3 (20.0)	0.436
Preballoon diameter, mm	5.0 ± 0.9	5.3 ± 0.5	0.196
Preballoon pressure, mmHg	11.8 ± 4.1	11.4 ± 2.5	0.673
Mean DCB diameter, mm	5.6 ± 0.6	5.6 ± 0.7	0.943
Maximum DCB diameter, mm	5.8 ± 0.7	5.7 ± 0.8	0.768
Bailout stenting	14 (17.1)	8 (50.0)	0.010
Adjuvant ballooning	14 (17.1)	7 (43.8)	0.041
Dissection	50 (61.0)	8 (50.0)	0.590
Residual stenosis > 30%	19 (23.2)	5 (32.2)	0.072
Technical success			0.072
Suboptimal	19 (23.2)	5 (32.2)	
Successful	63 (77.8)	11 (8.8)	
Postprocedural ABI	1.01 ± 0.12	0.89 ± 0.10	0.001

Continuous values are presented as mean ± standard deviation, and categorical variables are presented as number (%).

* Peripheral artery calcium scoring system (PACCS) 3 and 4.

† Number of patent arteries below the knee artery = 0 or 1.

Abbreviations: ABI = ankle-brachial index; BTK = below the knee; DCB = drug-coated balloon; SFA = superficial femoral artery; TASC = Trans-Atlantic Inter-Society Consensus.

Turns out Size (MLA) Mattered

Table 3
Pre- and postprocedural IVUS data

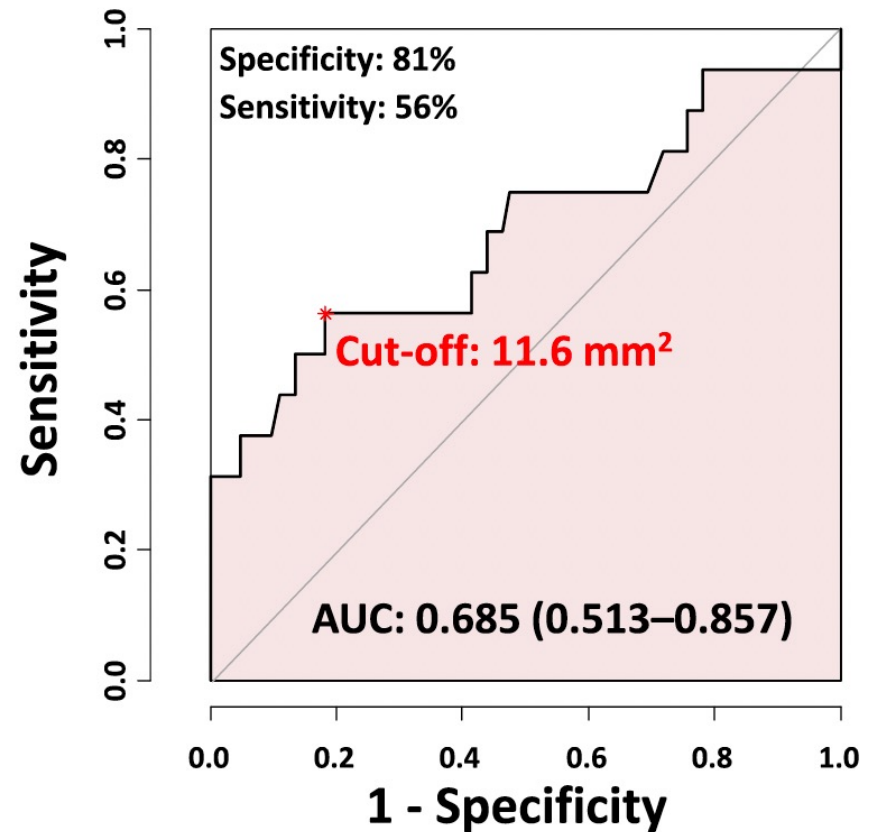
Values	Patency-maintained (n = 82)	Patency-loss (n = 16)	p-value
Proximal reference EEM area, mm ²	40.52 ± 12.52	44.83 ± 12.99	0.213
Proximal reference lumen area, mm ²	23.29 ± 7.83	25.98 ± 11.79	0.253
Distal reference EEM area, mm ²	29.09 ± 7.21	32.54 ± 9.40	0.100
Distal reference lumen area, mm ²	16.73 ± 4.86	18.08 ± 7.64	0.362
Mean reference EEM area, mm ²	34.80 ± 8.49	38.69 ± 10.78	0.113
Mean reference lumen area, mm ²	20.01 ± 5.37	22.03 ± 8.29	0.214
Intraluminal wiring	59 (72.0)	9 (57.2)	0.342
Calcium.angle >270, number (%)	21 (25.6)	5 (31.2)	0.875
EEM area ate MLA site, mm ²	32.93 ± 7.56	35.00 ± 8.66	0.330
MLA, mm ²	13.64 ± 2.86	11.34 ± 4.44	0.009
Plaque burden* at MLA site (%)	57 ± 10	68 ± 9	<0.001
MLA / Mean reference EEM area†	0.41 ± 0.11	0.30 ± 0.12	0.001
Edge dissection	34 (41.5)	8 (50.0)	0.723
Dissection length > 50% of lesion length	3 (3.7)	2 (12.5)	0.396
Dissection circumference > 180°	8 (9.8)	6 (37.5)	0.012

Continuous values are presented as mean ± standard deviation, and categorical variables are presented as number (%).

* Plaque burden: (EEM area – lumen area)/EEM area × 100%.

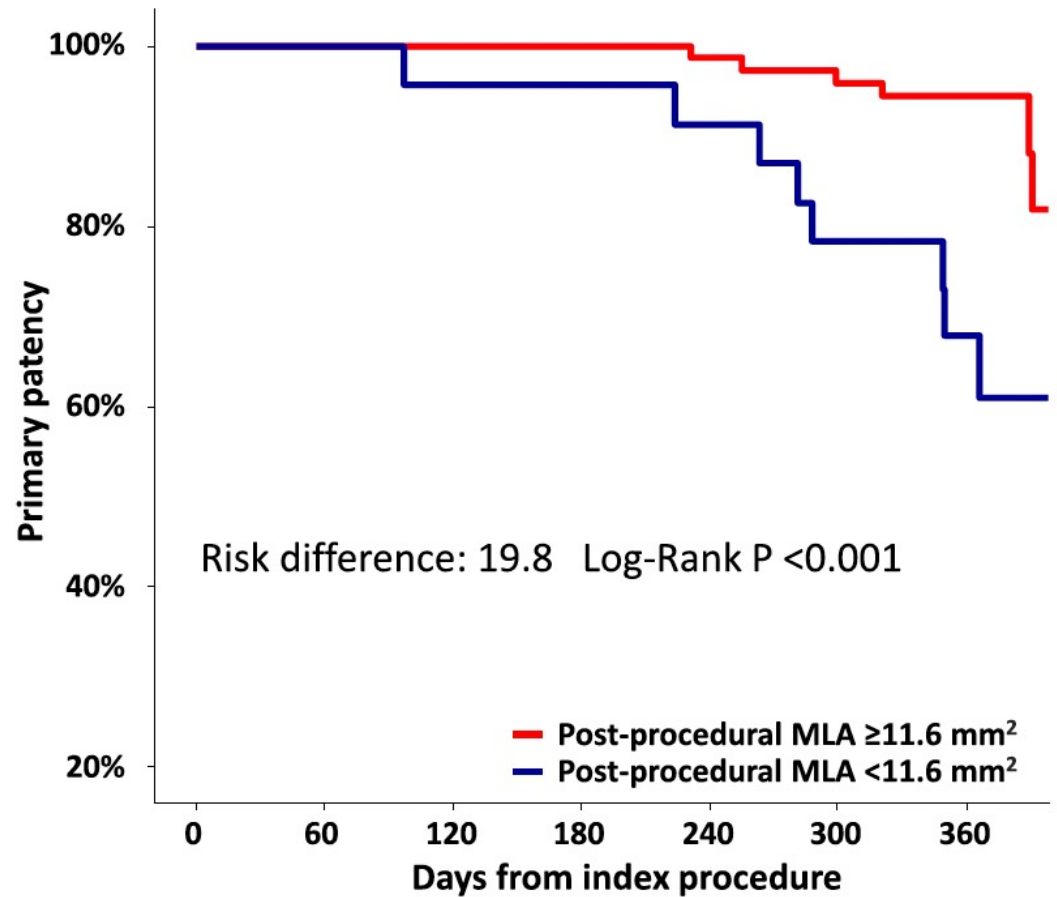
† Mean reference area: (Proximal reference vessel EEM or lumen area + distal reference vessel EEM or lumen area)/2.

Abbreviations: EEM = external elastic membrane; MLA = minimum lumen area.



MLA-Related Patency Loss

- **>11.6mm** at the end of case had better **12-month primary patency**



Limits

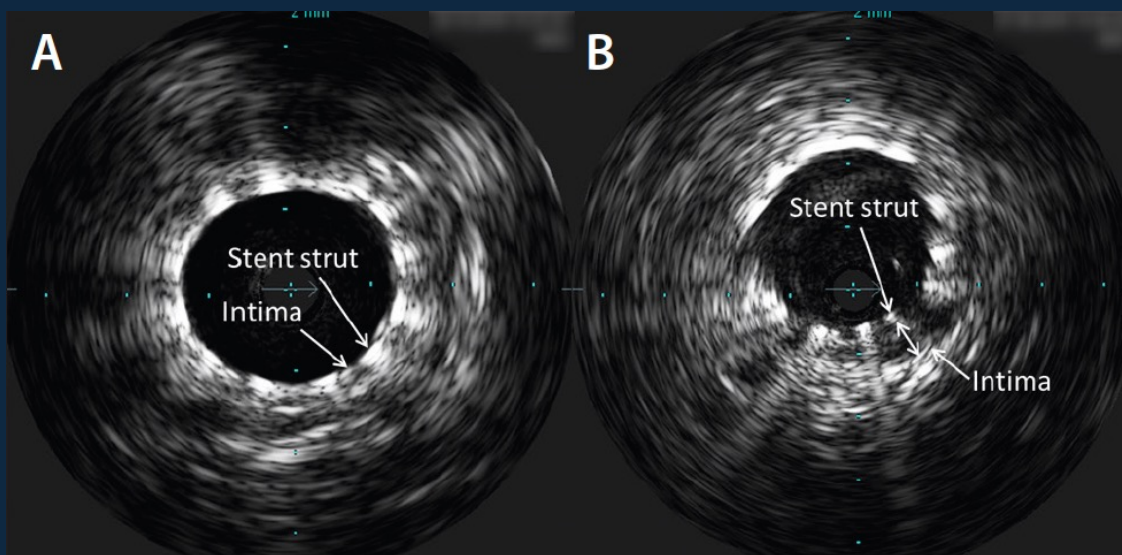
- Small **N** of patients
- DCB-only approach
- Specific set of patients (Korean)

Summary

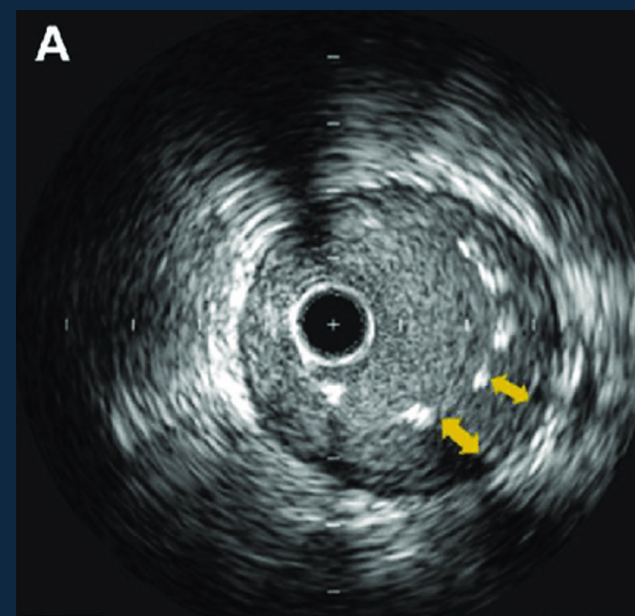
- Using IVUS resulted in larger balloons and more aggressive dilation
- Result was larger post-lumen diameter
- This translated to increased patency

Why would it matter in “ISR?”

Under-expanded and improperly sized stents



Under-expanded



Under-sized stent

In Summary

Only a fool operates in the dark when light is available

IVUS helps find dissections, vessel size, landing zones, and can help prevent negative sequelae

Continuing data showing outcome benefits of IVUS in femoral popliteal interventions

There is consensus on IVUS use and studies showing its benefits



Laser Atherectomy for PAD

Elizabeth Genovese, MD, MS, FACS

Assistant Professor of Surgery

Penn Advanced Limb Preservation Program, Director at HUP

Division of Vascular Surgery and Endovascular Therapy

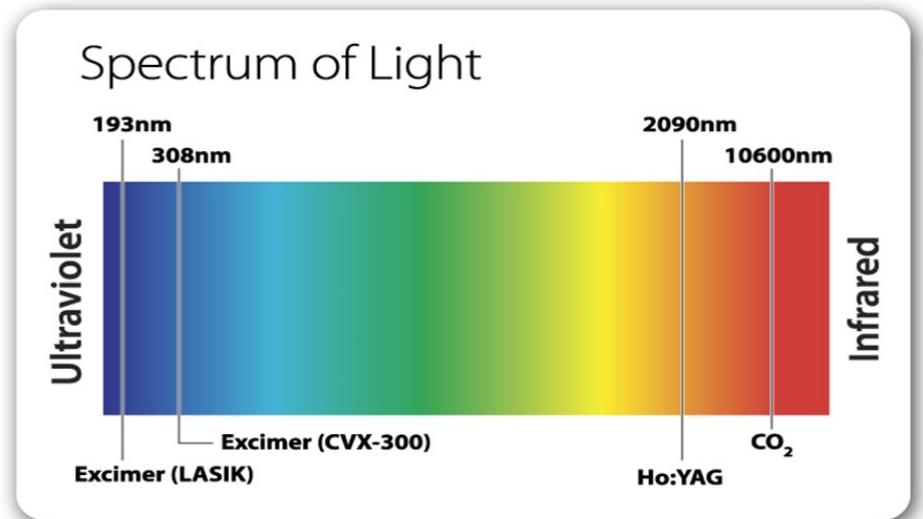
University of Pennsylvania

Laser Atherectomy

Laser atherectomy



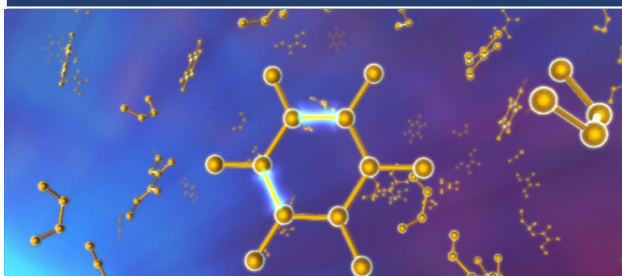
Ultraviolet → Infrared
Cool → Hot



Photoablation

① Light Pulse

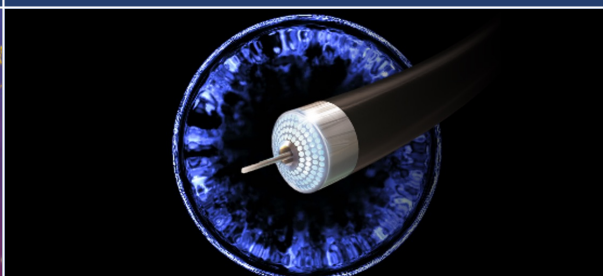
Ablates mixed morphologies at molecular level



Safe in all lesion types

② Sonic Wave

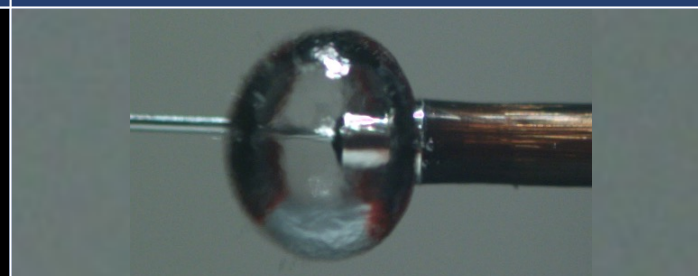
Impacts hard materials and changes vessel compliance



Affects both luminal and medial disease

③ Cavitation Bubble

Debulks mixed morphologies and breaks down materials



Debulking for luminal gain

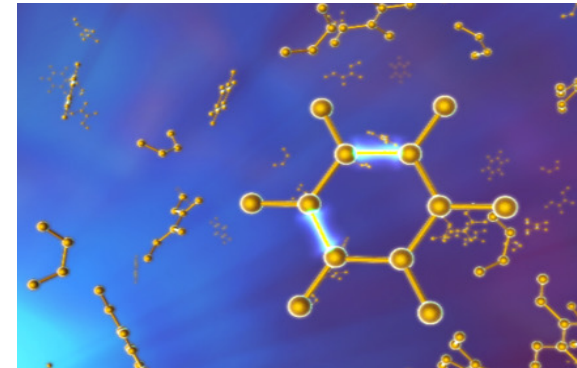

1

Light Pulse

Light Pulse

Absorbed by Plaque

Breaks Molecular Bonds



What It Is	Why It Matters
UV light pulsed for 135 billionths of a second	High energy, cool
50-100 micron penetration depth	Impacts material directly in front of the catheter
Material broken down at atomic level	Low embolization risk

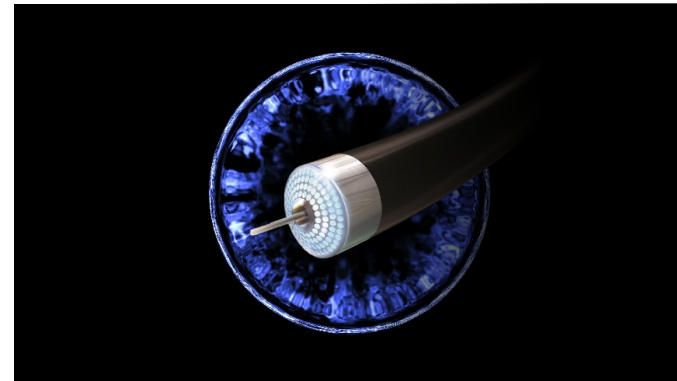
2

Sonic Wave

Sonic Wave

Impacts Hard Material

Changes Vessel
Compliance



What It Is	Why It Matters
High-pressure sonic wave	Impacts surrounding material
Expands out in all directions	Intraluminal and medial impact
Passes through soft materials, impacts hard materials	Microfractures in calcium, changes compliance



3

Cavitation Bubble

Cavitation Bubble

Expand and Collapse

Debulks Plaque

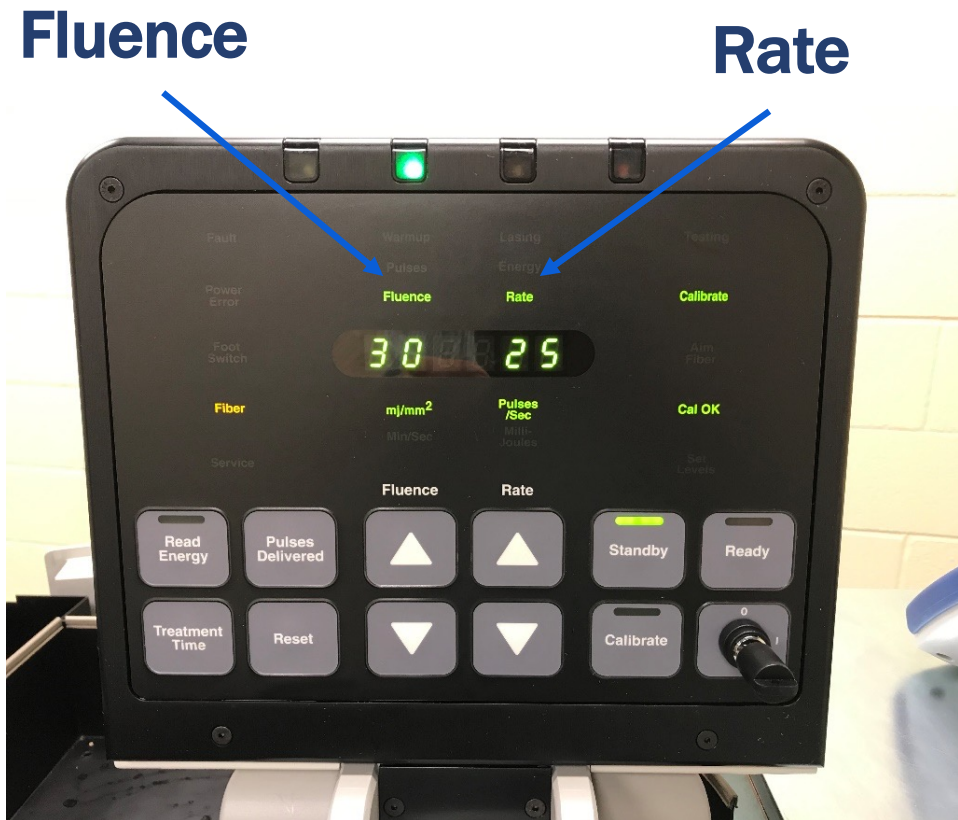

What It Is	Why It Matters
Low-pressure vapor bubble created by high-pressure sonic wave	Vaporizes material with low pressure: NO high temperatures!
Expands and collapses at the tip of the laser	Does not send bubbles downstream
Macerates plaque into particles at cellular level, smaller than a red blood cell	Low embolization risk

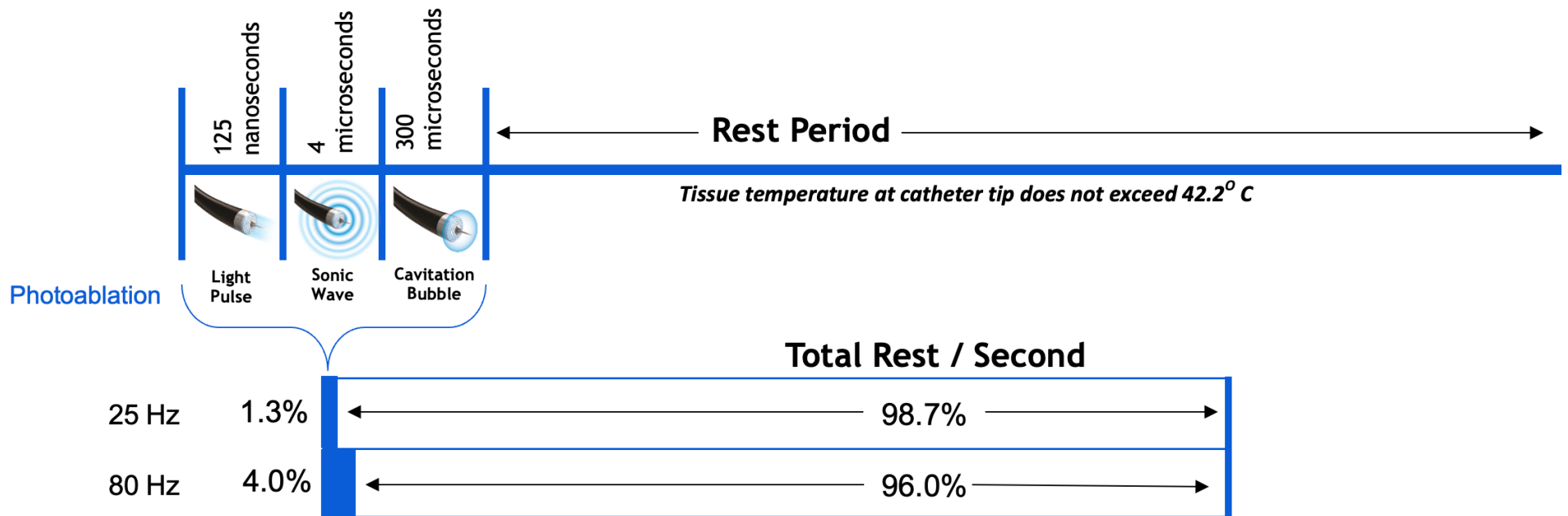
Energy Modulation of Photoablation

Can control 2 energy factors that affect photoablation

- **Fluence:** mj/mm^2
- **Rate:** Pulses/Sec



Timeline of a Single Laser Pulse




• Rate = $\frac{\text{Pulses}}{\text{Second}}$

1 sec

25
Second

50
Second

80
Second



Fluence = $\frac{\text{Energy}}{\text{Area}}$

25

40

60

80

3 ways to affect Photoablation, Sonic Intensity, and Cavitation Size

Device Size

Changing the catheter itself,
which changes the fiber area

Fluence (Energy / Area)

Changing the amount of light
delivered from a catheter (energy)

Ablation Medium

Changing what the light is
delivered into (absorption)

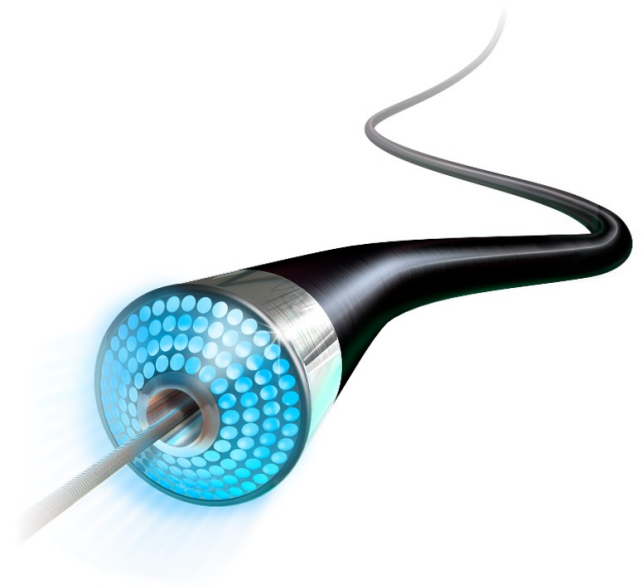
Catheter Size

Changing the area available for energy delivery

$$\text{Fluence} = \frac{\text{Energy}}{\text{Area}}$$


$$\text{Energy} = \text{Area} \times \text{Fluence}$$

Catheter	Optical Area (mm ²)	Fluence (mj/mm ²)	Energy Output (mj)
0.9 TE OTW	0.124	80	10
1.4 TE OTW	0.308	60	18
1.7 TE OTW	0.507	60	30
2.0 TE OTW	0.778	60	47
2.3 TE OTW	1.201	60	72




System Fluence

Changing the energy delivered for a given catheter size




30 Fluence




60 Fluence

Medium of Ablation

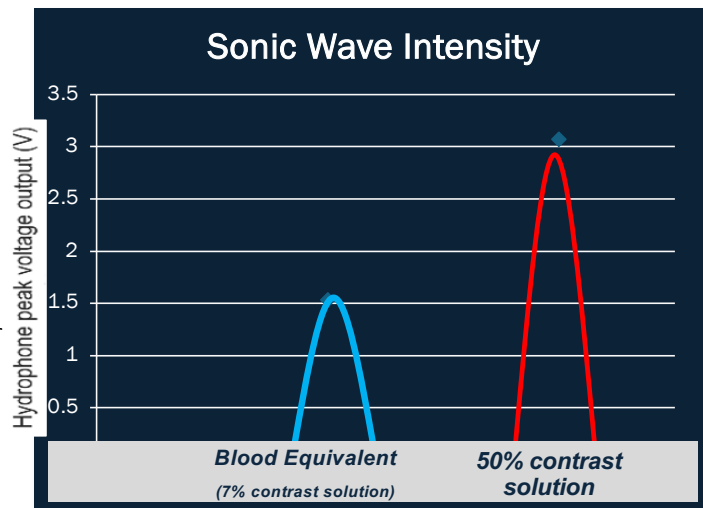
2.0mm Laser in Blood Equivalent



2.0mm Laser in Contrast

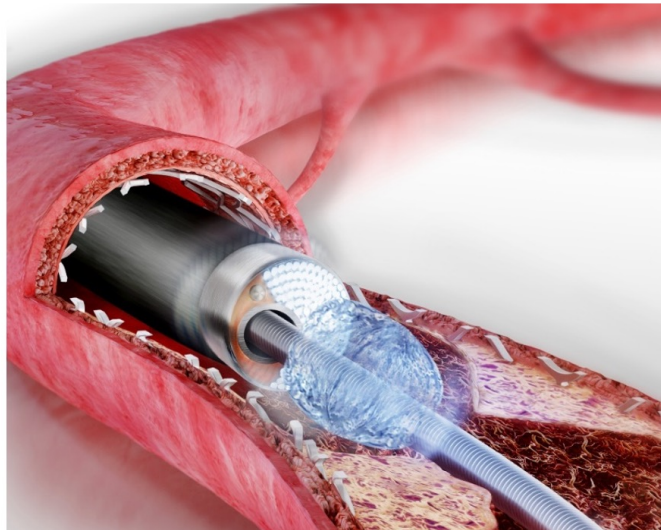


Bubble Size
directly proportional to
Sonic Wave Intensity



Advancement Speed

Optimal ablation speed is no more than 1mm per second



- Catheter tip size only one variable impacting luminal gain
- Acoustic wave and Cavitation bubble conveys energy beyond outer edge of catheter tip

4 Variables to Control

- Fluence
 - Higher fluence = more energy = more molecules broken = larger bubble
- Rate
 - Higher rate = more shots per second
- Catheter size
 - Larger catheter size = more fibers = more light = more energy = larger bubble
- Speed
 - Slower speeds = more work done by laser in single spot = better results

Intravascular Ultrasound in Arterial Interventions

Vessel Size

- Reference vessel diameter
- Luminal diameter
- Plaque burden

Plaque Morphology

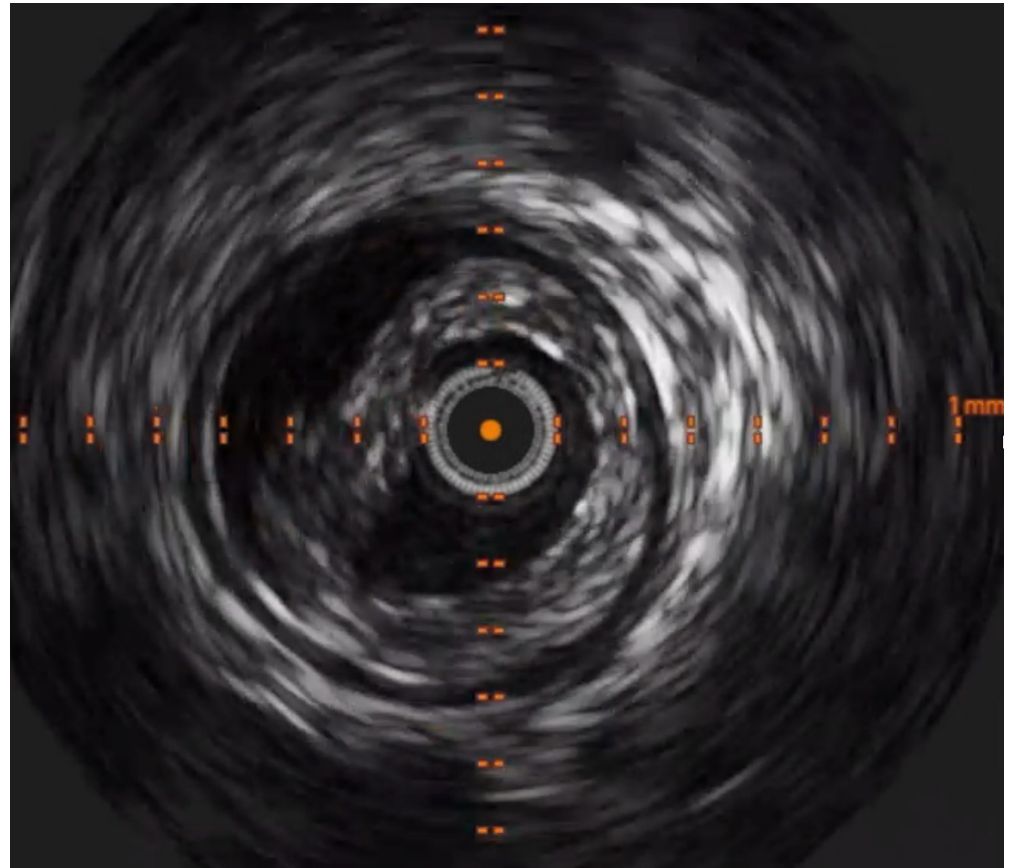
- Calcium
- Soft plaque
- Mobile
- Thrombus
- Dissection

Plaque Geometry

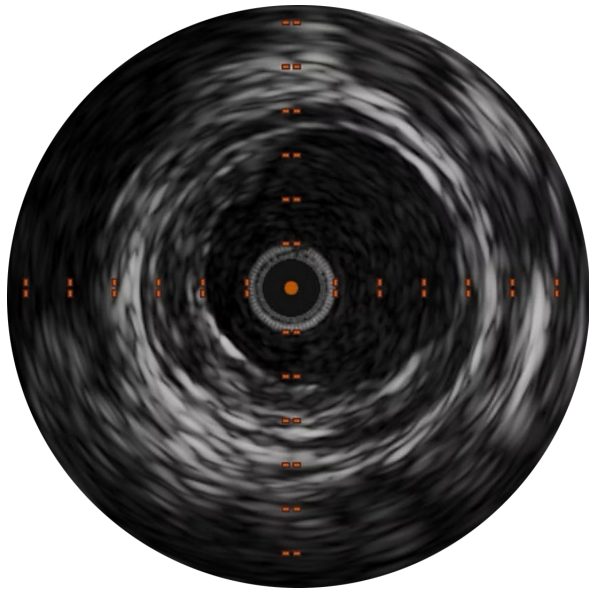
- Concentric
- Eccentric

Guidewire Position

- True Lumen
- Subintimal

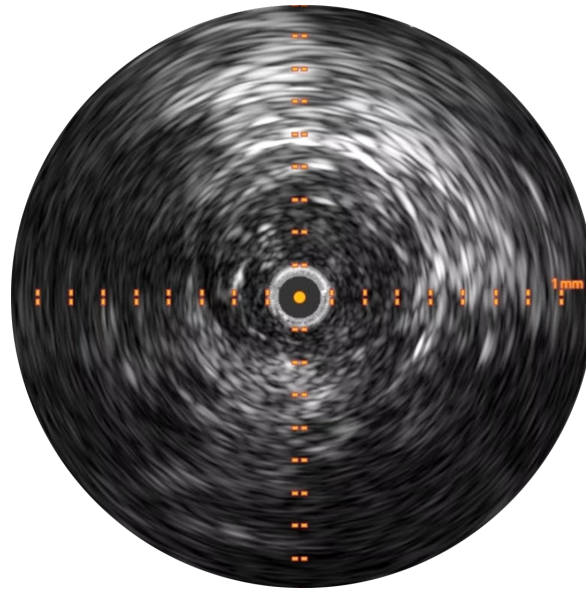


Plaque Morphology



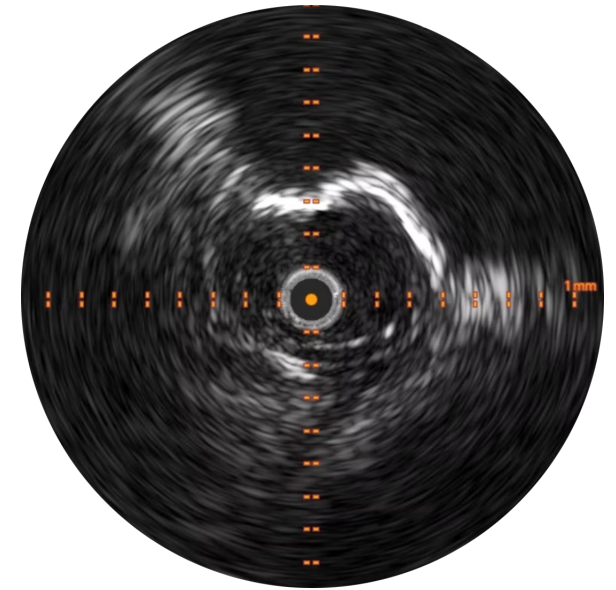
Soft Plaque

Low echogenicity, lipid-rich core
with potential rupture risk



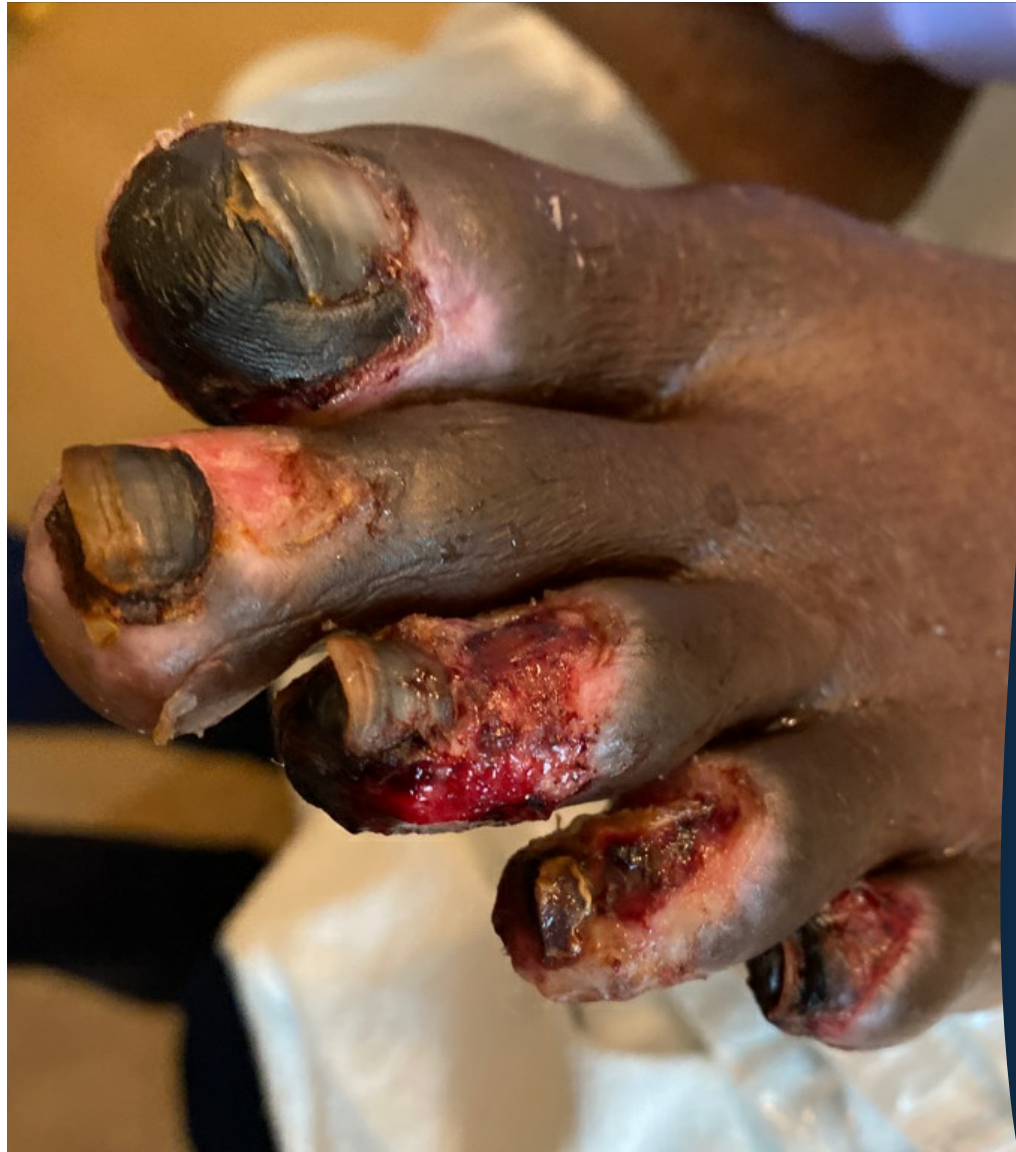Fibrous Plaque

Homogeneous, intermediate echogenicity
with dense collagen



Calcific Plaque

Bright echogenic appearance
with acoustic shadowing

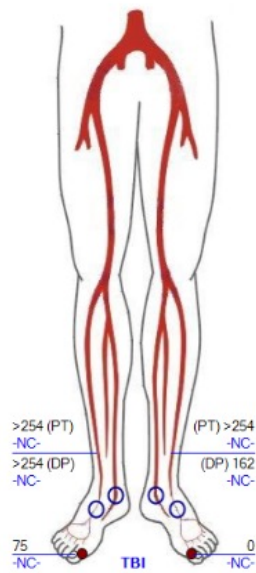
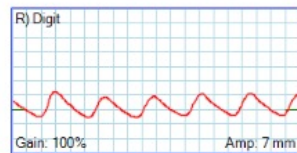
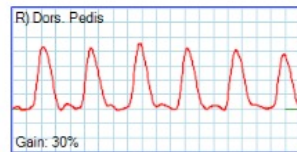
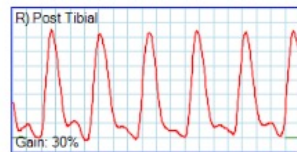
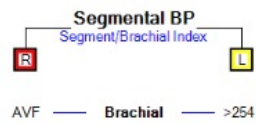

HPI

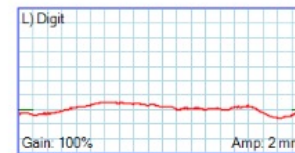
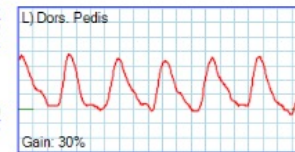
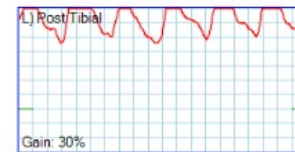
- 51y Male with hx of long-term dialysis and diabetes with severe PVD. He has undergone multiple endovascular interventions in LLE for non-healing wounds
- PMHx: DM, ESRD, HTN, PAD
- PSHx: Prior left PT and AT angioplasty

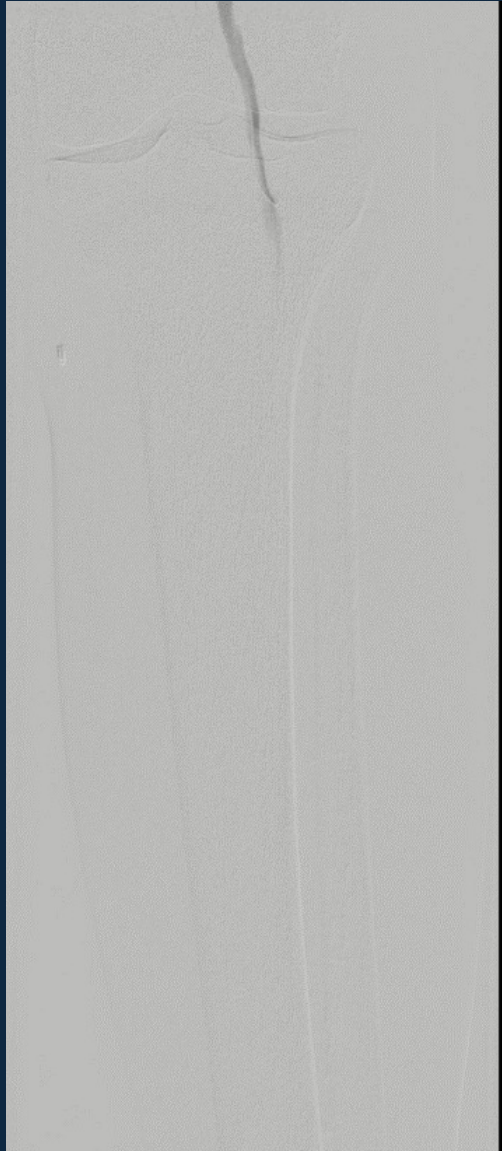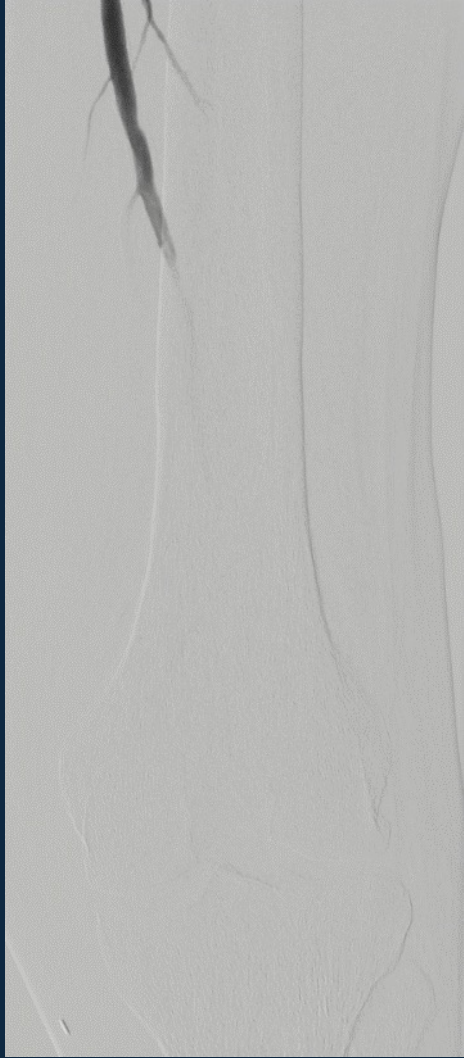
HPI

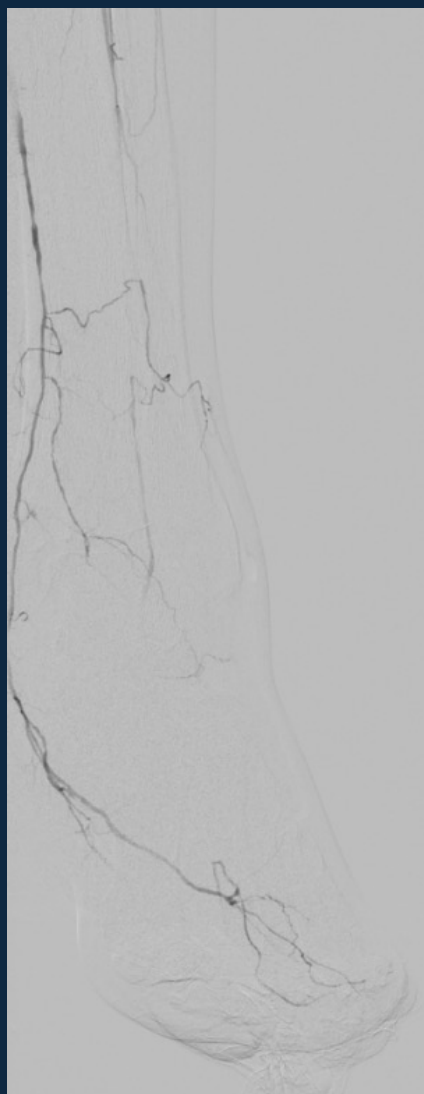
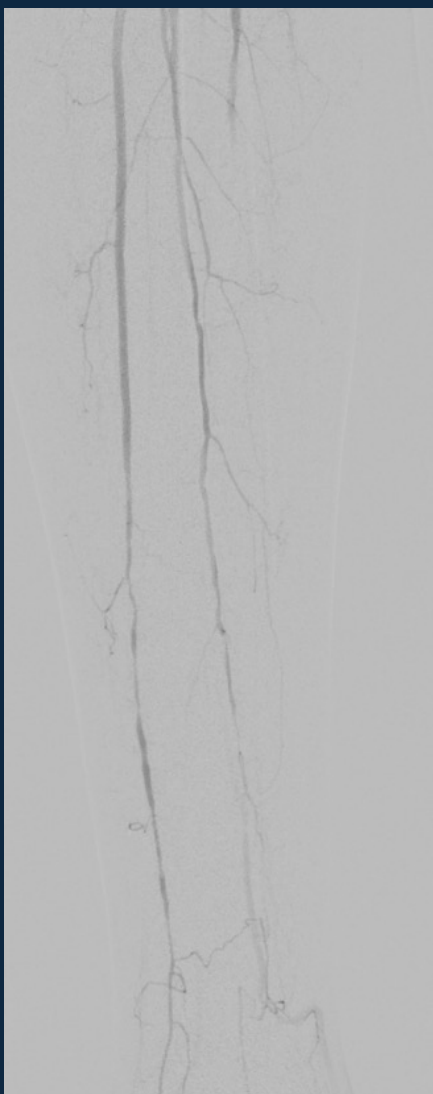
Doppler

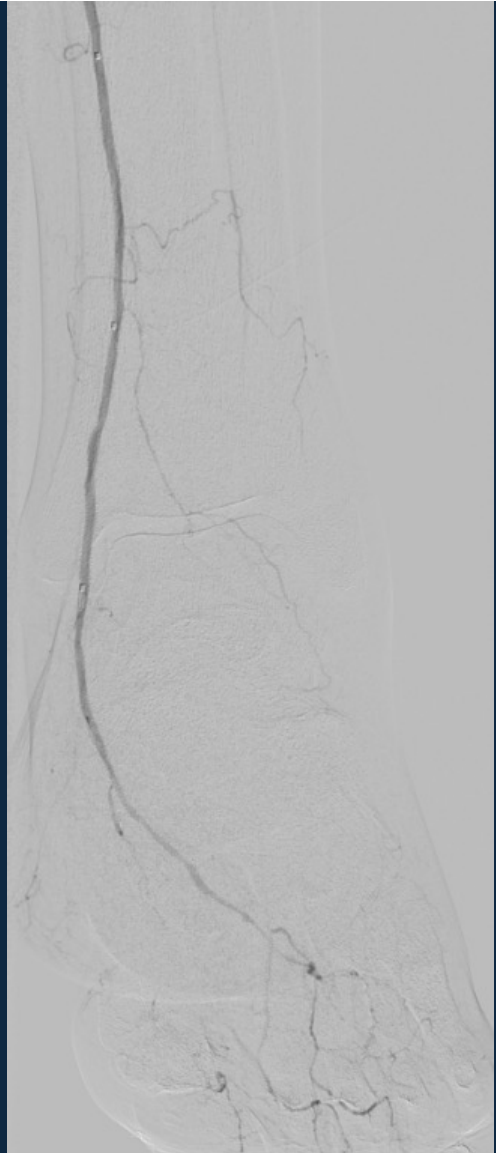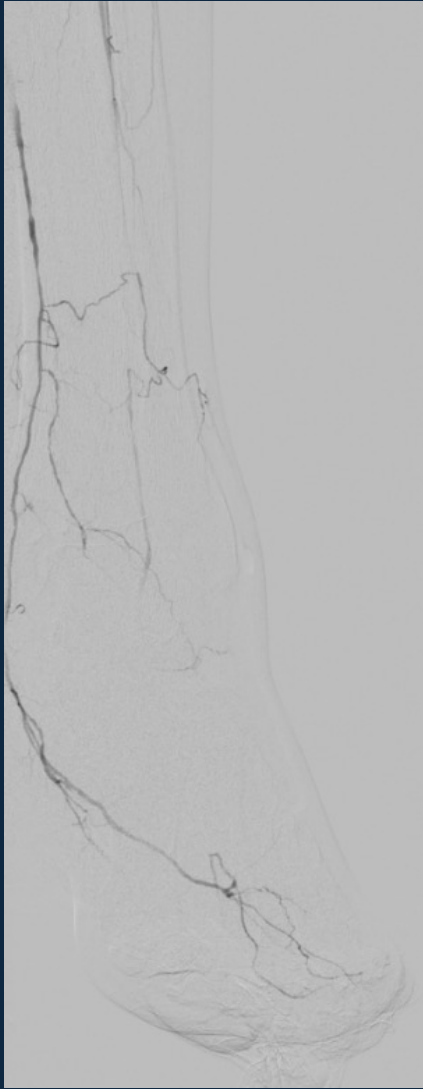

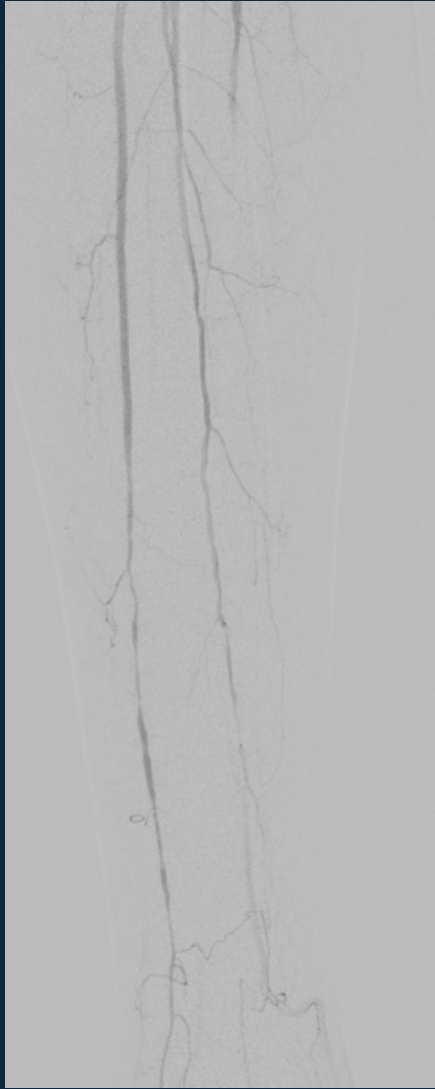
Ankle/Brachial Index

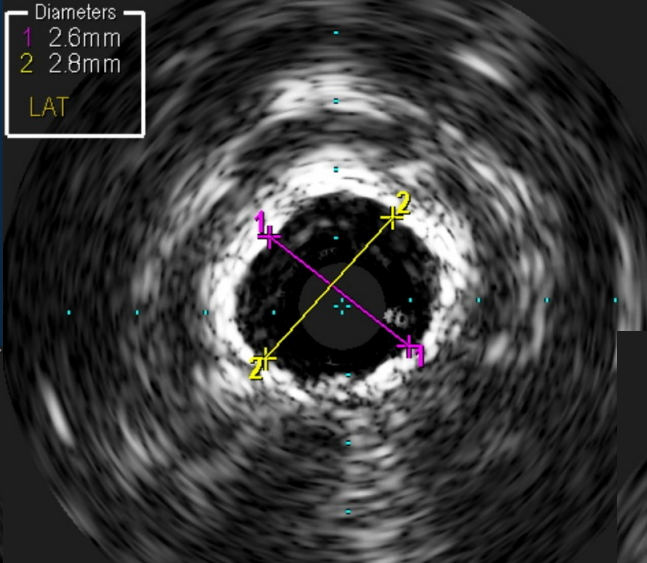




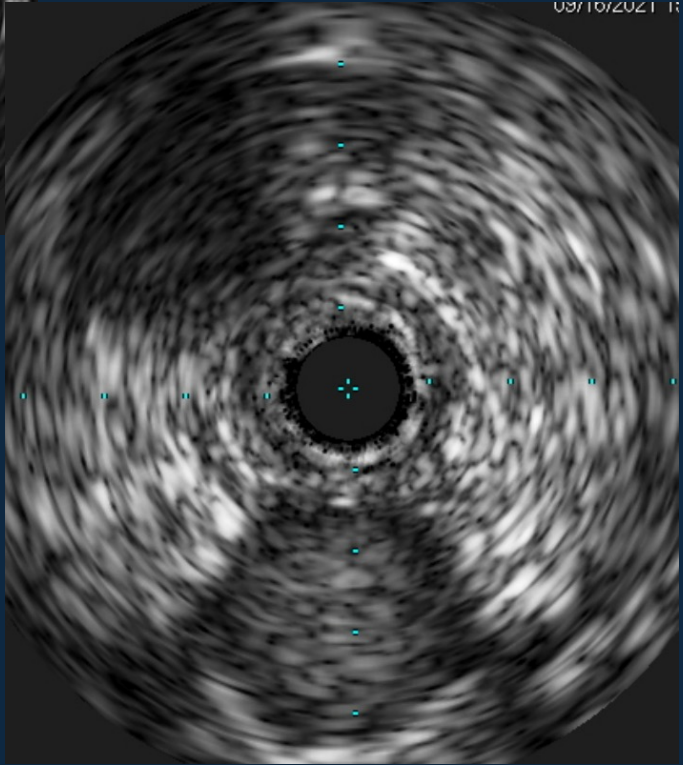
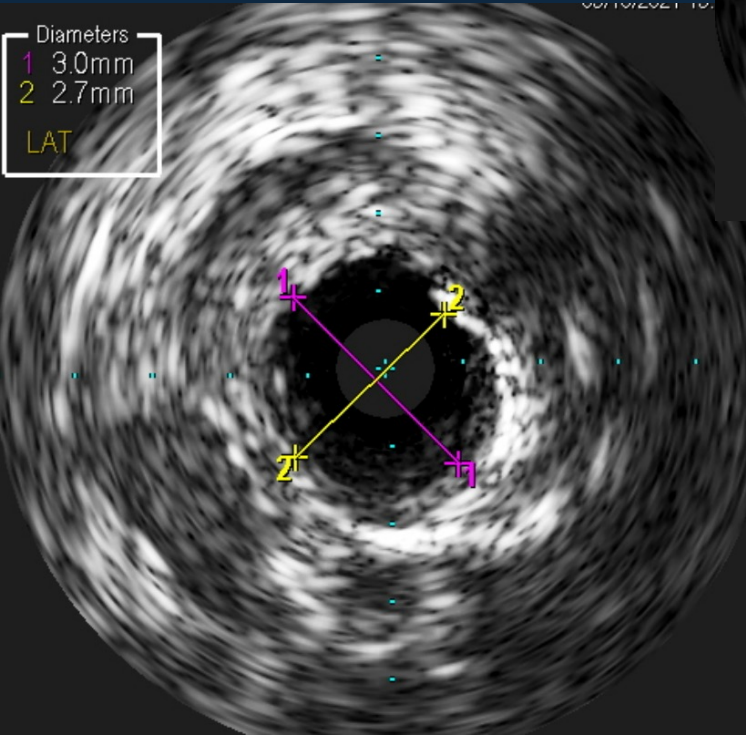




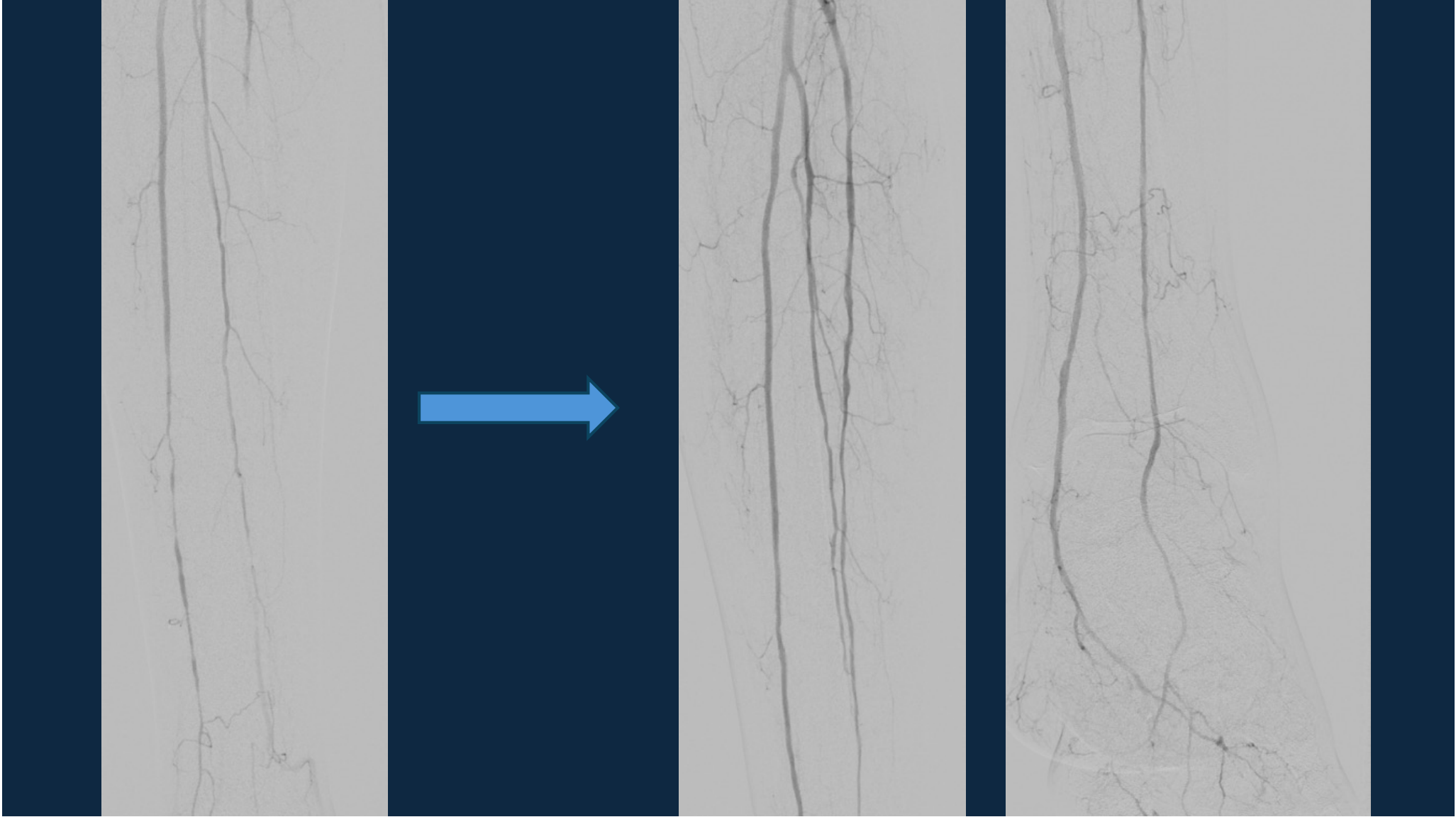
Diameters
1 2.6mm
2 2.8mm
LAT

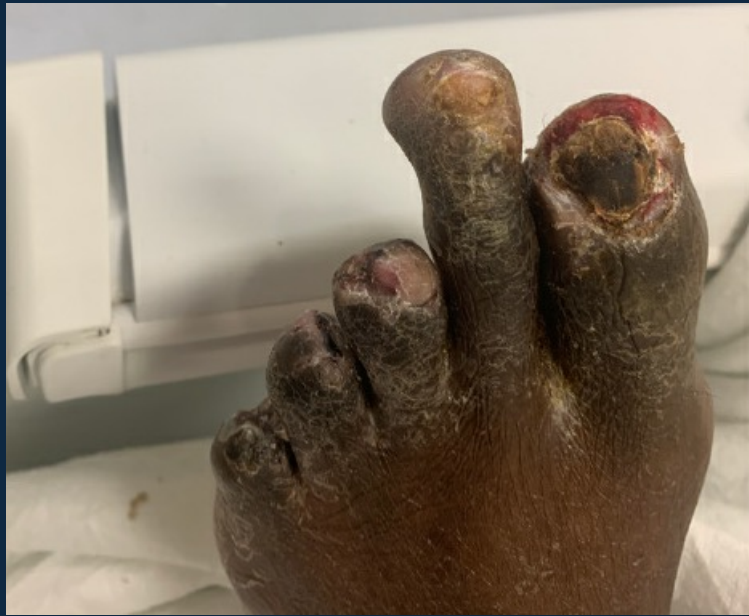

Diameters
1 3.0mm
2 2.7mm
LAT



03/10/2021 11






Intravascular Lithotripsy


- Laser can be used to treat a wide variety of lesion morphologies but is less resistant on calcified lesions → Medium is Blood (decreased sonic wave)
- IVL uses sonic pressure waves to target and fracture calcified plaques within the arteries
- IVL is now a first-line option for vessel preparation in complex calcified PAD, improving procedural predictability and long-term patency

THOR IDE Trial

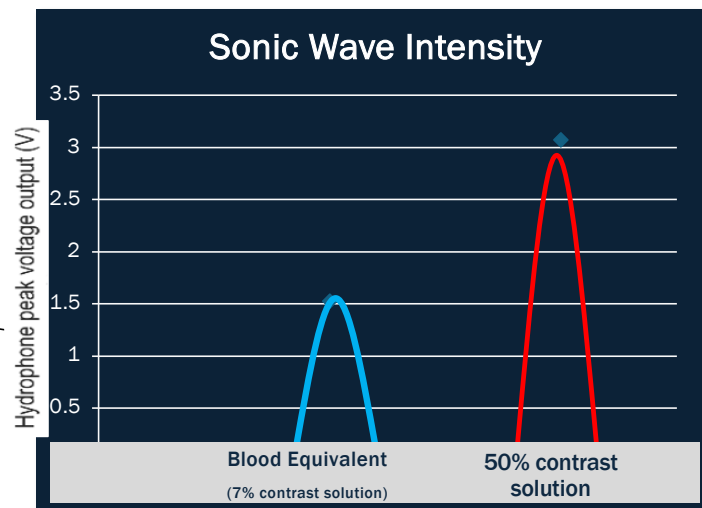
2.0mm Laser in Blood Equivalent



2.0mm Laser in Contrast



**Bubble Size
directly proportional to
Sonic Wave Intensity**




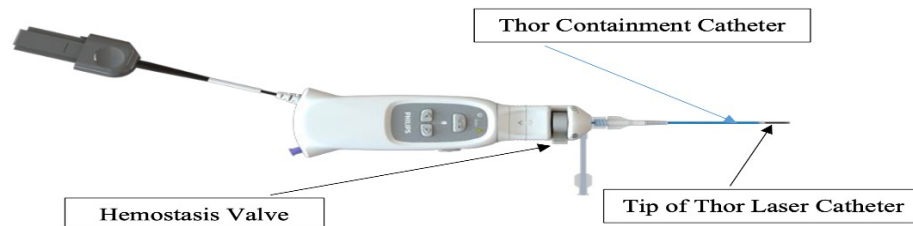
THOR IDE Trial

- **Thor System Components**

- Thor Laser Catheter (1.6mm & 1.8mm)
- Thor Containment Catheter

- **Modes of Operation**

- Forward Facing Atherectomy Mode
- Calcium Modification Mode



CAUTION: Investigational Device. Limited by Federal (United States) law to investigational use

THOR IDE Clinical Study Overview

- **Primary Objective:** To evaluate the safety and efficacy of the Thor Laser Atherectomy System for treating *de novo* calcified infrainguinal lesions in PAD patients
- **Design**
 - Prospective, single-arm, multicenter, open-label
 - Conducted under FDA IDE approval
 - 155 subjects at up to 30 US sites
- **Device**
 - Thor Laser Atherectomy System
 - Turbo-Power based catheter + containment sheath
 - **Clinicaltrials.gov: NCT05916950**

Primary Safety Endpoint

Primary safety endpoint: Freedom from major adverse events through 30 days post-index procedure, defined as the composite of

- All-cause mortality
- Clinically-driven target lesion revascularization
- Unplanned target limb major amputation
- Peri-procedure perforations, flow-limiting dissections, and symptomatic distal embolizations that require an intervention to resolve

Primary Efficacy Endpoint

Primary efficacy endpoint: **Procedural success**, defined as residual diameter stenosis $\leq 50\%$ at the end of the procedure as determined by the angiographic core lab

Key Clinical Inclusion and Exclusion Criteria

Inclusion Criteria

- Age ≥ 18
- Able to walk unassisted or with non-motorized aid
- Rutherford Class 2–4 PAD symptoms
- Life expectancy >12 months
- Signed informed consent

Exclusion Criteria

- Active infection or recent Myocardial Infarction/Cerebrovascular Accident
- Planned stenting or major amputation
- Severe renal dysfunction (creatinine ≥ 2.5 mg/dL)
- Pregnancy or breastfeeding
- Allergy to contrast media
- Participation in conflicting clinical trials

Key Clinical Inclusion and Exclusion Criteria

Inclusion Criteria

- *De novo* lesion in native SFA or popliteal artery
- Lesion stenosis $\geq 70\%$, length $\leq 150\text{mm}$
- Chronic Total Occlusion segment $< 100\text{mm}$, Vessel diameter $\geq 4.0\text{mm}$
- Successful guidewire crossing
- At least one patent tibial vessel
- Moderate to severe calcification (PARC criteria)



Exclusion Criteria

- Untreated inflow tract stenosis ($> 50\%$)
- Need to treat distal lesions during index procedure
- Focal or mild calcification
- Flow-limiting dissection after pre-dilation

THOR IDE Overview

Target Enrollment 155 Subjects	Current Enrollment 75 Subjects	Current Site Activations  27 sites	Target Total Site Activations Up to 30 sites	<ul style="list-style-type: none">• US only• Prospective• Multi-Center• Single-arm• Non-blinded
--	--	---	--	---

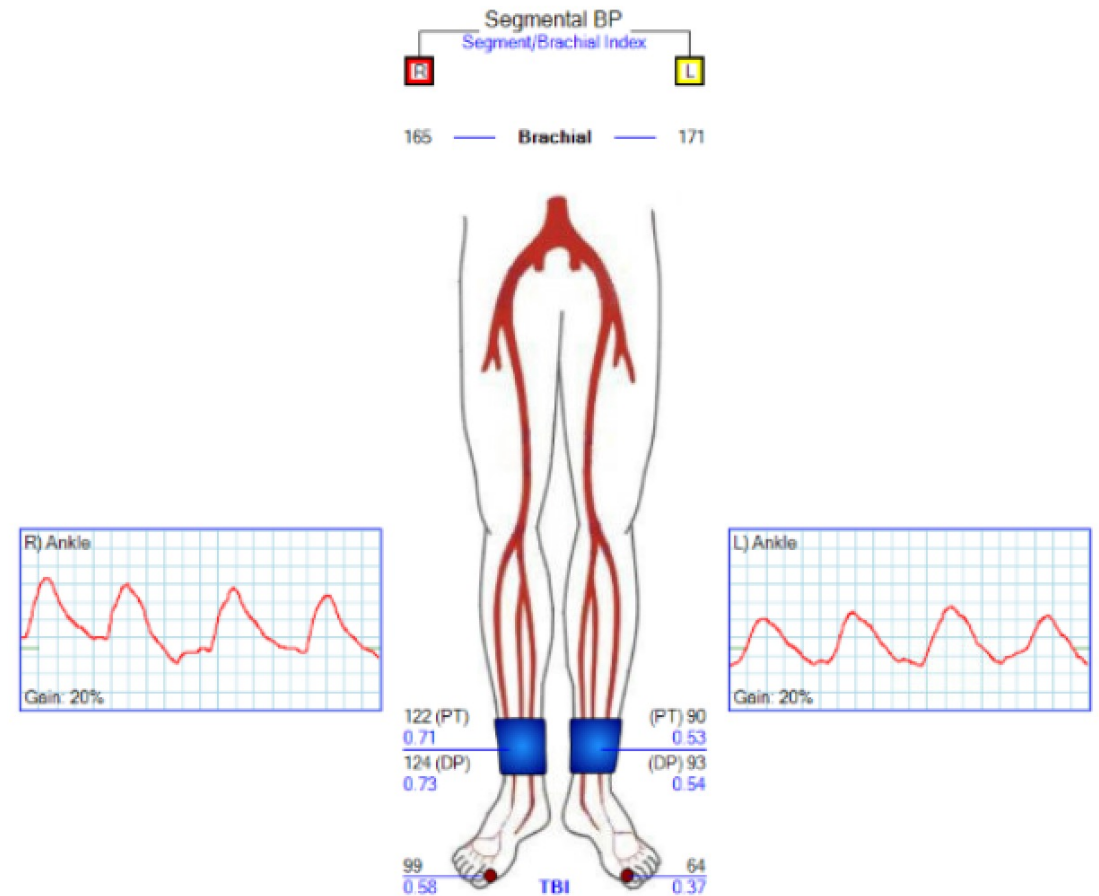
Maximum Enrollment per Site 23pts	<p>The objective of the Thor IDE study is to evaluate the safety and effectiveness of the Thor System in the treatment of <i>de novo</i> calcified lesions in native <u>infrainguinal arteries</u>* in patients with peripheral artery disease (PAD). The key objectives:</p> <ul style="list-style-type: none">- Demonstrate 30-day freedom from Major Adverse Events.- Demonstrate procedural success (defined as residual stenosis $\leq 50\%$ after completion of the procedure)
--	---

<p>Subjects with symptomatic claudication (RCC 2-4) with angiographic evidence of moderate to severe calcified lesions. Only one target limb and lesion will be treated and assessed.</p> 	<p>Treatment: The PI will be allowed to pre-dilate the target lesion using POBA. With the Thor System, the PI will perform forward facing laser atherectomy and then calcium modification mode.</p>	 <p>Follow-up Visits:</p> <ul style="list-style-type: none">• 30 days• 6 months• 12 months
--	--	--

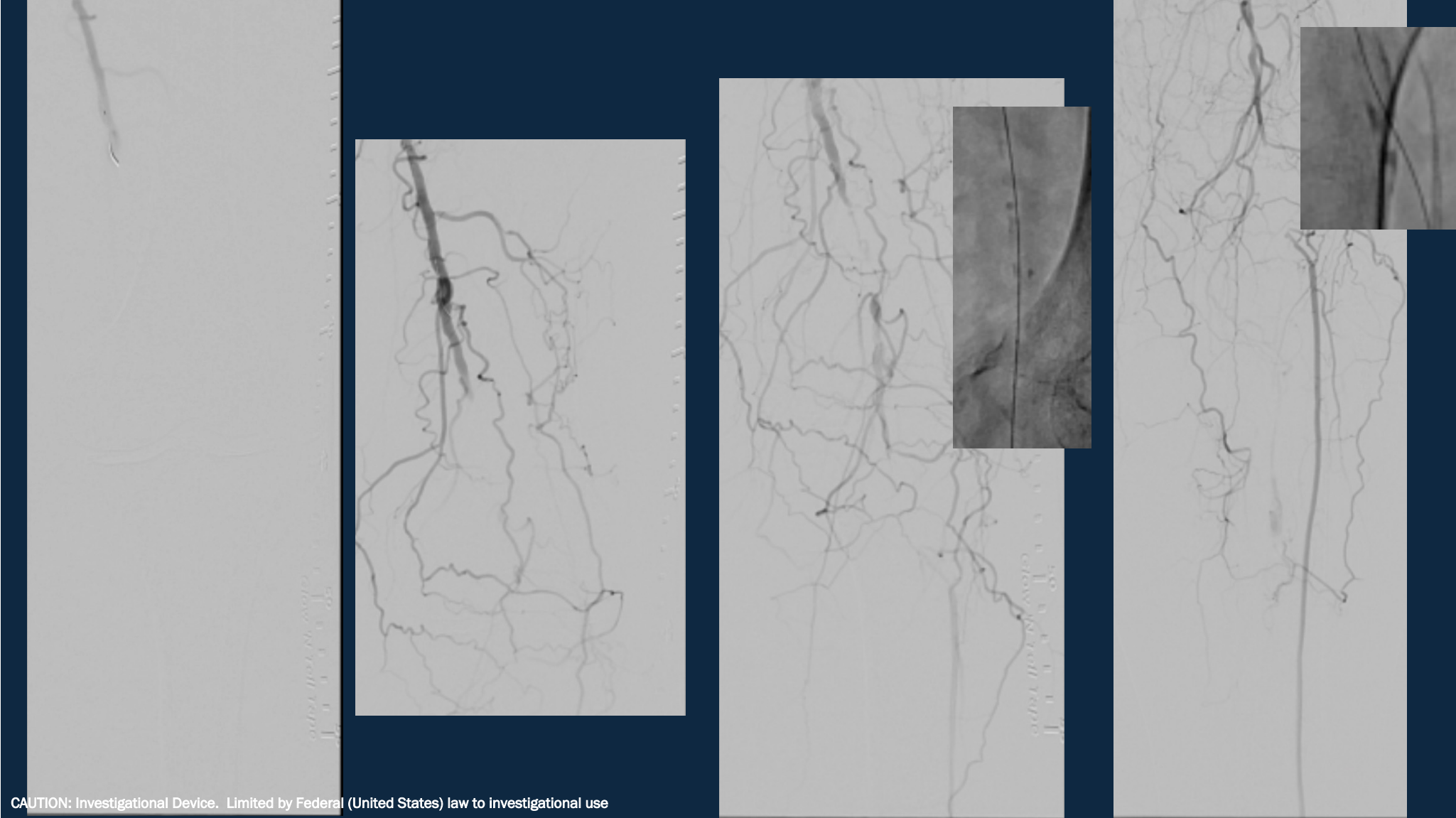
*Lesion locations include superficial femoral artery (SFA) and proximal popliteal (P1, P2, P3 as long as vessel diameter is larger than 4mm)

Case

- 88y Female with history of progressive LLE claudication; lives independently in NYC
- PMHx: HTN, HLD
- CTA demonstrated multifocal, eccentrically calcified SFA and pop occlusive disease

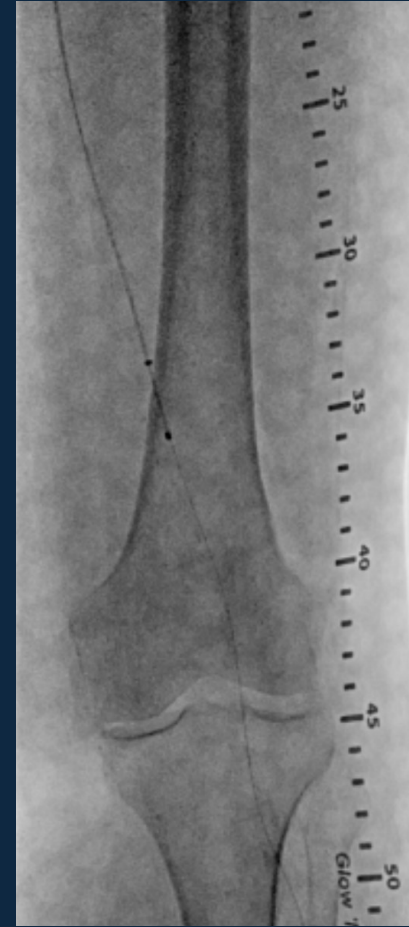
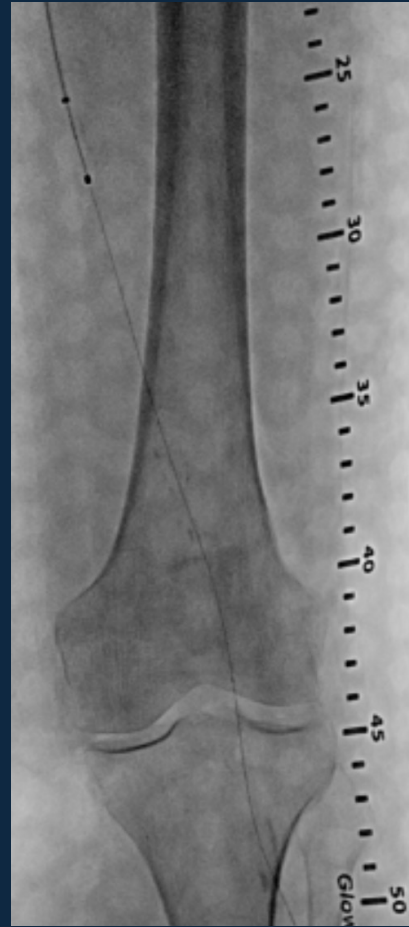
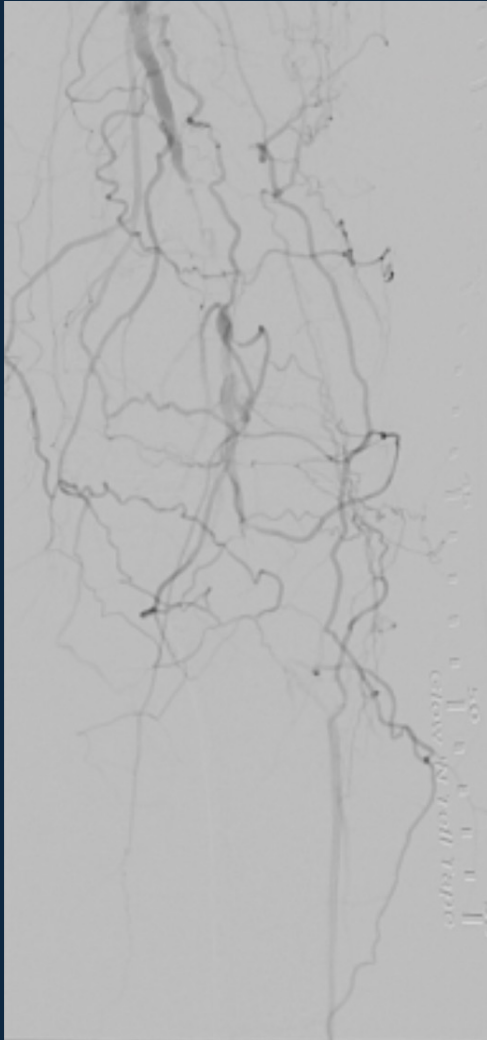


CAUTION: Investigational Device. Limited by Federal (United States) law to investigational use

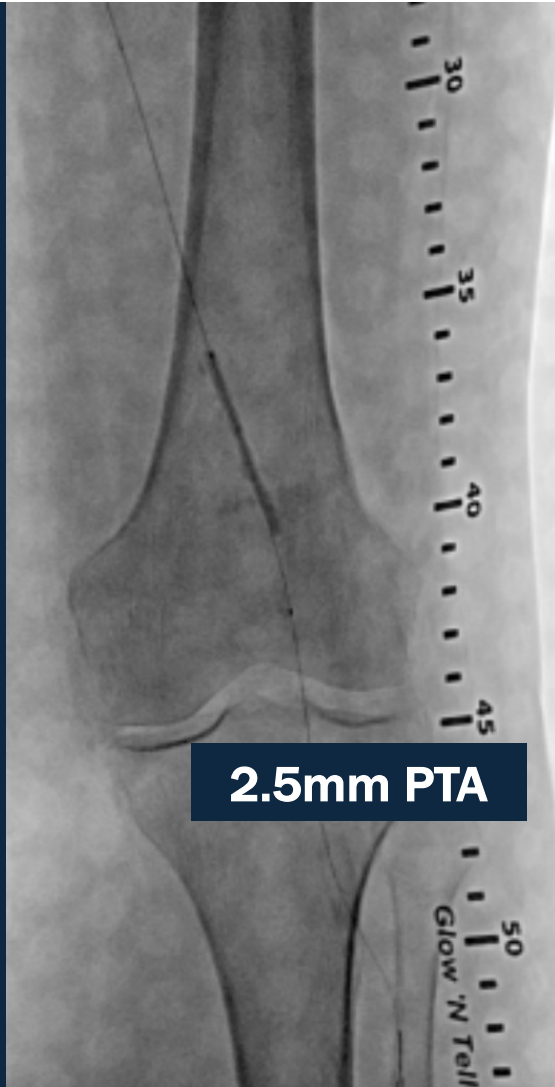


CAUTION: Investigational Device. Limited by Federal (United States) law to investigational use

3 Lesions, total length 140mm, CTO <100mm

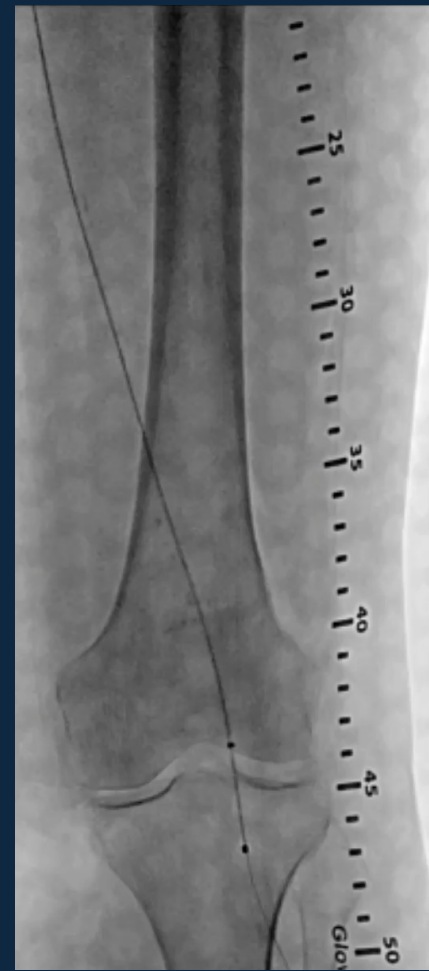
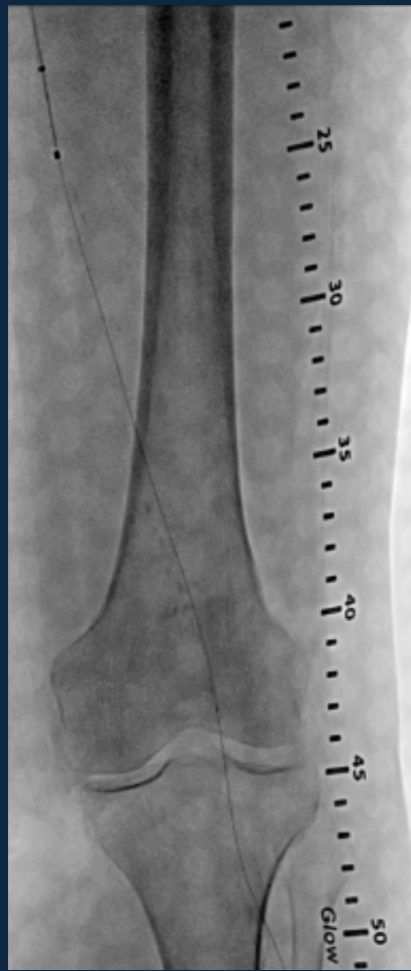
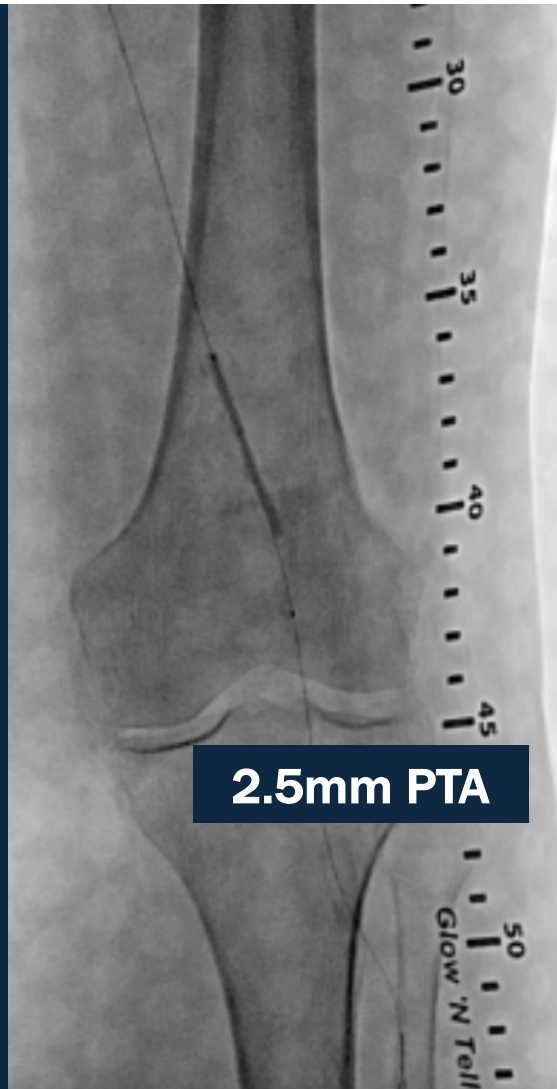


Forward Facing Atherectomy: 45/45, then 60/60

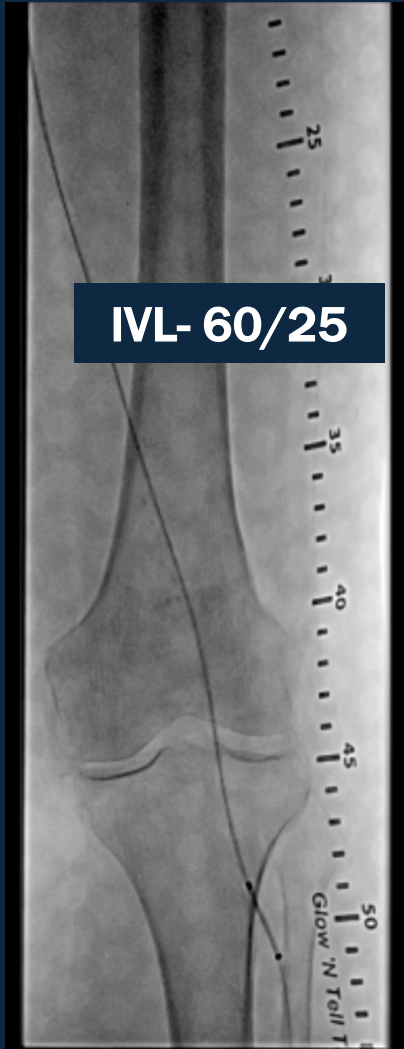


2.5mm PTA

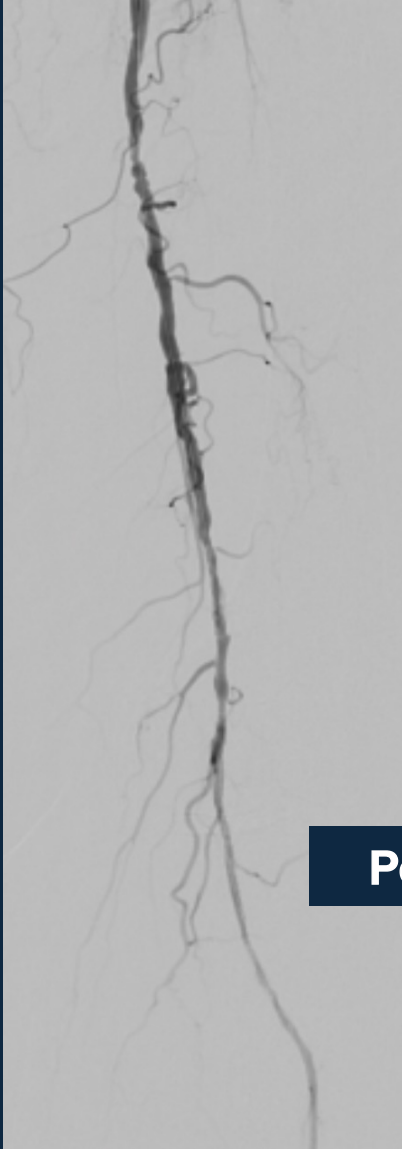
CAUTION: Investigational Device. Limited by Federal (United States) law to investigational use



Forward-Facing Atherectomy: 45/45, then 60/60



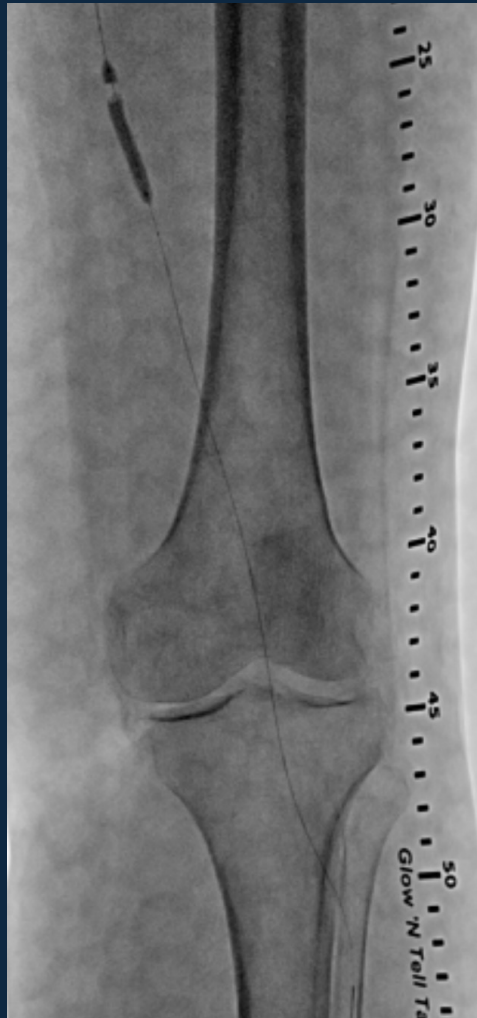
IVL- 60/25



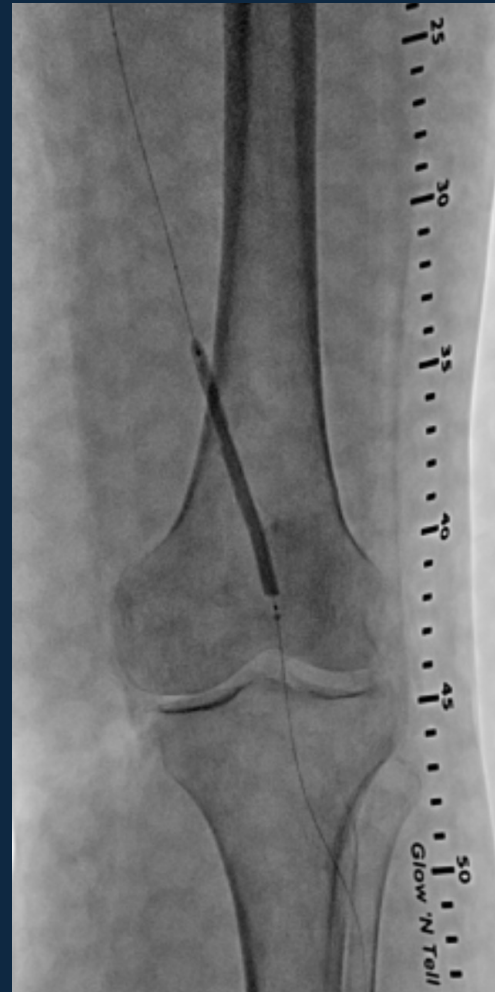
Post FFA and IVL

CAUTION: Investigational Device. Limited by Federal (United States) law to investigational use

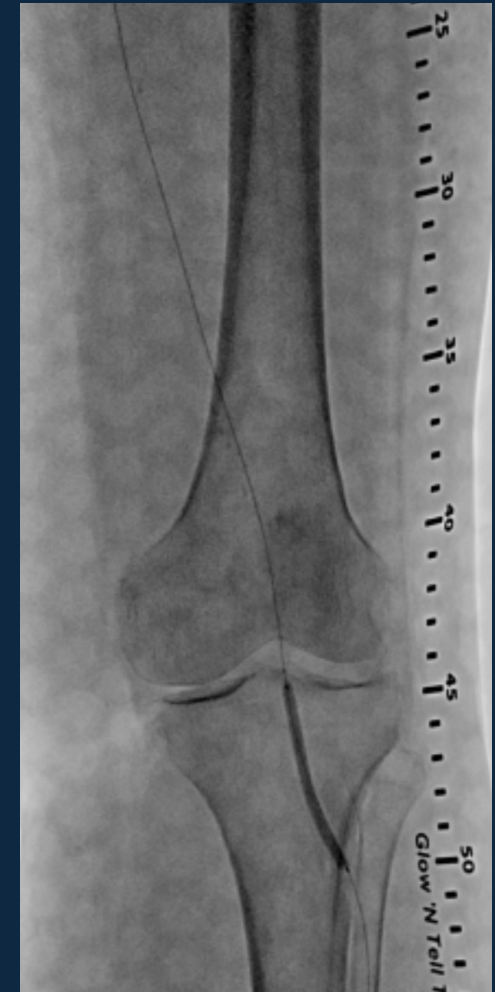
5mm x 40mm DCB



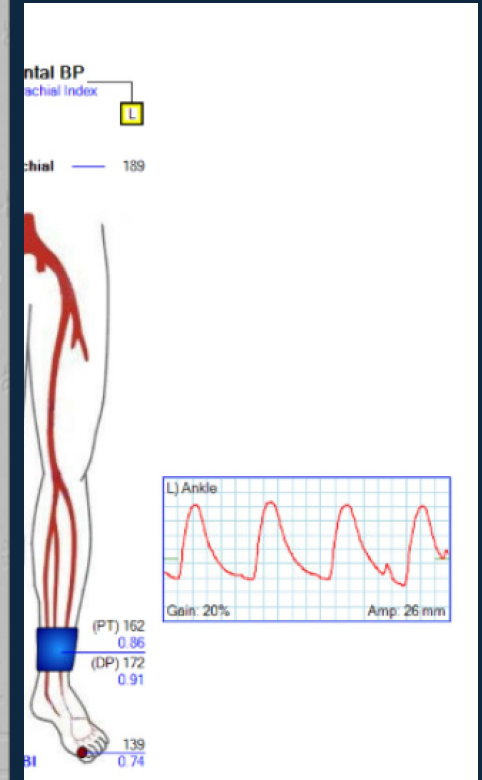
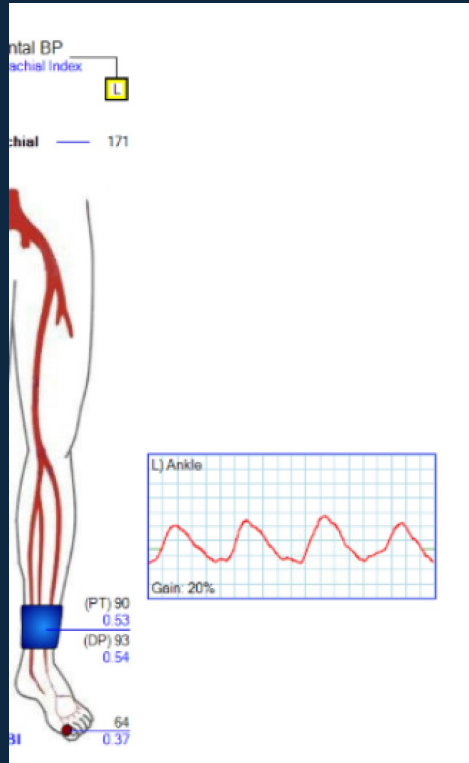
5mm x 60mm DCB



4mm x 60mm DCB



CAUTION: Investigational Device. Limited by Federal (United States) law to investigational use



CAUTION: Investigational Device. Limited by Federal (United States) law to investigational use

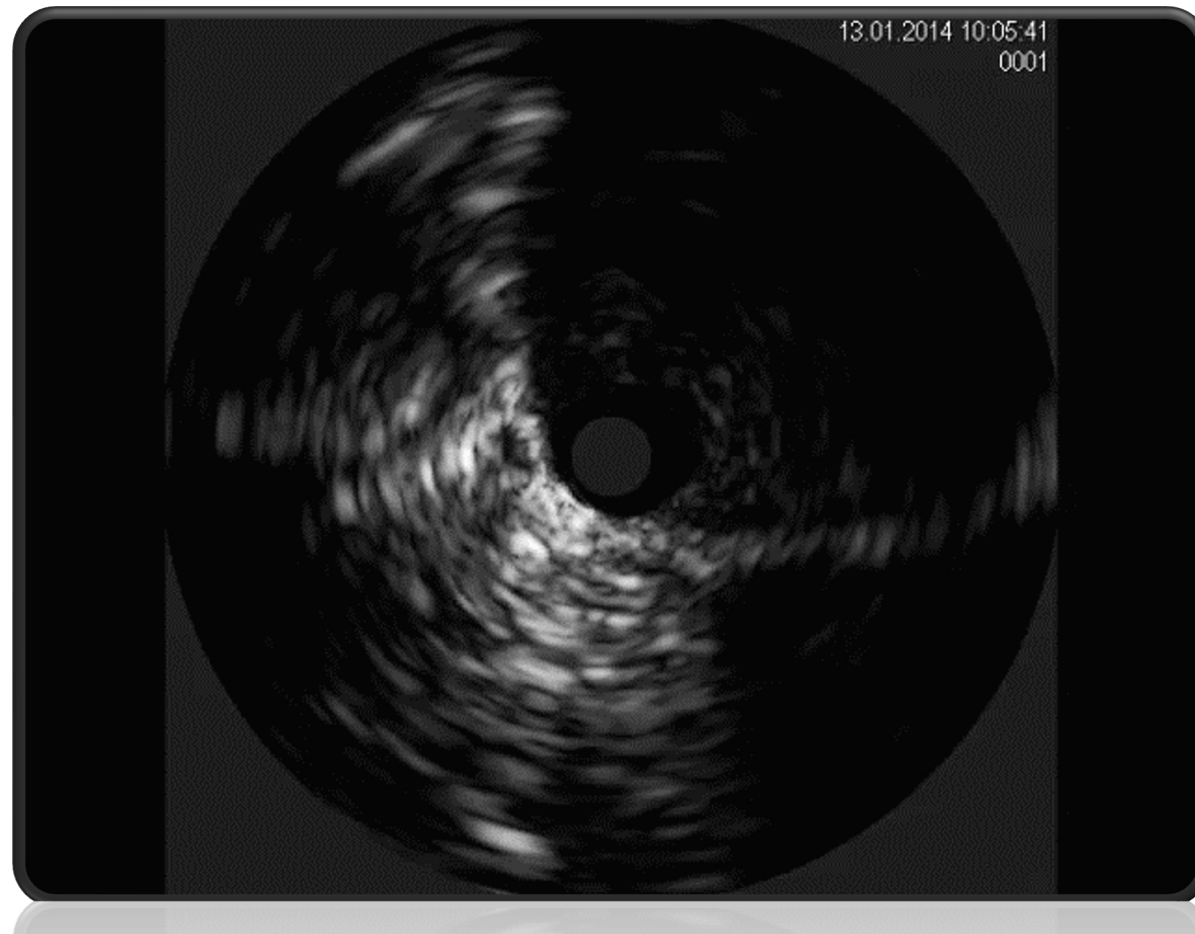

IVUS in Venous Disease: Focus on NIVL

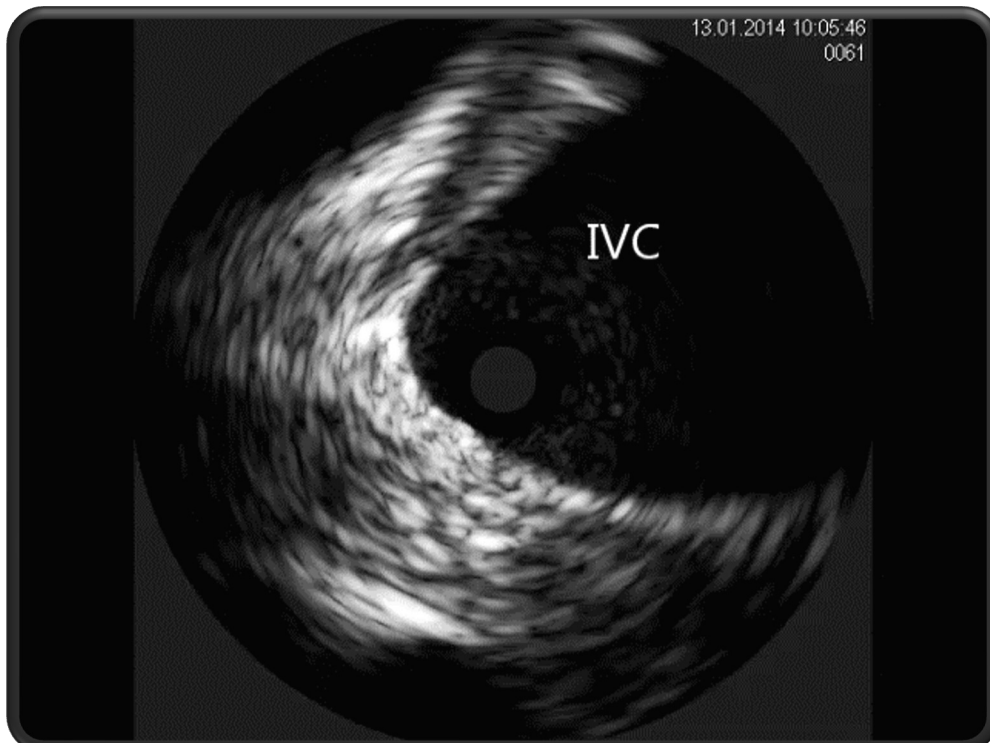
Stephen Black, MD, FEBVS, FRCS Ed, MBBCH

Chief of Surgery, Guy's and St. Thomas' Hospital
Professor of Venous Surgery, Kings College London
London, UK

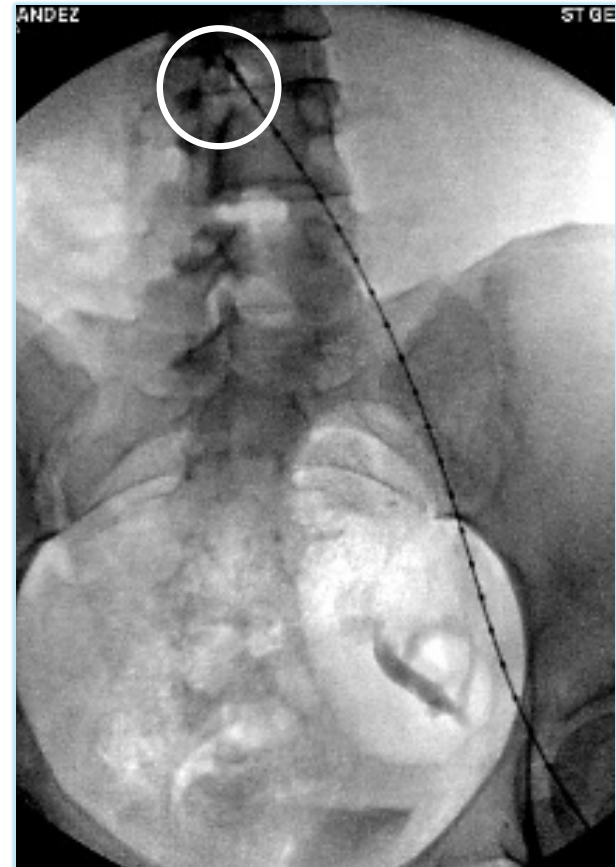
IVUS: Investigation



Identifying Central “Landing Zone”

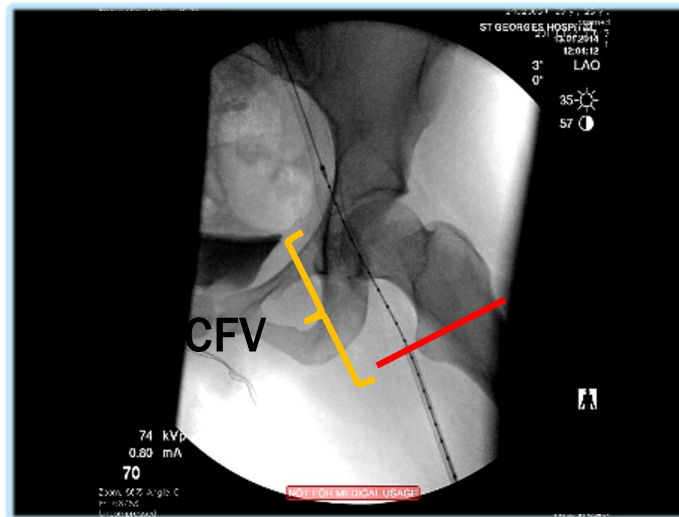
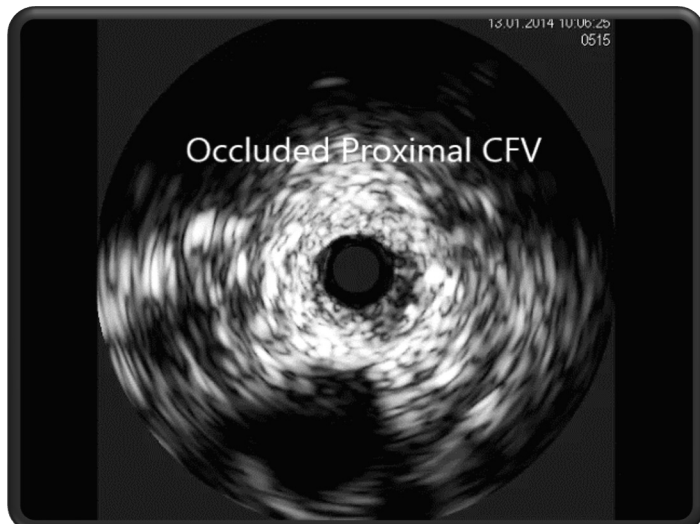


Stenting from centrum to periphery
Starting >5mm central to lesion



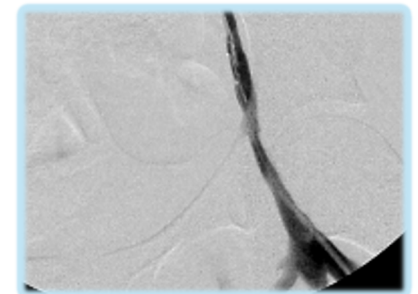
Identifying Peripheral “Landing Zone”

Pre-dilation IVUS



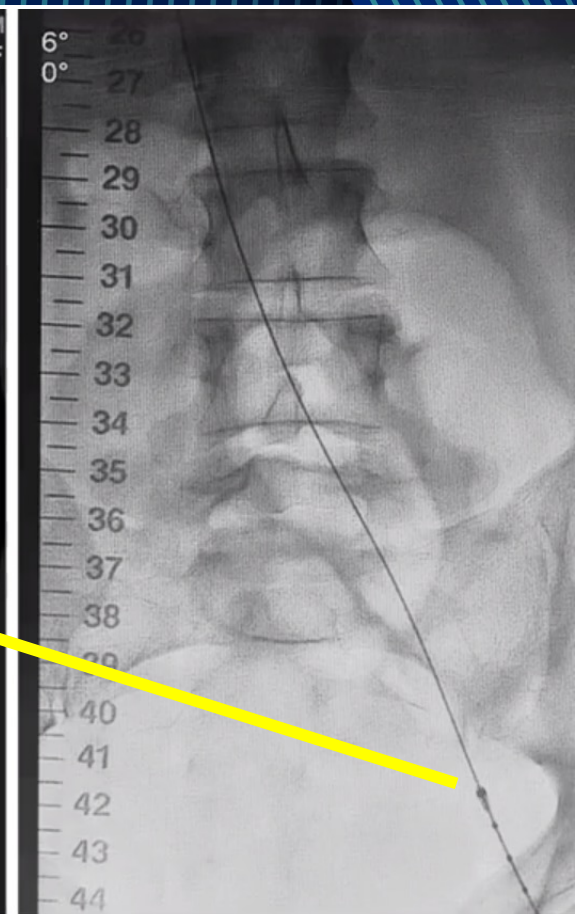
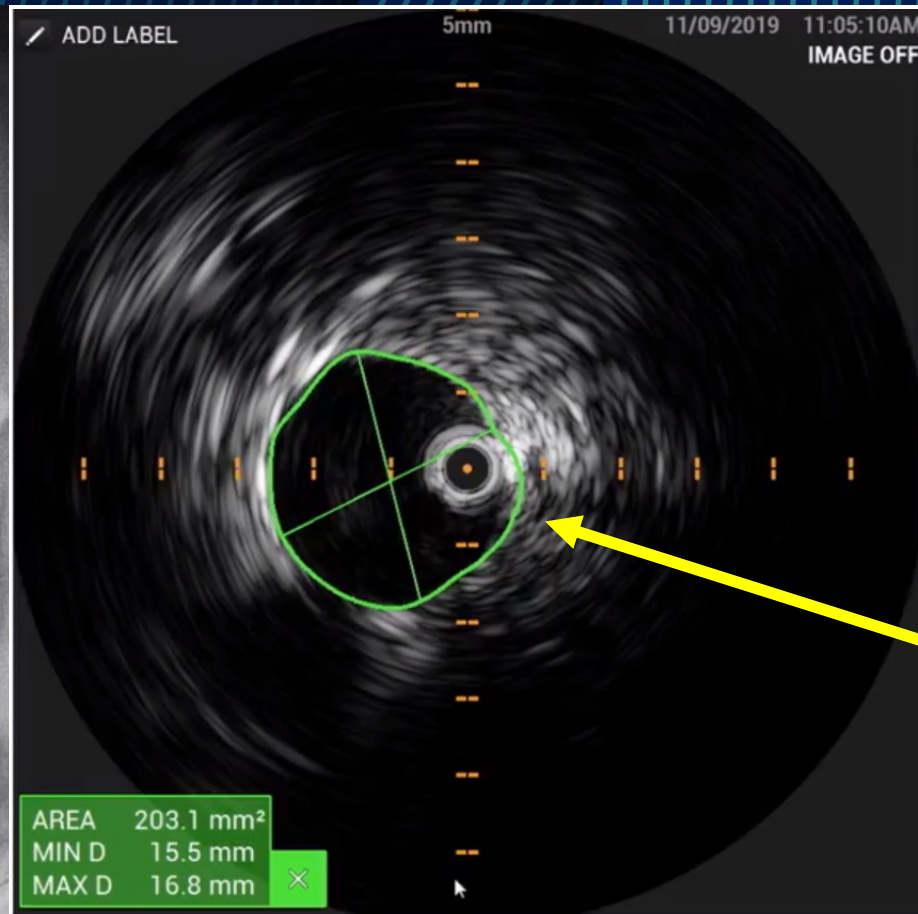
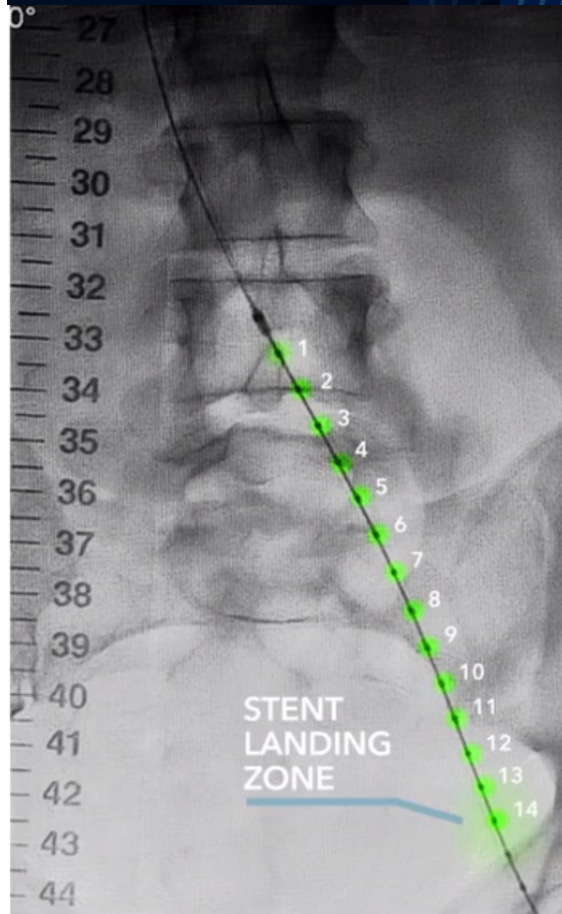
9cm stent will end land if placed with 5cm overlap

Stent lower limit

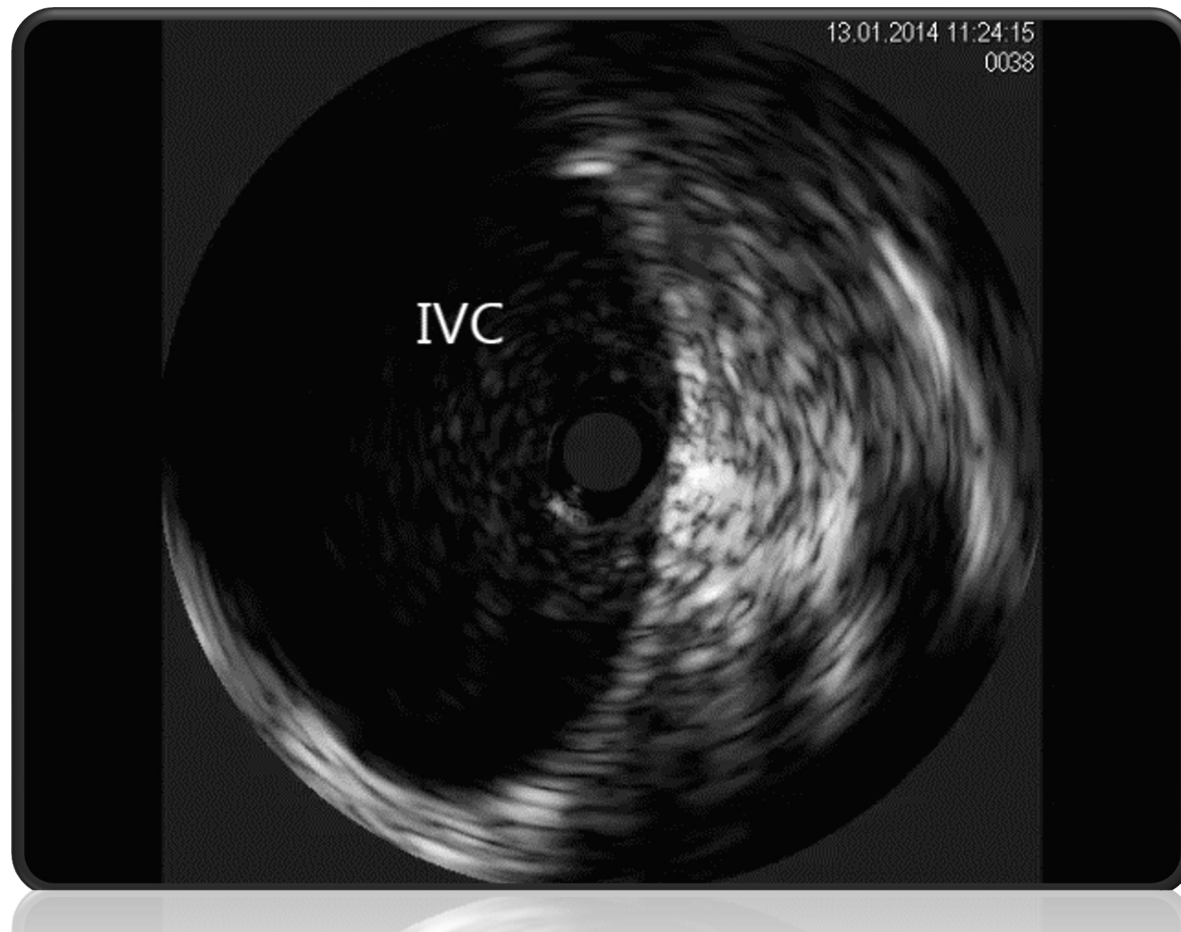


Important to focus on avoiding overlap at the ligament

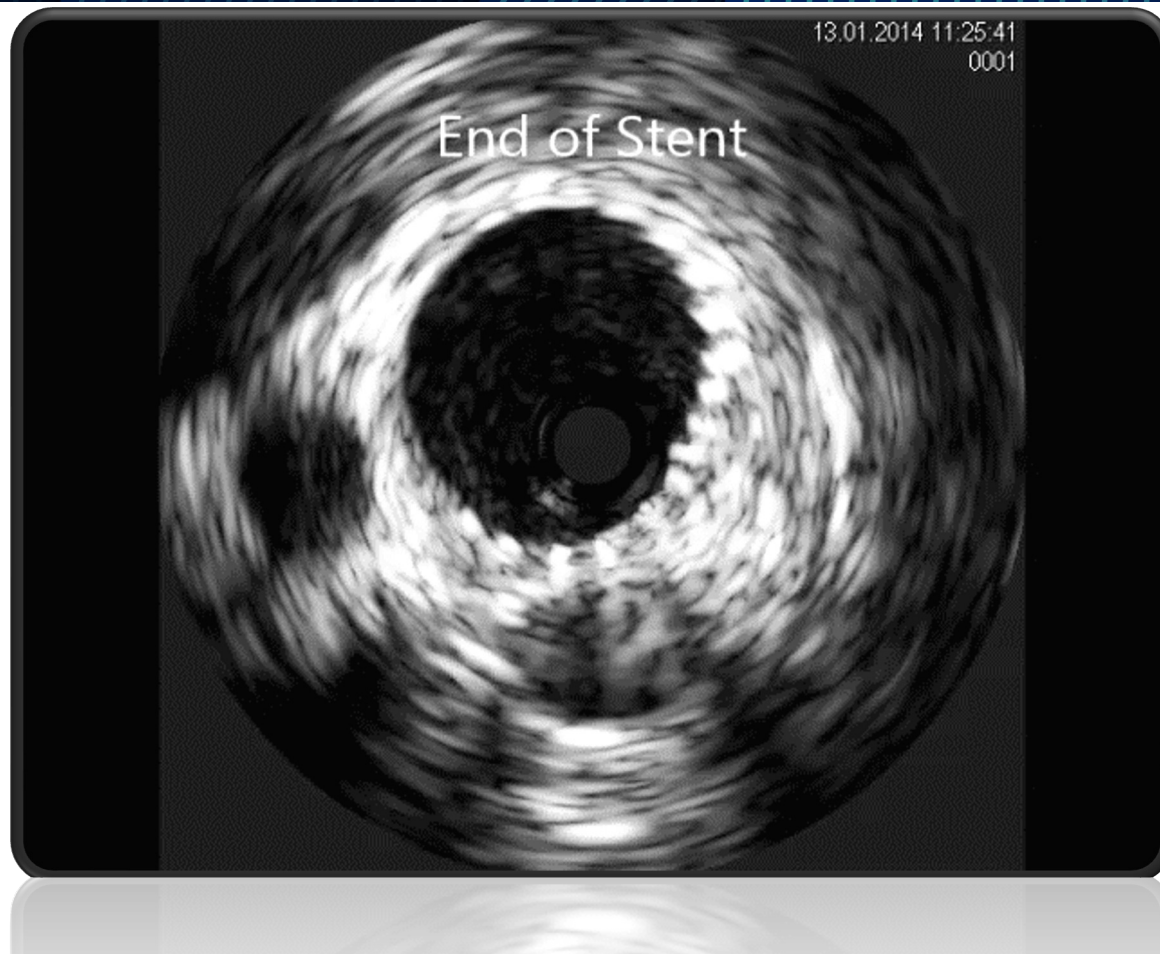
Stent Sizing

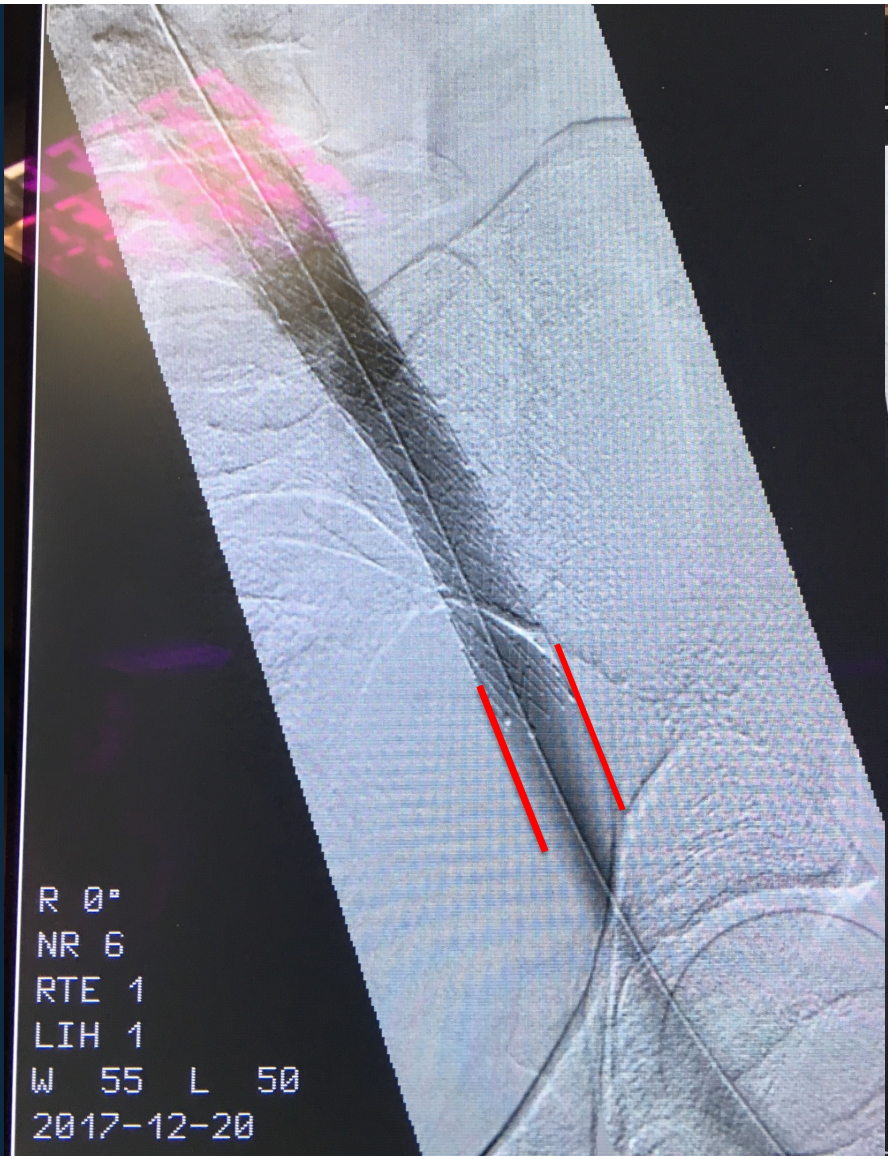


IVUS: Post-Stenting

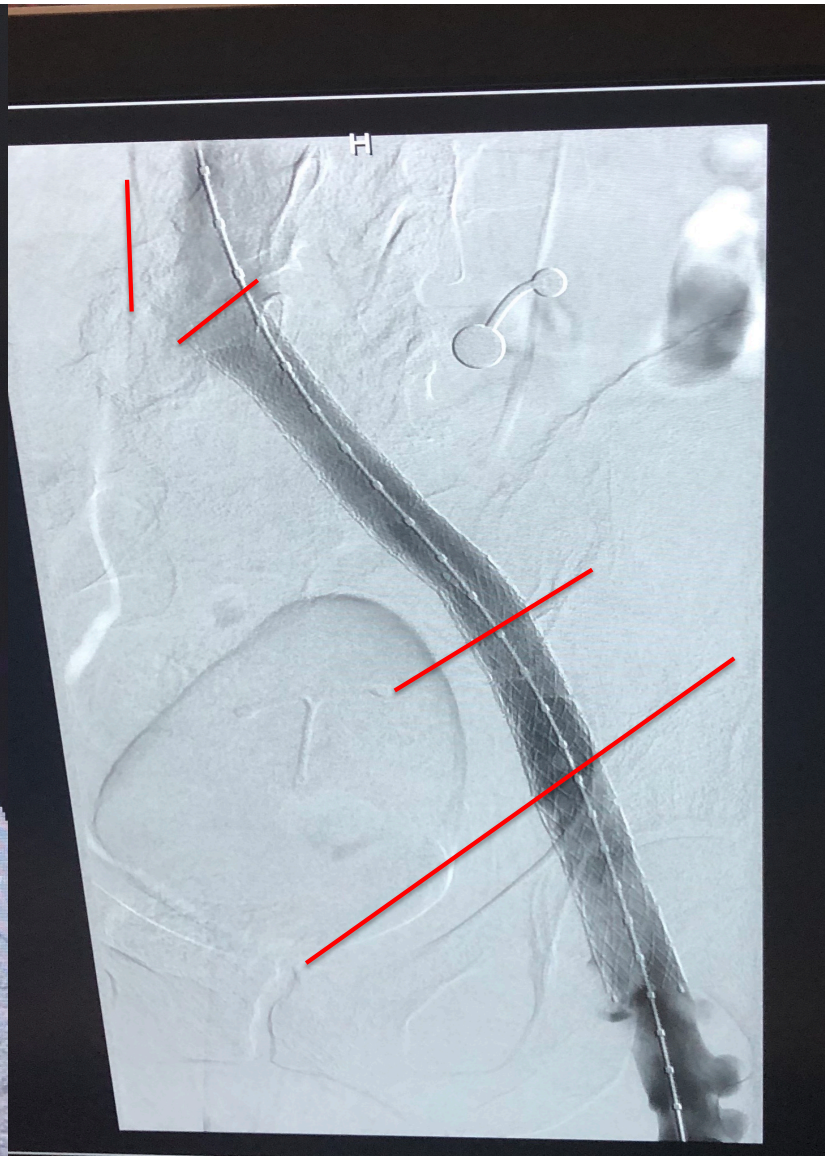

IVUS: Lower End of Stent





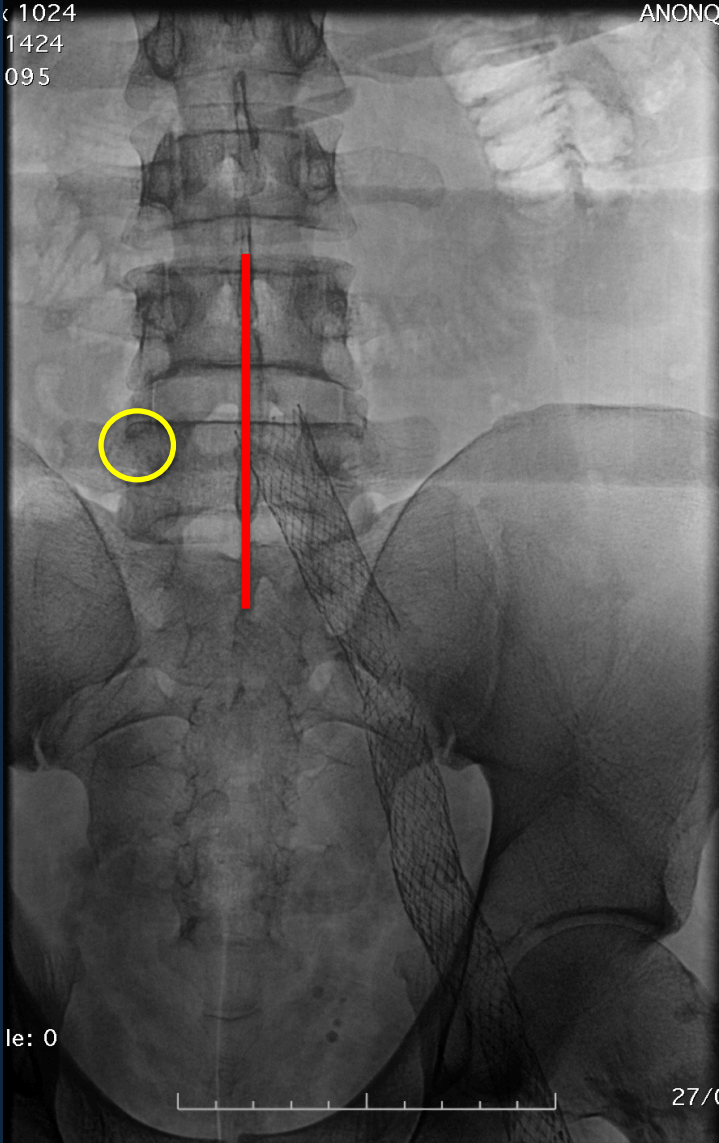
R 0°
NR 6
RTE 1
LIH 1
W 55 L 50
2017-12-20



c 1024
1424
095

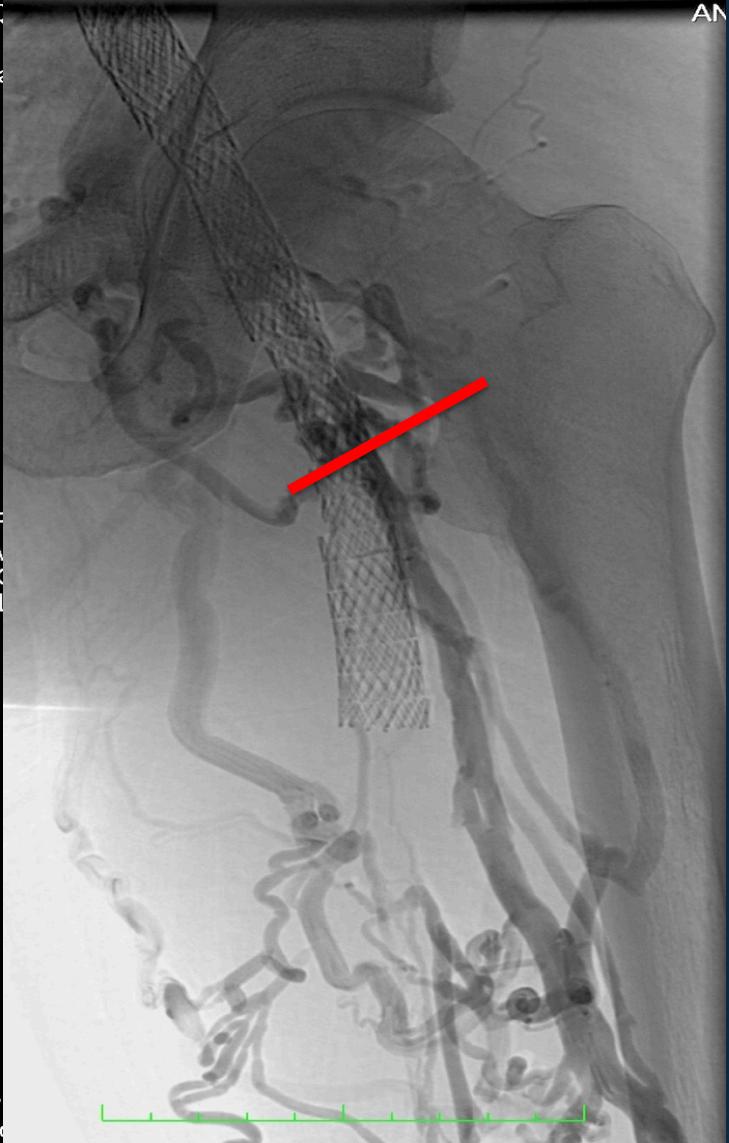
ANONQ9JLUD1C
Venog

AN



le: 0

27/09/2018
Ma



LEF
FEM
PRO
FINAL

What Is the Data?

- 1994-2020: 37 articles reporting 54 episodes of migration
- Likely to be under-reported
- 82.6% of reported migrations were short stents (<90mm)
- 93.6% were small diameter (< or equal to 14mm)
- Significant morbidity and mortality associated with migration



Journal of Vascular Surgery: Venous and
Lymphatic Disorders

Volume 10, Issue 2, March 2022, Pages 482-490



Recc

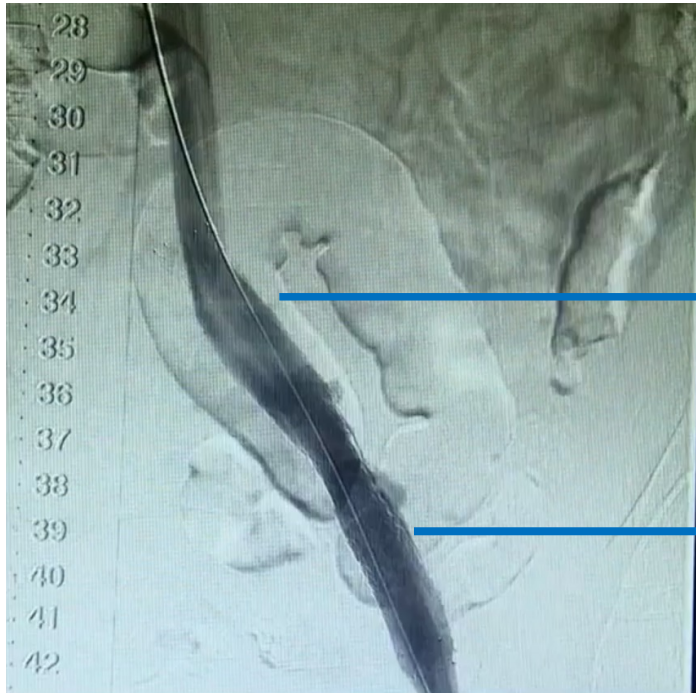No arti

Review article

A review of the incidence, outcome, and management of venous stent migration

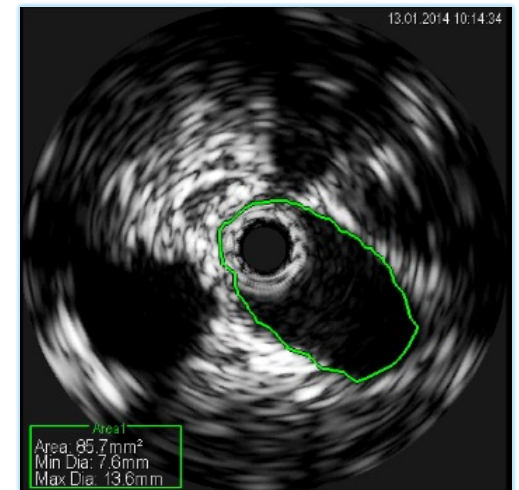
Mohamed Hosny Sayed MSc, MRCS^a, Murtaza Salem BMBS, PhD, FRCS^a, Kush R. Desai MD^b,
Gerard J. O'Sullivan FRCR, FSIR, FCIRSE^c, Stephen A. Black MD, FRCS^a✉

Sizing and Migration



**Sized for normal vein
not pre-stenotic dilation**

**Smooth transition from
normal vein to stent**



Conclusion

- **IVUS plays a crucial role in NIVL treatment**
- **Accurate sizing – critical to avoid migration**
- **Clear identification of landing zones**
- **Reduce contrast and radiation**
- **Learn what normal looks like**

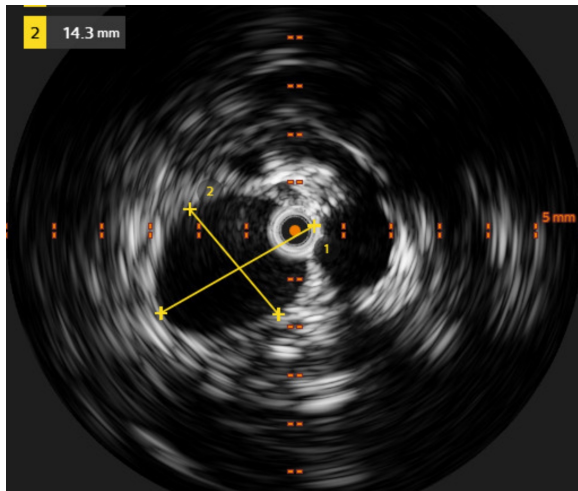
Venous Case-Based Insights

Gloria Salazar, MD, FSIR FCIRSE

Clinical Associate Professor of Radiology
University of North Carolina at Chapel Hill
Chapel Hill, NC

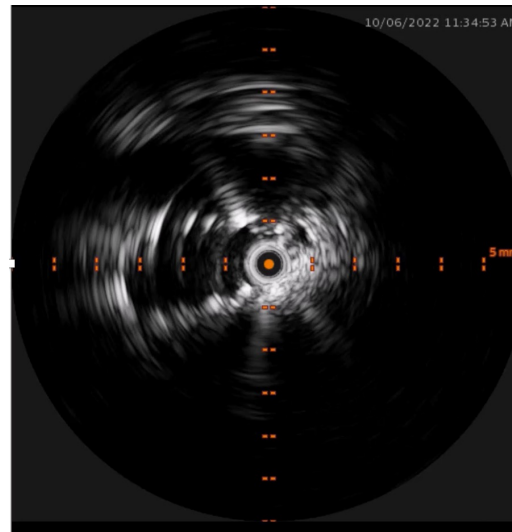
IVUS in Venous Interventions

Stent sizing¹



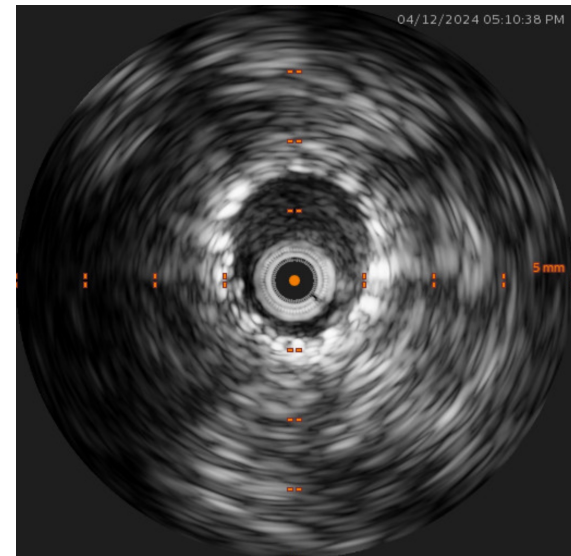
Venography underestimated diameter reduction of the most severe lesions by 11% compared to IVUS¹

Post-Intervention



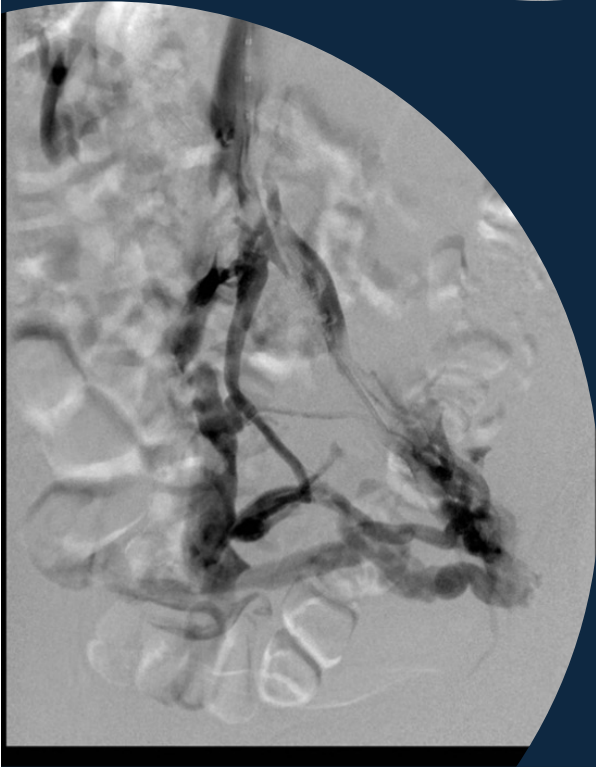
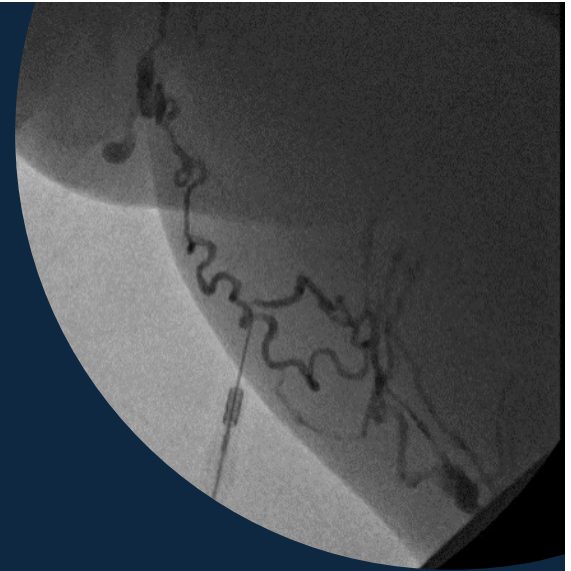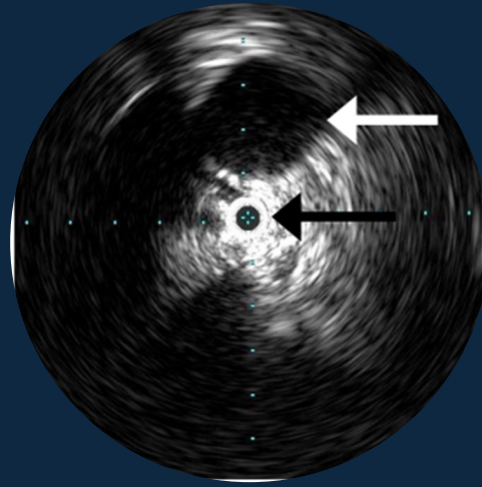
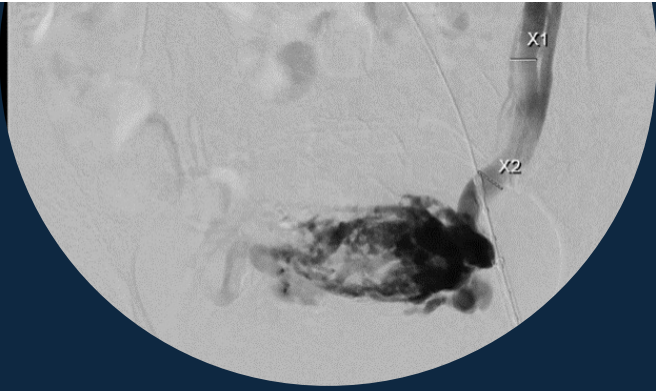
Confirm stent placement, apposition and expansion

Assessment of IRS²

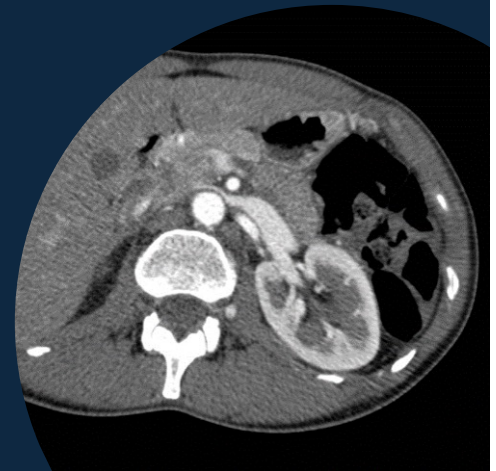

IVUS inflow channel luminal area $<125\text{mm}^2$ / Shear rate $>100\text{ s}^{-1}$

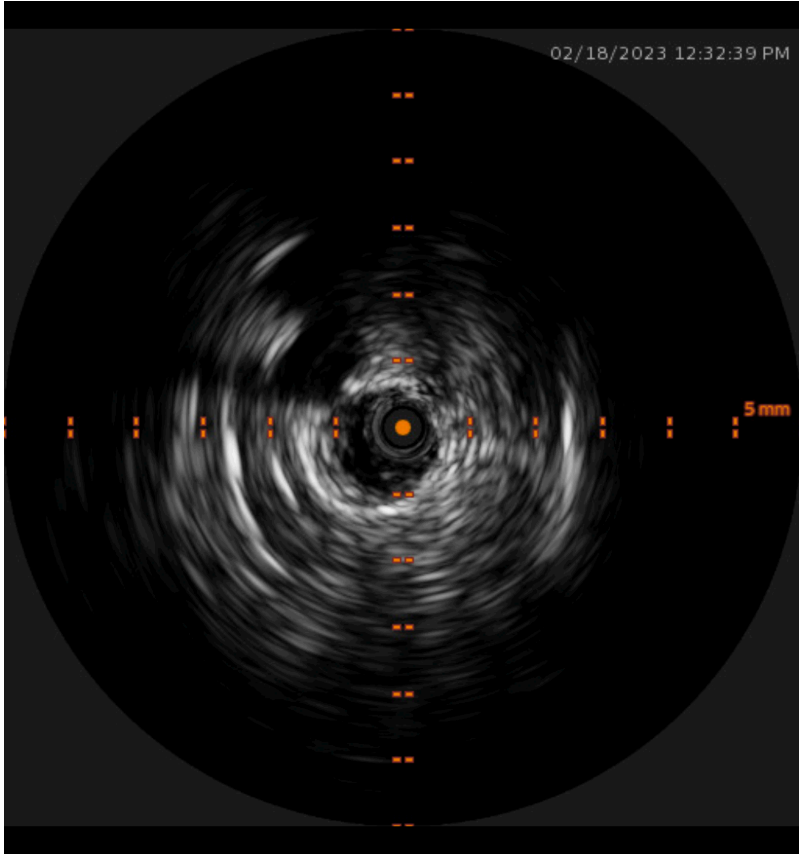
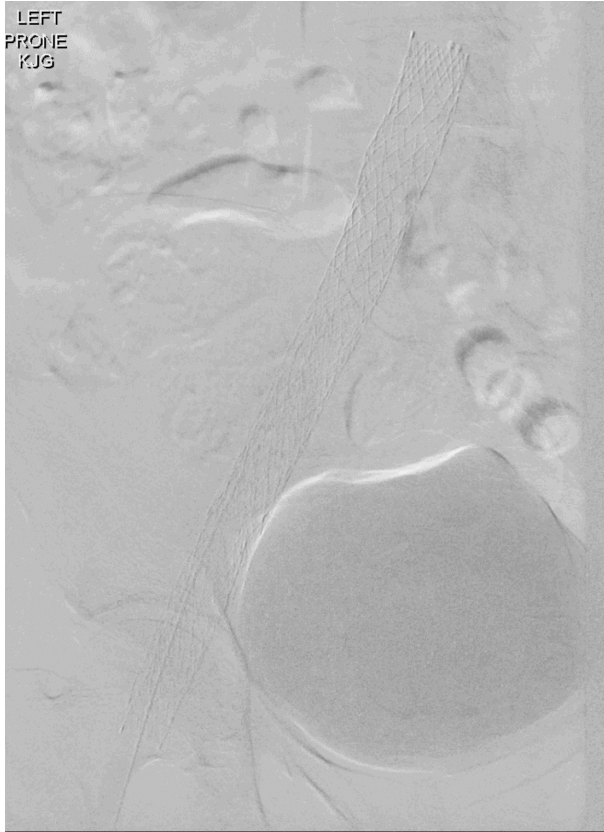1. Gagne PJ, et al. Venography versus intravascular ultrasound for diagnosing and treating iliofemoral vein obstruction. *J Vasc Surg Venous Lymphat Disord.* 2017;5:678-687
2. Jayaraj A, et al. In-stent restenosis and stent compression following stenting for chronic iliofemoral venous obstruction. *J Vasc Surg Venous Lymphat Disord.* 2022;10(1):42-51.



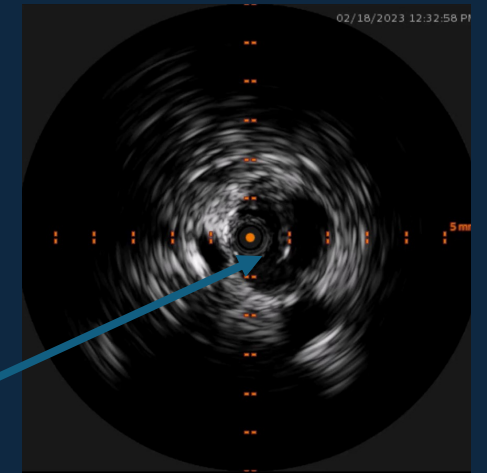
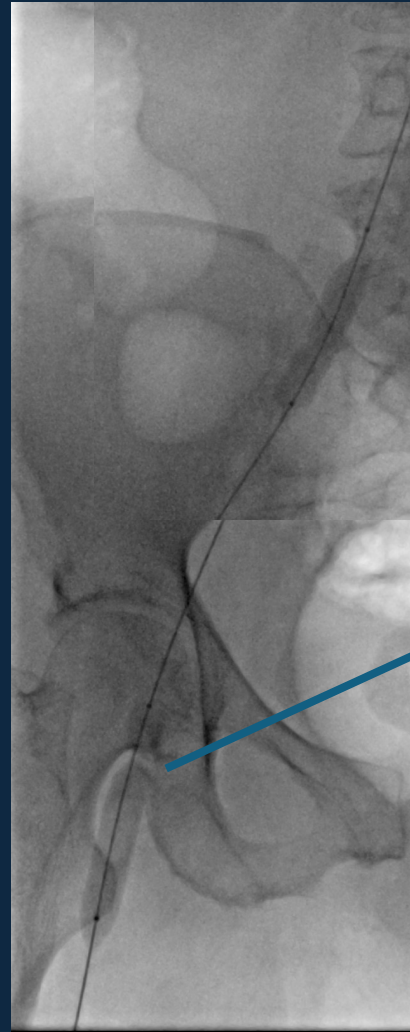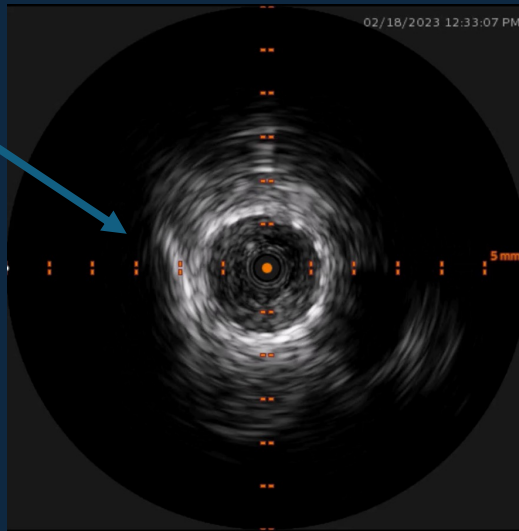
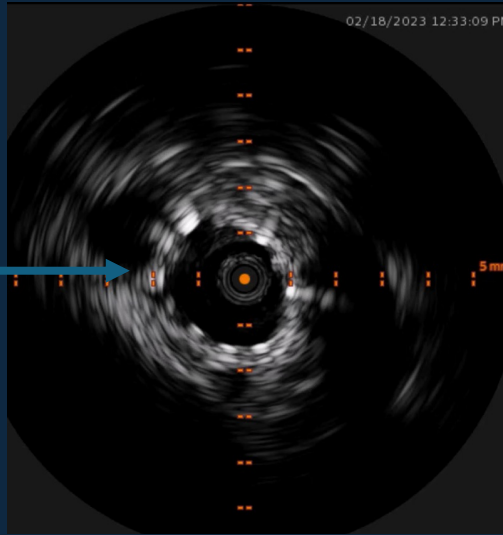
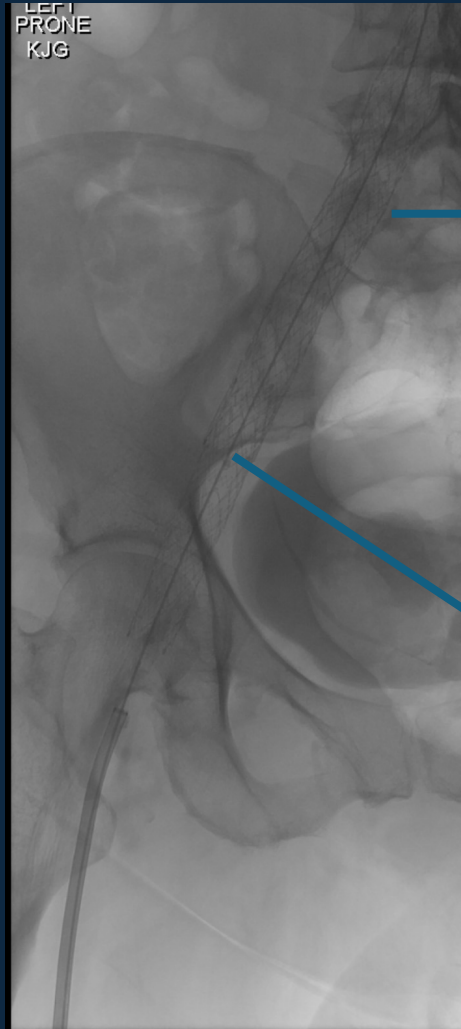
The view from
inside...



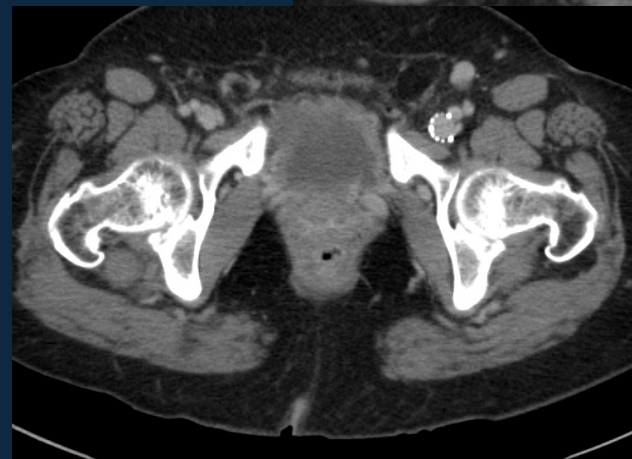
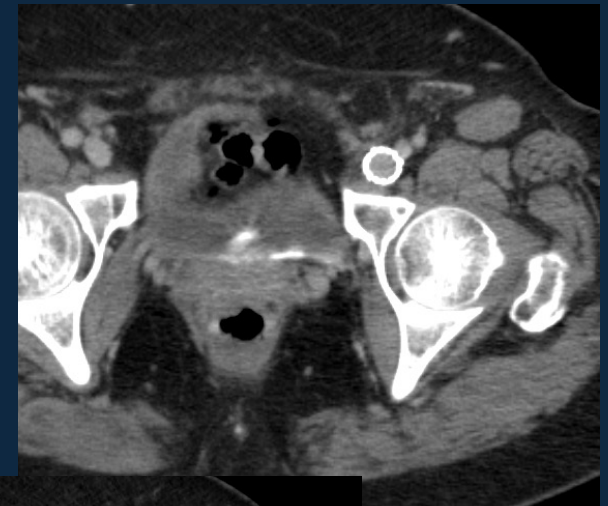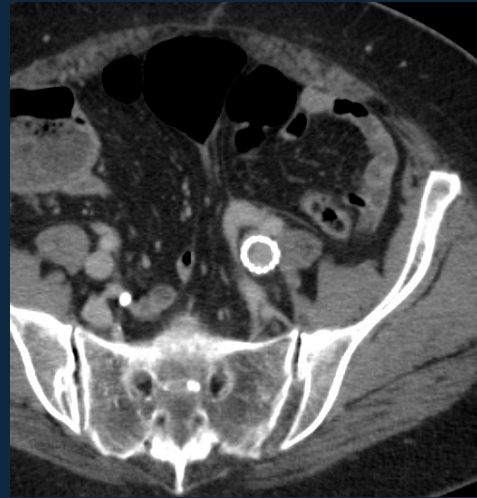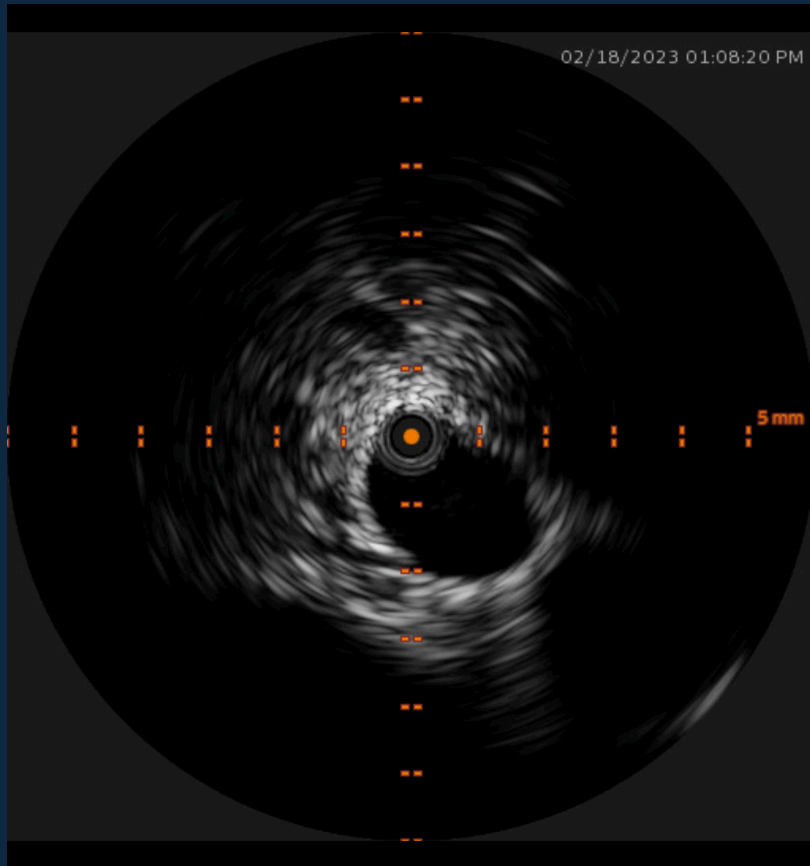
Reintervention in PTS Patient



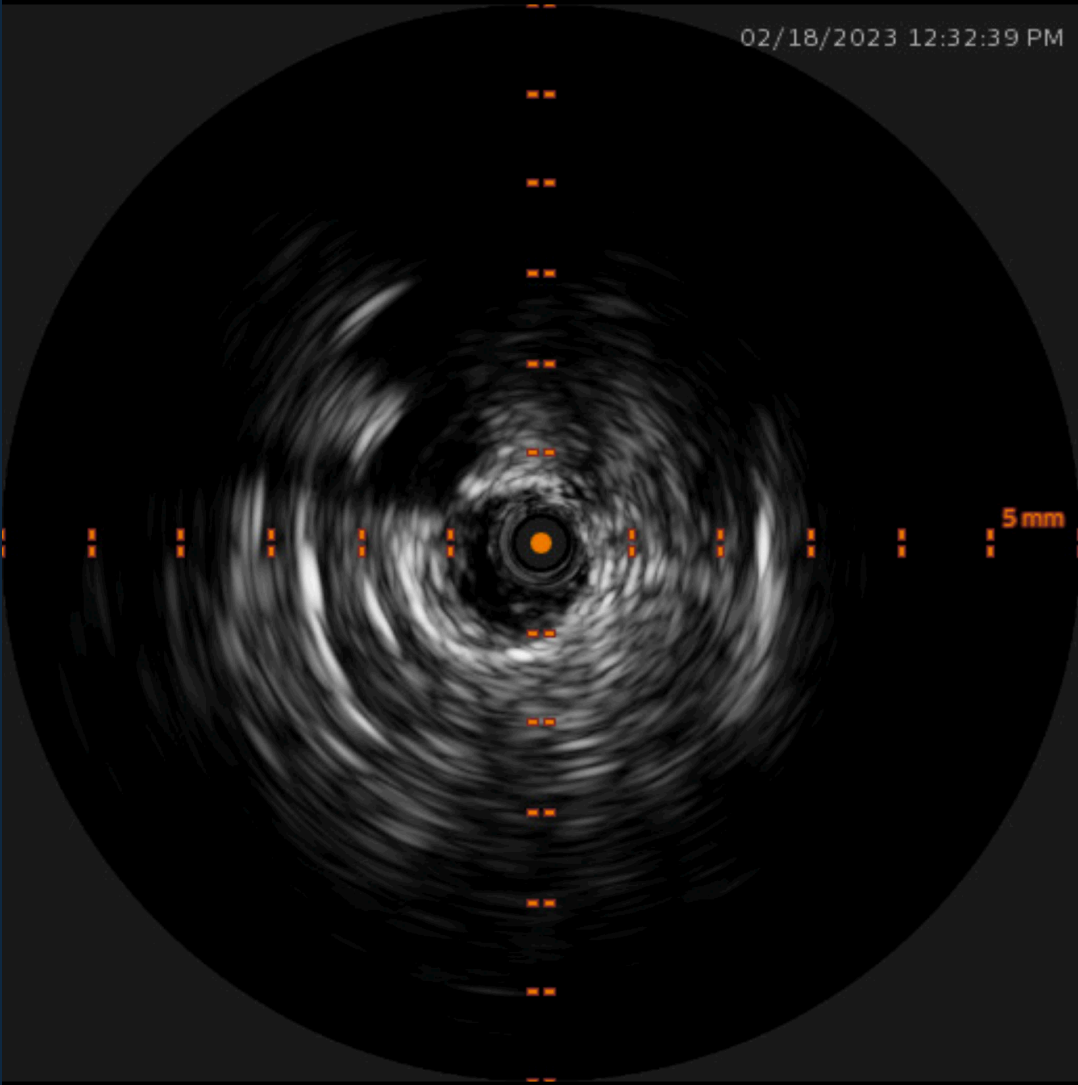
LEFT
PRONE
KJG



Final IVUS

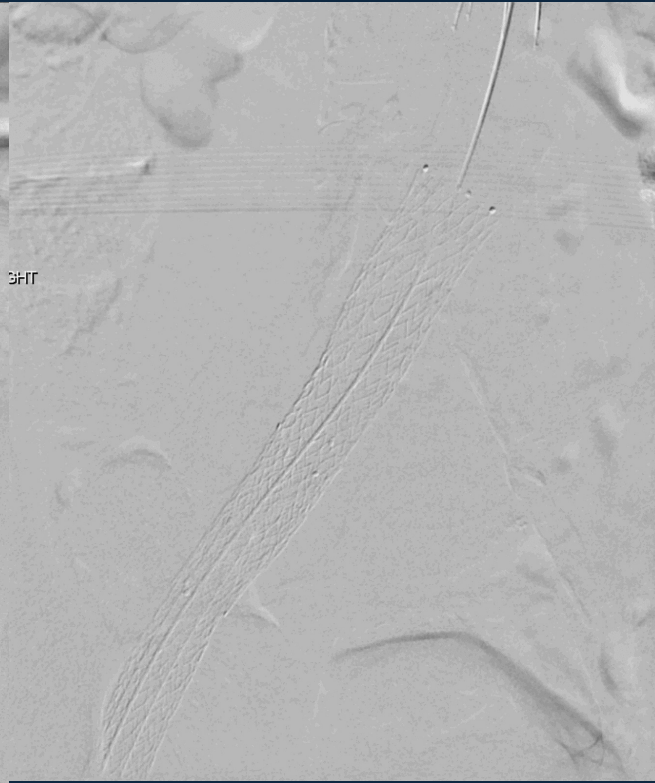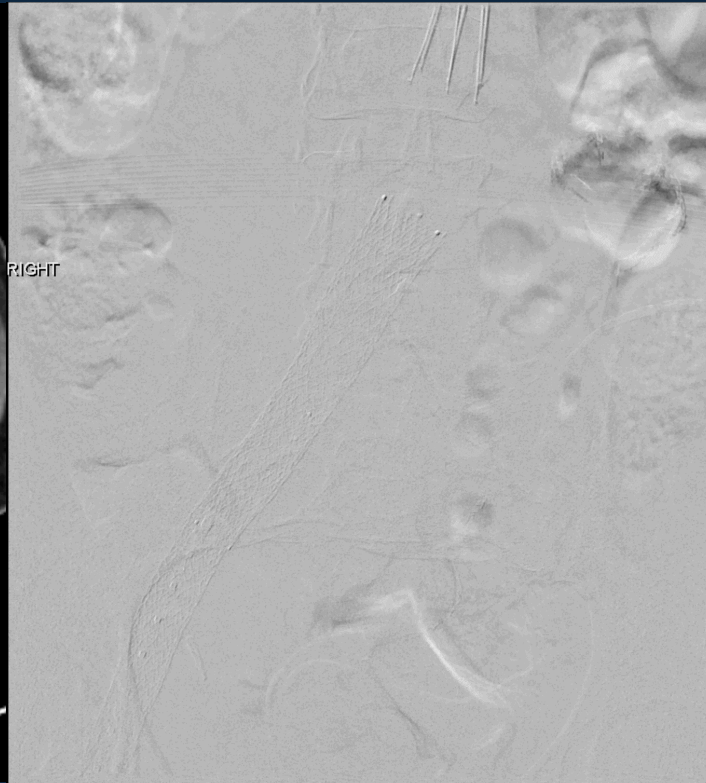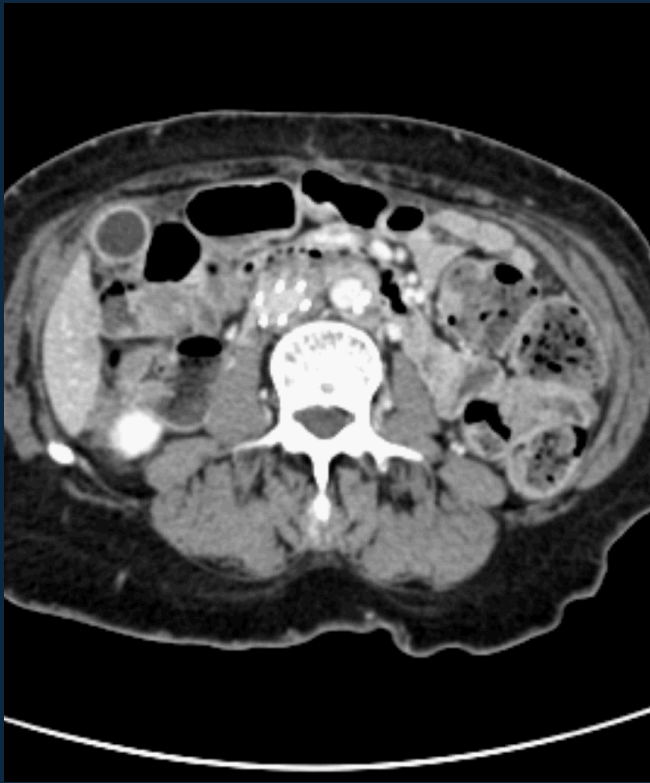


02/18/2023 12:32:39 PM

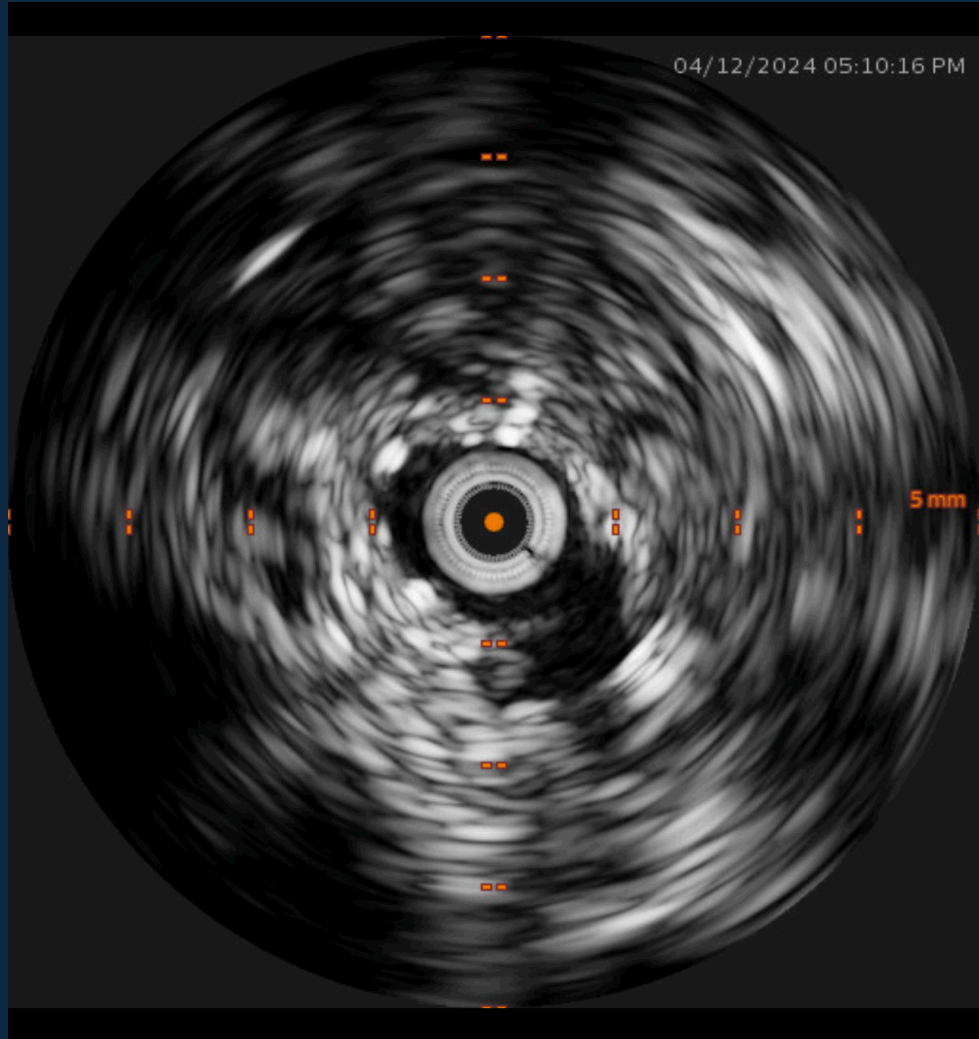


5 mm

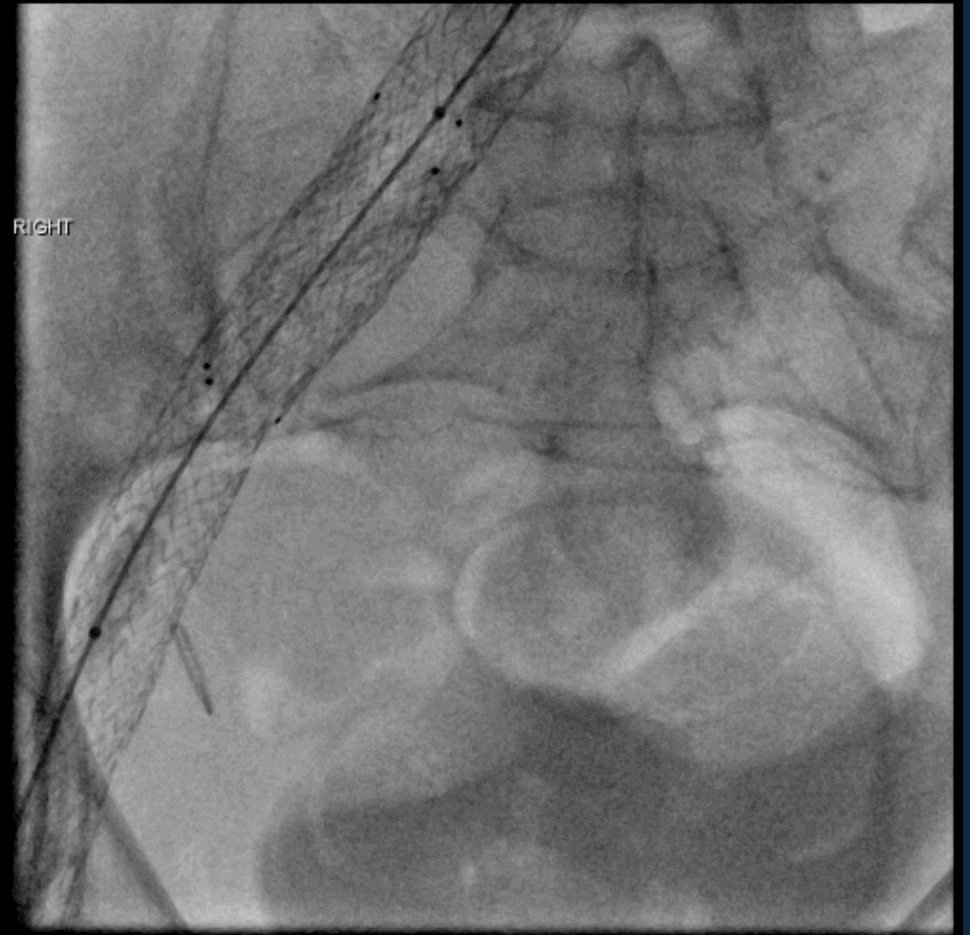
Reintervention in Thrombotic Cancer



04/12/2024 05:10:16 PM

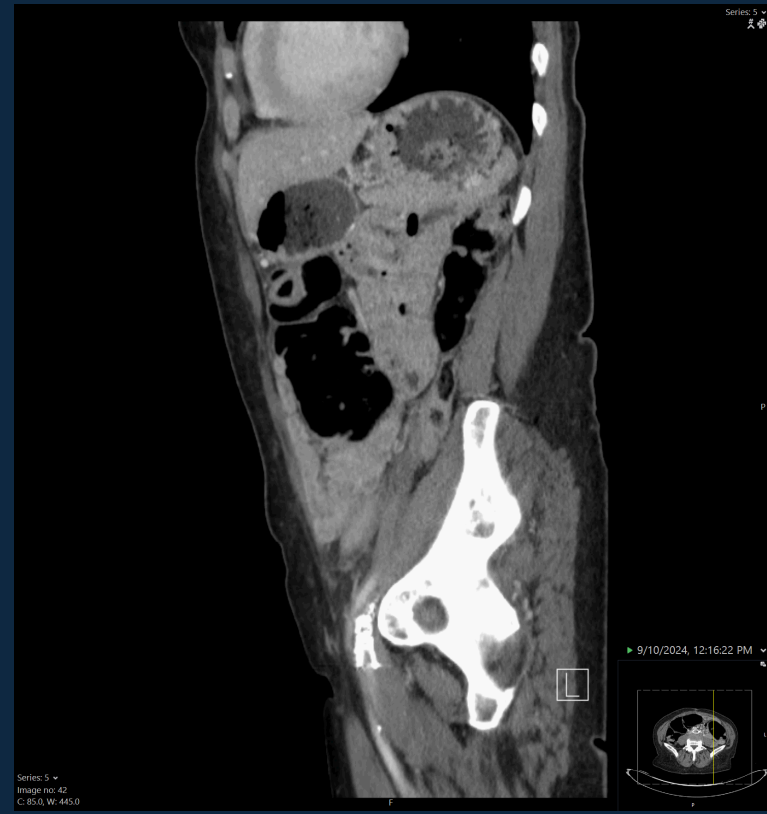
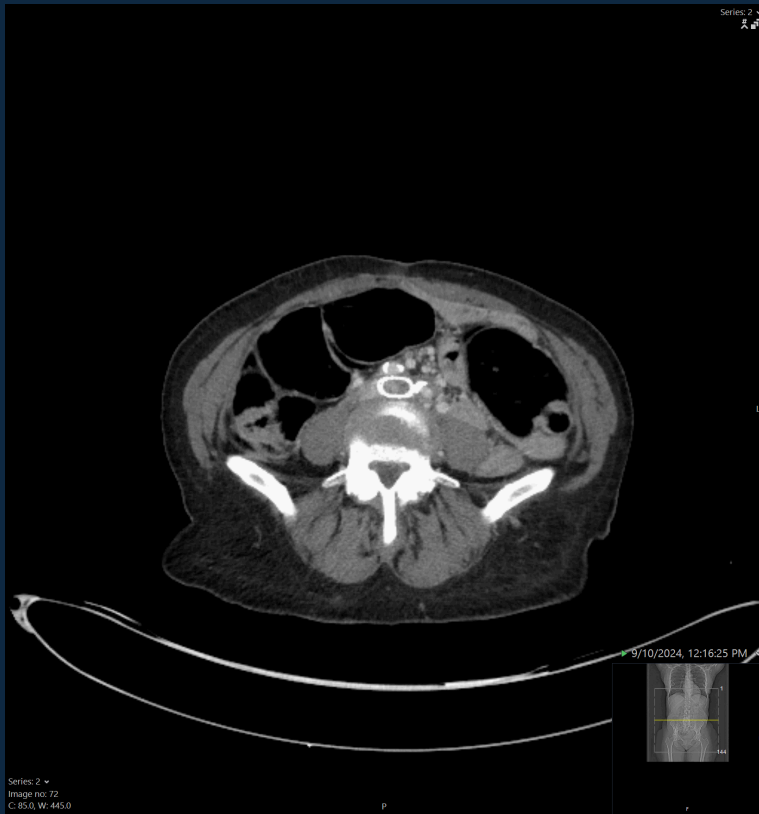
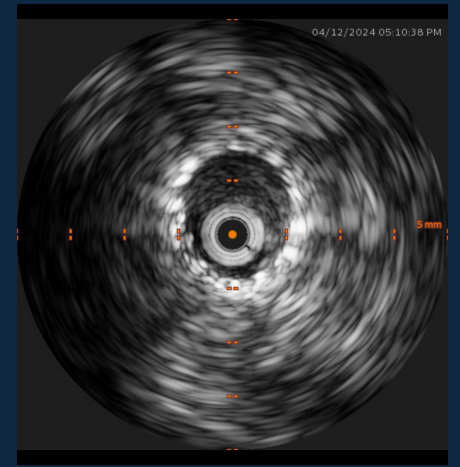
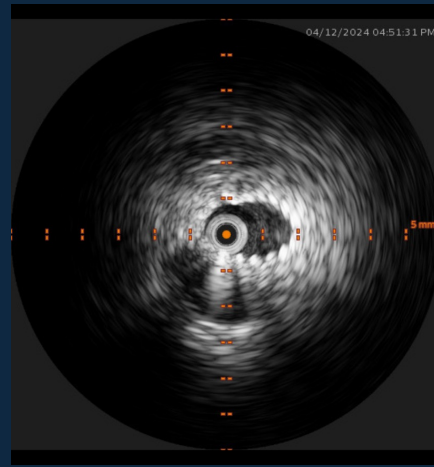
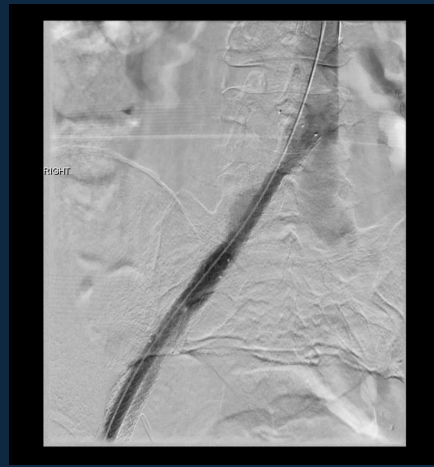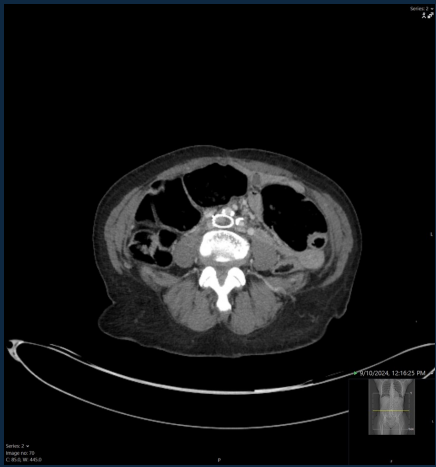5 mm



RIGHT

Follow-Up

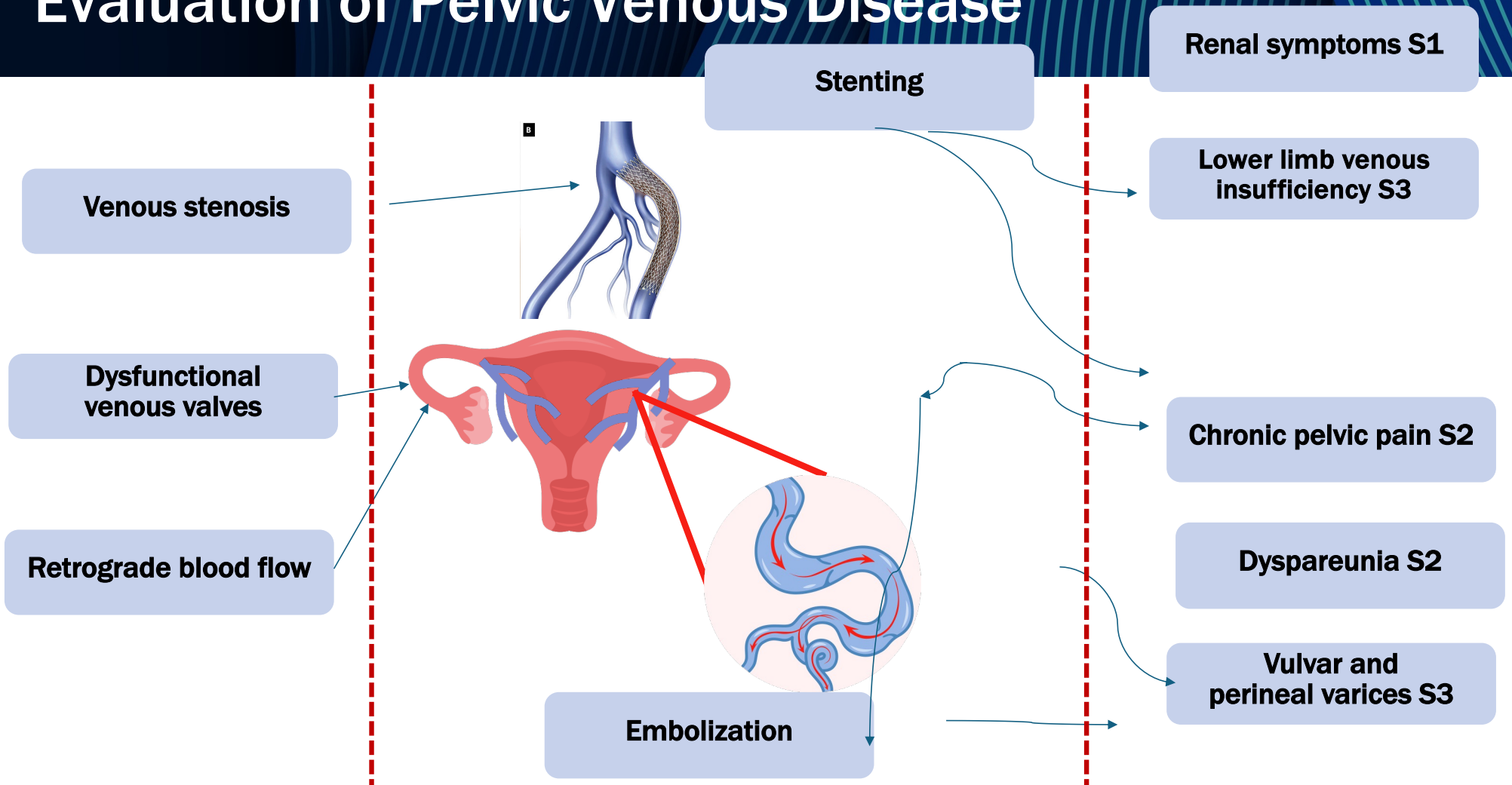




The background features a series of overlapping, wavy bands in various shades of blue and teal, creating a sense of depth and movement. The lines are closely spaced and curve across the frame.

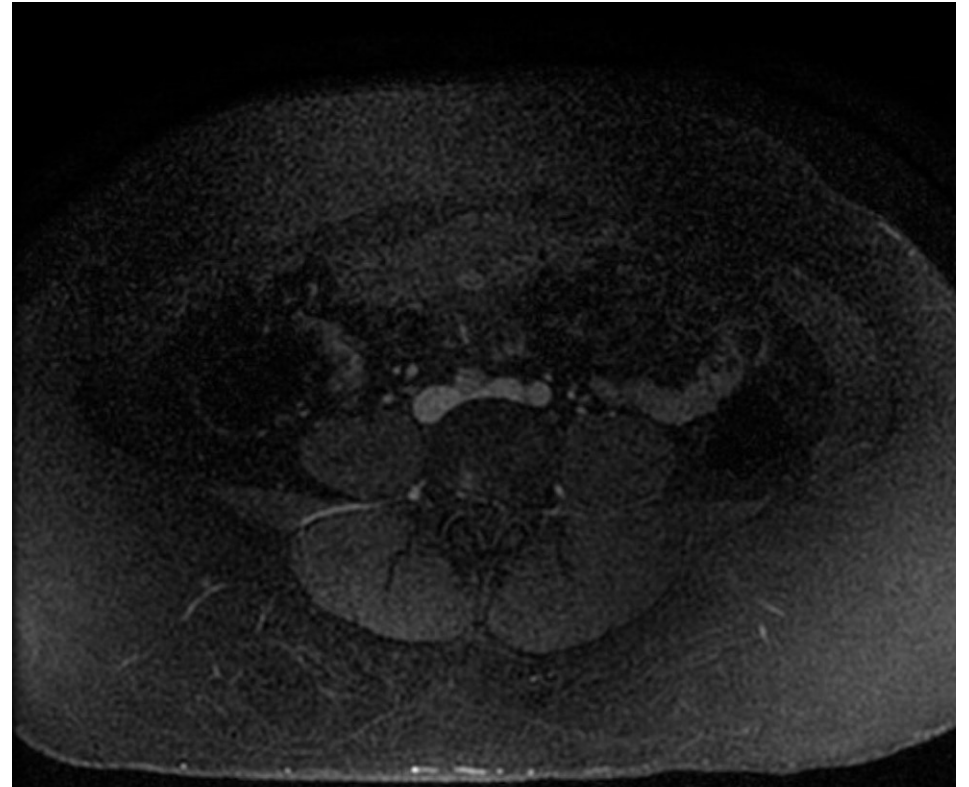
What else?

Evaluation of Pelvic Venous Disease

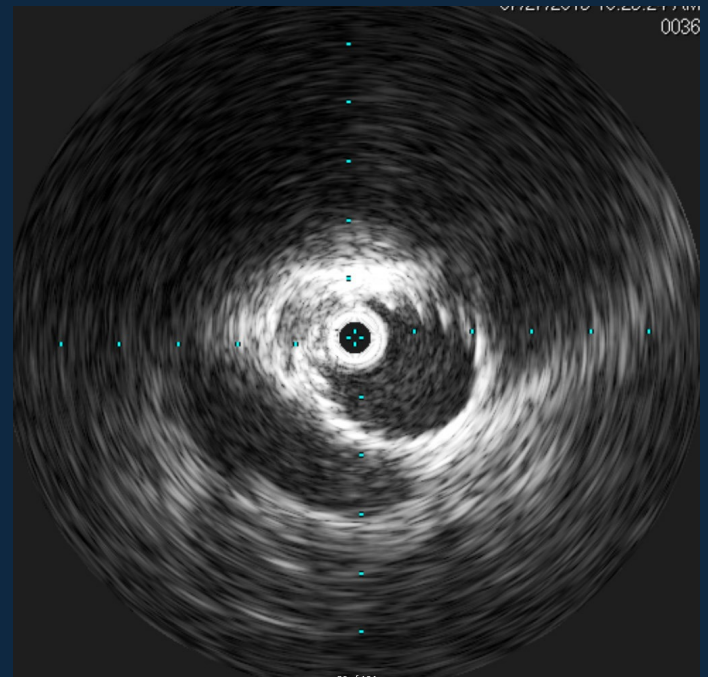
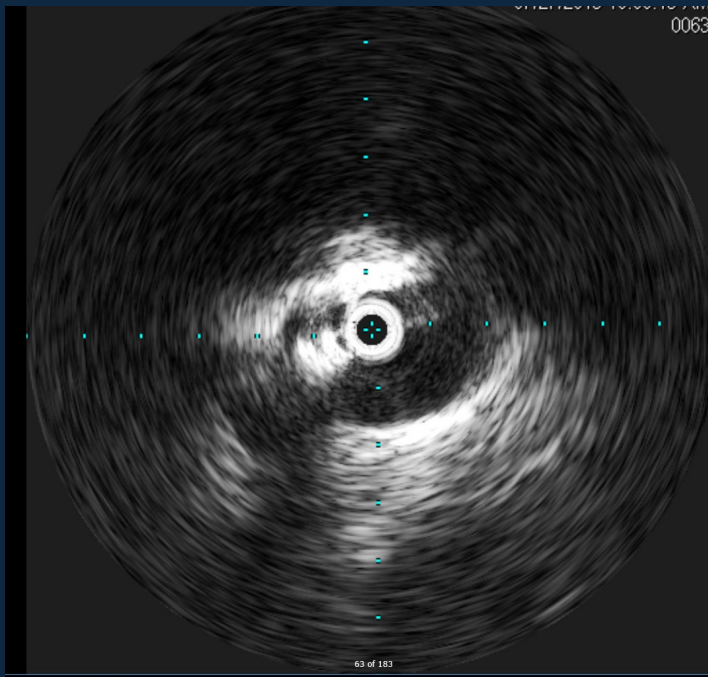


Case 1

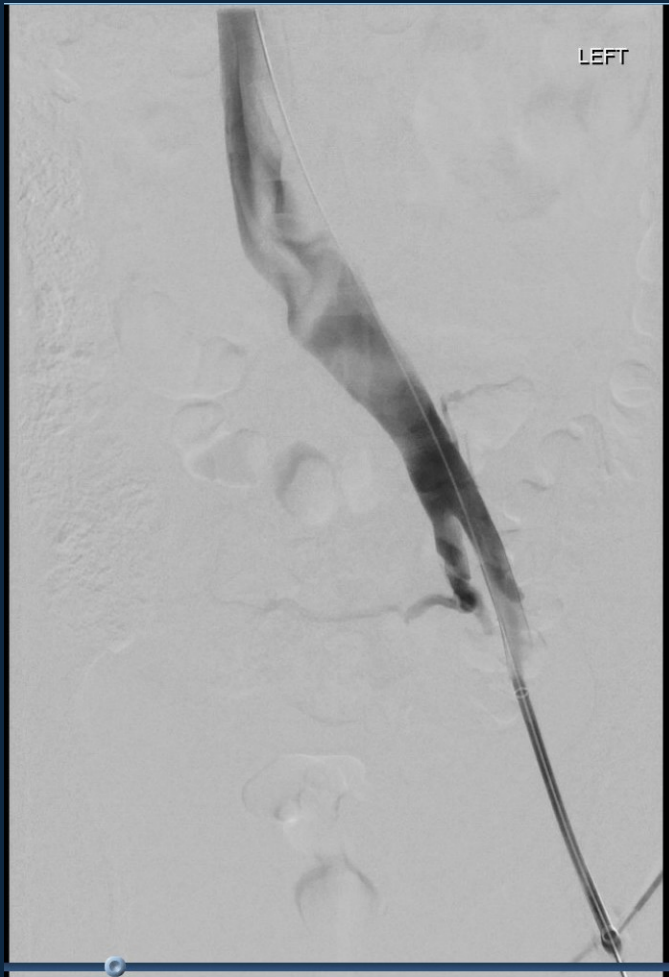
- 28y Female initially referred for CPP unable to become pregnant due to severe post-coital dyspareunia
- No endometriosis
- Undergoing IVF



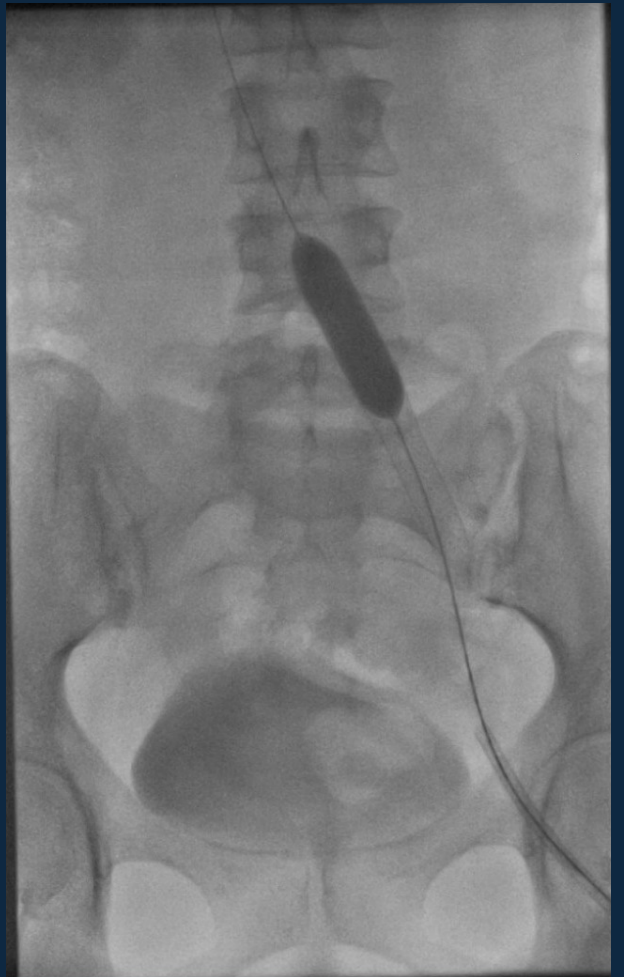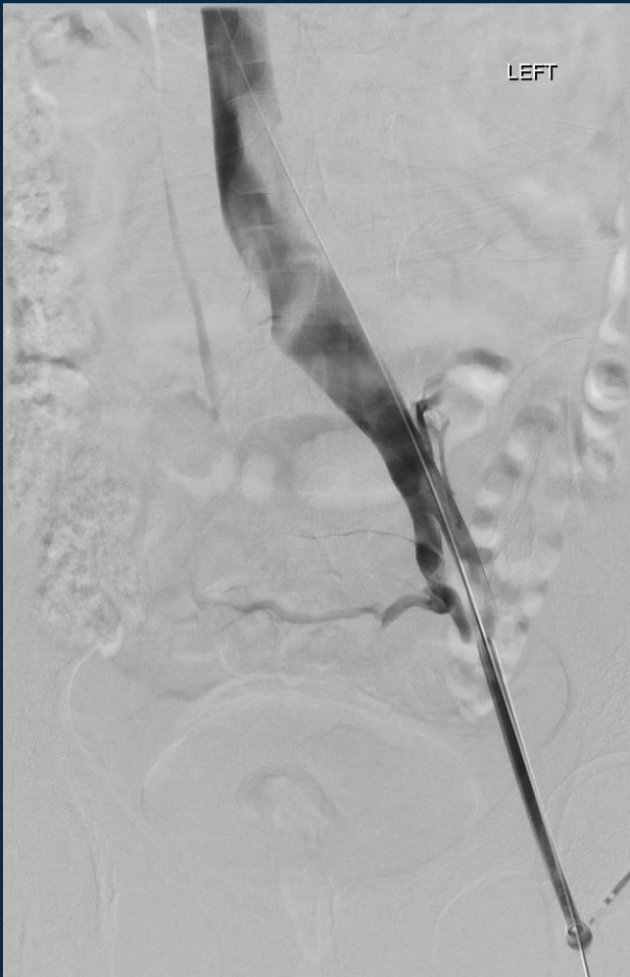IVUS



LEFT

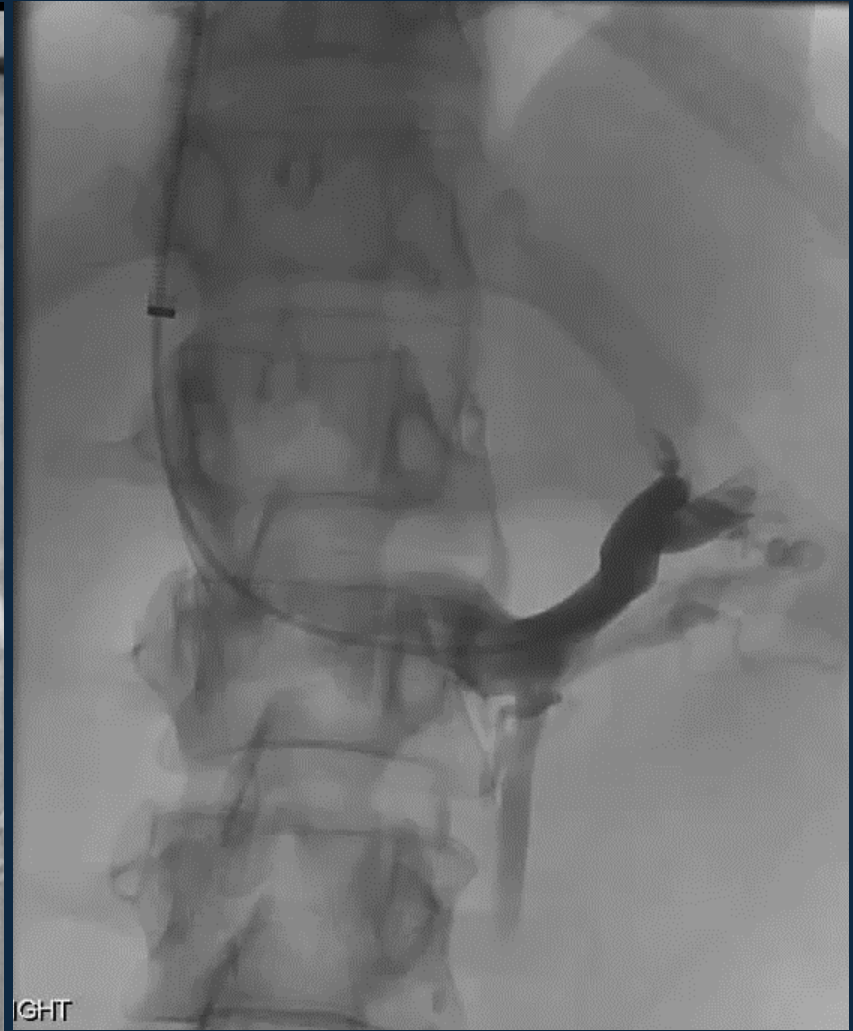
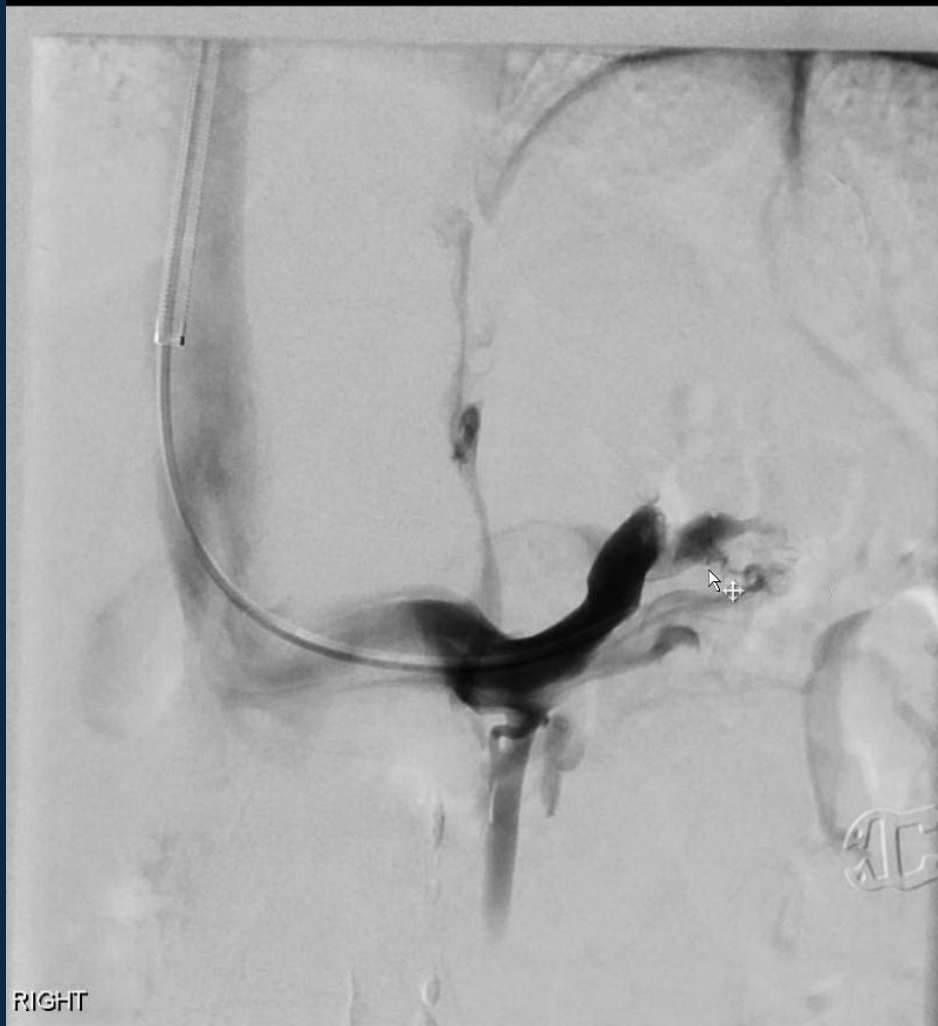
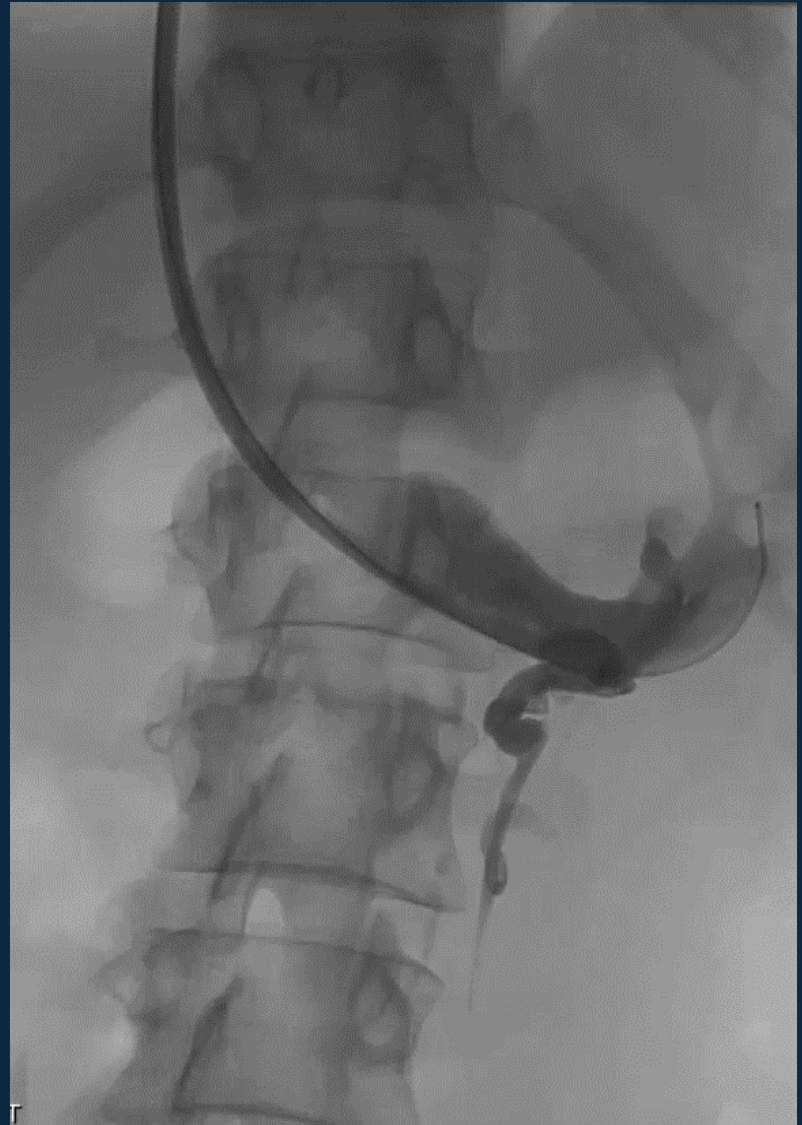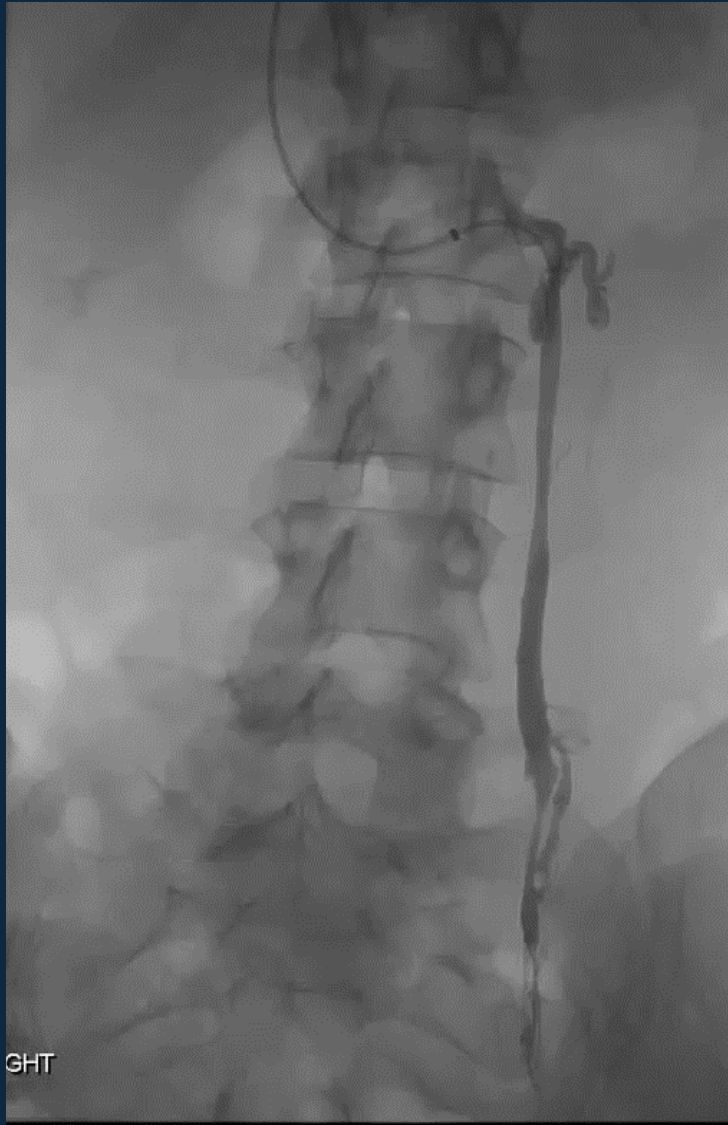
LEFT

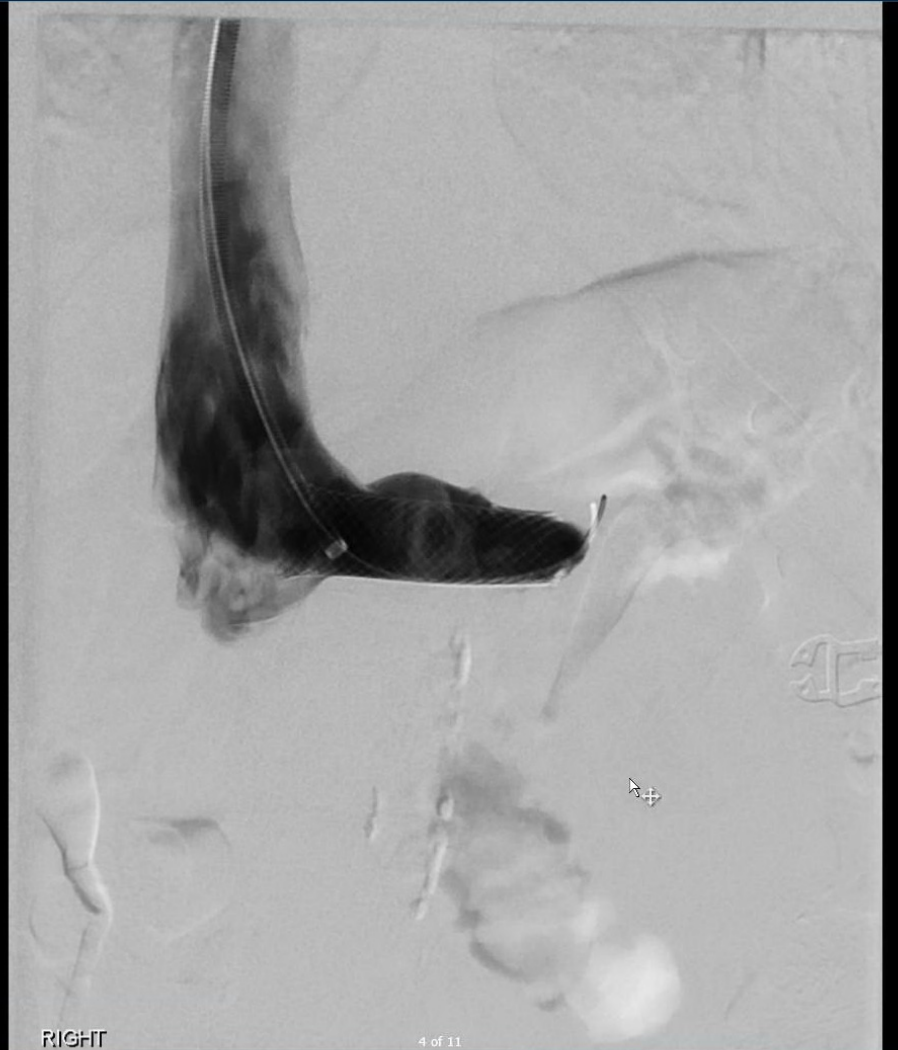
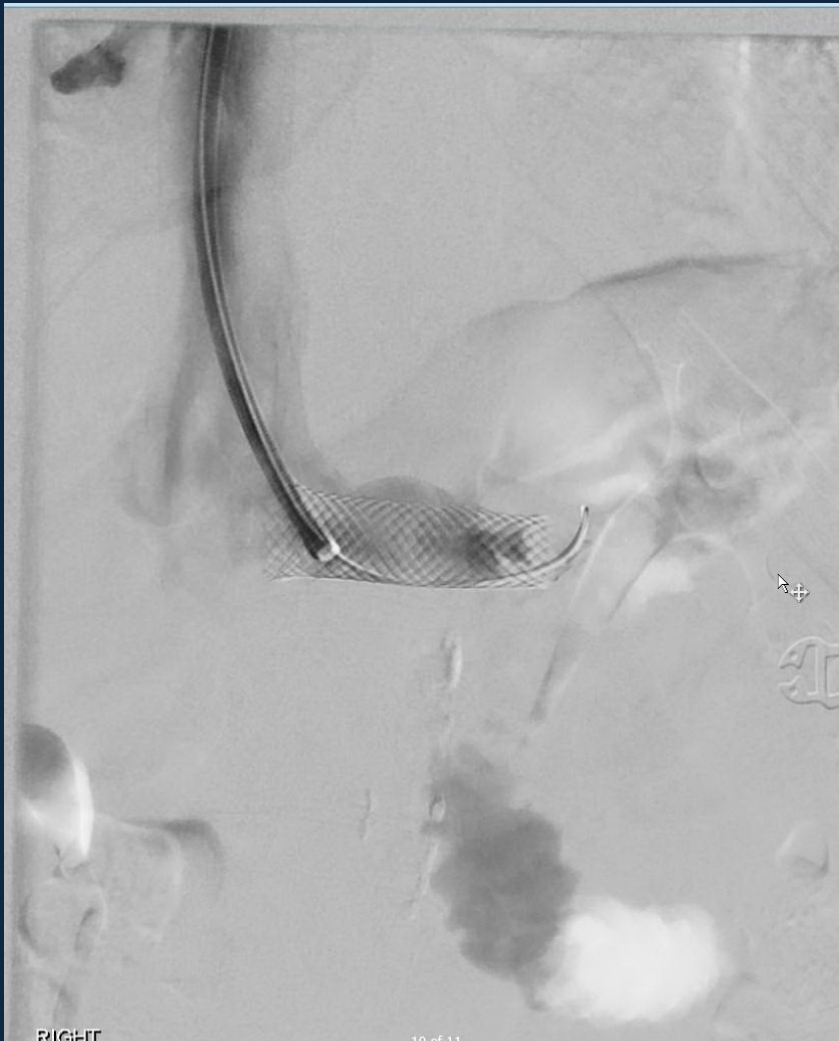

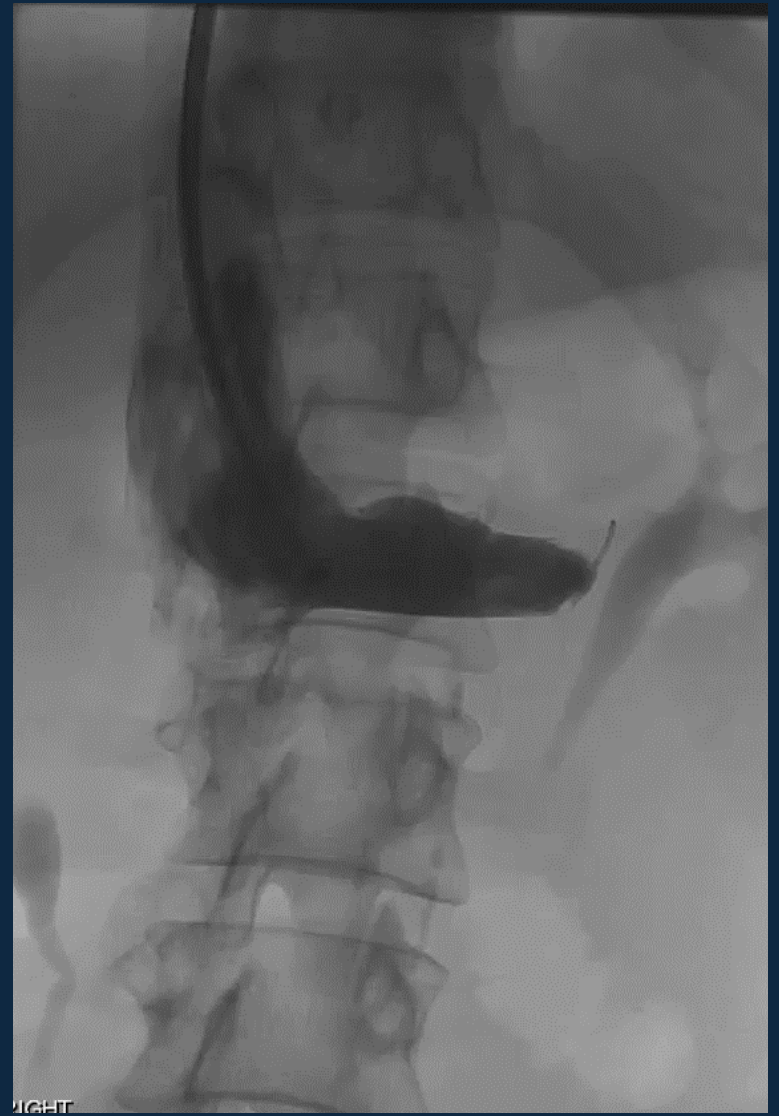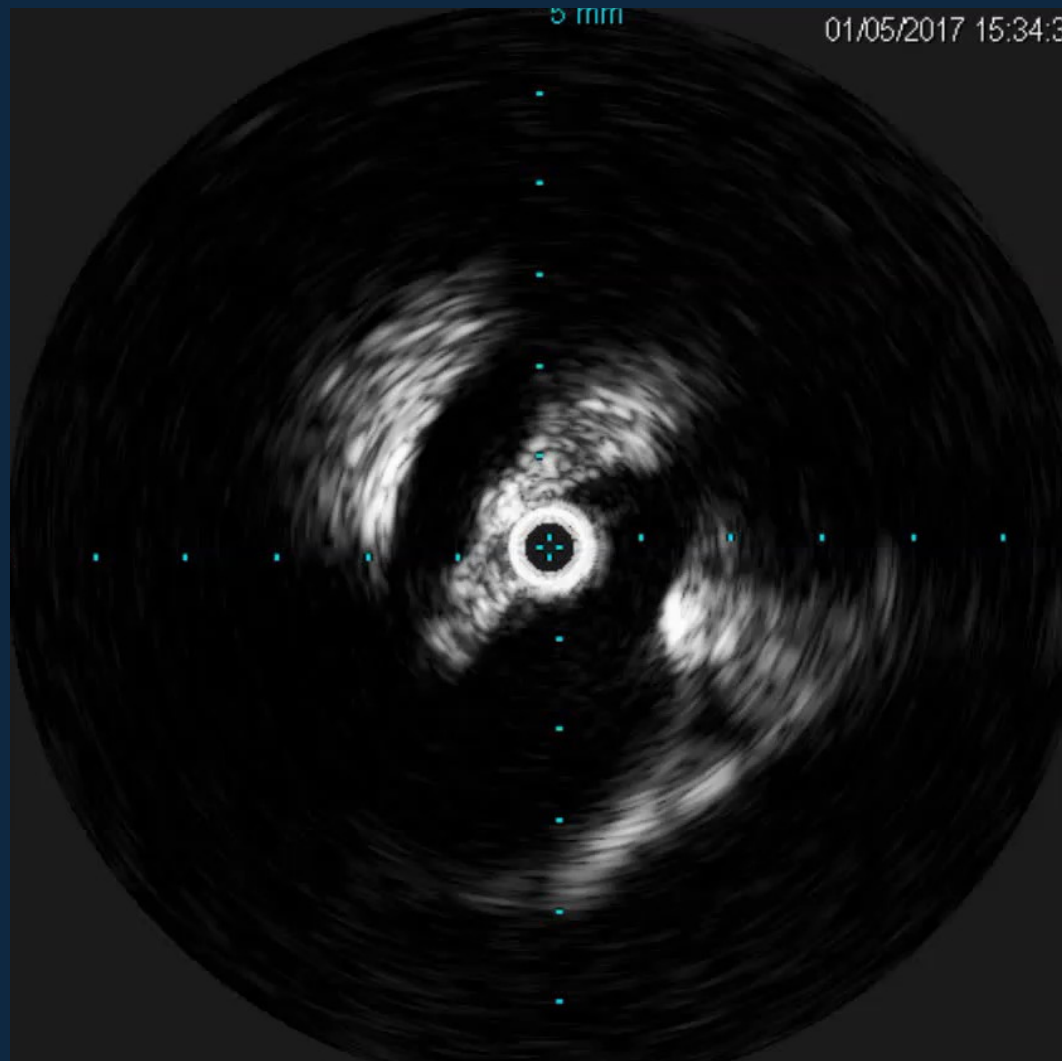
Case 2

- 47y F G3P3
 - Bilateral flank/back pain, left >>right, for 2 yrs. The pain is worse with standing and physical activity (8-9/10) on narcotics
 - s/p Hysterectomy 2/2 to Pelvic Congestion Syndrome 5 yrs ago for pelvic pain
 - Frequent gross hematuria
 - S1 V1P1

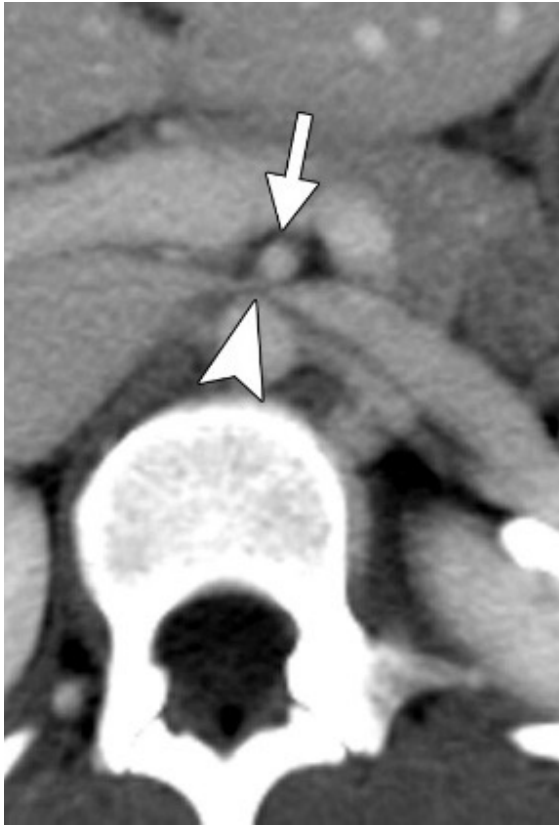








Evaluation of Left Renal Vein Stenosis

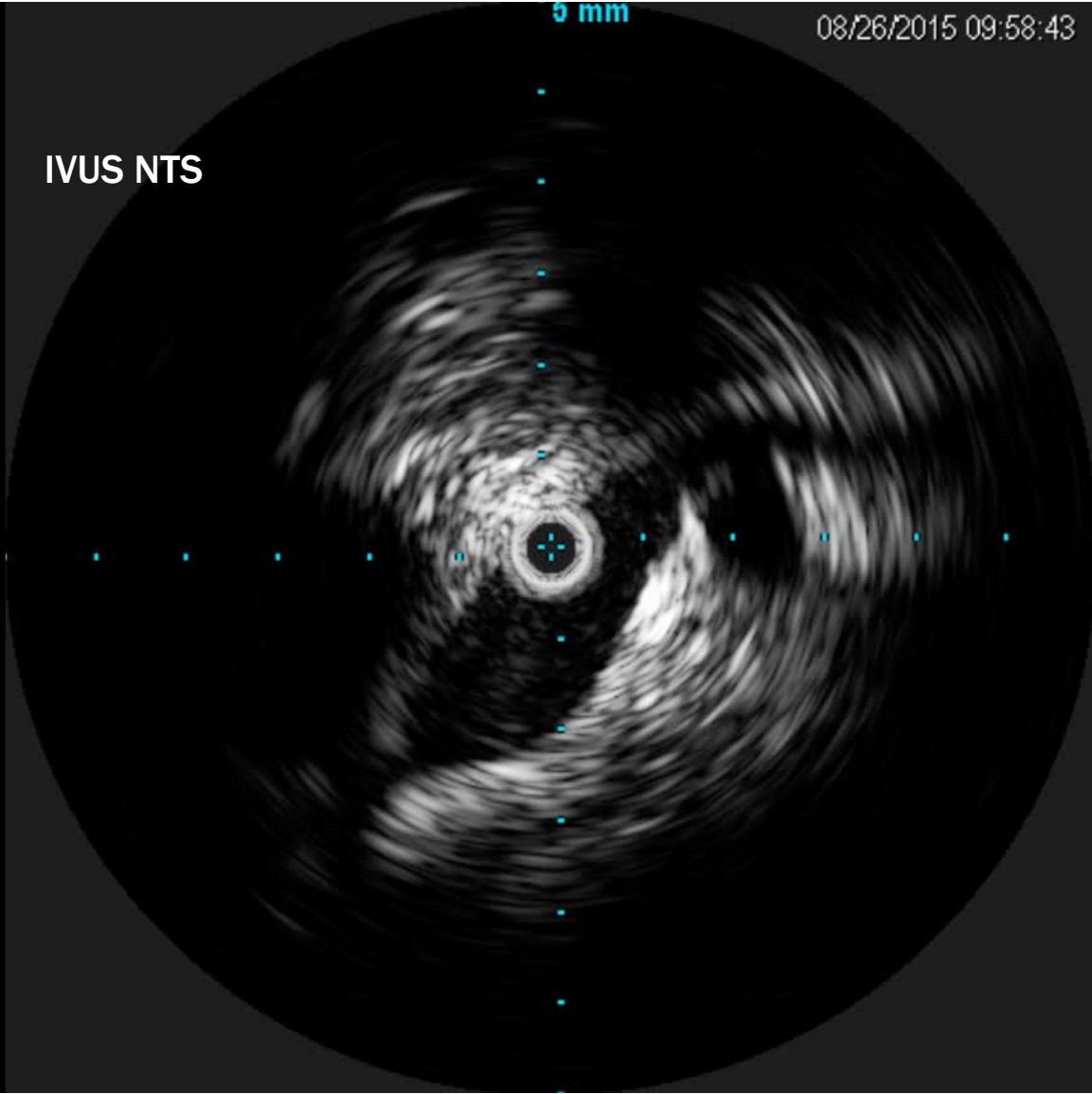


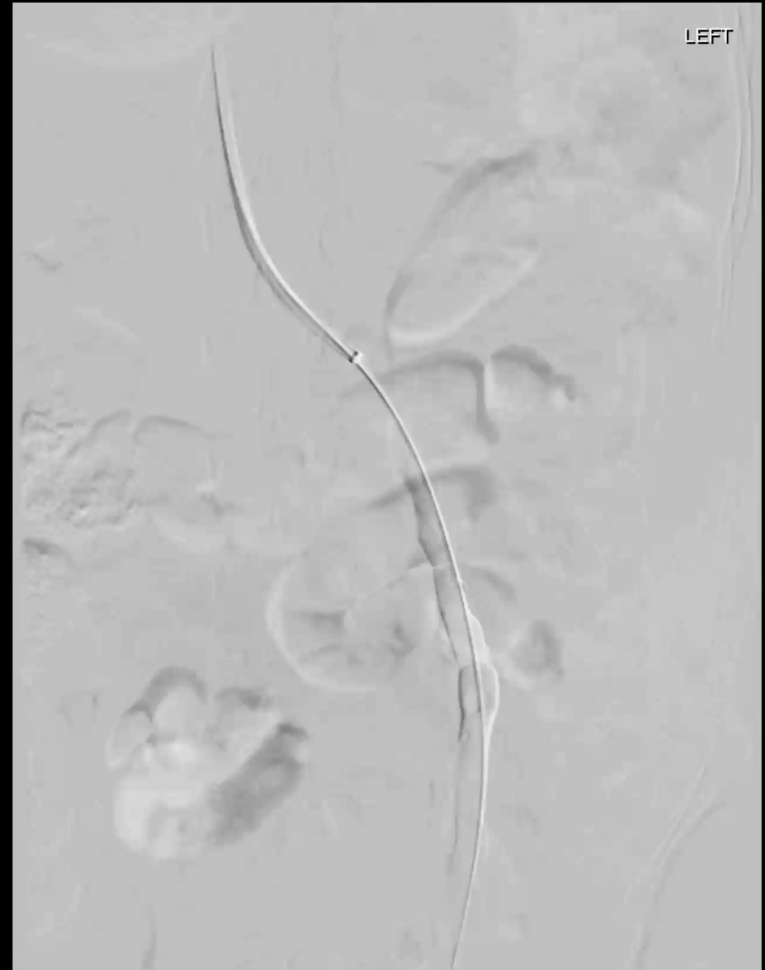
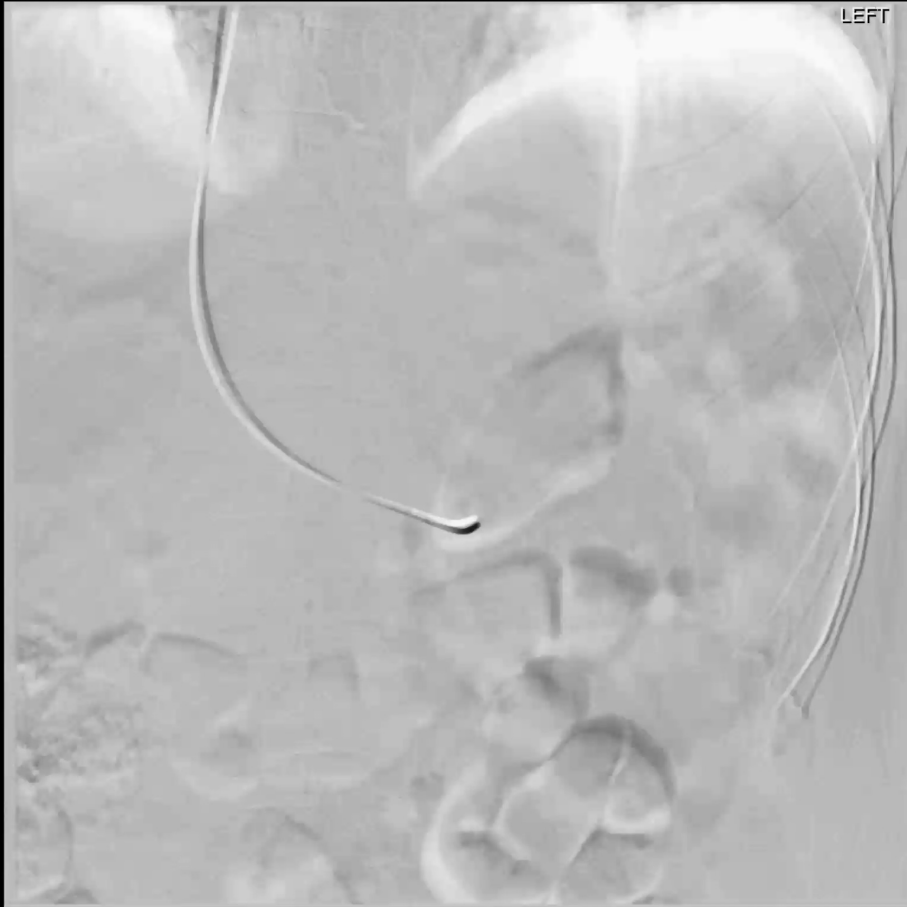- PeVD: prevalence range 8%-26%
- Management depends on clinical presentation
 - ✓ Stenting
 - ✓ Embolization
 - ✓ LRV/SMA transposition
 - ✓ Gonadocaval bypass
- **Multidisciplinary evaluation**

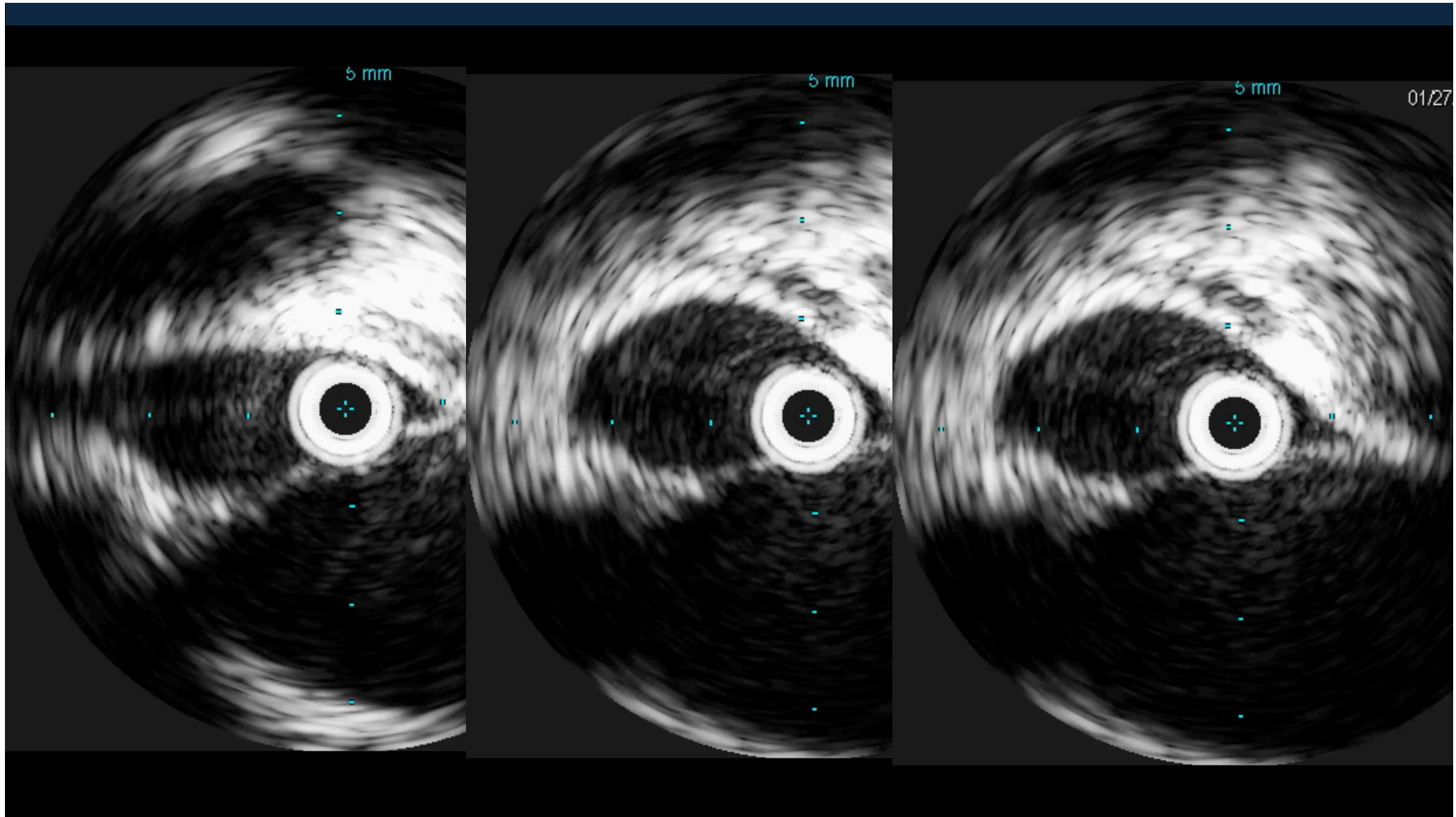
5 mm

08/26/2015 09:58:43

IVUS NTS

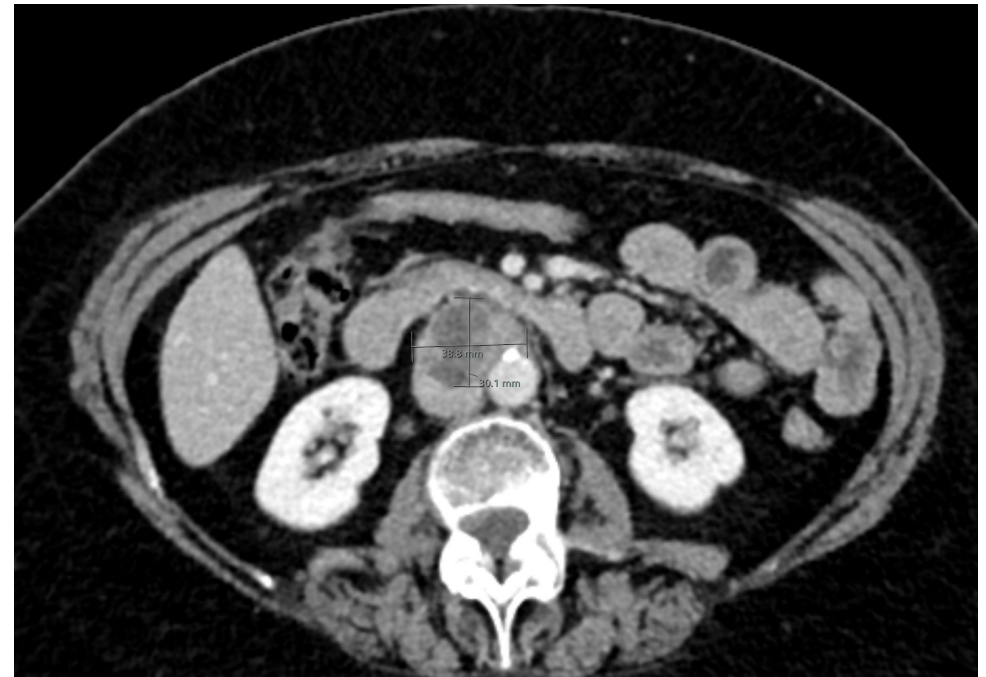





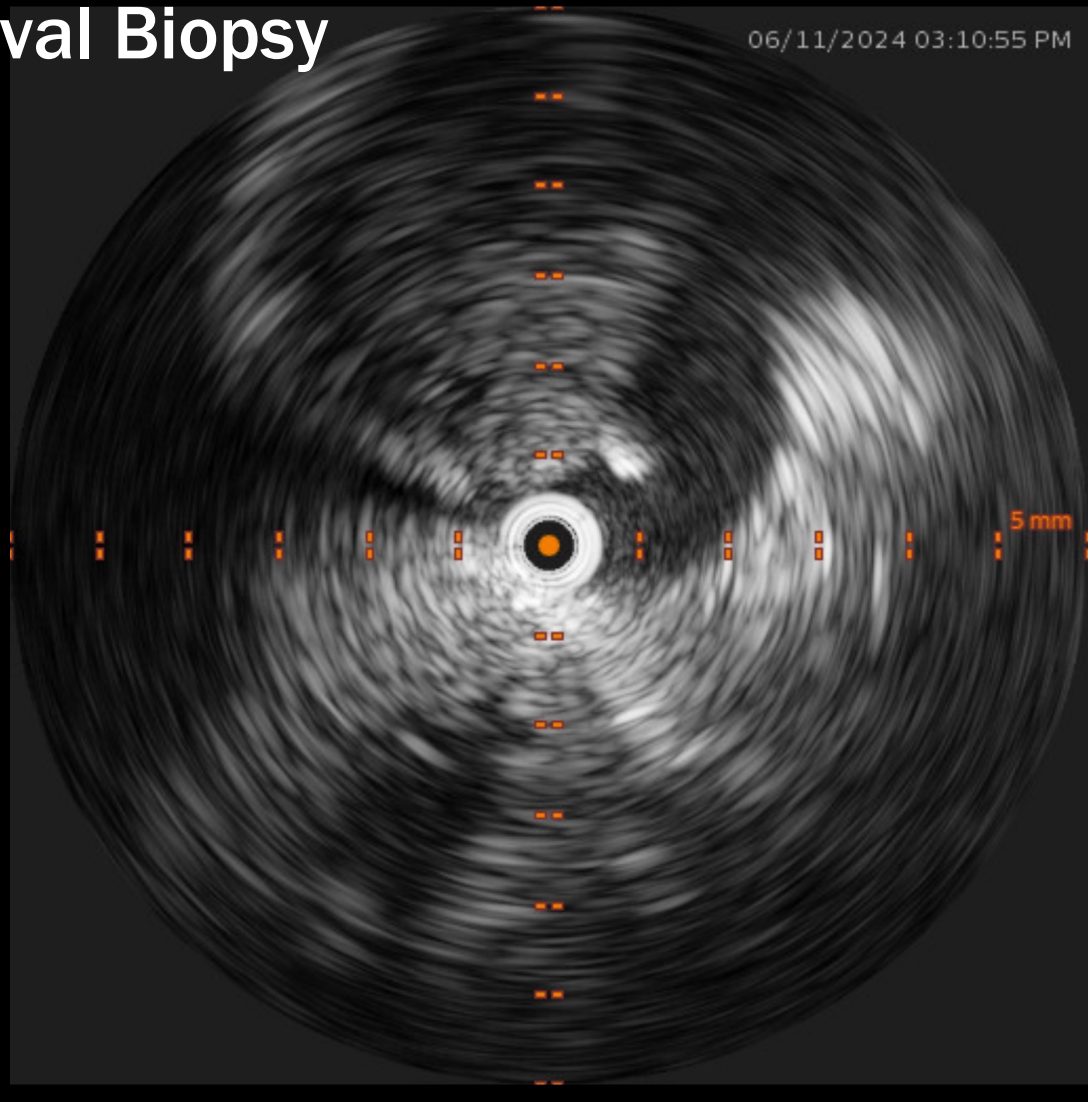
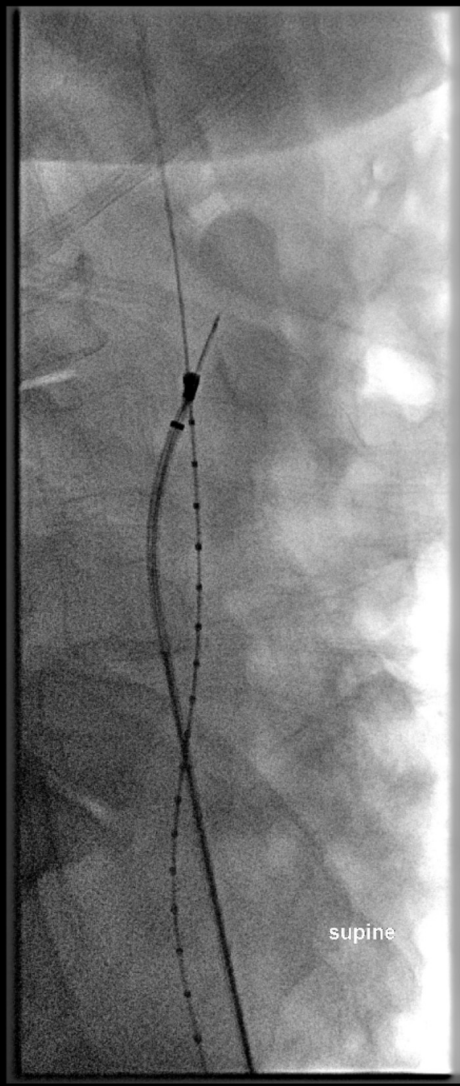
Transcaval Biopsy Retroperitoneal Masses

- **Diagnostic Yield:** 90% per-procedure diagnostic accuracy for retroperitoneal lymph node biopsy
- **Complications:** Rare, serious adverse events like venous thrombosis or injury to adjacent vessels

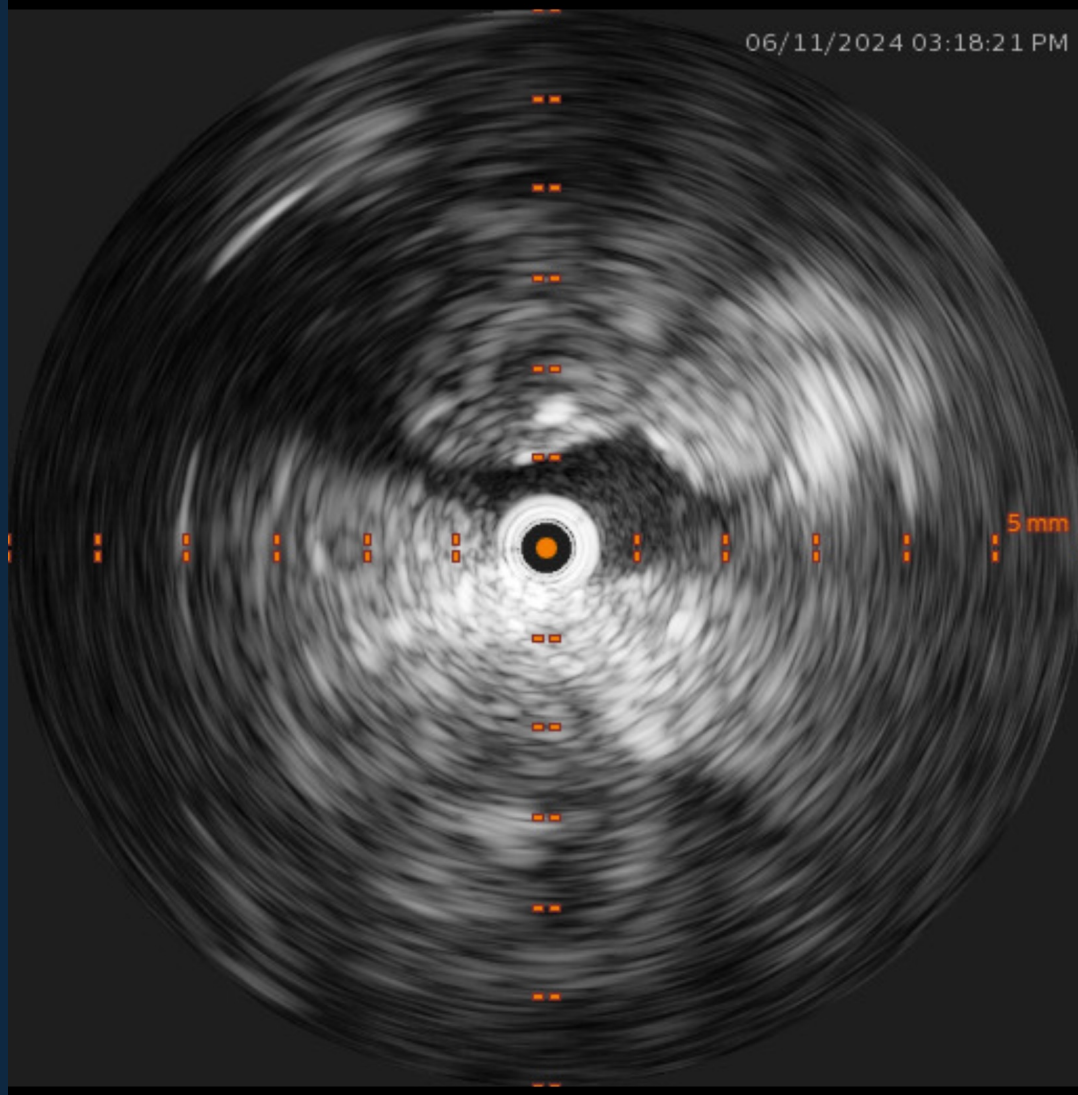


Transcaval Biopsy

06/11/2024 03:10:55 PM



06/11/2024 03:18:21 PM



5 mm

Takeaways: IVUS

Superior performance compared to standard venography, it's an essential tool for diagnosing and treating ISR. It also helps identify different treatment pathways for stenosis and is the primary tool for reinterventions of venous stenting.

The background features a series of overlapping, wavy bands in various shades of blue and teal, creating a sense of depth and movement. The lines are closely spaced and curve across the frame.

Thank You